UC SOUTHERN REGIONAL LIBRARY FACILITY
G 000 005 878 4

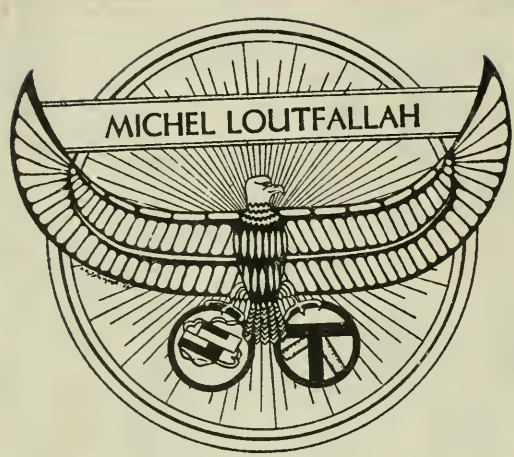

THE LIBRARY
OF
THE UNIVERSITY
OF CALIFORNIA
LOS ANGELES

LINDSAY & BLAKISTON'S

NEW ISSUES FOR THE PRESENT SEASON, NOW READY.

January, 1869.

1.

On Chronic Bronchitis,

Especially as Connected with Gout, Emphysema, and Diseases of the Heart. Being Clinical Lectures delivered at the Middlesex Hospital, by E. Headlam Greenhow, M.D., Fellow of the Royal College of Physicians, Consulting Physician to the Western General Dispensary, &c., &c.

One volume. Octavo. Price, $2.25.

The purpose of this volume is to demonstrate the frequently constitutional character of Chronic Bronchitis, and its intimate association with many other diseases, in the relation either of cause or of consequence.

In the earlier lectures the author has endeavored to show, from the results of a large analysis of cases, and also from the history of many individual cases, in how small a proportion of bronchitic patients the liability to suffer from Chronic Bronchitis can be traced exclusively to catarrh, and in how large a proportion it can be referred to catarrh only in connection with one of three internal predisposing causes; namely, long-standing mechanical irritation of the bronchial membrane; some form of Dyscrasia; or previous illness of some other kind. The Gouty Dyscrasia is shown to be, of all others, perhaps the most fruitful source of Chronic Bronchitis. The fifth and sixth lectures deal with the subject of Pulmonary Emphysema; showing from an analysis of cases, and also from detailed cases, that Emphysema is frequently hereditary; that it is frequently found in connection with the Gouty Dyscrasia; and, lastly, that it is not unfrequently developed, in these circumstances, previous to the existence of Chronic Bronchitis. These facts, in the Author's opinion, prove the mainly constitutional character of Pulmonary Emphysema, and lead to the further conclusion that the degeneration of the tissue of the lungs which predisposes them to yield to mechanical causes of distension, in coughing or otherwise, is often a result of the Gouty Dyscrasia. In the seventh and eighth lectures, the relations between Bronchitis and Diseases of the Heart are fully considered. Bronchitis is shown to be a frequent sequel to diseases of the left side of the heart; whilst it is, on the other hand, itself a direct cause of disease of the right side of the heart.

The practical conclusion suggested by the work is that the first step towards the successful treatment of Chronic Bronchitis must be the discovery, and, in so far as may be possible, the removal, or alleviation, of the internal condition which, in so many cases, is the remote cause of the patient's ailment.

2.

The Pennsylvania Hospital Reports. (Published Annually.)

Volume 2, for 1869. Containing Papers by Drs. Addinell Hewson, T. G. Morton, Da Costa, Hutchinson, E. Hartshorne, John Ashhurst, Jr., Hunt, Packard, Agnew, Harlan, Tyson, Richardson, J. F. Meigs, Wm. Pepper, &c., &c. Illustrated by lithographic plates and engravings on wood.

Octavo, cloth. Price, to subscribers, $4.00.

3.

A Treatise on the Diseases of the Eye,

Illustrated by Ophthalmoscopic Plates done in Chromo-Lithography, and engravings on wood. By J. Sœlberg Wells, Professor of Ophthalmology in King's College, London; Ophthalmic Surgeon to King's College Hospital, and Assistant Surgeon to the Royal London Ophthalmic Hospital, &c., &c.

One volume, octavo, bevelled cloth. Price, $9.00.

The great reputation of the Author of this volume, and his long experience in the treatment of Diseases of the Eye, together with the unusual facilities possessed by him, as Professor of Ophthalmology, and as Surgeon to King's College, and the Royal London Ophthalmic Hospital, has enabled him to make it the most complete and comprehensive work on the subject in the English Language.

It embodies all the most recent views in Ophthalmology, as well as the newest operations upon the eye, fully illustrated. The Ophthalmoscope and its Use in the internal diseases of the eye, receives, also, the fullest consideration, and is illustrated by beautifully colored plates.

4.

A History of the Medical Department of the University of

Pennsylvania, from its foundation in 1765, with illustrative sketches of Deceased Professors, &c., &c. By Joseph Carson, M.D., Professor of Materia Medica and Pharmacy in that Institution.

One volume, octavo. Price, $3.00.

5.

Kidney Diseases, Urinary Deposits, and Calculous Disorders,

Their nature and treatment, containing seventy plates and tables for the Clinical Examination of Urine. By Lionel S. Beale, M.D., F.R.S., &c., &c. Third edition, much enlarged.

Octavo, printed on tinted paper. Price, $12.00.

ALSO,

Beale's How to Work with the Microscope.

Fourth Edition. Over 400 Illustrations.

Octavo, cloth. Price, $10.00.

Beale, The Microscope in its Application to Practical Medicine.

Third edition, with numerous Illustrations.

Octavo. Price, $7.50.

6.

Mackenzie on the Use of the Laryngoscope

In Diseases of the Throat. Second Edition, with additions, and an Essay on Hoarseness, Loss of Voice, and Stridulous Breathing in relation to Nervo-Muscular affections of the Larynx. Edited by J. Solis Cohen, M.D., and Illustrated by two lithographic plates, and fifty-one engravings on wood.

Octavo. Price, $3.00.

7.

Cazeaux's Great Work on Obstetrics,

The most RECENT AND COMPLETE TEXT BOOK now published. The fifth American, from the seventh French edition, greatly enlarged and improved, containing over 1100 royal octavo pages, and 175 illustrations. Price, bound in cloth, $6.50.

do. do. leather, $7.50.

8.

"The Representative Book of Medical Science."—LONDON LANCET.

Aitken's Science and Practice of Medicine.

Second American from the fifth London edition. Now ready. In 2 volumes, containing over 2000 royal octavo pages, a Colored Map, Lithographic Plate, and one hundred and thirty Illustrations on Wood. Two volumes, royal octavo, bound in cloth, $12.00.

do. do. do. leather, $14.00.

The first American edition of this work was out of print in little more than twelve months after publication. So rapid a sale may be accepted as an evidence of its appreciation by the profession of this country, and as a recognition of its claim to being a fair exposition of the Medical Science and Art of the day.

The present edition, besides being thoroughly revised by the Author, is edited with special reference to the wants of the American practitioner; it contains many additions to the Author's text, and THIRTY-SIX NEW articles, several of them on subjects now introduced for the first time in any text-book on the practice of medicine. The new matter thus added, by the American Editor, Meredith Clymer, M.D., being equal to over 500 pages of the London edition.

9.

Hillier's Clinical Treatise on the Diseases of Children.

An entirely new and original work.

8vo., cloth. Price, $3.00.

10.

Hewitt's Diagnosis, Pathology and Treatment of Diseases

Of Women, including the Diseases of Pregnancy. Second edition, revised and enlarged, and containing an entirely new series of Illustrations. Price, in cloth, $5.00.

do. leather, $6.00.

11.

Prof. Biddle's Materia Medica,

For the use of Students.

The third revised and enlarged edition.

Price, $4.00.

12.

Lindsay & Blakiston's Physicians' Visiting List,

For 1869. Published Annually. Of various sizes, prices, and styles of binding. See complete catalogue.

13

Beasley's Druggists' General Receipt Book

And Veterinary Formulary. The seventh American edition.

Price, $3.50.

14.

Birch, on Constipated Bowels,

The various causes of the disease, and modes of treatment.

Third edition, 12mo., cloth, $1.25.

15.

Wythe's Physicians' Pocket Dose and Symptom Book.

Eighth edition, 32mo., cloth. Price, $1.00.

do. do. leather, with tucks and pockets, $1.25.

16.

Cleaveland's Pronouncing Medical Lexicon,

A new and improved edition (the eleventh).

Price, $1.25.

17.

Richardson's Practical Treatise on Mechanical Dentistry.

A new and much enlarged edition, containing 150 Illustrations.

Bound in Leather. Price, $4.50.

18.

Taft's Practical Treatise on Operative Dentistry.

A new and thoroughly revised edition, with over 100 Illustrations.

Price, bound in leather, $4.50.

19.

Robertson's Manual on Extracting Teeth,

With Illustrations. A new revised edition.

Price, $1.50.

20.

Goff's Physicians' Combined Day Book, Ledger and Register

For Patients. (For plan and description see Prospectus in general Catalogue.) A quarto volume, strongly bound.

Price, $12.00.

A FULL DESCRIPTIVE CATALOGUE

Of all our Publications, with prices attached, furnished free by Mail or otherwise, upon application.

LINDSAY & BLAKISTON, *Publishers*,

25 South Sixth St., Philadelphia.

A TREATISE

ON THE

DISEASES OF THE EYE.

A TREATISE

ON THE

DISEASES OF THE EYE

BY

J. SOELBERG WELLS,

PROFESSOR OF OPHTHALMOLOGY IN KING'S COLLEGE, LONDON, OPHTHALMIC SURGEON TO KING'S COLLEGE HOSPITAL, AND ASSISTANT SURGEON TO THE ROYAL LONDON OPHTHALMIC HOSPITAL, MOORFIELDS.

PHILADELPHIA:
LINDSAY AND BLAKISTON.

MDCCCLXIX.

The right of Translation is reserved.

LONDON:
HARRISON AND SONS, PRINTERS IN ORDINARY TO HER MAJESTY, ST. MARTIN'S LANE.

Barnes
WU
100
W462t
1869

TO

PROFESSOR ALBRECHT VON GRAEFE,

THIS WORK IS DEDICATED,

AS A

SLIGHT TRIBUTE OF ADMIRATION FOR HIS EMINENT MERITS IN THE ADVANCEMENT OF OPHTHALMOLOGY,

AND OF

GRATITUDE FOR HIS UNVARYING KINDNESS AND FRIENDSHIP,

BY

THE AUTHOR.

PREFACE.

WITHIN the last few years the want has often been expressed of an English treatise on the diseases of the eye, which should embrace the modern doctrines and practice of the British and Foreign Schools of Ophthalmology, and should thus enable the practitioner and student to keep up with the knowledge and opinions of the present day.

I now venture to lay before the profession a work which I trust may be deemed, to a certain extent, worthy to meet this desideratum. Whilst I have endeavoured to enter fully into all the most important advances which have been lately made in Ophthalmic science, I have not contented myself with simply recording the views of others, but have sought in most instances to make myself practically conversant with them, so that I might be able, from my own experience, to form an independent and unbiassed opinion as to their relative value. The vast and peculiarly favourable opportunities which I have had at Moorfields of studying all phases and kinds of eye-disease, as well as the great benefit which I have enjoyed of witnessing the practice and operations of my colleagues, have most materially assisted me in the possibility of doing this.

In preparing this work, I have steadily kept one purpose in view, viz., to make it as practical and comprehensive as possible, and I have, therefore, entered at length into an explanation of those subjects which I have found to be particularly difficult to the beginner. I have, on purpose, occasionally repeated important points in diagnosis and treatment, in order to render each article, to a certain extent, complete in itself,

so as to obviate the necessity of the reader having constantly to refer to other portions of the book for explanation or information. Moreover, I have thought that this would prove of great convenience to those who may desire to consult and study certain subjects, without being obliged to peruse the greater portion of the book.

The subjects of "Injuries to the Eye," and of "Congenital Malformations of the Eye," have assumed such considerable dimensions, that I have been obliged to treat of them somewhat briefly, and would, therefore, refer the reader, who seeks for fuller information, to special treatises upon these affections. Of these, I would particularly recommend the following excellent works:—"Injuries of the Eye, Orbit, and Eyelids," by Mr. George Lawson; "Verletzungen des Auges," by Drs. Zander and Geissler; and the "Malformations and Congenital Diseases of the Organs of Sight," by Sir William Wilde.

My best and warmest thanks are due to my colleagues at the Royal London Ophthalmic Hospital, Moorfields, and more especially to Mr. Bowman, for their constant kindness in permitting me to have free access to their cases, and for affording me much valuable information and advice upon all subjects connected with Ophthalmology.

Owing to the great liberality of my friend Dr. Liebreich, and of his publisher, Mr. Hirschwald of Berlin, I have been able to illustrate this work with 16 excellent coloured ophthalmoscopic figures, which are copies of some of the plates of Liebreich's admirable "Atlas D'Ophthalmoscopie."

As very frequent reference is made to certain Ophthalmic periodicals, I have used the following abbreviations:—

R. L. O. H. Rep. signifies "Royal London Ophthalmic Hospital Reports," edited by Messrs. Wordsworth and Hutchinson (Churchill).

A. f. O. signifies "Archiv für Ophthalmologie," edited by Profs. Arlt, Donders, and Von Graefe (Peters, Berlin).

Kl. Monatsbl. signifies "Klinische Monatsblätter der Augenheilkunde," edited by Prof. Zehender (Enke, Erlangen).

The following symbols are also frequently employed in the course of the work:—A, means range of accommodation; r, punctum remotissimum (far point); p, punctum proximum (near point); ∞ (= 0), infinite distance; $'$, foot, $''$, inch, $'''$, line.

The test types of Jaeger may be obtained from the Secretary of the Royal London Ophthalmic Hospital, Moorfields; and those of Snellen from Messrs. Williams and Norgate, Henrietta Street, Covent Garden.

16, Savile Row,
December, 1868.

CONTENTS.

INTRODUCTION.

PAGE

Eversion of the Upper Eyelid—The mode of ascertaining the degree of Intra-ocular Tension—The examination of the Acuteness of Vision—Mode of examining the Field of Vision—Diplopia—The Compress Bandage—The Artificial Leech—The Eye-douche 1–14

CHAPTER I.

DISEASES OF THE CONJUNCTIVA.

Hyperæmia of the Conjunctiva—Catarrhal Ophthalmia—Purulent Ophthalmia—Gonorrhœal Ophthalmia—Ophthalmia Neonatarum—Diphtheritic Conjunctivitis—Granular Ophthalmia—Acute Granular Ophthalmia—Chronic Granulations—Phlyctenular Ophthalmia—Exanthematous Ophthalmiæ—Xerophthalmia—Pterygium—Symblepharon—Anchyloblepharon—Injuries of the Conjunctiva—Tumours of the Conjunctiva, etc. 15–88

CHAPTER II.

DISEASES OF THE CORNEA.

Pannus—Phlyctenular Corneitis—Fascicular Corneitis—Suppurative Corneitis—Non-Inflammatory Suppurative Corneitis—Ulcers of the Cornea—Diffuse Corneitis—Opacities of the Cornea—Arcus Senilis—Conical Cornea—Kerato-globus—Staphyloma of the Cornea and Iris—Injuries and wounds of the Cornea 89–143

CHAPTER III.

DISEASES OF THE IRIS.

Hyperæmia of the Iris—Inflammation of the Iris—Functional Disturbances of the Iris—Tremulousness of the Iris—Wounds, etc., of the Iris—Tumours of the Iris—Congenital Anomalies of the Iris—Iridectomy—Iridodesis—Corelysis—Iridodialysis—Changes in the contents, etc., of the Anterior Chamber—Irido-choroiditis—Sympathetic Ophthalmia 144–205

Chapter IV.

DISEASES OF THE CILIARY BODY AND SCLEROTIC.

PAGE

Inflammation of Ciliary Body—Injuries of Ciliary Region—Episcleritis—Anterior Sclerotic Staphyloma—Wounds and Injuries of the Sclerotic 206-214

Chapter V.

DISEASES OF THE CRYSTALLINE LENS.

Cataract—Lamellar Cataract—Cortical Cataract—Nuclear Cataract—Traumatic Cataract—Capsular Cataract—Flap Extraction—Removal of the Lens in its Capsule—Linear Extraction—Scoop Extraction—Von Graefe's Operation—Reclination—Division of Cataract—Operations for Lamellar Cataract—Operations for Traumatic Cataract—Removal of Cataract by a Suction Instrument—Sperino's Treatment of Cataract by Paracentesis—Operations for Capsular Cataract—Dislocation of the Lens 215–282

Chapter VI.

THE USE OF THE OPHTHALMOSCOPE.

Theory of the use of the Ophthalmoscope—Ophthalmoscope of Liebreich, Coccius, and Zehender—Fixed Ophthalmoscope of Liebreich, and of Smith and Beck—Binocular Ophthalmoscope of Giraud-Teulon—Ant-ophthalmoscope—The Examination with the Ophthalmoscope—The Examination of the Actual Inverted Image—The Examination of the Virtual Erect Image—The Ophthalmoscopic Appearances of Healthy Eyes—The Optic Disc—The Ophthalmoscopic Appearances of Diseased Eyes 282–312

Chapter VII.

DISEASES OF THE VITREOUS HUMOUR.

Inflammation of the Vitreous Humour—Opacities—Foreign Bodies, etc., in the Vitreous—Persistent Hyaloid Artery 313–326

Chapter VIII.

DISEASES OF THE RETINA.

Hyperæmia of the Retina—Retinitis, Idiopathic and Parenchymatous—Retinitis Albuminurica, Leucæmica, Syphilitica, Apoplectica, Pigmentosa—Detachment of the Retina—Epilepsy of the Retina—Ischæmia Retinæ—Embolism of the Central Artery of the Retina—Hyperæsthesia of the Retina—Tumours of the Retina—Atrophy of the Retina 327–374

Chapter IX.

DISEASES OF THE OPTIC NERVE.

PAGE

Inflammation of the Optic Nerve—Atrophy of the Optic Nerve—Excavation of the Optic Nerve—Pigmentation of the Optic Nerve—Tumours of the Optic Nerve—Opaque Optic Nerve Fibres 375–395

Chapter X.

AMBLYOPIC AFFECTIONS.

Amaurosis—Amblyopia—Hemeralopia—Colour Blindness—Simulation of Amaurosis 396–421

Chapter XI.

DISEASES OF THE CHOROID.

Hyperæmia of the Choroid—Disseminated Choroiditis—Sclerotico-choroiditis Posterior—Suppurative Choroiditis—Colloid Disease of the Choroid—Tubercles of the Choroid—Tumours of the Choroid, Sarcoma, Carcinoma—Formation of Bone—Coloboma of the Choroid—Rupture of the Choroid—Hæmorrhage from the Choroid—Detachment of the Choroid 422–455

Chapter XII.

GLAUCOMA.

Acute Inflammatory Glaucoma—Chronic Inflammatory Glaucoma—Glaucoma Simplex—Secondary Glaucoma—Ophthalmoscopic Symptoms of Glaucoma—The Nature and Causes of the Glaucomatous Process—Prognosis of Glaucoma, etc. 456–487

Chapter XIII.

THE ANOMALIES OF REFRACTION AND ACCOMMODATION OF THE EYE.

The Refraction and Accommodation of the Eye—Optical Lenses, etc.—Mechanism of Accommodation—Negative Accommodation—The Range of Accommodation—Myopia—Presbyopia—Hypermetropia—Astigmatism—Aphakia—Paralysis, Spasm, and Atony of the Ciliary Muscle—Spectacles—Difference in the Refraction of the two Eyes 488–547

Chapter XIV.

AFFECTIONS OF THE MUSCLES OF THE EYE.

PAGE

Actions of the Muscles of the Eye—Paralysis of External Rectus—Paralysis of the Third Nerve—Paralysis of the Internal, Superior, and Inferior Recti, and of the Inferior Oblique—Paralysis of Superior Oblique—Nystagmus—Strabismus—Convergent Strabismus—Divergent Strabismus—Operations for Strabismus, Von Graefe's, Critchett's, Liebreich's—Insufficiency of the Internal Recti Muscles 548–604

Chapter XV.

DISEASES OF THE LACHRYMAL APPARATUS.

Diseases of the Lachrymal Gland—Stillicidium Lacrymarum—Inflammation of the Lachrymal Sac—Blenorrhœa of the Sac—Stricture of the Lachrymal Passages—Fistula of the Lachrymal Sac 605–626

Chapter XVI.

DISEASES OF THE ORBIT.

Inflammation of the Cellular Tissue—Periostitis—Caries and Necrosis—Inflammation of the Capsule of Tenon—Exophthalmic Goitre—Tumours of the Orbit—Vascular Tumours of the Orbit—Effusion of Blood—Emphysema—Pressure upon the Orbit from Neighbouring Cavities—Wounds and Injuries of the Orbit—Excision of the Eyeball—The Application of Artificial Eyes 627–667

Chapter XVII.

DISEASES OF THE EYELIDS.

Œdema and Inflammation of the Eyelids—Syphilitic and Exanthematous Affections—Blepharitis Marginalis—Ephidrosis and Chromhydrosis—Hordeolum—Tumours of the Eyelids—Ptosis—Paralysis of the Orbicularis—Blepharospasm—Trichiasis and Distichiasis—Entropium—Ectropium—Injuries, Wounds, etc., of the Eyelids 668–717

A TREATISE

ON THE

DISEASES OF THE EYE.

INTRODUCTION.

In order to avoid unnecessary repetition in the course of this work, I think it advisable to give in this introduction a brief description of some of the more important and frequent modes of examination of the eye, as well as of certain remedies and appliances in common use in ophthalmic practice.

Eversion of the upper eyelid has frequently to be practised if the presence of a foreign body is suspected beneath it, or if certain remedies are to be applied to its lining membrane. Various contrivances have been suggested for facilitating this proceeding, but it is best done in the following manner:—The patient being directed to look downwards, the surgeon seizes lightly the central lashes of the upper lid between the forefinger and thumb of his left hand, and draws the lid downwards, and somewhat away from the eyeball. He next places the tip of the forefinger of his right hand on the centre of the lid, about half an inch from its free margin. With a quick movement, the edge of the lid is to be then turned over the tip of the forefinger (which should be simultaneously somewhat pressed downwards). By slightly pressing the edge of the everted lid backwards against the upper edge of the orbit, the whole retro-tarsal fold will spring into view, and the lid become fully everted. In those exceptional cases in which the patient is very unmanageable, and forcibly contracts the orbicularis muscle, it may be necessary to use a probe, or the end of a quill pen or pencil, over which to turn the lid, instead of the forefinger. But as a rule it is more convenient to employ the latter, as we may not always have a probe at hand, and as anything in the shape of an instrument frightens some patients, whereas we may often succeed in everting the lid with the finger, before they have even time to resist. The surgeon may also stand behind the patient, and steady the head of the latter against his breast, and evert the lid from behind.

The oblique or focal illumination is in constant requisition for ascertaining the condition of the structures of the anterior half of the eyeball. By its aid we are enabled to examine with great minuteness the appearances presented by the cornea, iris, pupil, lens, and even the most anterior portion of the vitreous humour. This mode of examination is to be thus conducted:—A lamp being placed somewhat in front and to one side of the patient, at a distance of from 2—2½ feet [fig. 1], and on a level with his eye, the light is concentrated upon the cornea or the crystalline lens by a strong bi-convex lens of 2—2½ inches

Fig. 1.

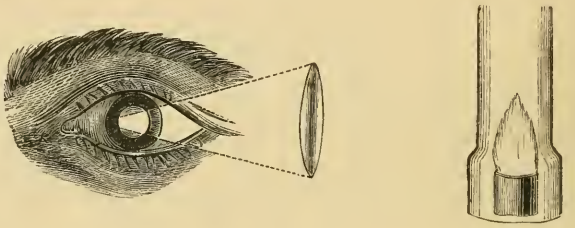

focus. The observer's eye is then to be placed on one side of the patient, so as to catch the rays emanating from the eye of the latter. By shifting the cone of light from one portion of the cornea or lens to another, we may rapidly, yet thoroughly, examine their whole expanse and detect the slightest opacity. In order to gain a larger image, we may employ a second lens as a magnifying glass. Opacities of the cornea or lens will appear by the oblique illumination (reflected light) of a light grey or whitish colour, whereas with the ophthalmoscope (transmitted light) they will appear as dark spots upon a bright red background.

The method of examining the eye with the ophthalmoscope will be found described, at length, in the section upon the ophthalmoscope.

The mode of ascertaining the degree of intra-ocular tension is as follows:—The patient being directed to look slightly downwards, and gently to close the eyelids, the surgeon applies both his forefingers to the upper part of the eyeball behind the region of the cornea. The one forefinger is then pressed slightly against the eye so as to steady it, whilst the other presses gently against the eye, and estimates the amount of tension, ascertaining whether the globe can be readily dimpled, or whether it is perhaps of a stony hardness, yielding not in the slightest degree even to the firm pressure of the finger. The beginner will do well to make himself thoroughly conversant with the normal degree of tension, by the examination of a number of healthy eyes, and then, if

he should be at all in doubt as to the degree of tension in any individual case, he should test the tension of the patient's other eye (if healthy), or that of some normal eye, so as to be able to draw a comparison between them. If there is much œdema of the lids, or conjunctival chemosis, or if the eyes are small and deeply set, it may be difficult accurately to estimate the degree of tension.

I would call particular attention to the signs which Mr. Bowman has devised for the designation of the different degrees of tension of the eyeball, as they will be found most useful, not only in practice, but also in the reporting of cases, or in the preservation of an accurate record of the state of tension.

Mr. Bowman introduced this subject to the attention of the profession in 1862, in his admirable paper "On Glaucomatous Affections, and their Treatment by Iridectomy," read before the Annual Meeting of the British Medical Association,* in which he says, "I have long paid special attention to the subject of tension of the globe, and particularly since it has assumed so much additional importance in the last few years. I have found it possible and practically useful to distinguish nine degrees of tension; and, for convenience and accuracy in note-taking, have designated them by special signs. The degrees may be thus exhibited:†

"T represents *tension* ('t' being commonly used for 'tangent,' the capital T is to be preferred). Tn, *tension normal*. The interrogative, ?, marks a *doubt*, which in such matters we must often be content with. The numerals following the letter T, on the same line, indicate the *degree of increased tension;* or if the T be preceded by —, of *diminished tension*, as farther explained below. Thus:

"T 3. *Third* degree, or *extreme tension*. The fingers cannot dimple the eye by firm pressure.

"T 2. *Second* degree, or *considerable tension*. The finger can slightly impress the coats.

"T 1. *First* degree, *slight* but *positive increase of tension*.

"T 1 ?. Doubtful if tension is increased.

"Tn. Tension normal.

"—T 1 ?. Doubtful if tension be less than natural.

"— T 1. First degree of reduced tension. Slight but positive reduction of tension.

"— T 2 } Successive degrees of reduced tension, short of such
"— T 3 } considerable softness of the eye as allows the finger to sink in the coats. It is less easy to define these by words.

* "British Medical Journal," Oct. 11th, 1862, p. 378.

† "Since this paper was read I have simplified the signs, with the concurrence of my friend, Professor Donders, in order to adapt them for general use. The simplified form has been substituted above."

"In common practice, some of these may be regarded as refinements; but in accurate note-taking, where the nature and course of various diseases of the globe are under investigation, I have found them highly serviceable, and they have as much precision as perhaps is attainable or desirable.

"It is also to be borne in mind that the normal tension has a certain range or variety in persons of different age, build, or temperament; and according to varying temporary states of system as regards emptiness or repletion. Experience will make every one aware of these varieties, which do not encroach on the above abnormal grades of tension. Medical men may understand how important is this matter of the *degree of tension*, by considering how priceless would be the power of accurately estimating it *by the touch* in the case of various *head affections*."

For the examination of the acuteness of vision various test-types are used, more especially those of Jaeger and Snellen. The former do not, however, afford a perfect clue to the acuteness of vision, for a person may be able to read No. 1 of Jaeger with facility and yet not enjoy a normal acuteness of sight. Snellen has, however, devised a set of test-types which fulfil this desideratum. The letters are square and their size increases at a definite ratio, so that each number is seen at an angle of five minutes. Thus, No. 1 is seen by a normal eye up to a distance of one foot, at an angle of five minutes, No. 2 up to two feet, and so on. These numbers cannot, as a rule be seen distinctly beyond these distances.*

Now, if the eye is suffering from any diminution of acuteness of vision, it will require to see the letters under a larger angle than that of five minutes, in order to gain larger retinal images. No. 1 cannot be read at a distance of one foot, but only, perhaps, No. 4 or 5. We may easily calculate the degree of the acuteness of vision thus:

"The utmost distance at which the types are recognised (d) divided by the distance at which they appear at an angle of five minutes (D), gives the formula for the acuteness of vision (V): $V = \frac{d}{D}$.

* At Professor Longmore's suggestion, Dr. Snellen has given in his second edition of the test-types some tables containing a series of figures and single numbers, for the examination of such recruits for the British army as are unable to read. For further information as to the examination of the sight of recruits, I must refer the reader to Professor Longmore's excellent "Ophthalmic Manual," which I would also recommend to the especial notice of the surgeons of the Militia and Volunteer Corps. These test-types may be obtained at Messrs. Williams and Norgate's, Henrietta-street, Covent Garden.

" If d and D be found equal, and No. 20 be thus visible at a distance of twenty feet, then $V = \frac{20}{20} = 1$; in other words, there is normal acuteness of vision. If, on the contrary, d be less than D, and if No. 20 is only visible within ten feet, No. 10 only within two feet, No. 6 only within one foot, these three cases are thus respectively expressed :

$$V = \frac{10}{20} = \frac{1}{2}; \; V = \frac{2}{10} = \frac{1}{5}; \; V = \frac{1}{6}.$$

d may sometimes be greater than D, and No. 20 be visible at a greater distance than twenty feet. In this case vision is more acute than the normal average."

It must, however, be confessed that some patients (more especially amongst the lower classes) often experience a difficulty in fluently reading type composed of these square letters. They have always been accustomed to ordinary type, the letters of which are of unequal thickness, and differ both in dimension and definition. I, therefore, generally employ Jaeger's test-types for ascertaining the fluency with which small print can be read, and those of Snellen, for testing with accuracy the acuteness of vision.

Besides examining the acuteness of vision, it is often of much importance to ascertain with accuracy and care the condition of the field of vision, which may be readily done in the following manner :— The patient, being placed straight before us, at a distance of from fifteen to eighteen inches, is directed to look with the eye under examination (closing the other with his hand) into one of our eyes, his right eye being fixed upon our left, and *vice versâ*. In this way any movement of the eye may be at once detected and checked. Whilst he still keeps his eye steadily fixed upon ours, we next move one of our hands in different directions throughout the whole extent of the field of vision (upwards, downwards, and laterally), and ascertain how far from the optic axis it is still visible ; we then approach the hand nearer to the optic axis, and examine up to how far from it he is able to count fingers in different directions. The number of the extended fingers is to be constantly changed, and the examination to be repeated several times, so that we may ascertain whether the patient can count them with certainty, or whether he hesitates in his answers, or only guesses at their number. We may thus readily discover whether the field of vision is of normal extent, or whether it is defective or altogether wanting in certain directions.

We may term that part of the field in which the patient can still distinguish an object (a hand, a piece of chalk, &c.) the *quantitative* field of vision, in contradistinction to that smaller portion in which

he is able to count fingers, and which may be designated the *qualitative* field.

The following method of examining the field is still more accurate, and I should advise its adoption in all cases where it is of importance to have an exact map of the extent of the field, as in glaucoma, detachment of the retina, &c., so that a record may be kept of the condition of the field during the progress of the disease, or that we may be able to compare its extent before and after an operation. The patient being placed before a large black board, at a distance of from twelve to 16 inches, is directed to close one eye and to keep the other steadily fixed upon a chalk dot, marked in the centre of the board and on a level with his eye. A piece of chalk, fixed in a dark handle, is then gradually advanced from the periphery of the board towards the centre, and the spot where the chalk first becomes visible is then marked upon the board. This proceeding is to be repeated throughout the whole extent of the field; the different points at which the object first becomes visible are then to be united by a line, which indicates the outline of the *quantitative* field of vision. The extent of the *qualitative* visual field is next to be examined, and it is to be ascertained how far from the central spot the patient can count fingers in different directions. The points thus found are also to be marked on the board, and the marks afterwards united with each other by a line, which should be of a different colour or character to that indicating the extent of the quantitative field, so that the two may not be confounded. It need hardly be mentioned that care is to be taken that during the examination the patient's eye remains steadily fixed upon the central spot, that the other eye is kept closed, and that his distance from the board is not altered. The extent of the field inwards will, naturally, vary according to the prominence of the patient's nose.

It is still more convenient to map out the field upon a large piece of blue paper placed against the board, as this saves us the trouble of copying the map from the latter. Such maps are to be kept for future reference, or for comparison with others that may be taken of the same case at a later period. If this, however, cannot be done, we may keep a record of the shape of the field, and of the distance to which the patient can see in different segments of it, by the following simple expedient which I have for some time adopted.

The board is to be divided into four equal parts by a vertical and horizontal line (of about 4 feet in length), cutting each other at the central cross; each quadrant is then again to be divided into two equal parts by another line, so that the whole is divided into eight equal segments, as in the accompanying figure (fig. 2) which represents the division of the field for the left eye. For the right eye the position of the letters must be reversed, thus *u i* (upwards and

inwards), would be *u o* (upwards and outwards), and so with all the others.

The meaning of the letters is as follows :—

V M—Vertical Meridian, dividing the field into two lateral halves (inner and outer).

H M—Horizontal Meridian, dividing the field into an upper and a lower half.

The upper half of the field is subdivided into four segments :—

u o upper and outer segment.
o u outer ,, upper ,,
u i upper ,, inner ,,
i u inner ,, upper ,,

The lower half is also subdivided into four segments :—

o l outer and lower segment.
l o lower ,, outer ,,
i l inner ,, lower ,,
l i lower ,, inner ,,

Fig. 2.

Left Eye.

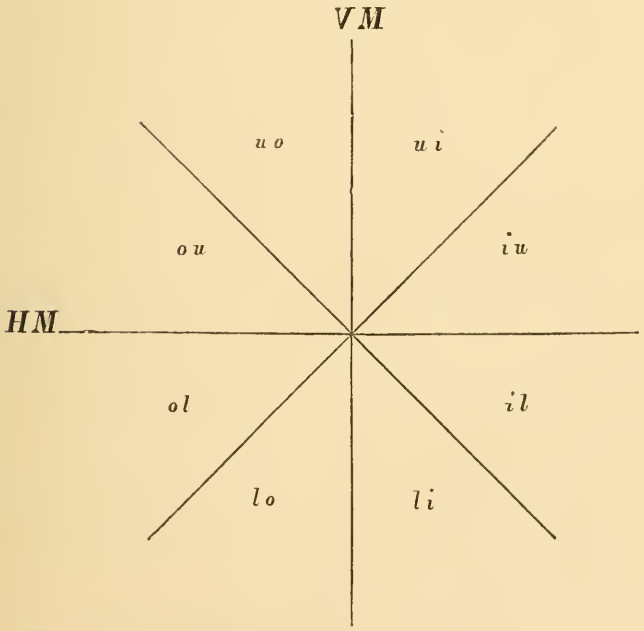

The method of examining the patient's field of vision is to be the same as that above described, when a plain board was used. The object of the divisions is only to furnish a kind of framework for the map of the field, which enables us to sketch it with more ease and rapidity. The boundary of the quantitative and qualitative fields is to be marked both upon and between each of the divisional lines, and the distance of each of these marks from the centre of the board is then to be measured, and its extent, in inches, is to be placed against each mark. A small fac-simile of the field of vision thus mapped out, may then be drawn in the note-book, the field being here also divided into eight segments, the boundaries and measurements of the map being likewise copied; so that we may preserve, in a small and convenient form, an accurate record of the shape and extent of the visual field.

But the sight of the patient may be so much impaired that he can no longer count fingers, even in the optic axis, being only able to distinguish between light and dark, as in cases of mature cataract, severe cases of glaucoma, etc., and yet it may be of great importance to know whether or not the field of vision is of normal extent. This may be readily ascertained in the following manner:—The patient is directed to look with the one eye (the other being closed) in the direction of his uplifted hand (held on a level with his eye, and at a distance of from 12 to 18 inches). A lighted candle is then held in different portions of the visual field, and the furthest point at which it is still visible in various directions is noted, the candle being alternately shaded and uncovered by our hand, so as to test the readiness and accuracy of the patient's answers. Care should also be taken to shade the candle when it is removed to another portion of the field. The light may also be thrown upon various portions of the eyeball by the mirror of the ophthalmoscope, and the patient questioned as to the direction from which the light appears to come.

Mr. Pridgin Teale has devised a modification of the above method, by subdividing the board (already divided by vertical, horizontal, and diagonal lines) by a series of concentric circles. There is, moreover, a travelling white disc of card board, which can be moved from the outer edge of the board to the centre along the diagonal and other lines, thus forming a very convenient and easily recognisable object. There is also a rest to steady the patient's head, and maintain it at a certain distance. He marks the existence of good vision by a + sign, imperfect vision by —, and absence of vision by 0. Blank diagrams are prepared, which are a copy of the markings on the board, on a scale of $\frac{1}{4}$ of an inch to 1 inch of the board.

Wecker employs the following mode of taking the field. He uses a large black board, towards the centre of which can be moved in a

radiating direction a number of small white ivory balls, thus marking the extent of the field; as soon as the ball reaches the limit of the field, it is turned round, and presents its black posterior surface to the patient. On the back portion of the board, the shape and extent of the field can be read off from the position of the white balls, which give its exact delineation.

Double images (*diplopia*).—An object only appears single when both optic axes are fixed upon it; any pathological deviation of either optic axis must necessarily cause diplopia, as the rays from the object do not then fall upon identical portions of the retina. The slightest degree of diplopia is that in which the double images are not distinctly defined, but seem to lie slightly over each other, so that the object appears to have a halo round it.

We meet with two kinds of double images.

1. *Homonymous* (or *direct*) diplopia, in which the image to the right of the patient belongs to his right eye, the left image to the left eye.

2. *Crossed* double images, in which case the image to the right of the patient belongs to his left eye, that on his left to his right eye.

Homonymous diplopia is always produced (except in incongruence of the retinæ) in convergent squint, for if the eye deviates inwards from the object, the rays coming from the latter will fall upon the inner portion of the retina, and the image will (in accordance with the laws of projection) be projected outwards, as in fig. 3.

Fig. 3.

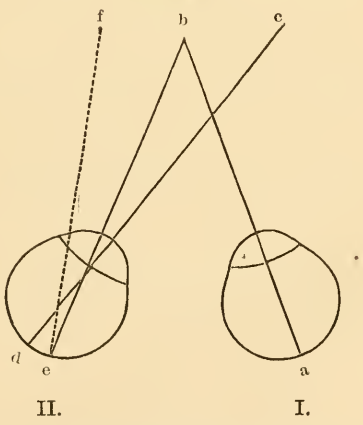

Let I. be the right eye, whose optic axis is fixed upon the object (b). II. The left eye, whose optic axis (c d) deviates inwards from the object; the rays from b therefore fall upon e, a portion of the retina internal to the yellow spot (d), and the image is consequently projected outwards to f; b and f are, therefore, homonymous double images, the image b, which is to the right of the patient, belonging to his right eye, the image f to his left eye.

Crossed double images arise in divergent squint, for as the one eye deviates outwards from the object, the rays from the latter fall upon a portion of the retina external to the macula lutea, the image is projected inwards, and crosses that of the other eye, as in fig. 4.

I. The right eye, whose optic axis is fixed upon the object (b). II. The left eye, whose optic axis (c d) deviates outwards from the object; the rays from the latter therefore fall upon e, a portion of the retina external to the macula lutea (d), and the image is projected to f, crossing the image b; the image f, which would lie on the patient's right hand, would, therefore, belong to his left eye, the image b, which would lie on his left side, to the right eye.

Fig. 4.

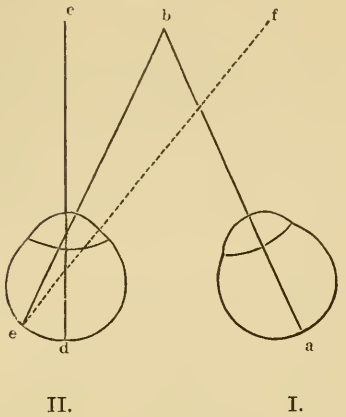

If one eye squints upwards, the rays will fall upon the upper portion of the retina, and the image be projected *beneath* that of the healthy eye. The reverse will be the case if the eye squints downwards, for then the rays will fall upon the lower portion of the retina, and the image will be projected *above* that of the healthy eye.

We should never forget to ascertain whether the diplopia be monocular or binocular; in the latter case, it will of course disappear upon the closure of either eye.*

Let us now glance at the action of prisms. When a ray of light falls upon a prism, it is refracted towards its base. If, for instance, whilst we look at an object (*e. g.*, a lighted candle) at 8 feet distance with both eyes, a prism, with its base towards the nose, is placed before the right eye, the rays from the candle will be deflected towards the base of the prism, and fall upon a portion of the retina internal to the yellow spot, and be consequently projected outwards, giving rise to homonymous diplopia. As we are, however, very susceptible of double images, the eye will endeavour to unite them by an outward movement (its external rectus becoming contracted), which will again bring the rays upon the yellow spot, but at the same time of course cause a divergent squint. Fig. 5 will explain this. Let a b be the optic axis

* In examining the double images of a patient, it is convenient to place a slip of red glass before the sound eye, for we thus enable him readily to distinguish the two images by their colour, and we also weaken the intensity of the image of the sound eye, and approximate it more to that of the affected one, whose image, owing to the rays from the object falling upon an eccentric portion of the retina, will be less intense in proportion to the distance of the spot, upon which the rays fall, from the macula lutea.

of the left eye fixed (with the other) upon a candle 8 feet off. Now, if a prism (with its base towards the nose) be placed before the right eye, the rays are refracted towards the base of the prism and do not, as in the other eye, fall upon the yellow spot, but on a portion of the retina (d) internal to the latter, and the image is projected outwards to e; homonymous diplopia therefore arises, and to avoid this the external rectus muscle contracts and moves the eye outwards, so as to bring the macula lutea (c) to that spot (d) to which the rays are deflected by the prism. As the rays from the object will now fall in both eyes upon the macula lutea, single vision will result, accompanied, of course, by a divergent squint of the right eye.

Fig. 5.

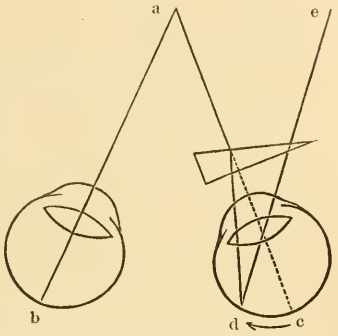

The reverse will occur if we turn the prism with its base to the temple, for then the rays will be deflected to a portion of the retina to the outer side of the macula lutea, and the image will be projected inwards across that of the left eye, and crossed diplopia will be the result. In order to remedy this, the internal rectus will contract and move the eye inwards, so as to bring the macula lutea to that spot to which the rays are deflected.

The Compress Bandage.—The form of bandage to be employed, as well as its mode of application to the eye, is of much practical importance, and it should vary according to the effect which we desire to produce. If the bandage is applied only for the purpose of keeping the dressing upon the eye, of preventing the movement of the latter and of the eyelids, or of guarding the eye against the effect of light or cold, it need be but of a very simple kind, and I think Liebreich's bandage answers these purposes best. But Von Graefe has shown that the compress and bandage may often be made of great therapeutical value, especially in arresting and limiting suppurative inflammation of the cornea, such as is apt to occur in old and decrepid persons after injuries to the cornea, or an operation (*e.g.*, extraction of cataract). In such cases Liebreich's bandage does not suffice, and we must employ the pressure-bandage of Von Graefe.

Liebreich's bandage consists of a knitted cotton band about 12 inches long and $2\frac{1}{2}$ inches wide. At the one end are two tapes, the one going round the back of the head, the other forming a cross-bar with the first, and passing over the top of the head. The other end of the bandage also carries a tape which is to be tied at the side of the head,

opposite the affected eye, to the one coming round from the back. The principal advantages offered by this bandage are—that it perfectly retains its position without slipping, and that it can be undone and the dressings changed without the patient's head having to be raised from the pillow. If the thick knitted band proves heavy and hot, I substitute for it a band of fine muslin or of elastic web. The bandage is to be applied over the following dressing:—The patient being directed gently to close his eyes, a piece of soft linen is laid over the lids so as to soak up any discharge, small oval pledgets of charpie* or carded cotton-wool are then placed over this, more especially in the hollow at the inside of the eyeball and beneath the upper edge of the orbit, so as to fill these out, and bring the padding nearly to the same level as in the centre. The pressure of this cushion should be quite uniform, and not greater upon one portion of the eye than another, more especially upon the centre of the eyeball, otherwise it will produce pain and discomfort. The succession of the pledgets of charpie should be applied in such a manner that the upper lid is gently stretched across the eyeball in a lateral direction, and the lids thus kept immoveable. The two principal points of pressure should be at the inner and outer canthus, so that the eyeball is only pressed by the upper lid being stretched gently across it.

Von Graefe† makes use of three different forms of compressive bandages—1, the temporary; 2, the regular compress; 3, the pressure compress.

1. *The temporary bandage* simply consists of a knitted cotton band about 15 inches in length and $1\frac{3}{4}$ inch in width, which is to be placed over the eye and fastened by a couple of tapes. For this purpose I think Liebreich's bandage is to be greatly preferred, but with the next two forms of bandage it is different, for here we can regulate the degree and mode of pressure desired with a nicety and accuracy not to be obtained with Liebreich's.

2. *The Regular Compress.*—This bandage is about $1\frac{3}{4}$ yard long and $1\frac{1}{2}$ inch wide. Its outer two-thirds consist of fine and very elastic flannel, its central third of knitted cotton. The eye having been padded with charpie or cotton wool, as above directed, the bandage is to be thus adjusted:—One end is to be applied to the forehead just above the affected eye, and is then to be passed to the opposite side of the forehead and above the ear to the back of the head; the

* Charpie consists of threads of very fine linen; the linen should be cut into small squares of about 3 or 4 inches in diameter, and the individual threads are then to be pulled out, thus forming the charpie, which should then be folded into small pledgets. This is much cooler and more comfortable than cotton wool.

† A. f. O. ix, 2; vide also an abridgement of this paper, by the author, in R. L. O. H. Rep. iv, 2.

knitted portion is then carried on below the ear and brought upwards over the compress, the bandage being then again passed across the forehead and its end firmly pinned. The opposite eye may be closed with a strip of plaster, or, should it also require a compress, a separate bandage is to be applied.

3. The *pressure bandage* is made of fine and very elastic flannel, and should be about $3\frac{1}{2}$ yards long and $1\frac{1}{4}$ inch wide. It is intended to produce complete immobility of the eye, and to exert a considerable degree of graduated pressure. The one end of the bandage is to be placed upon the cheek, at a point about midway between the angle of the jaw and the ear of the affected side, and the bandage brought up over the compress (but not applied too tightly) and carried across the forehead to the back of the head; and then, passing beneath the ear, a second turn is to ascend (somewhat more vertically) over the compress, pressing firmly upon the latter. The bandage is then again carried across the forehead to the back of the head, and finally brought once more over the compress, but this time it is not to be pulled tight.

Baron Heurteloup's Artificial Leech.—This instrument is of the greatest service in the abstraction of blood in deep-seated intra-ocular diseases, as, for instance, in inflammations of the choroid, retina, and optic nerve. For in order to relieve the intra-ocular circulation, it is necessary that the depletion should be rapid, and we find that in the inflammations of the deeper tunics of the eye, depletion by leeches is almost useless, whereas the effect of the artificial leech is very considerable. The instrument consists of a small sharp cylindrical drill, and of a glass exhausting tube, with an air-tight piston. The drill can be set so as to make the incision of the desired depth, and is worked by a string, on pulling which a rapid revolution of the drill is caused, and the skin consequently deeply incised. The instrument is to be applied to the temple, and the hair should be previously shaved off at this spot, otherwise it will get between the skin and the edge of the exhausting tube, and thus cause the admission of air. The incision should be made tolerably deep (the depth varying of course with the thickness of the skin), in order that the blood may flow freely and rapidly. The air-tight piston is then to be applied over the incision, and a few rapid turns given, so that the skin may be somewhat sucked up into the tube. The blood will now flow very rapidly, and the screw in the piston must be moved in accordance with the flow of blood, so that no vacuum exists between the plug and the column of blood, nor should the screw be moved roughly and too quickly, otherwise it may produce great pain. The glass cylinder (which holds about 1 oz. of blood) should be filled in from three to

four minutes. The plug of the cylinder should be soaked in hot water previous to the operation, so that it may swell up and fit very tightly into the tube, and the edge of the latter, which is applied to the skin, should be greased or soaped, in order that it may fit closely to the skin, and prevent the entrance of air. With a little practice the operation may be gently, yet effectually performed without giving much pain to the patient. Hot fomentations should be applied afterwards, so that there may be free after bleeding. As the abstraction of blood near the eye always causes considerable increase in the flow of blood to the part and its vicinity, the patient should be kept in a darkened room for the first twenty-four hours, until the period of reaction is passed. At first the sight will be a little dim and indistinct, but after thirty to thirty-six hours have elapsed, the beneficial effects of the depletion will generally be marked.

The Eye-douche.—The best and cheapest form of this instrument consists of a piece of india-rubber tubing about 4½ feet in length, carrying a rose at one end, and at the other a curved piece of metallic pipe, which is to be suspended in a jug of water placed on a high shelf. The fine jet of water thrown up through the rose will be about 12 to 15 inches in height, and the force with which it plays upon the eye may be regulated by approximating or removing the latter from the rose. This form of eye-douche is to be preferred to that which is applied by means of a cup to the eye itself, as the jet is in this case far too strong, and often increases instead of alleviating the irritation. It is to be employed night and morning, or oftener if the eyes feel hot and tired, for two or three minutes at a time. The eyelids are to be closed, and the stream of water is to play gently upon them.

Mathieu's (Paris) water pulverizer, or the instrument used for Dr. Richardson's ether spray, will also be found very useful and agreeable.

Chapter I.

DISEASES OF THE CONJUNCTIVA.

1.—HYPERÆMIA OF THE CONJUNCTIVA.

We not unfrequently meet with a hyperæmic condition of the conjunctiva, and it is of practical importance to distinguish this from a mild form of conjunctivitis. In the former condition we find, on everting the eyelids, that their lining membrane is abnormally red, and perhaps a little swollen, and traversed by well-marked meshes of blood-vessels, which render the Meibomian glands somewhat indistinct. This increased redness may extend to the retro-tarsal fold, caruncle, semilunar fold, and even to the ocular conjunctiva, so that the white of the eye appears flushed and injected. The papillæ of the conjunctiva may also be slightly swollen and turgid, which gives a somewhat rough and velvety appearance to the inside of the lids. The patient is generally troubled by a feeling of smarting and itching in the eye, and a heaviness and weight in the eyelids, so that he experiences some difficulty in keeping them open. These sensations become worse in the evening, more especially in bright artificial light. Sometimes there is a slight tendency to lachrymation when the eyes are exposed to wind or a smoky atmosphere, but there is no trace of any mucous discharge.

This hyperæmic condition may be produced by long-continued work at small objects, such as reading, engraving, microscopizing, more especially by strong artificial light. It is also not unfrequently a reflex symptom of hyperæmia of the choroid and retina. Thus in very short-sighted persons affected with sclerotico-choroiditis posterior, we often notice that the conjunctiva becomes flushed if they persist long in reading, sewing, etc. Again, we frequently meet with the same thing in persons suffering from hypermetropia, who either do not use spectacles at all, or of an insufficient power, so that their accommodation is strained and fatigued.

It may also be caused by an irritating condition of the atmosphere, *e.g.*, cold wind, dust, etc. Or it may be due to mechanical irritants, such as a foreign body lodged under the eyelids or in the cornea, inversion of the lashes, or an obstruction of the lachrymal passages.

The treatment of hyperæmia of the conjunctiva is very simple, and

should be chiefly directed to the removal of the cause. If it be brought on by overwork, cessation from this must be enforced, and if the patient suffers from hypermetropia, this must be treated by the proper use of spectacles. The eye-douche or the pulverizer must be frequently used, and the eyelids should be bathed with an evaporating lotion, which greatly relieves the feeling of heaviness in the lids. The following lotions will be found very useful for this purpose :—

1. ℞ Sp. Æther. Nit. ʒj, Acet. Aromat. gtts. vj, Aq. Distill ʒvj. To be sponged over the closed eyelids and around the eyes 3—4 times daily, and allowed to evaporate.

2. ℞ Ætheris ʒij—ʒiv. Spir. Rosismar, ʒiv. To be used in the same way as the above, but in smaller quantity, especially if the skin be very delicate and susceptible. The best astringent lotions are those composed of 2—4 grains of sulphate of zinc or acetate of lead, in 4—6 ozs. of water. A piece of folded lint saturated with this lotion, is to be laid over the eyelids for 15 or 20 minutes several times a day, and a few drops may be allowed to enter the eye.

But if the hyperæmia has become chronic, these applications will not suffice, and it will then be necessary to apply a drop or two of a weak collyrium (gr. j.—ij. to ʒj. of water) of sulphate of zinc or copper, or even of the nitrate of silver, to the conjunctiva; or the sulphate of copper or the lapis divinus* may be lightly applied in substance. The eye-douche or cold compresses should be used after these applications. I must here call attention to a very prevalent popular error, namely, that it strengthens the eyes to dip the face into cold water with the eyelids open. This habit is, however, to be condemned, as it often produces much irritation and hyperæmia of the conjunctiva.

2.—CATARRHAL OPHTHALMIA.

The term "simple conjunctivitis" should, I think, be altogether discarded. It is, in fact, only the mildest form of catarrhal ophthalmia, and hence there is no reason to make it a distinct disease.

On everting the eyelids in a case of catarrhal ophthalmia, we notice that the conjunctiva is red, vascular, and swollen, so that the Meibomian glands are nearly or entirely hidden. The hyperæmia commences at the tarsal portion of the conjunctiva, to which it may indeed remain confined in very mild cases. Generally, however, it soon extends to the retro-tarsal fold, caruncle, semilunar fold, and ocular conjunctiva, reaching perhaps quite up to the edge of the cornea. As the disease subsides the vascularity retraces its steps in the reverse direction. It is

* Lapis divinus is composed of equal parts of sulphate of copper, nitrate of potass and alum, which ingredients are to be moulded into sticks.

important to distinguish the vascularity of the ocular conjunctiva from that of the subconjunctival tissue.* The former is characterised by a superficial network of vessels of a brick-red or scarlet colour, which run up to the edge of the cornea, and are freely movable upon the sclerotic. The meshes of this network are coarse and large, more especially towards the region of the retro-tarsal fold. On and between them are often noticed coarse red patches of extravasated blood, particularly near the cornea. But these effusions are also seen on the palpebral conjunctiva and retro-tarsal fold. If the ocular conjunctiva is alone implicated, the white sclerotic can be seen shining through the vascular meshes. But it is different if the subconjunctival tissue is also injected, for we then notice fine, parallel vessels of a rosy tint, radiating towards the cornea, around which they form a pink zone. These vessels are not movable upon the sclerotic.

The eyelids are generally somewhat swollen and red, and their temperature is perhaps slightly increased; but none of these symptoms are so marked as in purulent ophthalmia. Occasionally the œdema of the eyelids is so considerable, that the upper lid hangs down in a massive fold, and overlaps the lower. The edges of the lids are usually somewhat red and swollen, and at a later stage they often become sore and excoriated from the discharge, and the altered secretion of the Meibomian glands. Indeed, this irritation may in time give rise to marginal blepharitis.

The degree of swelling of the lids does not, however, necessarily correspond to the intensity of the disease, or the redness of the conjunctiva. Thus, in feeble subjects we sometimes find that there is great œdema of the lids, leading us to suspect a severe form of the disease, and yet, on opening the eye, we are surprised to find but slight injection of the palpebral and ocular conjunctiva, and but little, if any, discharge. In such cases we should examine as to the existence of an hordeolum, or whether the patient has been stung on the lid by an insect.

In the severer cases of catarrhal ophthalmia, we find that the conjunctiva becomes very swollen, more especially in the region of the retro-tarsal fold, so that, on considerable eversion of the eyelids, it springs into view in the form of one or more thick red girdles encircling the eyeball. The caruncle and semilunar fold are also swollen, and

* We may distinguish three kinds of vascularity on the eyeball: 1. The conjunctival vessels, which are brick-red, large-meshed, and freely movable. They consist both of veins and arteries. 2. The subconjunctival vessels which are of a pink, rosy tint, their meshes being smaller, and the vessels radiating in a parallel direction towards the edge of the cornea, around which they form a rosy zone; these vessels are chiefly venous. 3. The sclerotic vessels, which do not appear in the form of distinct individual vessels, but as small ill-defined red patches, which lend a bluish-red blush to the surface of the sclerotic. For further information as to the blood-vessels of the eye, I must refer the reader to Leber's important researches, A. f. O. xi, 1, 1; and also to those of Donders, Klin. Monatsblät. 1864.

assume a dark red and fleshy appearance. At an early stage of the affection, the swelling of the conjunctiva is firm, and lends a peculiar lustrous and glistening appearance to the inner surface of the lids; but later it becomes more flaccid and soft, and falls more readily into folds. The papillæ of the conjunctiva generally become swollen and turgid, often to a considerable degree, so that they give a rough, velvety, and so-called "granular" appearance to the conjunctiva.* In severe cases, especially in old decrepid persons, and after the long-continued use of cold applications, the ocular conjunctiva may also become swollen (chemosis), which is due to a serous, or perhaps even plastic, infiltration of the conjunctiva and subconjunctival tissue. In the majority of cases, however, the chemosis is but very slight.

The discharge varies in quantity and quality, according to the stage and intensity of the affection. In the early stages, there is generally only an increased secretion of tears, but the discharge soon becomes more opaque and stringy, and of a yellowish red tinge, consisting chiefly of albumen and broken down epithelial cells. As the disease advances, and the inflammatory symptoms increase in severity, the discharge becomes more copious and of a muco-purulent character, the pus cells being suspended in the mucus. It then also assumes a light yellow colour, and a thicker and more creamy consistence. In very mild cases it is often so slight in quantity that it might easily escape detection. Perhaps it is only on very considerable eversion of the lids that a thin yellow string of matter is observed to be embedded and almost hidden in the folds of the conjunctiva, or collected in the form of a small yellow bead at the angle of the eye. The lashes are generally found to be somewhat glued together in the morning by the discharge, and the altered and increased secretion of the Meibomian glands.

There is generally very little pain in catarrhal ophthalmia. The patient only complains of a feeling of heat and itching in the lids which causes him to rub them frequently. These sensations increase towards night, and manifest themselves especially during reading or writing by artificial light, or in a crowded and smoky room. The eyelids feel stiff and heavy, so that it is difficult to open them, this is especially the case if the lids are rather tight and press upon the globe. One of the most characteristic symptoms is the sensation as if a foreign body, such as sand, grit, or finely-powdered glass were lodged under the lids. This is evidently due, as was pointed out by Mackenzie, to the friction of

* In using the term "granular" for this appearance of the conjunctiva, I must strongly insist upon the great necessity of not confounding this condition with that of true granular lids, which is but too often done, and which has led to very great confusion, not only in the diagnosis, but also in the treatment recommended for these affections. In the former case, the granular appearance is simply due to the infiltrated and turgid condition of the papillæ, whereas the true granulations are a new formation of a perfectly different character.

the swollen papillæ against the ocular conjunctiva. This sensation should, however, remind us of the fact that the symptoms of catarrhal ophthalmia, viz., conjunctival and subconjunctival injection, lachrymation, pain, &c., may be produced by a foreign body, and the inner surface of both lids, as well as the cornea, should therefore be carefully examined, in order that we may ascertain whether a foreign body be present or not.

There is generally only a slight degree of photophobia. If it is severe, and accompanied by much lachrymation, subconjunctival injection, and considerable pain in and around the eye, more particularly over the brow and down the side of the nose (ciliary neuralgia), it is a sign that there is much irritation of the ciliary nerves.

Vision is only in so far affected, that objects may appear somewhat hazy and indistinct, as if seen through ground glass, which is due to the presence of a little of the discharge upon the cornea. The patients also notice muscæ volitantes in the shape of strings of fine beads floating through the field of vision, these are produced by mucus and little flakes of epithelium being washed over the cornea by the movements of the eyelids. For the same reason, the flame of a candle often appears to be surrounded by a coloured ring which, however, also disappears when the lids are rubbed. I need hardly point out that this should not be confounded with the luminous ring round a flame, which is one of the premonitory symptoms of glaucoma.

Catarrhal ophthalmia may be caused by sudden changes in the atmosphere, by exposure to cold, draught, and wet, or to great heat and glare, as, for instance, from a blacksmith's forge, or a large cooking fire. Long confinement in hot, smoky, crowded, and ill-ventilated rooms may likewise produce it, as also excessive use of the eyes, especially by artificial light. Or it may show itself in conjunction with, and be a part symptom of the affections of the mucous membrane of the nose or respiratory organs. As a continuation of the common integument, the conjunctiva may, moreover, become affected in the acute exanthemata, as in small pox, scarlatina, and measles, also in erysipelas, herpes zoster, and eczema of the face. It may suffer consecutively in affections of the eyelids, as for instance in ectropion or distichiasis, or in those of the lachrymal apparatus. Indeed epiphora dependent upon some impediment to the free efflux of the tears, is a not unfrequent cause of obstinate and chronic inflammation of the conjunctiva, which readily disappears as soon as the lachrymal affection is cured. Undetected foreign bodies, or injuries from mechanical or chemical irritants may also give rise to conjunctivitis.

Finally, it may be produced by contagion, more especially if the disease is at all severe, if the swelling extends to the retro-tarsal fold of the upper lid and the discharge is of a muco-purulent character. It

almost always reproduces catarrhal ophthalmia and only in rare cases gives rise to the purulent or diphtheritic form.

The *prognosis* of catarrhal ophthalmia is favourable, for the affection is very amenable to treatment. The milder forms generally run their course in a few days, the more severe in two or three weeks. The cornea becomes but seldom implicated, and even if ulcers should form upon it, they are generally quite superficial and peripheral, so that at the worst they only give rise to a slight opacity. Only in very severe cases and under very injudicious treatment do the cornea and iris participate to any dangerous extent.

If the affection is neglected, it may become chronic and prove very obstinate and intractable, more especially in old persons. The conjunctiva becomes flaccid and rough, and this may give rise to superficial corneitis, or ectropion, particularly of the lower lid.

The *treatment* must vary according to the stage and the severity of the disease. If the eye is very irritable, and there is much photophobia, lachrymation and ciliary neuralgia, accompanied by conjunctival and marked subconjunctival injection, astringent lotions should be carefully avoided, as they would increase the irritability, or might even set up inflammation of the cornea or iris. In such cases, the lids should be well everted and a careful examination made as to the presence of a foreign body beneath them, or upon the cornea. If none is detected, the condition of the palpebral and ocular conjunctiva, and of the cornea and iris should next be ascertained, as these symptoms of irritation may be due to phlyctenular ophthalmia, or to a commencing inflammation of the cornea or iris. In this condition of the eye, it is often impossible to decide whether it is simply a case of commencing catarrhal ophthalmia accompanied by unusually severe symptoms of ciliary irritation, or whether it is a case of incipient corneitis or iritis. It is, therefore, always the wisest plan to leave the question of diagnosis open, until the real character of the affection becomes more pronounced, and to endeavour to alleviate the symptoms of irritation by soothing applications. By so doing, we guard ourselves against committing, perhaps, a serious error in treatment. For if it should turn out to be a case of catarrhal ophthalmia, astringents may be employed as soon as the symptoms of irritation have somewhat subsided, and the discharge has assumed a muco-purulent character; if, on the other hand, it should prove to be a case of corneitis or iritis, the treatment has been most appropriate and judicious, whereas the use of astringents, more especially the more powerful ones, would have been very injurious.

The patient should be warned to guard his eyes against exposure to wet or cold; and to abstain from all reading, &c., more especially by artificial light.

In order to relieve the ciliary neuralgia, hot poppy fomentations

should be applied to the eye; but if the patient should be of a rheumatic habit, the moisture may produce considerable œdema of the lids, and, hot dry flannels are therefore to be preferred.

A solution of atropine (gr. ij to ʒj of water) should be dropped into the eyes two or three times a-day, and the following compound belladonna ointment should be rubbed over the forehead:—

℞ Extract Belladonnæ gr. x.—Hydrarg. Ammon. Chlorid. gr. v.—Adip. ʒj. M. A portion of this is to be rubbed over the forehead three or four times daily, and should be covered by a piece of thin tissue paper, so as to prevent its drying and becoming hard. It should not be washed off until it is time for its re-application. In the course of two or three days a slight papular eruption will appear, when the ointment is to be discontinued.

When the acute symptoms of irritation have subsided, and those of catarrhal ophthalmia—more especially a muco-purulent discharge—begin to show themselves, astringents must be applied. In the milder cases, in which there is not much conjunctival redness, and the discharge is chiefly of a mucous character, lodging in the form of thin, yellowish stringy flakes in the retro-tarsal fold, or the angles of the eye, a solution of sulphate of zinc or copper (1 or 2 grains to the ounce of distilled water) should be dropped into the eye two or three times daily. If the blood vessels are much dilated, and the conjunctiva relaxed and flaccid, a solution of tannin (gr. iv—viij to ʒj of water) is to be preferred. I have also found much benefit from the chloride of zinc (gr. ss—j to ʒj) which is strongly recommended by Mr. Critchett.

But if the inflammation is severe, if the discharge is copious, thick, and creamy, these remedies will no longer suffice, and we must have recourse to the nitrate of silver, the strength of the solution varying according to the amount and thickness of the discharge. For general purposes a solution of 2 or 3 grains to the ounce will be found the best. A large drop of this should be applied with a camel's hair brush or a quill to the inside of the lower eyelid three or four times a-day. The lids should then be rubbed with the finger, so that the solution may come in contact with the whole of the conjunctiva. The feeling of grit and sand in the eye as well as the lachrymation are much relieved, and will disappear for five or six hours. On their reappearance, the collyrium should be again applied. It may, however, be necessary to apply a still stronger solution (gr. iv—vj to ʒj) if the discharge is very copious and thick, and if the affection has lasted for some time. Before the collyrium is applied, the discharge must be removed by the injection of lukewarm water beneath the lids. This renders the action of the collyrium far more efficacious. After each instillation of the astringent collyria, cold water compresses should be applied to the lids for the space of from a quarter to half an hour, being changed as soon as they

become at all warm. This will give great relief to the patient, and subdue the pain and irritation produced by the lotion.

Lukewarm water should be injected between the lids every two or three hours so as to wash away the discharge. Or the following lotion recommended by Mackenzie may be employed with advantage for this purpose. ℞ Hydrarg. Bichlorid. gr. j.—Ammoniæ Muriat. gr. vj.—Aq. distill. ʒvj.—Misce. A table-spoonful of this lotion is to be mixed with a table-spoonful of hot water. In mild cases the eyes should be fomented with it three or four times daily, a little being permitted to enter the eye. In severer cases it should be injected over the whole conjunctiva.

A little simple cerate or unscented cold cream is to be applied to the edges of the lids to prevent their sticking. If crusts have formed upon the lashes, they are to be soaked with warm water, and then carefully removed so as not to produce any excoriation. If the edges or angles of the lids are sore and excoriated, the red precipitate ointment (gr. j—ij to the drachm of lard) is to be applied night and morning, or the weak nitrate of mercury ointment may be used.

The attendants must be warned that the discharge in catarrhal ophthalmia is contagious, and that the sponges, towels, &c., used for the patient must be carefully kept apart, and not employed for any other purpose. Some authors have expressed a doubt as to the contagiousness of catarrhal ophthalmia, but in out-patient practice we have very frequent opportunities of seeing several members of the same family affected consecutively with the disease. Constitutional treatment will hardly be required; the bowels should be kept freely open and if the patient is feeble and out of health, tonics should be administered.

3.—PURULENT OPHTHALMIA.

(Syn. Egyptian ophthalmia, contagious ophthalmia, military ophthalmia.)

We cannot draw a sharp line of demarcation between acute catarrhal, and purulent ophthalmia. The latter may indeed be regarded as a more severe form of catarrhal ophthalmia, in which all the symptoms of this affection are intensified in degree. The lids are more œdematous, hot, and red, the palpebral and ocular conjunctiva more injected and swollen, and the papillæ more turgid and prominent. The chemosis is also more considerable, and the discharge is thicker, more copious, and more contagious. The inflammation is, moreover, not confined to the conjunctiva, but extends deeper, and involves also the sub-conjunctival tissue. So that there is not only a secretion of muco-purulent discharge upon the free surface of the conjunctiva, but also an infiltration of sero-plastic lymph into the

substance of this membrane. The cornea is, moreover, far more frequently and more seriously implicated than in catarrhal ophthalmia.

At the commencement, the patient experiences a sensation of heat and itching in the eye, as if a foreign body, more especially sand or grit, were lodged beneath the eyelids. The edges of the latter become slightly glued together, and small beads of matter collect and harden on the lashes and at the corners of the eye. On eversion of the lids, their lining membrane is found to be very vascular, swollen, and of a uniform redness, so that the Meibomian glands can no longer be distinguished. The retro-tarsal fold, the caruncle, semilunar fold, and ocular conjunctiva are also abnormally red and swollen. The eyelids are red, glistening, and perhaps somewhat puffy. At first, there is only considerable lachrymation, but the discharge soon assumes a muco-purulent character, having yellow flakes of pus and broken-down epithelial cells suspended in it.

Up to this point, all these symptoms are only those of catarrhal ophthalmia. But as the disease advances, they soon become more severe in character. The patient often experiences great pain in and around the eye, which may even extend to the corresponding half of the head, especially if the inflammation be of a sthenic character, in which case marked febrile symptoms may also present themselves. Generally, the pain diminishes as soon as the discharge becomes purulent. It may, however, again increase in severity if the cornea becomes affected, and especially if the iris or other tissues of the globe should become involved in the inflammation. In general inflammation of the eye-ball (panophthalmitis) the pain is often excruciating.

The lachrymation and photophobia increase, the lids become very swollen, so that the upper hangs down in a thick heavy fold, and they can only be opened or everted with difficulty. They are red, glistening, and œdematous, and, if deeply pressed, somewhat tender. Their temperature, though markedly increased, never reaches a very high degree, and this, together with the absence of tenderness, is of importance in the differential diagnosis between purulent and diphtheritic ophthalmia. The conjunctiva becomes vascular and swollen, and patches of effused blood are noticed both on its palpebral and ocular portion. The papillæ are very turgid and prominent, giving a rough and villous appearance to the inside of the lids. As they increase in size they become flattened at the sides, from being pressed against each other, and they appear arranged in rows without a distinct base. The prominence may be so considerable that they assume the appearance of cauliflower excrescences. They often bleed freely on the slightest touch, as their epithelial covering is very thin and easily shed. The retro-tarsal fold is much swollen, and, on eversion of the lids, springs into view in the form of thick, red, fleshy girdles which encircle

the eye-ball. The ocular conjunctiva becomes very vascular, and a serous or even plastic effusion takes place into it and the sub-conjunctival tissue. This chemosis is far more marked than in catarrhal ophthalmia, and may be so considerable as to rise like a high, red, semi-transparent mound round the cornea, overlapping its edges more or less considerably, and even perhaps protruding between the lids. The chemosis is most prominent at the outer and inner side of the cornea, at the triangular spaces opposite the palpebral aperture; for the pressure of the lids keeps down the chemotic swelling above and below. On account of the great swelling and weight of the eyelids, and the great chemosis, the vessels supplying the cornea become much compressed and its nutrition proportionately impaired; and this explains the great tendency to ulceration and suppuration of the cornea in severe purulent ophthalmia. For the idea that the irritating and noxious character of the discharge produces the affection of the cornea is erroneous.

As the disease advances, the discharge increases in quantity, becomes more opaque, thick, and creamy, and, on account of its admixture with blood, frequently assumes a reddish yellow tint. It is often so considerable in quantity that it wells out from between the eyelids when these are opened and flows down over the cheek; the lashes become clogged with it, and glued together into little bundles. It collects in the retro-tarsal fold and on the surface of the cornea in the hollow formed by the chemosis, and this appearance may easily be mistaken by a superficial observer for suppuration of the cornea. The discharge should, therefore, always be wiped away from the cornea before any opinion is formed as to the condition of the latter. On cleansing away the matter from the surface of the palpebral conjunctiva, we notice that the latter looks red, glistening, villous, and succulent, which enables us at a glance to distinguish the disease from diphtheritic conjunctivitis. Sometimes, however, the discharge is more tenacious and clings to the surface of the conjunctiva like a thin membrane, so that it cannot be easily wiped away, but requires to be stripped off, when it comes off in the form of thin flakes. But on its removal, we find that the membrane was quite superficial, and that the appearance of the conjunctiva beneath is the same as that described above. Hence it is erroneous to call this diphtheritic conjunctivitis, simply because the discharge is more tenacious and comes off in flakes, for the symptoms of true diphtheritic ophthalmia are not only very different, but demand a very different course of treatment. There can be no objection, however, to terming it "membranous ophthalmia." We sometimes, however, meet with mixed forms of purulent and diphtheritic ophthalmia.

The chief danger in purulent ophthalmia is the implication of the

cornea. Any cloudiness of the latter must, therefore, be always regarded as an untoward symptom, more especially if it already shows itself at an early stage of the disease, and if there is any tendency to a diphtheritic character in the ophthalmia. At a later period it is less to be feared. The appearance of the cornea must be carefully watched from day to day, and in severe cases its condition should be examined, if possible, at the interval of a few hours. Implication of the cornea is especially likely to occur if the inflammation is very severe, the temperature of the lids much increased, the chemosis considerable and firm, and accompanied by great photophobia, lachrymation, and ciliary neuralgia. The pain is generally intermittent, and often very severe especially towards night; it may extend deep into the orbit and over the corresponding side of the head and face. On examining the condition of the cornea we may then perhaps discover small phlyctenulæ at its edge or upon its surface, which soon pass over into ulcers. Sometimes there is a serous infiltration (œdema) into the cornea which may remain confined to the periphery, giving it a slightly steamy or clouded appearance. If this opacity is considerable, and extends over the centre of the cornea, the sight may be greatly impaired, or a circumscribed light grey infiltration may appear at one portion of the cornea and disappear again as the ophthalmia subsides, or it may become more dense and assume a yellow tinge. Generally, the infiltration soon changes into an ulcer, which may in favourable cases remain superficial and ultimately leave only a very slight, or even no opacity of the cornea. But if the infiltration or ulcer is of considerable size and rather deep, a dense opacity may remain behind, and greatly impair the sight if it be situated in the centre of the cornea. The ulcer, instead of remaining superficial, may, however, rapidly increase in circumference and depth, and soon lead to extensive perforation of the cornea, accompanied by prolapse of the iris, escape of the lens and perhaps of a portion of the vitreous humour, and be followed probably by the formation of a considerable staphyloma.

When the cornea gives way, the patient experiences a sudden remission of the violent pain, accompanied by a gush of fluid over the cheek. If the ulcer is large, the cornea, on account of being thinned and softened at this point, may become somewhat bulged forward before perforation occurs. The dangerous character of the ulcer of course increases with its extent, as the perforation will be proportionate in size.

Sometimes several infiltrations are formed near to each other and then coalesce, thus giving rise to one large ulcer. In many cases the perforation, if it be but of limited extent, is the best thing that can occur, for the ulcer instead of increasing in circumference, then begins at once to heal.

Perforation of the cornea may give rise to the following complications. 1. Prolapse of the iris. 2. Anterior synechia. 3. Central capsular cataract. 4. Displacement or obliteration of the pupil. 5. Anterior staphyloma. For further information upon this subject, I must refer the reader to the chapter upon ulcers of the cornea.

If the perforation of the cornea is small, a little portion of the iris will fall against it; when the aqueous humour escapes, lymph will be effused at the bottom of the ulcer, and the iris will become adherent at this point to the cornea, giving rise to an anterior synechia. The pupil will be dragged towards the adhesion and more or less displaced; or it may be partially or wholly implicated in it. If the perforation was extremely small (such as would be produced by a fine needle) the re-accumulation of the aqueous humour may tear through any little adhesion that has taken place between the iris and cornea, and no anterior synechia will be left. When the perforation occurs at the centre of the cornea, the lens will come in contact with the bottom of the ulcer, and a central anterior capsular cataract may be formed. If the cornea gives way to a greater extent, a knuckle of iris may be pushed into the ulcer and cause a prolapse of the iris, which may increase to a very considerable size from the aqueous humour collecting within it and swelling it out. A small protrusion of this kind has been termed a *myocephalon*. Or the lens may escape together with a portion of the vitreous humour, if the rupture of the cornea is large, and then the eyeball may become atrophied. Or the iris falls into the gap, becomes adherent to the cornea and covered with lymph, which assumes a cicatricial character, and yielding gradually to the intra-ocular pressure, becomes more and more prominent, and a partial or total staphyloma results.

A very dangerous kind of ulcer is that which makes its appearance in the form of a small crescentic ulcer near the edge of the cornea (generally the lower), looking as if it had been scratched by a finger nail. Its edges soon become infiltrated and assume a yellow tint. It increases in depth, and rapidly extends further and further round the cornea until it may give rise to a very considerable perforation or slough of the cornea. On account of its being situated so closely to the edge of the cornea, this form of ulcer is often hidden by the chemosis and thus easily overlooked at the outset.

In very severe cases of purulent ophthalmia with intense inflammatory symptoms, sloughing of a great portion or even of the whole of the cornea may take place within a few hours. The cornea loses its transparency, becomes of a greyish white colour which soon passes into a yellow tint, and looks shrivelled and quite opaque. It soon yields to the intra-ocular pressure, gives way, and the eyeball becomes atrophied.

Iritis may supervene when the ulceration has extended to the deeper

layers of the cornea, or when perforation has occurred. If severe, it generally gives rise to great ciliary neuralgia, photophobia, and lachrymation. If a portion of the cornea remains sufficiently clear to permit of our seeing the iris, we find the latter discoloured, and the pupil contracted, irregular, and perhaps blocked up with lymph, or there may be pus in the anterior chamber. The inflammation may extend from the iris to the other tissues of the eye, and general inflammation of the eyeball (panophthalmitis) set in, accompanied by excruciating pain. Pannus occurs but seldom in acute purulent ophthalmia, and only in cases where the papillæ have been much swollen from the very commencement of the disease, and from their rubbing against the cornea have induced a superficial vascular corneitis. It is more frequently met with in chronic ophthalmia. It is an interesting fact, that if the cornea has been suffering from pannus before the attack of purulent ophthalmia, there is far less danger of its ulcerating or suppurating than if it is quite transparent. This important fact has been utilized in the treatment by inoculation of pannus dependent upon granular lids.

Purulent ophthalmia generally runs its course in three or four weeks. It may, however, become chronic and last for many months or even years, and prove very obstinate. This is especially the case if the papillæ remain swollen and prominent, for by their constant friction against the cornea, pannus is but too often produced. The relaxed condition of the conjunctiva may also give rise to ectropion, or this may be produced by the lids having become everted during the progress of the disease, and not having been properly replaced.

Causes.—Purulent ophthalmia may become developed from an acute catarrhal ophthalmia, by the symptoms of the latter increasing in severity, either through a continuation of the original cause, through neglect, or through a mistaken course of treatment. The same causes which may give rise to catarrhal ophthalmia, viz., exposure to cold or draught, great glare, &c., may also produce the purulent form. We find sometimes that it occurs epidemically, and that mild irritants, which would at other times only have caused a simple catarrhal conjunctivitis, now produce purulent ophthalmia. An unhealthy locality, a vitiated atmosphere, crowded and badly ventilated rooms, exposure to great heat or cold, dust, and glare, intensify the character of the epidemic. Some of these causes are frequently met with in places where many persons are collected together, as in workhouses, foundling hospitals, and large barracks. If purulent or even catarrhal ophthalmia once breaks out in such establishments, it is often very difficult to arrest it before it has spread widely amongst the inmates and committed great ravages. If soldiers on their march or in camp are exposed to great heat and glare, and to hot winds carrying before them clouds of sand or dust, as occurs in India or Egypt, ophthalmia will soon show itself amongst

them. Hence the terms military and Egyptian ophthalmia. These names should, however, be abandoned, for this affection shows no special characteristics warranting its being classed as a disease *sui generis*. The epidemic is in such cases generally one of purulent ophthalmia, but sometimes it may assume the character of severe catarrhal or granular ophthalmia. Or these affections may pass one into the other, or exist side by side in the same army. This being so, we can easily understand how such various, and often conflicting and confused accounts have been given of the character, the severity, and the contagiousness of the so-called military ophthalmia.

Contagion is the most frequent cause, as the contagious power of the discharge is often very great. This varies, however, according to the severity and stage of the disease. Piringer,* who made a great number of valuable and interesting experiments to test the contagious power of the discharge, found that during the earliest stage, and also in chronic cases, in which the discharge is thin, watery, and transparent, it is hardly, if at all, contagious. But it becomes slightly so when, though still watery, it assumes a somewhat muco-purulent character, and then it generally reproduces a mild form of the disease. The contagiousness increases in proportion to the intensity of the disease, and the purulent nature of the discharge. According to the same authority, the discharge of a severe purulent ophthalmia, if applied to a healthy conjunctiva, may reproduce the disease in from 6—12 hours; that from a moderately severe form in from 12—36; the mild, in 60—70; and that from chronic ophthalmia in 72—96 hours. It is of the greatest practical importance to remember that the discharge from purulent ophthalmia does not always reproduce the purulent form, but may give rise to catarrhal, granular, or even diphtheritic conjunctivitis. Just as the discharge from catarrhal, diphtheritic, and acute granular ophthalmia may produce purulent ophthalmia. The special form of conjunctivitis which may arise, will depend upon atmospherical, local, and constitutional causes, and also upon the age of the patient. Thus Von Graefe states † that in Berlin the matter from ophthalmia neonatorum, when applied to the eyes of children of two or three years of age, generally produces diphtheritic conjunctivitis, whereas when applied to adults it mostly gives rise to purulent or sometimes to granular ophthalmia.

Healthy eyes are more rapidly and severely affected by the inoculation of contagious matter than those suffering from vascular forms of corneitis, more especially pannus. Repeated inoculation diminishes the contagious power of the discharge. This is also diminished by diluting the latter with water, it being altogether lost when it is diluted with about one hundred parts of water. Gonorrhœal and vaginal discharges

* Piringer "Die Blennorhoë im Menschenauge," Gratz, 1841.

† Deutsche Klinik, 1864, p. 79.

may also produce purulent ophthalmia. It appears certain that the air is often a carrier of the contagion, especially if many persons suffering from severe purulent ophthalmia are crowded together in one room, and this is perhaps small and ill ventilated. Von Graefe thinks that in such cases the propagation is partly caused by the suspension of the constituents of the discharge in the atmosphere, and partly by the air expired from the lungs, from the discharge passing down the lachrymal passages into the nose. Just the same, in fact, as what occurs in common nasal catarrh, the contagious nature of which depends chiefly upon the expired air.

The *prognosis* which may be given in a case of purulent ophthalmia will depend upon the stage and severity of the disease, and also upon the prevailing character of the epidemic, should such exist. It may be favourable, if the affection is of a mild muco-purulent character and is due to spontaneous causes; or, having been produced by contagion, if the inoculating matter was mild and chiefly mucous in character. Also, if the redness and swelling of the eyelids and conjunctiva are but slight; if the inflammation is chiefly confined to the palpebral conjunctiva, or if it extends to the ocular, the chemosis is serous and soft, not plastic and hard; if the discharge is thin and scant, the cornea unaffected, the character of the epidemic mild, without any tendency to the diphtheritic form of conjunctivitis. We must, on the other hand, be extremely guarded in our prognosis, or even form an unfavourable one, if the inflammation is very intense, the chemosis hard and lardaceous, and so considerable as completely to surround the cornea and overlap it; if there is any ulceration of the cornea, especially if this be considerable in extent, and occurring early in the disease; if the inflammation shows a diphtheritic character.

Treatment. If the attack is severe, the patient should be confined to a darkened room, or even to his bed. The room must, however, be well ventilated, and plenty of fresh air be admitted, particularly if it is occupied by several patients. Those who have the disease in a severe form should, if possible, be separated from the milder cases. I need hardly point out that in barracks, unions, schools, &c., the healthy inmates should be strictly kept apart from those who are suffering from ophthalmia. Their eyes should, moreover, be examined every day, in order that the first symptoms of the disease may be detected. The patients and attendants should be made aware of the contagious character of the disease, which continues as long as the discharge remains opaque and mucous. Especial care must be taken that the sponges, towels, water, &c., which are employed for the patients are not used by others. To guard them against the risk of contagion, the medical attendants and nurses should wear the curved blue eye protectors, more especially whilst applying the collyria or syring-

ing out the eyes, as a little of the matter may otherwise be easily splashed into their eyes. If, by accident, any of the discharge should have got into a healthy eye, lukewarm water should be at once injected under the lids so as to wash it away, and then a drop of a weak solution (2 grains to the ounce of water) of nitrate of silver or sulphate of zinc should be applied to the conjunctiva. If only one eye is affected with purulent ophthalmia the other must be at once, without loss of time, hermetically closed. The common compress bandage will not suffice for this purpose, for the discharge might soak through, especially during the night, when it may run over the bridge of the nose from the affected to the healthy eye. The best protection is the following compress recommended by Von Graefe. A pad of charpie or cotton wool should be applied to the eyelids and covered by diacolon plaster, which is to be fixed down by collodion, so as to completely exclude the air. This compress should be removed twice daily, and the eye cleansed and carefully examined. If there is any redness or swelling of the conjunctiva, or any discharge the pad should be discontinued, although in some cases the continuance of the firm pressure appears to cut short the attack. A drop of a weak solution of nitrate of silver or sulphate of zinc should be at once applied. Ice compresses may also be applied to the eyelids, as they, according to Piringer, will often cut short the attack.

There is generally not much constitutional disturbance, except the disease is severe, in which case, more especially in gonorrhœal ophthalmia, it is often accompanied by marked febrile symptoms. If the tongue is foul and loaded, a brisk purgative should be administered, and the bowels be kept well opened. If the patient is plethoric and feverish, cooling salines must be prescribed, and the diet be kept low. Formerly the depletory plan of treatment was carried to great excess, and venesection employed to such an extent that we read of cases in which the patient was bled "as long as the blood could be got from the arm" (Wardrop). Now, however, this course of treatment has fortunately almost completely exploded, and venesection is hardly ever employed. Indeed we not unfrequently find that patients suffering from purulent ophthalmia are of a weakly and cachectic habit, in whom such a line of treatment would be most injudicious and injurious. In all such cases tonics, especially quinine and steel with perhaps some ammonia, should be freely administered, the patients being at the same time put upon a good, nourishing and easily digestible diet, with meat once or twice a-day, and, if necessary, they may even be allowed a moderate quantity of stimulants. In this we must, however, be guided by individual considerations. If the patient is restless and sleepless, a narcotic should be given at night, as it is a great relief if he can obtain a good night's rest.

The greatest attention must be paid to the local treatment. The eye should be frequently cleansed of the discharge. The eyelids being

opened, a small stream of lukewarm water or milk and water should be allowed to play gently upon them until all the discharge is washed away. Still better is it to employ for this purpose a small syringe, the nozzle of which is to be gently inserted between the eyelids. The syringe should be very carefully and delicately handled, otherwise it will bruise and irritate the eye, or even perhaps rub against the cornea. The nurse must also be very careful that no drop of the returning fluid is thrown into her eye. In severe cases, the eye should be thus cleansed every hour or two, in milder cases three or four times daily will suffice. The bichloride of mercury lotion may also be used for cleansing the eye, instead of warm water. The crusts which form upon the eyelashes should be well soaked with warm water and then gently removed, so as not to excoriate the lids. A little simple cerate should be applied to the edges of the latter, night and morning, to prevent their sticking, or if they are getting sore this should be exchanged for the citrine ointment. If the temperature of the lids is but moderately increased, it is only necessary to employ cold compresses for an hour or two after the application of caustics, for we thus assist the astringent action of the caustic upon the blood vessels, and also moderate the reaction produced by it. But if the attack is very severe, and the eyelids very red, swollen and hot, a temporary use of cold water will not suffice, and we must have recourse to a constant application of ice compresses. They should be applied in the following manner: slightly moistened pledgets of lint, of a sufficient size to cover both eyelids, should be laid upon a lump of ice until they are quite cold, when they are to be applied to the eyelids and changed as soon as they get the least warm. Several of such pledgets should be kept lying upon the ice, so that one is always ready for use. If the temperature of the lids is very high, the lint may require to be changed every three or four minutes. It is, therefore, absolutely necessary to have a nurse for each patient or at least for every two. If great attention cannot be paid to the application of the ice compresses, it is better to abstain altogether from their use, as they may otherwise do more harm than good. We must then rest satisfied with the use of cold water dressing or Goulard lotion. When the eyelids become cooler and less red, the patient begins to find the extreme cold disagreeable, and then cold water dressing should be substituted for the ice compress, or it may even be necessary to pass over to the use of warm fomentations. A constant small stream of cold water may also be allowed to play upon the eyelids by means of a small syphon connected with a little reservoir placed at the bed head.

Local depletion is often of great benefit. If there is much ciliary neuralgia, accompanied by great swelling, heat and redness of the eyelids, and if these symptoms do not readily yield to cold compresses,

leeches should be at once applied. The best place for their application is on the temple, about an inch from the outer canthus, for if they are put close to the eyelids, they often produce great œdema of the lids which may even extend to the cheek. Their number should vary from four to eight, according to the requirements of the case. They should be applied two at a time, so that the effect may be prolonged, and free after-bleeding is to be encouraged by warm fomentations.

If the eyelids are much swollen, very tense, and press greatly upon the eyeball, and especially if the cornea is beginning to become affected, the outer commissure of the lids should be divided. This will not only mitigate the injurious pressure of the lids upon the eyeball and cornea, but it will also give rise to free bleeding from the vessels which are divided, and thus greatly relieve the circulation of the external portions of the eye. The incision is to be carried through the skin and fibres of the orbicularis, but not through the mucous membrane, otherwise an ectropion might be produced.

We have now to consider the most important part of the treatment, namely, the topical application of caustics and astringents. At the commencement of the disease, whilst the discharge is still but moderate in quantity, we must be careful not to employ too strong a caustic, more especially if the eyelids are hard and the conjunctiva and papillæ not much swollen, for fear that there should be a tendency to diphtheritic conjunctivitis, which would be greatly aggravated by free cauterization. As soon as the discharge has become copious, and the symptoms of true purulent ophthalmia are well pronounced, astringents must be employed more energetically. The choice of the astringent and the mode of its application will depend upon circumstances. If we have to treat the person as an out-door hospital patient, and shall perhaps only see him every second or third day, it will be necessary to give him a remedy which can be readily and efficiently applied by some attendant. Under these circumstances I have found the injection of zinc and alum, as employed at the Royal London Ophthalmic Hospital, Moorfields, by far the best. Its strength, and the frequency of its application, must vary according to the severity of the disease. I generally employ a solution of 2 gr. of sulphate of zinc and 4 to 6 gr. of alum to the ounce of distilled water. This is to be injected between the eyelids with a small glass syringe every 15 or 30 minutes during the day, and every two hours at night. As the condition of the eye improves, it is to be employed less frequently. Every second or third day, the surgeon should apply a drop or two of a strong solution of nitrate of silver (gr. x to ℥j of water) to the inside of the lids, or it should be brushed over the conjunctiva with a camel's hair brush ; the patient in the interval continuing with the injection. Lukewarm water should be injected every half hour in order to cleanse away the discharge.

Much benefit may also be derived from a solution of nitrate of silver (gr. x to ℥j of water if the case is severe) which should be dropped into the eye every five or six hours, with a quill or camel's hair brush. But it is more difficult to apply these drops properly and efficiently than the injection, and it is therefore always better that the surgeon should, if possible, do this himself. My friend, Mr. Moss, has very successfully treated, at the Moorfields Hospital, out-patients suffering from very severe purulent or gonorrhœal ophthalmia, in the following manner, which was, I believe, suggested to him by Professor Donders. The lids being well everted, he applies with a camel's hair brush a very strong solution of nitrate of silver (gr. xxx—to xl to the ℥j) to the conjunctiva once a-day. In the intervals the patient uses an injection of alum every half hour or hour. Quinine or steel is at the same time given internally.

But if the patient is in the hospital, or can be frequently seen by the surgeon, I greatly prefer to apply the nitrate of silver in substance. It has this great advantage, that we can regulate and limit its effect, and prevent its coming in contact with the cornea and the ocular conjunctiva, which is quite impossible with the solution. Moreover, the latter is easily decomposed if the discharge is copious, and its effect is thus impaired. It is, however, absolutely necessary that the surgeon or a skilful assistant should apply it, as it cannot be entrusted to a nurse. We are indebted to Von Graefe* for the scientific explanation of the action of the nitrate of silver in purulent ophthalmia, and for very exact and comprehensive directions as to its use. During a prolonged stay in Berlin, I saw it employed most successfully in this way by Von Graefe in many cases of purulent ophthalmia.

Pure nitrate of silver is too strong to apply in substance to the conjunctiva, as its escharotic action is too severe. It produces a thick eschar which is thrown off with difficulty, hence the superficial portion of the conjunctiva is very liable to become destroyed, and deep cicatrices may be produced. Its strength should, therefore, be diluted by mixing it with one-half or two-thirds of nitrate of potash.

The application is to be made in the following manner. The eyelids having been thoroughly everted, so as to bring the retro-tarsal fold well into view, the folds of the conjunctiva of the upper and lower lid should be allowed to cover the cornea, and thus protect it from the action of the caustic. The crayon of mitigated nitrate of silver should then be lightly passed over every part of the surface of the palpebral conjunctiva, especially in the retro-tarsal region. A solution of salt and water should then be freely applied with a large camel's hair brush, in order to neutralize the nitrate of silver. The caseous shreds of chloride of silver which are thus formed, should be washed away with

* Von Graefe on Diphtheritic Conjunctivitis (A. f. O., vol. I.)

clean cold water, before the lids are replaced. We can very easily regulate the action of the caustic. When but a slight effect is required, the crayon should be passed but once or twice very lightly over the conjunctiva. If a stronger action is desired, it may be used with more freedom. The neutralization with the salt and water should not take place immediately after the application of the caustic, except where the effect of the latter is to be but very slight. It should not, however, be postponed longer than from ten to fifteen seconds.

The caustic should not, as a rule, be applied to the ocular conjunctiva, for as this is but secondarily affected, its swelling and inflammation will generally subside as the condition of the palpebral conjunctiva improves. It may, however, be necessary to do so, if the chemosis is so considerable as to protrude between the lids, and does not yield to free incisions. But it should only be touched here and there, and the salt and water should be immediately applied.

If the swelling of the conjunctiva is very considerable, it should be freely scarified with a scalpel or Desmarres' scarifier, directly after the neutralization of the caustic; and the bleeding should be encouraged by the application of hot sponges, and by slightly kneading the lids between the fingers. The incisions in the papillæ should be very superficial, otherwise deep cicatrices will be left. The lids should on no account be scarified before the application of the nitrate of silver, for the latter would act too severely upon the incised conjunctiva. If the chemosis is great, incisions radiating towards the cornea should be made in it, either with a pair of scissors or a scalpel: or a small fold of conjunctiva may be snipped out with scissors near the outer edge of the cornea. Ice compresses are to be applied directly after the cauterization, for they diminish the inflammatory reaction, and assist in the contraction of the blood vessels.

If we watch the condition of the eye, we shall find that it becomes very hot and painful directly after the cauterization, and that this is accompanied by increased lachrymation and a mucous discharge. The eschars which are formed upon the palpebral conjunctiva are shed in from 30—60 minutes in the form of little yellowish-white, rolled-up flakes. Those on the ocular conjunctiva remain somewhat longer. The inflammatory symptoms soon subside, the conjunctiva becomes less turgid, the lachrymation and purulent discharge diminish, and the stage of remission sets in, during which the epithelium is regenerated. When this has taken place, the original condition, as it existed before the application of the caustic, begins to reappear. The conjunctiva becomes more red and swollen, the discharge increases in quantity, and the inflammatory symptoms in severity. It is of consequence to endeavour, by renewed cauterization, to cut short this third period at the outset, before it has regained its original intensity. We shall thus be able, by degrees, to extend

the duration of the stage of remission, and to diminish the intensity of the inflammatory stage. Generally, it will suffice to apply the crayon once in 24 hours; in very severe cases it may be necessary to do so more frequently, but it should never be applied until the purulent discharge has again set in.

Von Graefe has shown that the effect of the nitrate of silver (although it momentarily increases the congestion), is to contract the blood vessels, and to accelerate the circulation, which is retarded in purulent ophthalmia, the conjunctiva being at the same time very vascular and congested, and its vessels dilated; moreover, the serous infiltration of the conjunctiva is greatly relieved by the copious serous effusion which follows the cauterization. This is the period of remission, during which the epithelial layer of the conjunctiva is regenerated.

If the cornea becomes cloudy, a solution of atropine (gr. ii to ℥j of distilled water) is to be dropped into the eye three or four times daily. Where the crayon is employed, the atropine should not be used until the period of remission has set in. If the nitrate of silver drops are used, the atropine should be applied during the intervals, and about two hours after the former.

If there is a deep ulcer of the cornea, which threatens to perforate the latter, we should at once perform paracentesis by pricking the bottom of the ulcer, and letting the aqueous humour flow off very gently. The opening in the cornea will thus be extremely small; a little portion of iris will fall against it, lymph will be effused, and the intra-ocular pressure being now taken off, the ulcer will begin to heal at the bottom. The re-accumulation of the aqueous humour will generally suffice to detach the portion of iris from the cornea. If, however, a small anterior synechia should persist, atropine drops should be applied, in order, if possible, to tear it through. It may be necessary to repeat the paracentesis several times, if we see that the bottom of the ulcer is being bulged forwards by the aqueous humour. By such a timely paracentesis we often limit the ulcer to a small extent, and finally little or no opacity of the cornea may remain. But, if we permit the ulcer to perforate of its own accord, the opening will be much larger, for the bottom of the ulcer becomes attenuated and extended in size before the cornea gives way. The aqueous humour will then escape with considerable force, and carry the iris, or even, perhaps, the lens if the perforation be large, into the opening in the cornea, and thus a considerable anterior synechia, or prolapse of the iris, may occur. If, in the latter case, the prolapse does not yield to the action of atropine, it should be pricked with a fine needle, and the aqueous humour distending it be allowed to flow off, which will cause the prolapse to collapse. This may be repeated several times, until the prolapse shrinks and dwindles away. If this does not occur, the prolapse should be snipped off with a pair of scissors,

after having been pricked. Should the lens have fallen into the opening and be presenting through, it should be at once removed, together, perhaps, with a little of the vitreous humour. An incision should be made through the central portion of the perforated cornea, with Von Graefe's narrow cataract knife. If a piece of iris protrudes, this should be somewhat drawn out and snipped off. The capsule should be freely lacerated with the pricker, and the lens will then readily escape if a little pressure is made upon the eye. A little vitreous humour will generally exude, and the lips of the incision fall into close apposition. A firm compress bandage should be carefully applied, so as to keep the eye immovable, and the vitreous pressed back. Should the latter show a tendency to protrude through the incision, and thus interfere with its firm cicatrization, it should be pricked, and a little be allowed to escape, the bandage being then re-applied. We may thus be able to save a sufficient portion of clear cornea to permit of the subsequent restoration of some useful degree of sight, by the formation of an artificial pupil.

If the disease has become chronic, the nitrate of silver must be less frequently applied, or it should be exchanged for, or alternated with, the use of sulphate of copper in substance. A crayon of this should be passed lightly over the palpebral conjunctiva, more particularly in the retro-tarsal region, once every day. Or, a solution of sulphate of copper (gr. ij ad ℥j) should be dropped into the eye once or twice daily. The astringent must be occasionally changed, as the conjunctiva after a time becomes accustomed to it, and it loses its effect. Thus, we may alternate the sulphate of copper with a collyrium of the sulphate, acetate, or chloride of zinc, alum, acetate of lead, or vinum opii, or the red or white precipitate ointment may be applied to the conjunctiva. If the papillæ are much swollen and very prominent, like cauliflower excrescences, it may be necessary to snip them off with a pair of scissors.

4.—GONORRHŒAL OPHTHALMIA.

Gonorrhœal ophthalmia is one of the most dangerous and virulent diseases of the eye. In the majority of cases it presents the symptoms of a very severe purulent ophthalmia, accompanied sometimes by marked constitutional disturbance.

Shortly after the infection, the patient experiences a feeling of tingling and smarting in the eye, as if a little grit or sand had become lodged beneath the lids. The eye becomes red, watery, and irritable, and the edges of the eyelids somewhat glued together by a slight greyish white discharge. These symptoms rapidly increase in severity, and the disease quickly assumes the character of purulent ophthalmia of

an aggravated form. The eyelids become greatly swollen, hot, red, and œdematous, the conjunctiva very vascular, swollen, and villous; the chemosis is often also very considerable, enveloping and overlapping the cornea, and protruding between the lids. The discharge is thick and creamy, and perhaps so profuse that it oozes out between the lids, and when they are opened streams over the cheek. There is always great danger of the cornea becoming affected with deep and extensive ulceration, which frequently quickly leads to perforation. The constitutional symptoms are often severe; the patients being generally in a feeble and weakly condition, their general health having perhaps suffered from the existence of the gonorrhœa.

Sometimes the disease shows from the outset a marked tendency to assume the character of diphtheritic conjunctivitis, and this proves especially dangerous to the eye. In such cases, we notice that the conjunctiva, instead of presenting the usual red, vascular, succulent appearance common to purulent ophthalmia, becomes pale, smooth, and infiltrated with a fibrinous exudation. The discharge is also quite different, being thin, grey, and watery. The cases of gonorrhœal ophthalmia which prove so virulent as to destroy the cornea in the course of a few hours are mostly of this diphtheritic, or, at all events, of a mixed character. In England, however, this form is very rare, and amongst the numerous cases of gonorrhœal ophthalmia which have come under my care or observation, I have only met with the purulent disease.

Gonorrhœal ophthalmia is always due to contagion, and the doctrine of metastasis (which was formerly much in vogue) is quite untenable. It may be produced during any stage of the urethral disease, but about the third week of the existence of the latter is the most dangerous period, the discharge being then very copious, thick, and noxious. I have, however, seen the discharge from a gleet give rise to severe and even destructive gonorrhœal ophthalmia. Medical men unfortunately sometimes altogether neglect to warn their patients of the danger of contagion from the urethral discharge. I have met with several instances of severe and destructive gonorrhœal ophthalmia, in which the patients had never been informed by their medical men of the very contagious character of the discharge.

Gonorrhœal ophthalmia is far more frequent amongst men than women, and the right eye is the one usually attacked, the corresponding hand being most used for the purpose of ablution, etc., and, consequently, most prone to be the carrier of the virus to the eye.

If we see the patient very shortly after the inoculation, the eye should be thoroughly syringed out with lukewarm water, and a drop or two of a weak solution of nitrate of silver (gr. ij. ad ℥j) be at once applied, and repeated at the intervals of a few hours. Ice compresses

may also be employed. The other eye should be *at once* protected by an hermetical bandage against the danger of contagion. The treatment must be the same as that for purulent ophthalmia, the patient's health being sustained by tonics and a generous diet. But if the disease shows a tendency to assume the diphtheritic character, the use of astringents (more especially the nitrate of silver) must be particularly avoided, and the case must be treated upon the same principles as diphtheritic conjunctivitis, viz., by ice compresses, leeches, and, perhaps, the use of mercurials.

5.—OPHTHALMIA NEONATORUM.

Strictly speaking, we cannot recognise this as a special form, for it assumes the character either of purulent or catarrhal ophthalmia. It demands, however, some special remarks as to the treatment to be pursued. The inflammation generally appears first in one eye, the other becoming affected a few days later if preventive measures are not at once taken. The symptoms of the disease vary from those of mild catarrhal conjunctivitis, to those of severe purulent ophthalmia. On account of the laxity of the tissues, there is great serous infiltration and swelling of the eyelids, even perhaps in the milder cases. The papillæ of the conjunctiva also become very prominent and swollen; and there is often a great tendency to ectropion.

It has been stated by some authorities that the cornea is more frequently implicated in infants than in adults, but this does not appear to be the case, although suppuration of the cornea is of but too frequent occurrence, from the feeble and weakly condition of many of the infants, and the negligence and want of care in the nursing, which is so often met with amongst the out-patients of an hospital.

Contagion is a very frequent cause of the disease. The infection often occurs from some leucorrhœal, or perhaps gonorrhœal discharge during the passage of the child through the vagina. But it must be always remembered that other vaginal discharges besides the gonorrhœal may induce this ophthalmia. The disease may also be produced by the child's eyes being wiped and cleansed with a sponge or cloth which is soiled with some vaginal discharge. Frequently the ophthalmia is not due to contagion at all, but is caused by the sudden exposure of the infant to the irritation of bright dazzling light, cold winds, or by a want of cleanliness in washing the eyes. This is proved by the fact that the disease sometimes does not make its appearance till some weeks after birth; whereas, if it were due to contagion this would not be the case, for we find in inoculation that the period of incubation lasts from 12 to 70 hours.

The course of ophthalmia neonatorum is generally much less intense than that of purulent ophthalmia (due to contagion) in adults.

Although the pure diphtheritic conjunctivitis never occurs in newborn infants, yet we sometimes meet with mixed forms, in which during the early stages, the purulent ophthalmia shows a more or less marked tendency to assume a somewhat diphtheritic appearance. The lids are not soft and flaccid (doughy), but stiff, and rather hard, and their temperature is high. The surface of the conjunctiva is of a pale or yellowish grey tint, the papillæ being not much swollen; the discharge, instead of being thick and creamy, is thin, fibrinous, and rather flaky, so that it adheres somewhat to the conjunctiva, and has to be removed with forceps, exposing beneath it a red succulent surface. These peculiar symptoms are simply due to a stasis in the blood-vessels, and the fibrinous mass does not penetrate into the substance of the conjunctiva, as is the case in the diphtheritic form.

The prognosis will depend upon the severity of the attack, the condition of the cornea, and if there be any epidemic, upon the nature of this in general.

Treatment.—The first indication is prevention. The eyes should be washed with warm water directly after birth, and this should be repeated frequently. The sponges, towels, lint, etc., should be perfectly clean, and used for no other purpose. The hands of the nurse and the mother (more especially if she is suffering from any vaginal discharge), should always be washed before the infant's eyes are cleansed. If the disease breaks out in a workhouse, or lying-in-charity, the children suffering from it should be separated from the healthy, and should have special nurses. Moreover, they should not be crowded together into small ill-ventilated wards, but enjoy plenty of fresh air.

If the eyes look red and irritable, with a discharge at the corners or upon the lashes, a weak collyrium of sulphate of zinc (gr. j—ji ad ℥j) should be used 2—3 times daily, and the eyes frequently cleansed. But if the discharge is thick, creamy, and considerable in quantity, stronger astringents must be employed. In out-patient practice, where the patients can only be seen two or three times a week, by far the best remedy is the injection of the collyrium of alum and zinc (Zinc. Sulph. gr. ij., Alum. gr. iv., Aq. dist. ℥j.). A little of this is to be injected with a glass syringe between the lids every quarter or half-hour during the day, and every three or four hours during the night. The frequency of the injection must be regulated according to the severity of the disease. The eyes are to be cleansed before the use of the collyrium by the injection of luke-warm water between the lids, so that the discharge may be washed away. If the patient can be seen every day, or even more frequently, the mitigated nitrate of silver, in substance, should be used, as we can regulate and localise its effect far

better than can be done if injections or collyria are employed. The edges of the lids should be smeared night and morning with a little simple cerate, or, if they are sore and excoriated, with a little citrine ointment. For severe cases, other local remedies are also indicated, *e.g.*, leeches, scarification, cold compresses, etc. But we unfortunately encounter great difficulty in their proper employment, except in a special hospital, or in private practice. The nurses or parents are often so careless in the application of cold compresses that they do more harm than good.

If there is a tendency to stasis in the circulation of the conjunctiva, and to the formation of the above-named fibrinous membranes, the astringents must be used with care, and their effect closely watched. If mitigated nitrate of silver in substance is employed, it should be only lightly used, at once neutralized by salt and water, and the cauterization be followed by free scarification and the application of cold compresses to the eyelids. Wecker, moreover, recommends the administration of small doses of calomel during this condition of cyanosis of the conjunctiva. Affections of the cornea must be treated in the same way as in purulent ophthalmia. The health of the mother or wet-nurse should also be attended to. If the infant is feeble, and the ophthalmia shows a tendency to become chronic, and the mother is out of health, tonics and a generous diet should be prescribed.

6.—DIPHTHERITIC CONJUNCTIVITIS.

This extremely dangerous disease is fortunately very rare in England. I have never yet met with a case of pure diphtheritic conjunctivitis here, whereas during my residence in Berlin, I had the opportunity of seeing many cases in Von Graefe's clinique. Indeed, it is of frequent occurrence in that city, and often assumes a very severe and even epidemic character.

The first symptom is very rapid and great swelling of the eyelids, which are also hard and firm, very hot, and exquisitely tender, so that the patient shrinks back and trembles at the mere idea of their being touched. The swelling and stiffness of the eyelids soon become so great, that they can hardly be opened, and certainly not everted; whereas in purulent ophthalmia we have seen that although the eyelids may be greatly swollen, they are soft, flaccid, and not painful to the touch, nor is the temperature very high; they can also be readily everted.

The conjunctiva is at first somewhat red, but soon assumes a greyish yellow tint, especially at the retro-tarsal fold. It is not soft, red, succulent, and villous, as in purulent ophthalmia, but thick, smooth, and

somewhat glistening. This pale, greyish-yellow tint is chiefly due to the firm, gelatino-fibrinous infiltration of the substance of the conjunctiva, which compresses the blood-vessels, and gives rise to a great retardation, or even stoppage in the circulation. Numerous extravasations of blood may also be noticed on the conjunctiva. The chemosis is pale and yellow, but the infiltration is not serous and transparent, but firm and fibrinous, pressing upon and strangulating the blood-vessels which supply the cornea, and hence the great danger which the latter runs in this disease. When the lids are opened, a stream of hot, scalding tears gush forth, mixed perhaps with a few yellow fibrinous flakes, quite different to the thick creamy discharge in purulent ophthalmia.

Even deep scarification of the conjunctiva fails to produce a copious sanguineous discharge, for the latter is either thin, scant, and of a reddish-yellow tint, or the incisions remain almost dry.

The discharge on the surface of the conjunctiva often assumes the form of thin yellowish, reticulated patches, of varying size. In some cases, thick opaque membranes are formed, which are so coherent that they can be stripped off in large pieces, forming casts of the lids and the surface of the eyeball. Their forcible removal may cause considerable bleeding, but we do not find, as is the case in purulent ophthalmia, that the denuded conjunctiva presents a red, succulent, villous surface, but we come down upon another layer of yellowish-grey fibrinous infiltration. In fact, the latter is not confined to the surface of the conjunctiva, but extends more or less deeply into its stroma.

The disease is not always accompanied by such severe inflammatory symptoms, but may run a milder and less dangerous course. It may occur as a primary affection, or ensue secondarily upon purulent ophthalmia, the latter assuming a diphtheritic character.

In the primary form, it generally sets in with considerable violence, all the characteristic symptoms showing themselves in two or three days; indeed, the disease may even attain its acme in that time, remain stationary for a few days, and then gradually pass over into the second or blenorrhoic stage. The latter is ushered in by the following symptoms:—The lids diminish in hardness and become more soft and flaccid, so that they can be everted with greater ease, and without much pain. The surface of the conjunctiva assumes a more vascular and succulent appearance; here and there patches of fibrinous exudation soften and become detached from the surface of the conjunctiva, which bleeds more or less freely. The deep-seated infiltration gradually diminishes, and this is accompanied by a corresponding diminution in the firmness and hardness of the conjunctiva, which assumes a more vascular, succulent, and villous appearance, the discharge at the same time becoming thick, creamy, and copious. In fact, the disease now presents the characters of purulent ophthalmia, with this peculiarity, however, that

there is a great tendency to the formation of cicatrices, and shrinking of the conjunctiva. But sometimes there is a relapse after the purulent stage has set in, the diphtheritic symptoms reappearing with more or less prominence, and such relapses may occur more than once. This is especially the case if the use of astringents has been commenced too early, or they have been too energetically employed.

Diphtheritic conjunctivitis is a far more dangerous disease than purulent ophthalmia, on account of the frequency and severity of corneal complications. Extensive ulceration or suppuration of the cornea is but too frequent. The dense, hard, infiltrated conjunctiva presses upon the cornea and upon the blood-vessels which supply it, hence the nutrition of the cornea is greatly impaired, and its suppuration may rapidly ensue. If the cornea is about to be implicated, we notice that its lustre is slightly diminished, its surface faintly clouded, and its epithelial layer somewhat abraded. A yellow infiltration appears, which rapidly passes over into an ulcer, the latter extends quickly in circumference and depth, until a very considerable portion of the cornea may be involved. In some cases, when the ulcer has extended nearly as far as the membrane of Descemet, the floor of the ulcer becomes somewhat more transparent and bulged forward by the aqueous humour. The patient's sight is temporarily much improved, and he is buoyed up by the vain hope that his eye is safe; but perforation generally rapidly ensues. If the disease is very severe, and the cornea has become affected at a very early stage, the whole cornea may suppurate, give way, and a considerable amount of the contents of the globe escape. The perforation is soon blocked up by a glutinous exudation, which also glues down the edges of the prolapsed portion of iris to the cornea. The earlier the cornea becomes affected, the greater is the danger, for the ulcers which occur at a later period of the disease spread less rapidly, and show a greater tendency to limitation. We also find, as in purulent ophthalmia, that those eyes are safest in which there exist either vascular ulcers of the cornea, or a vascular pannus, for then the nutrition of the cornea is carried on by the blood-vessels upon its surface, and there is far less danger of its undergoing suppuration.

The prognosis is very unfavourable if the disease is at all intense, and the character of the epidemic (if such exist) is severe, and if the patient is an adult. It is somewhat more favourable in children, and towards the end of the epidemic; also if the first stage of the disease is not very severe.

In framing our prognosis, we must be chiefly guided by the severity of the inflammatory symptoms, the amount of the fibrinous exudation, the swelling and hardness of the lids and of the chemosis, and especially by the condition of the cornea. If the latter becomes affected very shortly after (within 24—36 hours) of the outbreak of the disease, or

during the first period, before that of vascularization has set in, we must look upon the eye as all but lost. If the cornea is not implicated until the second period (that of purulent ophthalmia) has set in, the prognosis is more favourable, but even in this case we must remember that a relapse may occur, and the safety of the eye be again endangered.

The *causes* of diphtheritic conjunctivitis are very much the same as those which may produce other inflammations of the conjunctiva; but it must be conceded that there is generally some constitutional peculiarity which determines the character of the disease, the same causes—exposure to cold, draughts, inoculation, etc.—producing in one case a purulent or granular, in the other a diphtheritic ophthalmia, moreover it generally affects both eyes, however much we may guard the second. It occurs most frequently in weakly and scrofulous persons, more especially in children between the ages of two and eight, of a delicate, feeble habit, or affected with hereditary syphilis. In them it often occurs in conjunction with croup or diphtheria. Contagion is also a very frequent cause, for the discharge from diphtheritic conjunctivitis is exceedingly contagious. If it be applied to a healthy conjunctiva it generally reproduces diphtheritic conjunctivitis, but this does not necessarily follow. Sometimes it occurs epidemically, which is especially the case in some parts of Germany, more particularly in Berlin.

The injudicious and excessive use of caustics in the treatment of purulent ophthalmia (more particularly that of children) may change the disease into the diphtheritic form.

With regard to the *treatment*, it must be confessed that we have, unfortunately, but little control over the disease during the first period.

Our first care must be to remove the patient from all noxious influences that may keep up and intensify the disease, and every effort must be made to prevent its spreading.

We must endeavour to diminish the inflammatory symptoms, more particularly if they assume a sthenic type. If the eyelids are greatly swollen, and very red, hot, stiff, and painful, ice compresses must be employed almost without intermission, being changed as soon as they become at all warm. They must be less frequently employed when the second period (that of vascularization) is setting in, and when this has become fully established they must be only used after the cauterization. The effect of the cold is to counteract the stasis, by causing contraction of the vessels, and it also acts as a sedative, giving great relief to the intense pain. But if there is extensive ulceration of the cornea, the cold compresses should be replaced by warm fomentations, so that we may produce an acceleration in the vascularity of the conjunctiva. Indeed,

lately some surgeons, especially Berlin* and Mooren,† have recommended the substitution of warm fomentations for the ice compresses, on the ground that they bring about the second period more rapidly. Thus they may prove of advantage when ulceration of the cornea occurs during the first period, and the ulcer shows no tendency to become limited or vascularized, for the tendency to necrosis is markedly aggravated by the application of cold or of caustics. Mooren formerly always employed ice compresses, but in later years he has substituted the use of warm poultices, together with derivatives internally. But, then he himself admits that the disease never appears in Düsseldorf with the extreme intensity that it so often assumes in Berlin.

Local depletion also proves of much service. Unfortunately, the disease occurs so frequently in anæmic and cachectic individuals, that we generally cannot make a full use of this. In adults, more particularly if the disease is due to contagion, and the patient robust and strong, leeches should be applied in large quantities to the temples, or at the upper angle of the nose. Three or four leeches should be applied at a time, and as soon as these drop off they are to be replaced by others. But care must be taken not to push this remedy too far, especially in feeble persons, for by greatly weakening the patient we increase the danger of sloughing of the cornea. In very severe cases as many as 30—40 leeches (Weeker) or even a greater quantity (Graefe) may have to be applied before any impression is made upon the disease.

Scarification is but of little, if any, use during the first stage, for only a very small quantity of blood is obtained; indeed, sometimes it may even do positive harm, being followed by a more considerable fibrinous infiltration; but when the second stage has set in, when the conjunctiva has become more vascular and there is an effusion of serum into it, scarification is often of much benefit. The incisions should be somewhat deeper than in purulent ophthalmia, and the bleeding be kept up by kneading the lids.

In order to hasten the vascularization and the breaking down and elimination of the fibrinous infiltration of the conjunctiva, the system should be got as quickly as possible under the influence of mercury, so that salivation may be produced in the course of 30—40 hours. The mercury may either be administered internally in the form of calomel and opium (calomel gr. ss.—gr. j every 2—3 hours) in doses varying with the age of the patient, or from ʒss—ʒj of the mercurial ointment should be rubbed in three times daily. In very severe cases the rapidity with which the fibrinous infiltration pervades the conjunctiva is often so great that the cornea becomes implicated and the eye lost,

* "Kl. Monatsbl." 1864.

† "Ophthalmiatrische Beobachtungen," p. 70.

before the system can be brought under the influence of mercury. Moreover, the free use of this remedy is often contra-indicated by the very feeble and cachectic condition of the patient.

When the disease is passing over into the second stage, and is assuming more and more the character of purulent ophthalmia, we must gradually commence the use of the mitigated nitrate of silver. But at first the cauterization must be employed with great care and discretion, as there is always the risk of causing a relapse if it be used with too great a freedom at once. Should symptoms of stasis re-appear the cauterization must be immediately abandoned until these have disappeared, and the disease again assumes the purulent character.

7.—GRANULAR OPHTHALMIA.

It has been already mentioned that in catarrhal and purulent ophthalmia, the papillæ of the conjunctiva are often much swollen and hypertrophied, forming more or less prominent elevations on the palpebral conjunctiva. They appear in the form of bright or bluish red, velvety, succulent elevations, which have no distinct pedicle, but seem to pass over into the tissue of the conjunctiva. They are ranged in rows, and are of course confined to that portion of the conjunctiva which contains papillæ. Commencing at about a line from the free margin of the lid, they extend slightly beyond its tarsal border; their sides are generally flattened, on account of the papillæ being pressed against each other. They are often very conspicuous at the angles of the eye, and assume also a considerable size near the retro-tarsal fold, looking perhaps like large warty excrescences. The name of granular lids is but too often given to this hypertrophied condition of the papillæ, instead of being limited to the true granulations, which are neo-plastic formations and not swollen papillæ. On account of this error, the greatest confusion still reigns upon this subject, a confusion which not only materially affects the diagnosis but also the treatment of the disease. What has tended still more to foster this misconception of the real nature of granular ophthalmia is the fact, that true granulations are generally accompanied in the course of their development, by a more or less swollen and hypertrophied condition of the papillæ. If the latter gain a considerable prominence the granulations may even be hidden by them. Stellwag de Carion* applies the term of "*papillary trachoma or granulations*" to these hypertrophied papillæ, and I see no objection to retaining this name, if it be only remembered that these differ altogether in their nature and mode of development from the true granulations.

* "Practische Augenheilkunde," 3rd edition, p. 404. 1867.

Before proceeding to the consideration of granular ophthalmia, I must call especial attention to a peculiar vesicular condition of the conjunctiva, which is frequently premonitory of that affection. It is a matter of surprise that this condition, which has been so carefully and elaborately described by several eminent continental writers, more especially Stromeyer, Bendz, and Warlomont, should have apparently altogether escaped the attention of many English ophthalmic surgeons; indeed, we are principally indebted to two distinguished English military surgeons* for giving this subject due prominence in our medical literature, and calling the attention of the profession, and more especially of army medical men, to a condition of the eye which is very important to all who have the charge of large bodies of men, *e.g.*, soldiers, paupers, convicts, etc.

This vesicular condition of the conjunctiva is distinguished by the following symptoms:—On everting the lower eyelid, we notice upon it small, round, transparent bodies like little sago grains or herpetic vesicles, which are situated directly beneath the epithelium. They mostly make their appearance first on the lower eyelid, and may, indeed, remain confined to it, but they generally extend to the upper eyelid, and I have seen a few rare instances in which they encroached considerably upon the ocular conjunctiva. The vesicles are sometimes isolated and but few in number, being sparsely scattered about the conjunctiva especially near the outer angle of the eye. In other cases they are studded thickly over the palpebral conjunctiva and retro-tarsal fold. They cannot be emptied of their contents by pricking, and differ in this from the sudamina of herpes, and the serous elevation of the epithelium of the conjunctiva, which is occasionally met with in catarrhal ophthalmia; moreover, in the latter condition the vesicles are much larger. The vesicles consist of a stroma of connective tissue containing nucleated cells like lymph corpuscles, with a little fluid. They are surrounded by a delicate layer of condensed connective tissue, which has no proper enveloping membrane, but passes over into the neighbouring less condensed tissue. With a fine needle we may often succeed in removing them entire. They seem to be identical in structure with the closed follicles of the intestines, etc. Sometimes these vesicles appear without any change in the conjunctiva. Generally, however, there is an increased vascularity of this membrane with some swelling, more especially at the retro-tarsal fold. The vessels of the conjunctiva are very apparent, and often of a dusky

* I refer here to the excellent and very interesting articles on "Military Ophthalmia," by Dr. Frank, late of the Army Medical Department, and by Dr. Marston. Both deserve the careful study of all surgeons. The first appeared in the "Army Medical Blue Book," of 1862; the second in Beale's "Archives of Medicine," No. xi. 1862.

bluish-red colour, sending small branches towards the vesicles, which may appear arranged in rows like little transparent beads. But this hyperæmic condition may sometimes mask the presence of the vesicles, especially if they are small and not very numerous, so that they might readily be overlooked by a superficial observer. If the conjunctiva is however examined through a magnifying glass, they will be easily distinguished.

If the hyperæmia of the conjunctiva is but slight, these vesicles may exist for a very long time, for months or years, without producing any sensible discomfort or symptoms of inflammation. The patient may either be quite unaware that there is anything the matter with his eyes, or he may only notice a slight sensation of pricking or itching in the eye, the lashes being perhaps somewhat glued together in the morning. There may also be a tendency to irritability of the eyes during reading or writing, more especially by artificial light. Sometimes, however, even these symptoms are entirely absent.

This vesicular condition of the conjunctiva is due to an enlargement of the closed lymphatic follicles of Krause, which are situated directly beneath the epithelium, and which are not apparent in a normal state of the conjunctiva, but become swollen and enlarged when this membrane is in an irritable condition. Stromeyer* called special attention to these vesicular granulations, but supposed that they were pathological products and did not exist in a healthy conjunctiva. The researches of Krause and Dr. Schmidt of Berlin have, however, distinctly proved that they are physiological organs, which are not apparent to the naked eye whilst the conjunctiva is in a normal condition, but are apt to become enlarged into these sago grain vesicles from a proliferation of their contents, more especially of their connective tissue elements, when there is any chronic irritation of the conjunctiva.

Now it is a very important question, and one which has not at present received a decided and satisfactory answer, whether the true granulations are developed from these vesicular bodies, or rather the follicles of Krause, or whether they are a distinct neo-plastic formation, due to a proliferation of the contents of the connective tissue cells of the conjunctiva. The former view is maintained by several observers of eminence, more especially Bendz and Stromeyer. But one weighty argument against this view is furnished by the fact that true granulations sometimes occur in situations where these follicles are more or less completely wanting, as for instance on the ocular conjunctiva. Wecker strongly advocates the view that the true granulations are neo-plastic formations, akin to tubercle, and are due to a proliferation of the contents of the connective tissue cells, and that they consist of a mass of closely packed nuclei with little or no connective tissue between them.

* Stromeyer, "Maximen der Kriegsheilkunst." 1861.

At a later stage the connective tissue becomes increased in quantity, and forms a semi-transparent, gelatinous, grumous mass containing a small quantity of fat. The nuclei diminish in number, and are finally only sparsely scattered amongst the connective tissue. It is an important fact that this gelatinous mass becomes transformed at a later stage into a dense fibrillar tissue, and that the latter shows a great tendency to contraction, thus causing more or less destruction of the true conjunctival tissue. A firm cicatricial tissue is formed, which gives a streaky tendinous appearance to the inner surface of the lids; the latter gradually become shortened, the retro-tarsal fold almost obliterated, the tarsal cartilages incurved, thus giving rise to trichiasis and entropion.

I have never had the opportunity of distinctly tracing the transformation of the vesicles into true granulations, as they are far less frequently met with in civil than in military practice. Moreover, we cannot watch the patients so constantly and closely. They attend perhaps for some length of time with vesicular granulations, and are then lost sight of. The same difficulty exists with regard to the determination as to whether a given case of acute or chronic granulations has been preceded by a vesicular condition of the lids, for it has been already stated that the latter may exist for a long time without the knowledge of the patient. The definite settlement of these questions will, I think, depend very much upon the observations made by our military *confrères*, who enjoy every opportunity of constantly watching the development of the disease from its earliest (vesicular) stage to the latest, and their experience upon these points is therefore of the greatest importance.

But whether we accept or not the theory that vesicular granulations are the first symptoms of granular ophthalmia, and may become developed into true granulations, there cannot be the slightest doubt that they must be regarded as a strongly predisposing cause of the latter. It is, therefore, of great importance that their existence should be detected as early as possible, more especially where a large number of persons are collected together as in barracks, workhouses, and schools. For this vesicular state of the conjunctiva must be watched with care and anxiety, as it chiefly occurs in individuals living in a confined and vitiated atmosphere, and under faulty sanitary arrangements. Proper hygienic measures should, therefore, be at once adopted, and the patients, if necessary, submitted to treatment; for if these vesicular granulations be allowed to exist unchecked, and such eyes are exposed to the usual irritating influences met with in marches and encampments, as for instance exposure to wind, dust, draughts of cold air or bright glaring sunlight, an epidemic of granular ophthalmia is but too likely to break out, the ravages and extent of which cannot be foretold. It is an inte-

resting fact that Stromeyer* also met with these vesicular granulations amongst many of the domestic animals, more especially pigs, and that they existed in proportion to the dirty condition in which these animals were kept. These observations, moreover, entirely agree with those made amongst human beings, for he found that vesicular granulations occur especially amongst persons inhabiting crowded, close, dirty, and ill-ventilated dwellings.

Dr. Marston, who has enjoyed great opportunities of studying the phenomena of granular ophthalmia, holds similar views. He found† vesicular granulations very prevalent amongst the poorer classes in Gozo, especially where there was a large family, who live in wretchedly confined cabins, often with their domestic animals. With regard to the importance of vesicular granulations, as being indicative of a vitiated state of the atmosphere, he says, "So certain do I feel that the prevalence of vesicular disease of the lids is in direct ratio to the amount and degree of defective sanitary arrangements, that I conceive the palpebral conjunctiva offers a delicate test and evidence as to the hygienic conditions of a regiment."

It is, therefore, of much importance to discover the presence of vesicular granulations as early as possible, in order that the hygienic conditions of the ward or sleeping apartment of the patient may be thoroughly examined. Such patients should be placed in large, airy, well ventilated rooms, which are not exposed to the bright sunlight. Strict orders should also be given that the same sponges, towels or water are not used for others. Indeed, it is advisable that even healthy persons should always wash in fresh water. It is better to separate those affected with vesicular granulations from the healthy, for I think that there can be little doubt that vesicular granulations are contagious, more especially when they are accompanied by conjunctival swelling, and a little muco-purulent discharge. The patients should be in the open air as much as possible, care being taken, however, that they are not exposed to dust, wind, and bright sunlight. Their diet should be nutritious and easily digestible. If they are weak or scrofulous, quinine, steel, cod-liver oil, etc., should be administered. If there is slight conjunctivitis, with a little discharge, or small yellow shreds are formed on the conjunctiva, a weak astringent collyrium (Zinc. Sulph. or Plumb. Acetat., gr. 1—4 ad ʒj Aq. distill., or Boracis gr. iv—vj ad ʒj) should be used, or the lids may be very lightly touched with a crayon of sulphate of copper, or still better, of the lapis divinus. Pricking the vesicles with a needle does little or no good. The eye douche or the pulverizer is found to be very beneficial and agreeable to the patient. I have occasionally met with this vesicular condition of the eyelids

* Stromeyer, "Maximen der Kriegsheilkunst," p. 49. † Loc. cit., p. 201.

amongst wealthy persons, in whom the conjunctiva was in a state of irritation from exposure to cold, bright light, etc., and where no faulty hygienic arrangements could be discovered. The affection readily yielded to mild astringents, the eye douche, and careful guarding the eyes against exposure and too much reading, etc. Vesicular granulation may also be produced by the long-continued use of atropine. I have lately met with some striking examples of this. The disuse of the atropine and the employment of a weak astringent collyrium, soon caused the granulations to disappear; but, on the re-application of atropine, a fresh crop rapidly sprung up.

We must now pass on to the consideration of "Granular Ophthalmia." In practice we find that we may distinguish two special forms under which the disease shows itself, viz., the *acute*, which is often accompanied by severe inflammatory symptoms, and the *chronic*, in which these are sometimes but moderate, and occasionally almost entirely absent. Of course we meet with numerous cases which cannot be properly placed in either category, but show a mixed character. Practically, it is, however, of much consequence to distinguish between the acute and chronic forms, for great and serious mischief may accrue from a mistaken diagnosis and treatment of a case of severe acute granular ophthalmia.

ACUTE GRANULAR OPHTHALMIA.

If the attack is severe, there are generally marked inflammatory symptoms; the eyelids are red, swollen, and œdematous, and on opening the eye, we see that there is a good deal of conjunctival and subconjunctival injection. The degree of conjunctival swelling varies; sometimes it is considerable, more especially in the retro-tarsal region, and there may also be marked serous chemosis. The photophobia and lachrymation are often very great, so that the patient is quite unable to open the eye, and directly it is attempted, hot scalding tears flow over the cheek. There is often severe throbbing pain in and around the eye, and perhaps over the corresponding half of the head. On eversion of the lids, we find that the conjunctiva is vascular and swollen, and that the papillæ are prominent, red, and succulent. On closer inspection (with or without a magnifying glass) we notice, scattered between the papillæ, and perhaps almost hidden by them, numerous small, round, white bodies, like sago grains, which are not, however, confined to the palpebral conjunctiva, but extend to the retro-tarsal fold. They are also sometimes seen on the ocular conjunctiva, and even on the cornea, where they give rise to a superficial vascular inflammation (pannus). If we examine the cornea in such a case by the oblique illumination,

and through a magnifying glass, we find that this opacity is composed of a quantity of small elevated grey dots, with the epithelium raised over them. Numerous blood vessels run over from the conjunctiva to these spots, giving a more or less red tint to the opacity of the cornea. This vascular opacity may involve a considerable portion of the cornea, and is not chiefly confined to the upper half, as is the case in the pannus produced by the friction of granulations or inverted eyelashes of the upper lid, upon the surface of the cornea. Sometimes small ulcers appear at the edge of the cornea. When the acute stage has lasted for a few days, the symptoms of irritation begin to diminish. The severe pain, photophobia, and lachrymation decrease, the papillæ at the same time becoming more turgid, vascular, and prominent, thus hiding the granulations; whilst the discharge, which has hitherto been chiefly watery, with perhaps only a few yellow flakes suspended in it, becomes thicker and muco-purulent in character. The intensity of the conjunctival inflammation varies greatly; sometimes it reaches only the catarrhal form, at others it assumes a severe purulent type. The stage of purulent ophthalmia generally lasts for several weeks, and then the symptoms gradually subside; the papillæ diminish in size, and the white sago grain granulations are then perhaps found to have disappeared, they having in fact been absorbed during the inflammatory state of the conjunctiva. But so favourable a result is not always obtained, for on the decrease of the inflammatory symptoms, and the diminution in the size of the papillæ, the white, and now more prominent, spots may re-appear between them, the inflammation having been insufficient for their absorption. If the patient is exposed to any fresh exciting cause, a relapse may occur, and a renewed attack of more or less severe acute ophthalmia may take place. This is, however, far less common than in the chronic form.

Contagion is a very frequent cause, for the discharge from an eye affected with acute granulations is very contagious, more especially during the muco-purulent stage. It does not necessarily reproduce the same affection, but like purulent, or even diphtheritic ophthalmia, may give rise to catarrhal, purulent, or diphtheritic conjunctivitis. This will depend upon local and individual circumstances, and upon the character of any epidemic of conjunctivitis that may be prevailing at the time.

Another very fruitful source of acute granulations is defective hygiene. The long continued use of atropine may also produce them.

The *prognosis* in acute granular ophthalmia is generally favourable, if the true nature of the affection is recognised at the outset, and a proper course of treatment is adopted. But if the disease is mistaken for a case of purulent ophthalmia, and freely treated by strong caustics, the intensity of the irritation will be greatly increased, and the inflammation may even assume a diphtheritic character. At the best, the

salutary inflammation of the conjunctiva will be suppressed, and the absorption of the granulations checked.

The *treatment* must vary with the nature and stage of the affection. We must especially remember that when the acute symptoms of irritation have subsided, our chief object is to obtain, if possible, the absorption of the granulations by keeping up a certain amount of inflammation of the conjunctiva. The degree of the latter should just suffice to promote this absorption, but should never be allowed to become so considerable as to arrest or retard it.

If there is much photophobia, lachrymation, and ciliary irritation, the greatest care must be taken to avoid all stimulating applications. Atropine drops (gr. ij ad ℥j) should be applied three or four times daily. If they are, however, found to keep up or increase the irritability, they should be at once exchanged for a Belladonna collyrium (Ext. Bellad. ℥ss. ad Aq. distill ℥j), which should be applied somewhat more frequently, and in larger quantity. At the same time, the compound Belladonna ointment should be rubbed into the forehead every four or six hours, until a slight papular eruption is produced. If the pain in and around the eye is very severe, of a pulsating, throbbing character, and increases much towards night, a few leeches should be applied to the temple. Cold compresses are also of much benefit in subduing the irritation and relieving the pain. They must, however, be applied with circumspection, and their effect watched. If the conjunctiva is much swollen, more especially in the retro-tarsal region, it may be lightly scarified, care being taken to make the incisions very superficial, so that no cicatrices may be left.

When the symptoms of irritability subside, and the disease assumes the character of purulent ophthalmia, it must be treated on the same principles as that affection. The same rules as to the choice and mode of application of caustics apply, as in the latter disease. The only difference being, that the cauterization must not be repeated so frequently, as we must remember that it is desirable to maintain a certain degree of inflammation in order to favour the absorption of the granulations. But care must be taken not to commence the use of caustics too early, whilst there is still considerable irritability of the eye, otherwise this will be greatly increased, and infiltrations, or even ulcers of the cornea, may be produced. In those cases in which we are in doubt as to whether the irritability of the eye is not still too great for the application of the nitrate of silver or sulphate of copper, it is always wiser to feel our way with some milder application. For this purpose we may try a weak solution (gr. vi—x ad ℥j) of the acetate of lead, a little of which should be painted over the granulations with a brush, and at once washed off with warm water, and if this is well borne, and causes a subsidence of the inflammatory symptoms, we may, in the

course of a day or two, pass over to the use of the stronger caustics. But if any infiltrations or ulcers of the cornea exist, the acetate of lead should never be used, as it will be precipitated upon the cornea, and give rise to very marked stains. Von Graefe* strongly recommends chlorine water for the purpose of paving the way for the use of stronger caustics in acute granulations.

When the crayon of nitrate of silver and potash is applied, it should be *at once* neutralized by the application of salt and water. As a rule the cauterization should not be repeated more frequently than every 48 hours. Great care must be taken if any ulcers of the cornea exist, for they may be easily aggravated by too free a use of the nitrate of silver. If there is a great deal of irritation, I often apply atropine drops in the interval of the cauterization. When the swelling of the conjunctiva has considerably subsided, and the purulent discharge diminished, the sulphate of copper in substance, or a collyrium of acetate of lead may be employed with advantage. If it is found that, together with the diminution of the inflammation and the size of the papillæ, the granulations assume a more prominent character and increase in size and number, this tendency to a neo-plastic formation must be checked at once, and their absorption hastened, by exciting a more considerable amount of inflammation by means of a freer use of some caustic, especially the sulphate of copper, which possesses the great advantage of increasing the inflammation without giving rise to thick firm eschars.

CHRONIC GRANULATIONS.

Instead of the very pronounced symptoms of irritation and inflammation which are met with in acute granular ophthalmia, the inflammation accompanying the chronic form is often very slight, and may, indeed, be almost absent at the commencement of the affection. So that, in fact, persons may be suffering from chronic granulations without being aware that there is anything particular the matter with their eyes; the eyelids being only a little glued together in the morning, or there being perhaps a slight feeling of roughness under the eyelids. At the same time, the upper lid may hang down somewhat, its natural folds being more or less obliterated, and the palpebral aperture consequently narrowed. During all this time the conjunctival inflammation may be almost absent; indeed, it is never very prominent, or in proportion to the amount of the granulations. On eversion of the lids, we at once notice the presence of the granulations in the form of small greyish-white bodies, like tapioca grains, more especially at the retro-tarsal fold, and in the vicinity of the angles of the eye. They may

* "A. f. O.," x, 2, 197.

also appear on the palpebral conjunctiva, which is somewhat injected and swollen. In this situation, however, their size and number are less than at the retro-tarsal fold. These may be termed "simple granulations," or, according to Stellwag, "granular trachoma." Generally, however, this condition is soon followed by inflammatory symptoms. The conjunctiva becomes vascular, thickened, and swollen, and the papillæ hypertrophied and prominent, having the granulations scattered between them. Here, therefore, we have true granulations existing side by side with the swollen papillæ, and hence Stellwag calls this form "mixed granulations." The lids are more or less pulpy, the conjunctiva red and swollen, especially in the retro-tarsal region, and there is, perhaps, some chemosis round the cornea. The discharge, which was at first thin and watery, with only a few yellow flakes suspended in it, becomes thicker, more copious, and of a muco-purulent character. The eyes are very irritable, and the patient experiences a sensation as of grit or sand in them, especially under the upper lid, and is unable to expose them to wind, bright glare, dust, or to long continued work, without their becoming very red, watery, and inflamed.

But all these symptoms vary considerably in intensity, according to the degree of the accompanying conjunctival inflammation. Sometimes this assumes a mild catarrhal form; in other cases it is more severe and of a purulent type. The course of the disease is often extremely protracted, extending over many months, or even years. A source of danger and great annoyance and discomfort is the tendency to relapses, the intensity of which also varies. Thus a mild attack of chronic mixed granulations may be nearly cured, when from an exposure to some irritating cause, a relapse occurs, accompanied, perhaps, by a more severe form of conjunctivitis than the original one, and a fresh crop of granulations appears before the former ones have been absorbed. These inflammatory symptoms are, however, rather due to a renewed swelling of the papillæ than to a new formation of granulations. Sometimes these relapses are accompanied by considerable infiltrations of the cornea. Such relapses may occur again and again, leaving the eye each time in a worse condition, and gradually giving rise to various serious complications, such as pannus, trichiasis, entropion, &c.

If the attack is severe, and the crop of granulations very considerable, the infiltration but too often extends from the surface to the substance of the conjunctiva. The granulations then become more velvety, red, prominent, and diffused in appearance, (hence the "diffuse trachoma" of Stellwag), and are often divided by deep chinks. They are, therefore, less distinguishable from the papillæ, especially as the latter often assume a brownish-red colour, and their epithelial layer becomes somewhat thickened.

If the development of the granulations cannot be checked, and they extend deeply into the stroma of the conjunctiva, the latter often contracts, atrophies, and becomes gradually changed into a kind of fibrous cicatricial tissue. These changes may even extend to the cartilage, and the cicatrices lend a peculiar glistening or tendinous appearance to the surface of the conjunctiva. We see the latter occupied by narrow tendinous streaks, the longest and most marked generally running parallel to, and about one line from the edge of the lid. Other tendinous streaks extend in a reticulated manner towards the retro-tarsal fold. But if the atrophy of the conjunctiva and cartilage is very considerable, the blood-vessels gradually become obliterated, and the surface of the conjunctiva then assumes a pale, waxy, uniformly tendinous appearance, the papillæ, follicles, and finally the Meibomian glands becoming destroyed. It is important to remember that too free a use of caustics (especially the nitrate of silver in substance or in strong solution) will destroy the delicate structure of the conjunctiva, and produce more or less extensive cicatrices.

These changes often extend to the retro-tarsal fold, which becomes contracted and tendinous, so that its free border is shortened and rounded. It no longer springs into folds at the point where it is reflected from the lid on to the eyeball, but, on account of this shortening, it passes almost straight on, so that the fold or cul de sac which should exist at this point is obliterated. This condition has been termed symblepharon posterius. If it is very considerable, the lids cannot be completely closed, and thus a certain degree of lagophthalmos may be produced.

These changes in the conjunctiva are of course accompanied by an alteration and diminution in its normal secretions, so that its surface becomes dry, rough, and scaly. This dryness (xeropthalmia) is often increased by the narrowing or even obliteration of the ducts of the lachrymal gland, by the inflammation of this portion of the conjunctiva.

On account of the atrophy and contraction of the conjunctiva and tarsal cartilage, the latter becomes shortened and incurved. If this be but slight, it may only produce an inversion of the eyelashes (trichiasis), which now sweep and rub against the surface of the cornea. This inversion may be confined to one portion of the lashes, or extend to the whole row. If the contraction of the cartilage is considerable, not only the eyelashes, but the free edge of the lid will be rolled in, and thus an entropion will be produced. The constant friction of the lashes and the edge of the eyelid against the cornea, irritates the latter, and soon gives rise to superficial vascular corneitis (pannus). This pannus may be termed "traumatic" (Arlt), being produced by the friction of the inverted lashes, or of prominent granulations or papillæ, &c., in

contradistinction to the pannus, which is due to an extension of the granulations on to the cornea. The differential diagnosis between these two forms is generally not difficult. In the latter, we can trace the extension of the disease from the ocular conjunctiva on to the cornea. Small, round, elevated, grey infiltrations are formed on its surface just beneath the epithelium, and extend over a considerable portion, or even the whole of the cornea. Between these little nodules, blood-vessels appear in more or less considerable number. These infiltrations often leave behind them depressions or small ulcers on the surface of the cornea. The traumatic pannus almost always commences at the upper portion of the cornea, extending from the periphery. This is due to the fact, that the granulations are generally more prominent, and trichiasis is more frequent in the upper lid than in the lower. The pannus frequently remains confined to the upper portion of the cornea, the lower continuing transparent.

Chronic granulations occur most frequently in adults, and are but seldom met with in children, or the very aged. Both eyes generally become affected either at the outset, or after a time. It has been maintained by some ophthalmic surgeons of eminence (more especially Arlt), that the disease is often due to constitutional causes, particularly scrofula. This does not, however, appear to be the case, although it must be conceded, that it is frequently met with in weakly, cachectic, and scrofulous individuals. But ill-health is, I think, rather the effect than the cause, for the very protracted course of the disease is sure to tell more or less severely upon the health and spirits of the patient.

Defective hygiene and contagion are also the chief causes of chronic granulations. The muco-purulent discharge is very contagious, and may re-produce a similar affection, or it may cause catarrhal, purulent, or even diphtheritic ophthalmia, just as, conversely, these diseases may produce granular lids.

It is probable that, as in purulent ophthalmia, the disease may also be propagated by the air, more especially if it is accompanied by severe purulent discharge, and the cases are crowded together in small, close, ill-ventilated rooms. The disease may occur epidemically and endemically. It spreads rapidly amongst the inhabitants of closely-crowded dwellings, such as barracks and workhouses. It is very prevalent amongst certain nationalities, where the people are crowded together for a length of time in small dirty cabins, filled, perhaps, with smoke and ammoniacal exhalations. Thus it is very common amongst the poorer Irish, and also amongst the Russian peasants (Wecker).

The *prognosis* of chronic granular ophthalmia may be favourable, if the granulations have been but limited in number, and the patient has been treated from the outset. It must, however, be always remembered that the course of the disease, even in the most favourable cases,

is apt to be very protracted. This will be more especially the case, if the granulations have appeared in considerable quantity; if they have invaded the stroma of the conjunctiva, and if there is a tendency to relapses. For then serious complications, such as trichiasis, entropion, and pannus, are likely to occur, and will not only aggravate the symptoms, but greatly retard the cure.

In the *treatment* of this disease, our first care must be to place the patients under the most favourable sanitary conditions. They should take a good deal of out-door exercise, their eyes being protected against wind, dust, and bright light by blue glasses. They should be warned not to expose themselves to any irritating causes, as, for instance, tobacco smoke. I have often known the disease aggravated and kept up by the patient spending much time in a room filled with tobacco smoke. For this reason no smoking should be allowed, except in the open air, and then only to a limited extent. The general health must also be attended to. Not only may the patient be naturally weak and feeble, but the severity and protracted course of the disease are but too likely to affect the health, and at the same time to exercise a most depressing influence upon the mind. The diet should be nutritious, and easily digestible, and malt liquor and wine will generally be very beneficial. If the patient is scrofulous, or weak and feeble, cod liver oil, steel, and quinine should be freely given, and every care taken to invigorate the constitution as much as possible by open air exercise, sea-bathing, or even a voyage.

In our local treatment we must be chiefly influenced by the fact, that the maintenance of a certain degree of inflammation of the conjunctiva is necessary and desirable, in order to produce and hasten the absorption of the granulations. Our chief efforts must, therefore, be directed to maintain the requisite degree of inflammation, and so to balance it that it shall not on the one hand be too considerable, nor on the other too slight for promoting the absorption.

The greatest stress must be laid upon the fact, as Arlt and Stromeyer remind us, that the purpose of the cauterization is *not* that of chemically destroying the granulations, for this would lead to great and lasting injury of the conjunctiva from the destruction of its secreting organs, and the formation of dense cicatrices; but, its object is to maintain a certain degree of hyperæmia and inflammation of the conjunctiva, in order to hasten the absorption of the granulations. The nature and strength of the caustic must vary with the effect we desire to produce. If there is much swelling of the conjunctiva and papillæ, together with a thick, copious muco-purulent discharge, the crayon of nitrate of silver and potash should be applied, its effect being at once neutralized by the solution of salt and water. The cauterization may be repeated every 48 hours. If the patient cannot be seen sufficiently frequently

for this, he should use a collyrium of nitrate of silver (gr. ij—iv ad ℥j), or of sulphate of copper of the same strength, two or three times daily. In these cases we may also first try the effect of a collyrium of acetate of lead, or the chlorine water, in order to see if the conjunctiva will bear the nitrate of silver. The use of very strong solutions of nitrate of silver (gr. x—xx ad ℥j.) are not judicious, as they are but too likely to destroy the granulations, and with them the normal structure of the conjunctiva, instead of simply favouring their absorption. I think the crayon of nitrate of silver or copper is always to be preferred to the use of collyria, as we can regulate and limit the effect of the cauterization according to our wish, confining it, if necessary, chiefly or entirely to certain portions of the conjunctiva. If there is considerable swelling of the conjunctiva, especially at the retro-tarsal fold, superficial scarification may be employed with much advantage. After the cauterization cold compresses should always be applied to the eyelids, in order to diminish the inflammatory reaction, or the cold douche or pulverizer may be employed. If the conjunctivitis is so slight as not to produce the absorption of the granulations, but rather to encourage their development, it will be necessary to increase the hyperæmia and inflammatory swelling of the conjunctiva. The repeated application of sulphate of copper in substance is very effectual for this purpose. The same effect may also be produced by the application of warm compresses to the eyelids. Von Graefe* has found this treatment very successful, especially in those cases in which the granulations tend to extend deeply into the conjunctiva, and in which there is not a sufficient degree of hyperæmia and swelling of this membrane. These warm compresses should, however, only be applied for a limited period, otherwise they may produce too considerable an inflammation and too great an irritability of the eye.

In treating chronic granulations, it will be necessary occasionally to change the caustic, as it loses its effect after a time, from the conjunctiva becoming accustomed to it. Thus alum, acetate of lead, or tannin, may be substituted with advantage for the nitrate of silver and sulphate of copper. In some cases the acetate of lead should be rubbed in (finely powdered) between the granulations. This treatment, which was first adopted by Buys,† has been practised with great success, especially in Belgium. I have employed it with much benefit in those cases in which, together with but a slight secretion and lachrymation, the granulations are prominent and fleshy, being arranged in rows with deep furrows or chinks between them. Finely powdered acetate of lead should be freely rubbed into these furrows until they are quite filled up. The effect of this is, so to speak, to choke the granula-

* "A. f. O.," vi, 2, 147.

† French Translation of Mackenzie's Treatise, by Warlomont, 1, 748.

tions, their vitality is impaired, and they gradually dwindle down in size and disappear. After the application, the conjunctiva looks marbled or tattoed of a red and white colour, the chinks are filled up, and it soon becomes smooth and even. An important fact in connexion with this treatment is, that the discharge is now no longer contagious; at least in Belgium it is always considered, when the acetate of lead has been rubbed in, that the patients may go with impunity amongst healthy persons, so that soldiers affected with granular lids need no longer be confined and separated from the others, but may, if they are able, resume their duties without danger of spreading the disease. The acetate of lead is best applied in the following manner:—The eyelids having been thoroughly everted and the retro-tarsal fold brought well into view, a small portion of very finely powdered acetate of lead is then taken up in a small curette and dusted over the granulations, being well rubbed into the chinks so as to fill them up. The watery discharge from the conjunctiva forms the powder into a thin plasma, which runs through and fills up the furrows between the granulations. When it has been applied to every portion of the granular conjunctiva, a small stream of cold water, either from a sponge or an india-rubber ball syringe, should be made to play upon the conjunctiva, in order to wash away any superfluous quantity of the powder, which comes away in small white flakes. Both eyelids may be everted at the same time, so as to fold over and protect the cornea, the powder being rubbed over both eyelids, and the stream of water applied before they are replaced. But if the simultaneous eversion of both lids is difficult, or the patient very restless and unruly, it is better to evert one lid at a time. It is best to commence with the lower lid, for if the lead be applied first to the upper, the lower becomes reddened and bathed in tears, so that it will not only be difficult to see the chinks, but the powder will be readily washed away by the tears, whereas the conjunctiva of the upper lid, from its greater expanse, can be more readily dried, and the tears are hence of less inconvenience.

Directly after the application, there is an increased flow of tears, the ocular conjunctiva becomes injected, and this is accompanied perhaps by considerable irritation, heat, and smarting in the eye, but these symptoms will soon yield to the application of cold compresses. In about half an hour, the lids should be everted and the conjunctiva again washed by a stream of water, in order that any remains of the lead may be removed. The conjunctiva will now be more smooth and even, the chinks between the granulations being filled up and obliterated by the powder. If the application has been insufficient or too superficial, the granulations will reappear after a time and increase in size and prominence, rendering a fresh application of the remedy necessary. If the acetate of lead is carefully applied and the surplus well washed

away, I cannot say that I have ever seen any disadvantage arise from its employment, nor have I found that it roughens the lids and thus irritates the surface of the cornea. The best mode of applying the solution of the acetate of lead is to evert the lids, and after drying the conjunctiva with a piece of linen, to apply it with a small brush to the granulations, this being neutralized after a few seconds with tepid water. The strength of the solution should vary from 6 to 10 or 20 grains to the ounce, according to the condition of the conjunctiva, and it should be applied every day or every other day.

I must strongly object to the application of undiluted liquor potassæ to the granulations, as this not only more or less destroys the stroma of the conjunctiva, but gives rise to very considerable cicatrices, leading to entropion, etc.

Should any ulcers of the cornea exist, the treatment of the conjunctivitis by caustics must be continued, but atropine should be applied in the intervals. The application of a firm compress bandage often acts very advantageously in checking the growth of the granulations, and hastening their absorption; but other local remedies must be at the same time applied. It has even been suggested to keep up a considerable degree of compression by ivory plates adjusted to the lids.*

The treatment of the pannus must vary according to its cause, its degree, and length of existence. If it be dependent upon the friction of inverted lashes, prominent granulations or papillæ, or upon entropion, these affections must be treated, and when they are cured the pannus will soon disappear. But if the granular lids and the pannus have become very chronic, they may set the most obstinate defiance to the most varied treatment. Caustics and stimulant applications of every kind may be tried, and yet the disease prove intractable. In some cases, in which the pannus was not too dense and vascular, I have found a good deal of benefit from a collyrium composed of 1 part of oil of turpentine to 2 or 4 parts of olive oil. A drop of it should be applied once or twice daily to the inside of the lid. This collyrium was, I believe, first recommended by Donders. If, on the disappearance of the pannus, we find the curvature of the cornea considerably altered, or a central opacity remain, it may be necessary to make an artificial pupil, either by an iridectomy or an iridodesis.

Von Graefe† has found great benefit from chlorine water in cases of even severe complete pannus. He especially mentions two cases in which the pannus was so advanced that the patients could only distinguish light from dark, and were quite unable to count fingers. In both, not only had various caustics, such as nitrate of silver, sulphate of copper, acetate of lead, been applied for many months without avail, but syn-

* Vide Dr. Stokes' paper on this subject, "Dub. Quart. Journal Med. Science," xli., 38.

† "A. f. O.," x, 2, 198.

dectomy had been performed, and in one inoculation, without any beneficial result. After using the chlorine water for six or eight weeks, they were both so much improved as to be able to find their way about tolerably well. In other less severe cases of pannus he has also experienced much benefit from its use.

For very inveterate cases of pannus, more especially if they only involve a portion of the cornea, syndectomy may be tried. This operation, which was first introduced by Dr. Furnari,* proves useful in cases of inveterate pannus, in which a portion of the cornea is clear, so that it would not be safe to perform inoculation, or, if the latter is for some reason inapplicable, in cases of complete pannus. The object of the operation is to cut off the supply of blood from the cornea by a division and part removal, not only of the conjunctival but also of the subconjunctival vessels. It is a less dangerous and troublesome proceeding than inoculation. It must, however, be also admitted that it is not always successful, the cases improving perhaps somewhat at first, and then a relapse takes place.

Syndectomy is to be performed in the following manner:—The patient should be placed thoroughly under the influence of chloroform, as the operation is very painful and protracted, and the eyelids should be kept apart by the stop speculum. The operator then seizes with a pair of forceps a portion of the conjunctiva and subconjunctival tissue, near the cornea, so as to fix the eye steadily. He next with a pair of curved scissors makes a circular incision through the conjunctiva, all round the cornea, and about an eighth of an inch from the edge of the latter, and parallel to it. This circular band is then prepared off, and excised close to the edge of the cornea, so that a wide circle of conjunctiva may be removed all round the cornea. For the purpose of more easily rotating the eye, two small portions of conjunctiva should be left standing near the cornea until the operation is completely finished, when they are to be snipped off. A circular portion of the subconjunctival tissue, corresponding to the wound in the conjunctiva, is next to be removed, quite close to the sclerotic, so as to bare the latter completely; if small portions of subconjunctival tissue remain adhering to it, they may be scraped off with the edge of a cataract or iridectomy knife. Some of the larger vessels upon the cornea may also be divided near its edge. Dr. Furnari advises that the exposed sclerotic should be cauterized with nitrate of silver. This is, however, a most dangerous proceeding, as it is but too likely to produce inflammation and sloughing of the sclerotic and cornea. Cold compresses should be

* "Gazette Medicale," 1862, No. 4, etc.; vide also an Article upon the subject by Mr. Bader, "Roy. Lond. Ophth. Hosp. Reports," iv, 22. This operation has received various names; at one time it was termed Circumcision of the cornea. It is now generally called either Syndectomy or Peritomy.

applied, until the symptoms of inflammatory reaction have subsided. These are, as a rule, but moderate, and the photophobia pain and lachrymation generally disappear in about 48 or 60 hours. It is wise to keep the patients in the hospital for a few days, so that, if severe inflammatory symptoms should supervene, they may be treated at once.

In those cases of inveterate pannus in which the latter is thick, very vascular, and covers the whole of the cornea, and in which, on account of the cicatricial changes in the conjunctiva, it is impossible to excite sufficient hyperæmia and swelling of the conjunctiva for the absorption of the granulation, it may be necessary to produce a purulent inflammation of the conjunctiva by the inoculation of pus, in order that, if possible, the granulations may be absorbed and the cornea cleared during the progress of the inflammation. This proceeding, which was first advocated by Piringer, has long been extensively and successfully practised in Belgium, where granulations are very common amongst the soldiers. In England it has also been very largely and successfully employed, more especially at the Royal London Ophthalmic Hospital, Moorfields, where Mr. Bader first introduced it. I have seen many admirable cures produced by it, and patients restored to the enjoyment of excellent sight (some being able to read No. 1 of Jäger) who had been suffering from so dense a pannus that they were unable even to count fingers. In many of these cases most other remedies had been tried without avail, and I know of no other treatment which would have restored their sight. The chief danger is, of course, that the purulent inflammation which is induced, should be so severe as to produce suppuration of the cornea and loss of the eye. But it is surprising what a degree of inflammation a very vascular and completely pannous cornea will bear with impunity, and be, perhaps, finally restored to almost normal transparency. It may be laid down as a rule, that the more vascular the cornea is, the less danger is there of its sloughing, for the numerous blood-vessels on its surface will maintain its vitality during the purulent inflammation. Inoculation is, therefore, much less safe where the vascularity of the cornea is but moderate, and is inadmissible if a portion of it remains transparent. Another danger of inoculation is, that the matter, instead of setting up purulent ophthalmia, may give rise to diphtheritic conjunctivitis. Happily this danger is but very slight in England, but we have seen that, in certain parts of the continent, more especially Berlin, this affection is but of too common occurrence, and that the mild forms of conjunctivitis often produce the most virulent form of diphtheritic ophthalmia. For this reason, it is there hardly safe to inoculate a case of pannus with even the mildest purulent matter, for we have no guarantee that it may not give rise to diphtheritis. Von Graefe has called especial attention to this fact, and has been obliged, in consideration of so great a risk,

to abandon almost entirely the employment of inoculation in the treatment of pannus. In England the occurrence of diphtheritis is extremely rare, and I have not seen a single case of inoculation in which it has ensued.

Many surgeons are still very much afraid of inoculation, but I think, when we consider how utterly hopeless most cases of severe chronic pannus are, that we are justified in strongly recommending the patient to run some slight degree of risk for the chance of obtaining a useful amount of sight. I do not, therefore, hesitate to employ it in cases of inveterate, complete, vascular pannus, in which the other remedies have been tried without avail, for in such we must admit that it is our last resource, and that no other chance of restoring the sight remains.

Care must, however, be taken in the choice of the purulent matter, and in regulating its strength according to the exigencies of the case. The more dense and vascular the pannus, the stronger may the matter be. The best and safest is that obtained from the eyes of an infant suffering from purulent ophthalmia, more especially if the disease is in its decline, and no affection of the cornea, or only a very slight one, exists. Yellow pus is more active and powerful than the whitish discharge, as is also that taken from the eye during the acute stage of the disease.

The matter from an eye suffering from inoculation is stronger than that from an infant, as its activity appears to be increased by the inoculation. Gonorrhœal matter is far too strong and dangerous. Even in the worst cases, I prefer the whitish discharge from an infant. Mr. Lawson, who has had very great experience in this subject of inoculation, has also very justly pointed out,* that in using gonorrhœal matter there is the risk of its being tainted by the syphilitic virus through a chancre perhaps existing in the urethra.

The mode of inoculation is as follows:—A drop of pus from the eye of an infant affected with purulent ophthalmia is to be placed with the tip of the finger (or a camel's hair brush) on the inside of the lower eyelid, and left there. Within 24 hours of the inoculation the eyelids generally begin to swell and become œdematous, often to a very considerable degree; this is accompanied by more or less irritability of the eye, photophobia, and lachrymation. In the course of three or four days all the symptoms of an acute purulent ophthalmia set in, together with a copious, thick, creamy discharge. The disease mostly runs its course in from three to four weeks, by the end of which time the cornea is generally much more clear, and the granulations diminished. This improvement, however, continues to increase for many weeks, or even

* "Roy. Lond. Ophth. Hosp. Reports," iv, p. 183.

months. No treatment is to be adopted for checking the course of the inflammation. After the second or third day the patient may be permitted to wipe away the discharge with a sponge or a bit of linen, so as to cleanse the eye. But however severe the inflammation may be, it must be allowed to run its course unchecked by the use of astringent or caustic lotions.

One eye should be inoculated at a time, the other being carefully closed by the hermetic collodion compress. This must be more especially done if this eye is sound. Indeed, in such case it may be a question whether the diseased eye should be inoculated at all, for fear that, through any mischance or carelessness, the healthy eye should become affected. In deciding this point, we must be chiefly guided by individual consideration. The compress should be removed every day, in order that the eye may be washed and cleansed, during which process, of course, the greatest care must be taken that no matter gets into it.

A very interesting and important fact has been pointed out by Mr. Lawson,* viz., that a preliminary syndectomy appears to render the inoculation a safer proceeding, for the conjunctiva and subconjunctival tissue having been removed from around the cornea, the intensity of the inflammation at this point is greatly diminished, and the cornea less apt to suffer. In cases, therefore, in which the pannus is not very vascular, or does not involve the whole of the cornea, and where, therefore, inoculation might prove dangerous, it would be advisable to precede it by a syndectomy, and then, when the eye has quite recovered from this, to employ inoculation.

8.—PHLYCTENULAR OPHTHALMIA.

The disease is generally ushered in by a feeling of heat and itching in the eyelids, and a watery and irritable condition of the eye. These symptoms of irritation increase until there may be a very considerable amount of photophobia, lachrymation, and pain in and around the eye (ciliary neuralgia). The latter, however, is never so severe when the phlyctenulæ are confined to the conjunctiva, as when they also invade the cornea. There is also more or less conjunctival and subconjunctival injection, the degree and extent of which vary with the intensity and extent of the disease. Sometimes the injection is only partial and confined to a certain portion of the ocular conjunctiva. We then notice a triangular, fan-like bundle of conjunctival vessels, extending from the retro-tarsal region towards the edge of the cornea. The base of the triangle is turned towards the palpebræ, and the apex is at the

* "Roy. Lond. Ophth. Hosp. Reports," iv, p. 185.

cornea. Beneath the conjunctival injection is observed a corresponding rosy zone of subconjunctival vessels. At this spot there is also generally a slight œdematous swelling of the conjunctiva (serous chemosis). At the apex of the triangle of vessels, one or more small herpetic vesicles or pustules make their appearance, which are semi-transparent, or of a yellowish-white colour, and about the size of a small millet seed. They are especially apt to occur at the outer side of the cornea, and are often symmetrical, being formed at the outer side of each eye. The epithelium which covers the phlyctenula is soon shed, leaving a small excoriation or ulcer, which gradually dwindles down and becomes completely absorbed. In other cases the ulcer increases somewhat in size and depth, and its contents become yellow and opaque; but after a time it is covered again by epithelium, and its contents then gradually undergo absorption. With the appearance of the phlyctenula the symptoms of irritation generally diminish, especially when the epithelium is shed and the contents of the vesicle escape. As the latter is being absorped the vascularity decreases, but at the same time the conjunctiva may become somewhat swollen, especially in the retro-tarsal region, and this is accompanied by a muco-purulent discharge; so that we have in fact a combination of catarrhal and phlyctenular ophthalmia. The affection may, however, from the outset have this mixed character.

If the phlyctenulæ are not confined to one portion of the ocular conjunctiva, but are scattered about on various parts of it, in perhaps considerable numbers, the vascularity is diffuse and well marked. The symptoms of irritation are more pronounced, and the ciliary neuralgia, lachrymation, and photophobia greater. The latter, indeed, is sometimes excessive in phlyctenular ophthalmia, more especially in scrofulous children, and is often quite disproportionate to the amount of the vesicles. The phlyctenulæ frequently form at the edge of the cornea, surrounding it like a row of beads, or they occur at the limbus conjunctivæ, lying partly on the cornea and partly on the conjunctiva. Very often the affection appears simultaneously on the conjunctiva and the cornea. The pustules sometimes increase considerably in size and depth, the inflammation extending to the subconjunctival tissue (episcleritis), and even perhaps to the superficial layers of the sclerotic. The corresponding portion of the conjunctiva and subconjunctival tissue are then often very vascular, and considerably thickened and swollen, so that the pustules appear situated upon a prominent base. The vascularity (especially of the subconjunctival tissue) is of a peculiar dusky, bluish-red tinge, which is very easily recognised. This form is extremely protracted and very prone to relapses, so that many months may elapse before it is cured. When the pustules are very numerous, it has been termed *pannus herpeticus*.

The *prognosis* of phlyctenular ophthalmia is generally very favourable, especially if the case is seen early; if the phlyctenulæ are few in number and limited to one portion of the conjunctiva; if the cornea is not affected, and there is no episcleritis. In favourable cases, the disease generally runs its course in from ten to fifteen days, and disappears without leaving any trace behind it. Very mild cases, in which only one or two small phlyctenulæ form near the edge of the cornea without much irritability or vascularity of the eye, may even be cured in five or six days, simply by a few insufflations of calomel, without any other treatment whatever. The chief source of trouble and annoyance is the great tendency to relapses. Perhaps just as the disease seems to be all but cured, fresh symptoms of irritation supervene, and a new crop of phlyctenulæ appear. If the disease then becomes complicated with episcleritis, its course may be very obstinate and protracted.

Phlyctenular ophthalmia occurs by far most frequently amongst children, especially those of a feeble, scrofulous habit, and of a highly nervous, excitable temperament. Stellwag is of opinion that local irritants acting upon the ciliary nerves may give rise to it; as, for instance, the premature and excessive use of strong astringent collyria in some ophthalmiæ, whilst the irritability of the eye is still very great. The irritation may also be propagated from other branches of the fifth to the ciliary nerves, as in cases of eczema, impetigo of the cheek, the mucous membrane of the nose, etc. Indeed, he thinks that the disease is of an herpetic nature, and hence terms it herpes conjunctivæ. Some of its varieties do not, however, bear any resemblance to herpes in their course.

The *treatment* must be especially directed to the following points: to diminish the irritability of the eye, to prevent any graver complications, to hasten the absorption of the phlyctenulæ, to prevent if possible the occurrence of a relapse, and to improve and strengthen the patient's general health.

If the photophobia is very considerable, a compress of charpie should be applied to the eye. This will prevent the constant friction of the lids against the eyeball, which greatly increases the irritability, and impedes the regeneration of the epithelial layer over the vesicle or ulcer. This point should be more especially attended to if the phlyctenulæ occur on the cornea, for then, as we shall see hereafter, if their epithelial covering is shed, the denuded nerve fibres of the cornea are exposed, and this often gives rise to great irritability of the eye, and the most intense photophobia, these symptoms often rapidly disappearing as soon as the phlyctenulæ are again covered by epithelium. In children the compress is especially useful, for it prevents their constantly rubbing the eyes with their hands, which greatly aggravates the irritability. Moreover the compress diminishes the lachrymation, soaks up the tears,

and thus prevents their flowing over the cheek, which often gives rise to excoriations and eczema of the lower eyelid and cheek. The compress should be changed every four or five hours, the eye washed with luke-warm water, and the crusts removed from the edges of the lids. If the latter are excoriated, a little simple cerate or weak nitrate of mercury ointment should be applied to them. The same remedies are to be applied to the nostrils if they are excoriated, or a small dossil of lint soaked in olive oil should be inserted into them. If there is much thick discharge from the nose, the inside of the nostril should be lightly touched with a finely pointed crayon of nitrate of silver. Liebreich* strongly recommends the "Eau de Labarraque" (a solution of soda impregnated with chlorine gas) for this purpose. If the lower lid and cheek are much excoriated and eczematous, a little violet powder should be dusted over the sores, or we may use the following powder—Zinc. Oxid. ʒj—ij Pulv. Amyl. ʒij. The following lotions will also be found very serviceable:—Plumb. Acetat. gr. x, Glycer. ʒii—ʒss., Aq. dist. ʒvj., to be applied three or four times daily. Instead of the Acetate of lead, Borax (ʒij) may be employed. Atropine drops must be applied three or four times a-day, but if they are found rather to increase than allay the irritability of the eye, a belladonna collyrium (Ext. Bellad. ʒss ad Aq. dist. ʒij) must be substituted for them. The compound Belladonna ointment should be rubbed over the corresponding half of the forehead three or four times daily, until a slight papular eruption is produced. When the symptoms of irritation have subsided, we must have recourse to the insufflation of calomel, and the application of the red precipitate ointment, two remedies which may be regarded as specifics for phlyctenular ophthalmia. Indeed the calomel often acts as a charm, frequently causing a well-marked phlyctenula together with the accompanying vascularity to disappear completely in the course of two or three days. It should not be applied whilst there is much vascularity, photophobia, or lachrymation, as it is apt to prove too irritating, but when these symptoms have subsided, it should be tried in very small quantity at first, so that we may feel our way. Its beneficial effect appears to be chemical, and not that of a simple mechanical irritant, for experiments made with other finely powdered substances (sugar, magnesia, etc.) proved ineffectual. It is supposed to act on the Meibomian glands, or on the epithelial cells of the conjunctiva. Donders has found that after its use some of the smaller conjunctival vessels appear to become obliterated.

The calomel should be finely powdered and perfectly dry, so that it does not form clots on the conjunctiva or cornea, for these would act as mechanical irritants. It should be applied with a small camel's

* "Klin. Mouatsbl.," 1864, p. 393.

hair brush, held lightly between the forefinger and thumb; and a slight quick fillip with the middle finger will readily jerk some of the powder into the eye. Care should be taken not to dust in too much, more especially at first, otherwise it may produce a good deal of irritation. It should be applied every day or every other day, according to the requirements of the case, but if the lids become much gummed together in the evening, it should be applied less frequently. It is an excellent remedy to prevent relapses, and should, therefore, be continued for eight or ten days after the disease is cured. I am in the habit of directing the patients to re-apply it at once, if they experience any renewed irritation in the eye, for its timely application will generally succeed in cutting short a renewed attack of the disease.

In children it is often very difficult to apply any remedy to the eye, on account of their great restlessness, or the intense spasm of the eyelids. In such cases, the head of the patient should be placed between the knees of the surgeon, who is to be seated; in this way it can be firmly and steadily fixed; an assistant seated on a chair opposite should hold the child's arms and legs. The surgeon should then open the eyelids with Desmarres' broad silver elevator, which will enable him to obtain a thorough view of the eyeball, and to apply any remedy. By adopting this plan much time and trouble will be saved, and the eye less irritated than by repeated ineffectual attempts to examine it.

The red precipitate ointment is also an excellent remedy. Although it has been long employed in ophthalmic practice, we are indebted to Pagenstecher for the more accurate indications as to its use, and for showing the advantage of employing it in considerably stronger doses than was formerly done. He has more lately substituted the yellow amorphous oxide of mercury for the red oxide, which is in the finest possible state of division, and, being entirely free from any crystalline form, does not adhere by any fine points to the conjunctiva.* He uses an ointment of very considerable strength, viz., half a drachm or one drachm of the yellow oxide of mercury, to an ounce of lard.† I have generally found that a much weaker ointment (gr. x—xxiv to the ounce) was equally beneficial, and caused less irritation. It should be applied once a day with a small brush to the inside of the eyelids, which, on being closed, will sweep off the ointment from the brush. After a few minutes it should be wiped off from the lids (between which it becomes exuded) with a piece of fine linen.

The ointment is especially indicated when the symptoms of severe irritation have subsided, but it may even be applied with advantage in the acute stage, if care be taken to remove it completely from the

* "Nassauer Corresp. Bl.," No. 10, 1858.

† An interesting and valuable paper, by Dr. Pagenstecher, on the use of this ointment will be found in the "Ophthalmic Review," vol. ii, 115.

conjunctival sac. It is also of great benefit in checking the tendency to relapses.

In cases in which the phlyctenular ophthalmia is accompanied by much swelling of the conjunctiva, and symptoms of catarrhal conjunctivitis, Von Graefe has found much benefit from chlorine water, as it diminishes the catarrhal symptoms, especially the swelling, without setting up too considerable a degree of irritation, which is the chief danger in employing the nitrate of silver or any strong astringents in these cases. It is also indicated in the prominent ulcers, accompanied by episcleritis, as it considerably hastens the formation of the epithelial covering over the ulcer. Some touch the latter with the point of a crayon of nitrate of silver, but this is not always free from risk, especially when the ulcer is situated near the cornea, and the chlorine water appears to act more beneficially.

It is not advisable to apply blisters to the temple, as the skin is often extremely irritable, and there is frequently a great tendency to eczema. Great attention should be paid to the constitutional treatment of the patient. He should be placed upon a nutritious and wholesome diet, and be allowed as much exercise in the open air as possible. Cleanliness should be strictly attended to, and cold bathing insisted upon if the patient is not too weak. Nothing is so injurious as to confine him in the dark on account of the photophobia, for in this way the eye will become so sensitive, that no light will be borne. Children are especially prone to seek the dark, burying their heads in their mother's lap, or in a sofa or bed in the corner of the room, and only the strictest injunctions will make them face the light. They should be gradually accustomed to it, their eyes being perhaps protected by a shade, or a pair of blue glasses. The compress bandage should only be applied if the photophobia and lachrymation are very intense, and should be left off when these symptoms of irritation have diminished.

The use of small doses of tartar emetic as a sedative is often found beneficial more especially if there is much photophobia. But care should be taken not to continue this remedy too long so as to debilitate and weaken the patient. The bowels should be kept well regulated, and an occasional purge of rhubarb and jalap, or calomel and jalap, should be given, prrticularly in children.

Tonics, more especially quinine, are of great benefit. This may be given in combination with steel, or also with cod liver oil. In infants and young children the liquor cinchonæ, or the vinum ferri should be administered.

The photophobia often proves very obstinate and intractable, but as a rule less so than when the cornea is also implicated. This spasm of the lids (blepharospasm) is a reflex neurosis, due to an irritation of the nerves of the conjunctiva and cornea, which produces hyperæsthesia of

the orbicularis muscle (*vide* blepharospasm). The photophobia dependent upon exposure of the denuded nerve fibres of the cornea, should, as has been recommended above, be treated by the application of a compress. As the health of the patient improves, and he becomes more and more accustomed to the light, the photophobia will generally disappear. In children it may be very advantageous to employ a remedy, which I first saw very successful in Von Graefe's hand, viz., the dipping their heads under water, as this breaks the circuit of reflex action by the intense fright of the child. This should, if necessary, be repeated several times, even at one sitting, until the child opens its eyes properly. I have often seen surprising results from this treatment, when all other remedies had failed. The head must, however, be well dipped under water, so that mouth, nose, and eyes are immersed, the child being kept in this position for a few seconds, which will effectually frighten it.

I have also obtained much benefit in severe blepharospasm from the subcutaneous injection of morphia in the region of the supra-orbital nerve. The division of this nerve will not be necessary in the photophobia accompanying phlyctenular ophthalmia.

9.—EXANTHEMATOUS OPHTHALMIÆ.

The eyes often become affected in measles and scarlatina. In the milder cases the conjunctiva becomes hyperæmic, and perhaps symptoms of catarrhal conjunctivitis supervene. Exceptionally, however, the inflammation may assume a more severe muco-purulent character, leading perhaps to perforating ulcers of the cornea, prolapse of the iris and anterior staphlyloma; this is more especially liable to occur in children of a weakly scrofulous diathesis. Not unfrequently the conjunctivitis presents the phlyctenular form, being accompanied by much photophobia, lachrymation, and general irritability of the eye. Extensive ulcers of the cornea or iritis are only of rare occurrence.

In the majority of cases the treatment need only be very simple. The eyes should be guarded against the light, be frequently washed, so that any discharge may be cleansed away, and if there is much hyperæmia, or any inflammation of the conjunctiva, or catarrhal ophthalmia, a mild astringent collyrium, of zinc, acetate of lead, or alum should be prescribed. If there is much photophobia and lachrymation together with phlyctenulæ on the conjunctiva or cornea, atropine or belladonna drops should be applied to the eye, and the compound belladonna ointment be rubbed in over the forehead. The general health should at the same time be attended to.

In small pox the eyes are apt to suffer in a far more dangerous manner, for the inflammation is not only more severe, but the variolous pustules may form on the lids, the conjunctiva, and even on the

cornea, leading to grave, and often very dangerous complications. Happily, since the introduction of vaccination, the variolous ophthalmia is far less dangerous than formerly, when it led but too frequently to destruction of the sight.

If a considerable number of pustules form on the eyelids, the swelling of the latter is often so great that it is impossible to open the eye. They are also apt to form at the very edge of the lid between the eyelashes, and often destroy the hair bulbs, thus producing perhaps permanent loss of the eyelashes (madarosis). If they are situated on the palpebral conjunctiva near the edge of the eyelid, they may obliterate the openings of the Meibomian glands, and cause a stoppage and alteration in their secretions; or the growth and arrangement of the lashes may become affected, and distichiasis or trichiasis be produced. If the pustules form on the limbus conjunctivæ, they are chiefly dangerous inasmuch as they may extend to the cornea. The very prevalent opinion that variolous pustules often form on the conjunctiva and the cornea, during the eruptive stage, has been distinctly denied by Drs. Gregory and Marson. The latter especially maintains most strongly that no pustules form on the eye. The conjunctival inflammation met with in small pox may assume the catarrhal, muco-purulent, or phlyctenular character. The latter is perhaps the most common. The eyelids and lachrymal apparatus are often affected, and this frequently gives rise to very obstinate and troublesome complications.

But the eye may become affected at a later stage of the disease, when the scales have fallen off from the pustules. Hence this has been termed by some writers, "secondary variolous ophthalmia." Mackenzie mentions that he has often seen both central abscess of the cornea and onyx at its lower edge produced, after the general eruption has completely gone. Although this generally occurs about the 12th day, he states that it may even take place five or six weeks after the patient has recovered from the primary disease. At first an infiltration of the cornea occurs, which generally soon passes over into an ulcer, and which, increasing in circumference and depth, may perforate the cornea, producing prolapse of the iris or partial staphyloma. If several of such infiltrations should coalesce, a large ulcer or abscess will be formed, giving rise to an extensive leucoma, even if the cornea do not perforate. Should the whole cornea be destroyed by suppuration, a complete staphyloma will be the result. Again, the inflammation may attack the other structures of the eye, and the latter be lost from panophthalmitis.

The treatment should be much the same as that recommended for the ophthalmia of measles and scarlatina. In order to prevent the formation of pustules on the eyelids, glycerine, olive oil, or unscented cold

cream should be freely rubbed over them three or four times daily. Mackenzie recommends that two or three leeches should be applied to the temples, or behind the ears. In the secondary variolous ophthalmia, he has found much benefit from tartar emetic, given so as to cause free vomiting and purging. The general health should be kept up by tonics, and the bowels properly attended to. If pustules form on the lids or conjunctiva, they should be pricked and emptied of their contents. If the cornea becomes implicated, and perforation is threatened, this must be treated according to the rules laid down in the treatment of ulcers of the cornea.

In erysipelas of the face, the conjunctiva is often affected, and this is accompanied by very great swelling of the eyelids. The cornea becomes but seldom implicated.

10.—XEROPHTHALMIA.

In this condition, the conjunctiva is thickened, dry, and of a dusky red colour, its epithelial surface being rough and scaly. If the affection exists to a considerable extent, both the palpebral and ocular conjunctiva assume a dirty, greyish-white appearance, and become rough, dry, and cuticular. This condition is due to atrophy of the conjunctiva, subconjunctival tissue, and even of the cartilage, all of which undergo cicatricial changes, the nature of which has been already mentioned under the head of granular ophthalmia. The secreting apparatus of the conjunctiva is more or less destroyed, and this membrane assumes more the character of the cutis. On account of this disturbance in the secretions of the eye, the latter appears dry, and the patient experiences a most annoying sensation of heat, dryness, and stiffness in the eyes. The puncta are generally much contracted, or even obliterated. The semilunar fold is also hardly apparent. There is, moreover, always more or less posterior symblepharon, so that the hollow in the retro-tarsal region is obliterated, and the palpebral conjunctiva passes abruptly on to the eyeball. Sometimes small frœna exist between the lid and the globe. During the movements of the eye the ocular conjunctiva is thrown into small concentric folds round the cornea. The latter is generally opaque, often very considerably so, the opacity assuming perhaps the character of pannus, and extending over the greater portion, or even the whole of the cornea. The surface of the cornea is generally rough and uneven, and its sensibility, as well as that of the conjunctiva, is greatly impaired, so that mechanical irritants, dust, dirt, foreign bodies, etc., are hardly felt, and excite little or no irritation.

Xerophthalmia is generally caused by long continued and severe inflammation of the conjunctiva, more especially by the chronic diffuse,

granular ophthalmia, which is so apt to give rise to extensive atrophy and cicatrices of the conjunctiva, and tarsal cartilage. It may also arise after diphtheritic conjunctivitis, or be produced by injuries to the conjunctiva, from strong acids, lime, &c., and the excessive and long continued use of strong caustics, more especially the nitrate of silver. In the latter case, we find not only that the palpebral and ocular conjunctiva have become dry and cuticular, but that they are very markedly discoloured, being of a dirty, olive-green tint, which is extremely unsightly.

Unhappily no treatment is of much avail. We can only endeavour to remedy the dryness of the eye, due to the absence of its normal secretions, by the frequent use of some bland fluid employed as a collyrium. I have found milk answer far better than any other, which has been also strongly recommended by Von Graefe. Benefit is also sometimes experienced from the use of glycerine, which was first proposed by Mr. Taylor. The effect of these applications is to soften and wash away the hardened epithelial scales, and sometimes perceptibly to clear the opacity of the cornea.

11.—PTERYGIUM.

This affection is due to an hypertrophy of the conjunctival and subconjunctival tissue, showing here and there tendinous or fibrillar expansions. The elevated portion of the conjunctiva is traversed by numerous blood-vessels, which run a horizontal course. If the vascularity is but slight, and the hypertrophy of the tissue but inconsiderable, it is termed *pterygium tenue*, whereas, if the thickening is extensive and the development of blood-vessels great, so that it looks like a well-marked red elevation—somewhat resembling a muscle—it is called *pterygium crassum*. It is always triangular or fan-like in shape, having its base, which is often very wide, turned towards the semi-lunar or retro-tarsal fold, and its apex towards the cornea. It sometimes passes close up to the edge of the latter and stops short just at the limbus conjunctivæ; in other cases it passes beyond this, and extends more or less on to the cornea, even reaching perhaps to the centre, but very seldom extending beyond the latter. Its apex is generally not very acute or pointed, but rather rounded off or indented. The portion situated on the cornea looks tendinous rather than vascular, or is made up of loose connective tissue like that on the sclerotic. It may be so superficial as to be readily shaved off, or it may extend deeper into the substance of the cornea, so that when it is removed an irregular hollow or furrow is left behind. The pterygium is mostly but loosely connected with the sclerotic and cornea, and with a pair of forceps it can readily be lifted up in a fold. But if the tendinous bands in its con-

junctival portion are considerable and dense, this laxity is a good deal impaired and the elevation is rather tense and stretched, thus impeding the movements of the eyeball to a certain extent, which gives rise to a sensation of tightness or dragging when the eye is moved. The pterygium is most frequently met with at the inner angle of the eye, corresponding to the situation of the internal rectus muscle. It is occasionally symmetrical in the two eyes. It is less frequently seen at the outer angle, and still less upwards or downwards. In some rare cases two or even more have occurred on the same eye. It occurs in adults, but is most frequently seen in persons beyond middle age, and very rarely in children.

The causes of pterygium are often somewhat obscure and uncertain, as its formation is generally very slow and gradual. There can be no doubt that long and constant exposure to heat, glare, wind, dust, and chemical irritants may produce it, by setting up a state of chronic irritation of the conjunctiva, which gradually leads to a thickening and hypertrophy of this membrane and the subconjunctival tissue. This occurs particularly in situations which are specially exposed to these influences, namely, at the inner and outer angle of the cornea, which lie in the palpebral aperture, and are unprotected by the lids. I have frequently met with this affection in persons who have long resided in hot climates, especially in several natives of the West Indies, and this agrees with the experience of other observers. Pterygium may also be produced by phlyctenular and even catarrhal ophthalmia.

Arlt* has, I think, offered by far the most reasonable and probable explanation of the formation of pterygium in many cases. He thinks that it is frequently produced in the following manner:—If a superficial ulcer or abrasion (due perhaps to some chemical or mechanical injury) exists at the very edge of the cornea, the conjunctiva near it, particularly if it be somewhat excoriated and relaxed, as is often the case in old people, falls against it, and becomes adherent to the ulcer, being at the same time dragged somewhat towards it. This is always accompanied by a certain degree of irritation and serous infiltration of the conjunctiva, which, on the serum becoming absorbed, causes a certain amount of contraction and dragging of the membrane. Should the external irritants continue to act upon the eye, we can easily understand how this condition is not only maintained but increased in extent, the conjunctiva being gradually more and more dragged upon and involved in the process. Hasner† has more lately pointed out that the connection between the conjunctiva and subconjunctival tissue at the limbus conjunctivæ is often relaxed, more especially in aged persons, and that this

* "Diseases of the Eye." 1855.

† "Clinical Observations," Prague, 1865.

forms a frequent predisposing cause of pterygium. A simple hypertrophy of the tissue may then suffice to draw up the neighbouring conjunctiva, but this will, of course, be much more likely to occur if an ulcer or excoriation is formed, for during the cicatrization the conjunctiva will be more or less dragged upon.

The pterygium is often but of slight extent and may increase but very slowly, remaining indeed almost stationary for a length of time, and without perhaps encroaching upon the cornea. In other cases its course is more rapid, and it may extend quite to the centre of the cornea, thus more or less affecting the sight and impairing the movements of the eye. Even if the pterygium is in such cases removed some opacity of the cornea will remain, so that it may be necessary to make an artificial pupil.

If the pterygium is but small, and is chiefly confined to the sclerotic, benefit is often derived from the application of astringent collyria, such as the sulphate of copper or zinc, the vinum opii, or even the nitrate of silver, more especially if there is any catarrhal ophthalmia. The application of the powdered acetate of lead (as recommended in granular ophthalmia) has also been advocated (Decondé). But if the disease is considerable, so that it annoys the patient during the movements of the eye, or if from its position on the cornea the sight is affected, these remedies will not suffice, and we must have recourse to operative treatment. Unfortunately this is not always so successful as we could desire, for if the pterygium encroaches much on the cornea, an extensive opacity will be left; and if the base of the pterygium is large the loss of substance will be considerable, and the resulting cicatrix will be dense, tendinous, and more or less prominent, giving rise to what has been termed "secondary pterygium," which may even necessitate a further operation. This is especially apt to occur if excision has been performed, and the wound has been made triangular in shape.

Numerous modes of operating for pterygium have been advocated, but I shall confine myself to the description of the three following, viz.: 1, Excision; 2, Transplantation; 3, Ligature. Of these I have found the transplantation the most successful.

1. Excision.—This operation is to be performed in the following manner:—The patient having been placed under the influence of chloroform, and the eyelids kept apart by the spring speculum, the operator seizes the pterygium with a pair of finely-toothed forceps, and raising it up, carefully abscises the corneal portion either with a cataract knife or a pair of curved scissors. When the pterygium has been removed from the cornea, its conjunctival portion is to be excised up to about $1\frac{1}{2}$ or 2 lines from the edge of the cornea. The lines of incision should run along the upper and lower edge of the pterygium for the desired extent, and should then be made to converge towards each other, so

that the wound may not assume a triangular but a rhomboidal shape. The hypertrophied tissue having been thoroughly removed, the edges of the conjunctival wound are to be accurately brought together by two or three fine sutures. As the edges of the incision are apt to be somewhat uneven and ragged from the irregular dragging of the conjunctiva into the pterygium, I have found it advantageous to pass the threads through the conjunctiva prior to the excision, so as to embrace the pterygium to the desired extent, and then to make the incisions within the line of the sutures, which will be a guide to the operator and enable him to render them more straight and even. The suggestion of making the wound rhomboidal instead of triangular is due to Arlt. The chief advantage of this is, that its edges can thus be made to fit more neatly and closely together, that it yields a more even and straighter line of adhesion, and that the tendency to the formation of a thick, prominent cicatrix is thus greatly diminished. Whereas, if the wound is made triangular, the angles of the base of the triangle become puckered and projecting when the edges are united by sutures, and the central portion of the base is apt to be drawn towards the cornea, thus increasing the tendency to a prominent cicatrix.

It is not necessary, nor indeed desirable, to remove the pterygium as far the semilunar or retro-tarsal fold, the extent mentioned above will generally suffice. Pagenstecher* does not excise the pterygium, but having separated it from the cornea and the sclerotic to the required extent, he simply turns it back, and brings the edges of the wound together by sutures. The pterygium soon shrinks, dwindles down, and gradually disappears altogether.

2. Transplantation, which is chiefly applicable when the pterygium is very large, was first introduced by Desmarres.† He abscises the pterygium from the cornea and sclerotic quite up to the base, and then turns it back towards the nose. He next makes an incision in the conjunctiva near and parallel to the lower edge of the cornea, and sufficiently large to receive the pterygium; the latter is then inserted into this incision and retained in this position by a few sutures.

The chief advantages of this proceeding are, that the conjunctiva is preserved, that the pterygium soon shrinks in its new situation, and that there is far less chance of recurrence than when excision is practised.

3. The ingenious operation by ligature was suggested by Szokalski.‡ A couple of small curved needles having been armed with the ends of a fine silk thread, the operator, lifting up the pterygium with a pair

* "Klinische Beobachtungen," 1861.

† "Maladies des Yeux," 2.

‡ "Arch. f. Physiol-Heilkunde," 1845, 2.

of forceps, inserts one needle at its upper edge, near the cornea, and passing it beneath the pterygium, brings it out at the lower edge (Fig. 6). The other needle is then passed in the same manner beneath the pterygium, near its base. The needles are then cut off, and the ligature will consequently be divided into three portions, viz., an outer, an inner, and a central one. The ends of the outer thread are then to be firmly tied, so as to tightly embrace this portion of the pterygium, then the ends of the outer thread are to be united, and, finally, the two ends of the central ligature, which lie at the lower edge of the pterygium, are to be firmly tied. The ends of the ligatures may be snipped off, or fastened to the cheek by strips of adhesive plaster. At the end of four days, the strangulated portion of the pterygium may generally be easily removed with a pair of forceps. The affection is said never to recur after this operation.

Fig. 6.

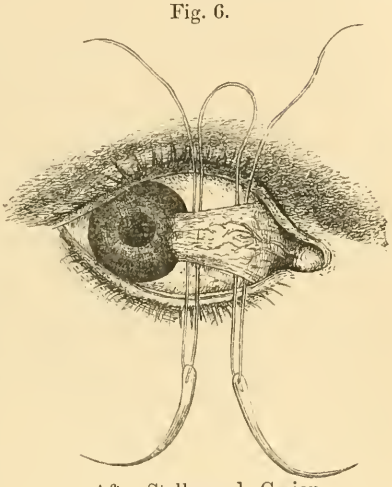

After Stellwag de Carion.

We must not confound a little yellow spot near the cornea (pinguecula or pterygium pingue) with true pterygium. It often appears on the conjunctiva of elderly persons, near the edge of the cornea, in the form of a small yellow elevation. It is not of a fatty nature, but is due to an hypertrophy of the subconjunctival tissue, accompanied by thickening of the epithelium (Weller). It but seldom causes any inconvenience; should it do so, it may be snipped off with a pair of scissors.

12.—SYMBLEPHARON.

In this affection there exists an adhesion between the conjunctiva of the eyelid and that of the eyeball. This frænum may be extensive, and nearly the whole length of the palpebral conjunctiva (of one or both lids) be adherent to the opposite surface of the globe, producing a considerable limitation of the movements of the eyeball; or, the adhesion may be very limited, so that only a narrow bridle exists. In the latter case, there may be simply a small bridge of conjunctiva passing from the lid to the eyeball, readily

permitting the passage of a probe beneath it; or, the adhesion may include a portion of the retro-tarsal fold, in which case no passage would exist. In some cases we have a combination of the two, the probe passing only part of the way. If the palpebral conjunctiva adheres to the cornea, it has been termed "symblepharon cum corneâ," and it then assumes somewhat the character and appearance of a pterygium. The most frequent causes of symblepharon are injuries from red hot metal, molten lead, gunpowder exploding near the eyes, strong acids, or quicklime. These produce more or less extensive sloughing and excoriation of the conjunctiva of the lid and eyeball, granulations form, and the opposite excoriated surfaces become firmly united. If these adhesions are but of limited extent, the constant movements of the eyeball will gradually stretch them, until the frœna become perhaps considerably elongated. Wounds penetrating through the eyelids into the globe may also produce symblepharon. It is but seldom due to ulcerations or pustules accompanying inflammation of the conjunctiva.

The effect which an operation will have in the cure of a symblepharon, will depend chiefly upon the extent of the latter. If it is very considerable, embracing the retro-tarsal fold, and producing a close adhesion between the lid and the eyeball, generally but little good can be done by an operation. The most favourable cases are those in which a narrow band passes like a bridge from the palpebral to the ocular conjunctiva, so that a probe can be freely inserted beneath it. But even those cases in which the adhesion passes to the retro-tarsal fold may sometimes be much improved if the frœnum is but small. If one or two narrow membranous bands exist, they should be put on the stretch and divided close to the globe, and re-union should, if possible, be prevented by frequently passing a probe dipped in a little oil or glycerine between the raw surfaces; or, these may be touched lightly with a crayon of nitrate of silver, in order that an eschar may be formed, and adhesion prevented.

When the adhesion is more extensive, a simple division of the frœnum will not suffice, for the raw surfaces will be so considerable in size, that they are sure to re-unite, for, as they contract during granulation, the opposing surfaces will be again drawn towards each other. Many of these cases appear to do very well at first, but, after a time, a relapse generally occurs, so that finally they are hardly, if at all, improved by the operation. In order to prevent this re-union of the raw surfaces, it has long been proposed to interpose a small shield of glass, horn, or ivory between the lid and eyeball. This has often been tried, but has almost always failed, except where the frœna are very narrow, for as the wound cicatrizes the parts in its vicinity

contract, and thus gradually push out the shield. Mr. Wordsworth* uses a glass mask, instead of a metal shield. It is a glass shell, like an artificial eye, having a central aperture for the cornea. He has found it very successful in the treatment of extensive frœna, and in cases of destruction of the epithelium of the conjunctiva, in which symblepharon was imminent.

In order to obviate this tendency to re-union, Arlt has introduced and practised with success the following operation.† The eyelid having been drawn away from the globe, so as to put the frœnum well on the stretch, the operator passes a curved needle, armed with a fine silk thread, through the symblepharon, close to the cornea, the adhesion is then to be carefully dissected off from the cornea and sclerotic as far as the retro-tarsal fold. Two curved needles having been armed with the thread, the symblepharon is doubled down, so as to bring its conjunctival surface in contact with the raw surface of the globe, and the needles are then passed through the thickness of the lid, close to the orbital edge, and the sutures tied on the outside of the lid, so as to keep the symblepharon folded down in the required position. If the frœnum is not very broad, the edges of the wound in the ocular conjunctiva should be brought together by two or three fine sutures. After the operation, cold compresses are to be applied. When the conjunctival wound is healed, the turned down symblepharon, which will by this time have shrunk considerably, may be excised if it should prove irksome to the patient.

The operation which I have found most successful for the permanent cure of moderate cases of symblepharon, is that of transplantation, for which we are indebted to Mr. Teale.‡ He describes the mode of operating, as follows:—

"Having first made an incision through the adherent lid, in a line corresponding to the *margin* of the concealed cornea (see A, Fig. 7), I dissected the lid from the eyeball, until the globe moved as freely as if

Fig. 7.

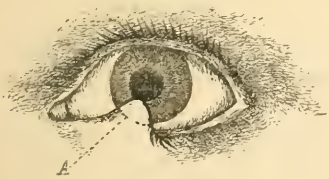

Fig. 8.

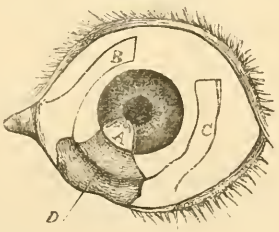

* "Roy. Lond. Ophthal. Hosp. Reports," vol. iii, 216.
† "Prager Vierteljahrschrift," xi, 161.
‡ "Roy. Lond. Ophthal. Hosp. Reports," iii, 253.

there had been no unnatural adhesions. Thus, the apex of the symblepharon (A, Fig. 8) being part of the skin of the lid, was left adherent to the cornea.

"In the next place, two flaps of conjunctiva were formed, one from the surface of the globe, near the inner extremity of the raw surface, the other from the surface of the globe, near the outer extremity. I first marked out, with a Beer's knife, a flap of conjunctiva (B, Fig. 8) nearly a quarter of an inch in breadth, and two thirds of an inch in length, with its base at the sound conjunctiva, bounding the inner extremity of the exposed raw surface, and its apex passing towards the upper surface of the eyeball. The flap was then carefully dissected from the globe, until it was so far at liberty as to stretch across the chasm without great tension, care being taken to leave a sufficient thickness of tissue near its base. A second flap was then made on the outside of the eyeball in the same manner. In making the flaps, conjunctiva alone was taken, the subconjunctival tissue not being included. The two flaps thus made were then adjusted in their new situation (see Fig. 9). The inner flap, B, was made to stretch across the raw surface of the eyelid, being fixed by its apex to the healthy conjunctiva, at the outer edge of the wound. The outer flap, C, was fixed across the raw surface of the eyeball, its apex being stitched to the conjunctiva near the base of the inner flap. Thus, the two flaps were dovetailed into the wound. The flaps having been adjusted in their new position, their vitality was further provided for by incising the conjunctiva near their base, in any direction in which there seemed to be undue tension, and by stitching together the margins of the gap whence the transplanted conjunctiva had been taken (*e.g.* D, E, Fig. 9). One or two other sutures were inserted, with a view to prevent doubling in of the edges of the transplanted conjunctiva." The apex of skin left on the cornea soon atrophies and disappears.

Fig. 9.

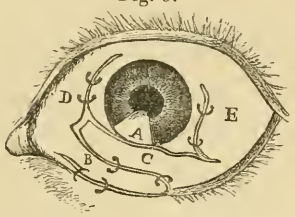

13.—ANCHYLOBLEPHARON.

By this is meant a more or less extensive thin, membranous or cicatricial adhesion of the edges of the eyelids to each other. It frequently co-exists with symblepharon, the same injury having given rise to both these conditions. Sometimes the adhesion is confined to the inner angle of the eye, leaving perhaps a small opening through which the tears can escape and a probe may be passed. Extensive

membranous adhesions between the edges of the lid are generally congenital. The most frequent causes of anchyloblepharon are chemical and mechanical injuries, such as burns or scalds from hot iron, molten lead, strong acids, &c. In these cases there is generally also symblepharon. Blepharitis, accompanied by ulcerations at the edge of the lids may produce it, if the ulcers are situated opposite to each other on the two lids, and kept for a long time in contact by the eye being bandaged (Stellwag).

Before an operation is attempted for the cure of anchyloblepharon, the surgeon should ascertain whether or not symblepharon co-exists, and if so, what is its extent, and whether it involves the cornea or not. For if the lid be widely adherent to the cornea, little or no benefit will accrue from an operation. If a small opening exists at the nasal side, or if the anchyloblepharon is but partial, a probe should be passed in underneath the lid, so as to ascertain whether any adhesions exist between it and the eyeball. If the adhesion between the eyelids is complete, the best way of determining this is to pinch the upper eyelid into a fold so as to draw it away from the globe, and then to order the patient to move his eye in different directions, when we can easily estimate the freedom of the movements. We should also examine what perception of light the patient still enjoys, in order, if possible, to ascertain whether the cornea and retina are healthy or not.

If the adhesion between the eyelids is not very considerable, consisting perhaps of one or more small bands, it should be simply divided close to the edge of the lid. In order to prevent re-adhesion of the surfaces, these should be touched with collodion (Haynes Walton). If the anchyloblepharon is complete, but a small opening exists near the nasal portion, a grooved director should be passed in through this, and run behind the adhesion, which is to be divided upon it with a scalpel. If no opening exists, the operator should at one point lift up the lids from the eyeball in a vertical fold, and divide the adhesion here, then introduce a director through this incision, and finish the operation with its aid.

14.—INJURIES OF THE CONJUNCTIVA.

These may be of a mechanical or chemical nature. The former may prove injurious by their contact with the conjunctiva, setting up irritation and inflammation, or from their wounding and lacerating this membrane. The foreign bodies most frequently met with on the conjunctiva are bits of steel, iron, glass, coal, straw, dust, etc., which may remain lodged on its surface, or become more or less deeply embedded in its structure. The presence of a foreign body in the eye generally

sets up at once severe symptoms of ciliary irritation. The eyelids are spasmodically contracted, the ocular conjunctiva becomes injected, and a bright rosy zone appears round the cornea; there is also much photophobia, lachrymation, and a feeling as of sand and grit in the eye or under the upper lid. Sometimes, the pain and ciliary neuralgia are considerable, and the pupil is markedly contracted. If the foreign body is small, and simply lies on the conjunctiva, the movements of the eyelids, the rubbing of the eye by the patient, and the copious lachrymation will often suffice to extrude it. If the surgeon suspects the presence of a foreign body, he must carefully and closely examine the surface of the palpebral conjunctiva of both lids, as well as the ocular conjunctiva and the cornea. The lower eyelid is to be depressed by the fore and middle finger so as to bring its inner surface, and especially the retro-tarsal fold, well into view, the patient being at the same time directed to look upwards.

The upper lid is next to be well everted, and its lining membrane thoroughly scanned, more particularly the retro-tarsal region, within the folds of which the foreign body often lies hidden, and may easily escape detection. Cases are narrated in which an undiscovered foreign body has set up a severe and obstinate ophthalmia. When found, the foreign body should be removed with the spud, which should be inserted beneath it, and gently lift it out. If it has got somewhat embedded in the conjunctiva, Mr. Haynes Walton's gouge will be found very serviceable. If the foreign body, more especially shot or small splinters of glass or steel, etc., are buried in the conjunctiva, their exact situation should be ascertained by lightly passing the finger over the surface of the conjunctiva, and they should then be excised with perhaps a small portion of the latter. Sometimes impalpable bits of dust or dirt get upon the conjunctiva and set up a good deal of irritation. The lids being well everted, a blunt probe should be passed over their lining membrane and behind the retro-tarsal fold, which will sweep off any such portions. The surface of the conjunctiva should then be washed by a stream of luke-warm water, directed upon it from a sponge or a syringe. If sand or grit has got into the eye it should also be washed away in this manner. After the removal of a foreign body a little castor or olive-oil should be dropped into the eye, and if there has been great irritation cold compresses should be applied to the lids.

Chemical injuries may produce a more or less extensive abrasion of the epithelium, or excoriation of the surface of the conjunctiva; if the injury was severe or the chemical agent very strong, a deep slough of this membrane may occur, which in cicatrizing, will cause a considerable contraction of the neighbouring tissues. Plastic lymph is effused and the opposite raw surfaces of the conjunctiva become closely adherent,

hence these injuries so frequently give rise to symblepharon and anchyloblepharon. Sometimes deep and obstinate ulcers are formed, the surface of which becomes covered with sprouting granulations.

Injuries from lime are unfortunately of very common occurrence, and are very dangerous in their nature, for this agent is very strongly irritant, producing not only destruction of the epithelium and the surface of the conjunctiva, but more or less deep and extensive sloughs of this membrane and of the cornea. It therefore frequently destroys the sight, or in more favourable cases gives rise to an extensive symblepharon. If the patient is seen at once, a weak solution of vinegar and water (ʒj, to ℥j of water), or of dilute acetic acid should be very freely injected under the lids; this will produce an innocuous acetate of lime. Then a few drops of olive or castor-oil should be applied to the eye so as to lubricate the surface of the conjunctiva, and the surgeon, everting both lids, should proceed to remove every particle of lime. This having been done, the eye should be well washed by letting a stream of luke-warm water from a sponge or syringe play upon the surface of the conjunctiva. A few drops of olive-oil should be applied three or four times a day. The eschars which form on the conjunctiva must be removed with a pair of forceps. If there is much conjunctivitis with a muco-purulent discharge, mild astringent collyria of sulphate of zinc, or nitrate of silver must be employed, or the eye may be frequently washed with a glycerine lotion (Glycerin ℥j ad. Aq. dest. ℥vij), a little being allowed to flow into the eye. But when the sloughs are detached, astringents should not be used, as they will excite too much irritation. Nor should they be used if the eye is very irritable and painful, and the cornea is affected. In such cases soothing applications are indicated, such as the belladonna-lotion, compound belladonna-ointment rubbed on the forehead, poppy fomentations, etc.

Strong acids, such as the sulphuric or nitric, produce extensive sloughing of the conjunctiva and cornea, accompanied by severe symptoms of irritation. Generally, however, the eyelids suffer the most, and the deep sloughs which may be produced, frequently give rise to entropion.

After an injury from strong acids, the eye should be syringed out with a weak solution of carbonate of soda or potass (ϑj to ℥iv—vi Aq. distill), in order to neutralize the acid. Afterwards olive-oil is to be dropped in.

15.—TUMOURS OF THE CONJUNCTIVA, ETC.

Polypi are occasionally met with in the conjunctiva, especially at the semilunar fold or caruncle. They appear in the form of small pink

lobulated elevations or excrescences, and have a distinct pedicle. Although they are generally small, they may reach the size of a hazel nut,* and protrude between the aperture of the lids. They may be readily snipped off with a pair of curved scissors, or a scalpel, but are apt to bleed rather freely. The hœmorrhage may, however, be easily arrested by a light touch with a crayon of nitrate of silver, which will, moreover, check the tendency to a recurrence of the disease.

Pingueculæ might be mistaken by a superficial observer for a slightly developed pterygium, as it is a small triangular elevation, situated generally close to the edge of the cornea, towards which its base is turned. It occurs at the outer or inner edge of the cornea, and is due to an hypertrophy of the conjunctival and subconjunctival tissue, as well as of the epithelial cells, but it does not contain any fat, as might have been suspected from its yellow tint. It is chiefly met with in old persons, and is due to a chronic irritation of the conjunctiva. It generally remains small and stationary, and produces no particular inconvenience or disfigurement. Should it, however, increase in size, or its appearance prove disagreeable to the patient, it may easily be excised.

Fatty tumours are of rare occurrence, and are most frequently observed on the ocular conjunctiva at some little distance from the cornea, and between the recti muscles, more especially the superior and external rectus in the vicinity of the lachrymal gland. They are often due to an hypertrophy and extension of the adipose tissue of the orbit. They appear in the form of smooth, yellow, lobulated, elastic tumours, and may reach a considerable size. They are mostly congenital, and do not become very noticeable, or increase greatly in size until a much later period. When they attain a considerable size they may push the eyeball aside, and by pressure impede the functions of the lachrymal gland.

If the tumour is inconsiderable in size, it may be easily removed, but care should be taken to preserve the conjunctiva as much as possible, and the incision should be closed by a fine suture.

Dermoid tumours are not of unfrequent occurrence. They are situated at the limbus conjunctivæ, partly on the cornea, and partly on the sclerotic, are of a pale, whitish-yellow colour, about one or two lines in diameter, and somewhat raised above the level of the cornea. The surface of the tumour is generally smooth, but it may be lobulated, and from it one or two short hairs may protrude. Wardrop† mentions an extraordinary case in which twelve very long hairs grew from the middle of the tumour, passed through between the eyelids, and hung over the cheeks; these hairs had not appeared till the patient was 16 years of age, at which time his beard also began to grow. The tumour is generally congenital, and almost completely stationary,

* Graefe, A. f. O. i, 1, 289.

† Wardrop's "Morbid Anatomy of the Human Eye."

increasing very slowly in size with the growth of the body. It may, however, become developed later in life, and augment considerably in size. The largest tumour of the kind that I have met with I saw in Von Graefe's clinique, in 1860. It extended over the outer two-thirds of the cornea, was prominent, lobulated, and very disfiguring, almost hiding the cornea. From their close analogy to the structure of the skin, these tumours have been called "dermoid." They sometimes, however, appear to consist only of elastic, fibrillar, connective tissue, rudiments of true skin, fat, hairs, and sebaceous follicles. Marked increase in their size, or recurrence after removal, appears to be due to an increase in their fatty constituents. They may be readily excised, but care must be taken not to endeavour to remove them thoroughly from the cornea, as they sometimes extend deeply into its structure.*

Warts are occasionally seen on the conjunctiva, forming small, red, flesh-coloured excrescences, being met with either singly, or in little clusters. They may occur on the palpebral or ocular conjunctiva, and also on the semi-lunar fold, and bear a strong resemblance to the warts upon the prepuce. They are generally accompanied by a certain degree of conjunctivitis, and a thin muco-purulent discharge. They should be at once snipped off with scissors before they attain any size, or have time to spread, and if necessary, the cut portion should be lightly touched with nitrate of silver.

Cysts of the conjunctiva may be readily distinguished by their circumscribed round form, and their pink, translucent appearance, the transparency of their contents being easily recognised with the oblique illumination. They may occur in different portions of the conjunctiva, and vary in size from a small pea to that of a hazel nut, or even exceed this. If they extend into the orbit, and attain a considerable size, they cause more or less protrusion of the eyeball. The walls of the smaller cysts are generally very thin, and only so slightly connected with the conjunctiva that they may be very readily removed.

Cysticerci have been found several times beneath the ocular conjunctiva, and in one instance (Sichel) beneath the palpebral. There is seen at some part of the ocular conjunctiva, near the angle of the eye, a transparent, cyst-like elevation, which is round, sharply defined, and somewhat moveable, and varies in size from a pea to a small bean. The conjunctiva over the cyst, and in its vicinity, is somewhat hyperæmic, but if it is sufficiently thin and transparent, we may be able to distinguish at the outer wall of the cyst a peculiar yellow or greyish-white spot, which is the head and neck of the entozoon, and Sichel† states that this appearance is quite characteristic.

* Vide Graefe's articles "On Dermoid Tumours," A. f. O. vii, 2, and xii, 2, 227.

† "Iconographie Ophthalmologique," p. 702.

Cancerous tumours are sometimes met with as primary affections, but far more frequently as secondary diseases, after cancer of the lids or the eyeball.

Epithelial cancer does not occur as a primary disease in the conjunctiva, but generally extends from the eyelids. It appears as a small, smooth, or slightly nodulated excrescence or button, at the edge of the cornea, and often bears a very striking resemblance to a pustule or phlyctenula. It may, however, be distinguished from the latter by the absence of all inflammatory chemosis and irritation, and arterial injection, only a few dilated tortuous veins converging towards the little tumour, together with a slight serous infiltration. Subsequently the tumour increases in size, and assumes a redder tint, and its surface becomes more nodulated (cauliflower excrescences), being covered by dry, thickened epithelium; or there may be a breach of surface, and a thin, muco-purulent discharge exude from the ulcer. The tumour may invade the cornea to a considerable extent, but is generally but slightly adherent to it, so that it may be nearly entirely removed. It may, however, produce a dense opacity of the cornea beyond the limits of the tumour, or lead to deep and extensive ulceration, or even perforation. If the tumour is stalked, it may be freely moveable upon the surface of the cornea. Like all cancerous tumours, it should be removed at the earliest possible period, and the edges of the conjunctival wound should be closed with fine sutures, in order that the sclerotic may not be exposed. It is, however, very apt quickly to recur, when the operation should be repeated without loss of time. But if the tumour has invaded the cornea to a considerable extent, is intimately connected with its tissue, and has greatly impaired the sight, it will be better to excise the eye; but even this does not always guard against recurrence, the new growth springing from the lids, or from the bottom of the orbit. In such cases it is, therefore, always advisable to apply the chloride of zinc paste to the orbit, after the removal of the lids.

Medullary cancer almost always extends to the conjunctiva from the lids or from the eyeball itself, the cornea or sclerotic giving way, and the tumour sprouting forth and very rapidly spreading thence into the neighbouring tissues.

Melanotic cancer appears in the form of a small darkish-red or brownish-black spot or tumour in the subconjunctival tissue near the cornea, or at the semilunar fold or caruncle. As it increases in size it may implicate the lids, extending beneath them and giving rise to more or less extensive adhesions. The tumour may remain stationary for a long period and then rapidly increase, and it is very prone quickly to recur after removal. It must be, however, remembered that many of the little black tumours which are often erroneously called melanotic cancer, are only sarcoma.

*Syphilitic ulcers** are sometimes met with on the conjunctiva, being almost always situated at the edge of the lid, and they bear a strong resemblance to a chancre upon the prepuce; in very rare instances they may occur at the edge of the cornea.† We shall enter more fully into their description when speaking of the syphilitic ulcers of the eyelids.

Nævi sometimes extend from the external portion of the eyelid to the palpebral or even ocular conjunctiva, and may reach a very considerable size if they are not treated at an early period. They may, however, occur primarily on the conjunctiva or the semi-lunar fold, and should be removed as early as possible.

Lithiasis is a term applied to a hardening or calcification of the secretion of the conjunctival glands, more especially the Meibomian glands. The affection appears in the form of white round concretions of the size of a pin's head, which may, however, attain a much larger size on the inner surface of the conjunctiva. They occur either singly, being scattered about over the surface of the lid, or they may appear arranged in single file along the tract of the ducts leading from the gland. The latter is, however, much more rare. On account of the roughness which they produce on the lid, considerable irritation and even a certain degree of conjunctivitis may be set up. The little calculi are easily removed by incising the conjunctiva over them, and lifting them out with the point of a cataract needle, or a grooved spatula. Sometimes the concretion is soft and semi-transparent, and appears at the opening of the duct, whence it may be readily pressed out.

The secretions of the caruncle also sometimes undergo cretification; chalky deposits are likewise met with in the caruncle, often giving rise to irritation and swelling.

Hæmorrhage into the conjunctiva is generally produced by blows or falls upon the eye or face, or by severe straining as in coughing, sneezing, etc., which cause a rupture of some of the minute blood-vessels of the conjunctiva. Such ecchymoses are also often met with in the course of inflammations of the conjunctiva, or in persons suffering from scurvy. In other cases they occur spontaneously without any apparent cause; I have met with several instances of this kind in which the ecchymosis had come on during the night. But the effusion of blood may not be due to a rupture of any of the conjunctival blood-vessels, but have gradually made its way forwards from the orbit beneath the conjunctiva. Thus a blow upon the skull may, by a contre-coup, produce a fracture of some portion of the walls of the orbit, this is followed by more or less severe hæmorrhage, and the effused blood may make its way forwards beneath the conjunctiva. The ecchymosis does not, however, in such cases appear directly after the accident, but only at an interval of several hours.

* "British Med. Journal," March 18, 1865. † Wecker, i, 177.

The ecchymoses are generally situated on the ocular portion of the conjunctiva in the vicinity of the cornea, or in the retro-tarsal fold. The effusion mostly gives rise to uniformly red patches, which vary in size and number, but it may be so considerable that it extends round the whole cornea.

The treatment should consist chiefly in the application of stimulating lotions, *e.g.*, Tr. Arnic ʒi., Aq dist. ʒiv., to be applied to the eye, or a compress moistened with this lotion should be firmly tied over the eye; indeed a firm compress bandage accelerates the absorption of blood more than any other remedy.

Œdema of the conjunctiva is met with very frequently in the course of many inflammations of the conjunctiva and inner tunics of the eye, but it may occur also spontaneously, more especially in elderly, feeble persons affected perhaps with disease of the kidney. The treatment should consist in the application of a firm bandage, and the use of mild astringent collyria. A few superficial incisions may be made in the chemosis with a pair of curved scissors. The health of the patient should be at the same time attended to.

Subconjunctival emphysema is caused by fracture of the nasal parietes which admits the air into the subconjunctival tissue, or by a rupture in the lachrymal sac; when the air is also admitted beneath the conjunctiva, if the nose is blown. The nature of the affection may be recognised by the peculiar crackling which is heard when the swelling is pressed with the finger; firm pressure will cause it to disappear. A bandage should be applied, and if necessary the swelling may be pricked with a needle and the air allowed to escape.

Chapter II.

DISEASES OF THE CORNEA.

1.—PANNUS.

This affection is characterised by a superficial vascular opacity of the cornea, occupying more or less of its expanse. The opacity generally commences at the periphery, and gradually extends towards the centre, but the reverse may also occur. It is due to the formation of a neo-plastic layer of cells beneath the epithelium, and also perhaps in the superficial layers of the cornea just beneath the anterior elastic lamina (membrane of Bowman). These neo-plastic cells show a tendency to become developed into connective tissue (Wedl), and blood-vessels appear amongst them. The blood-vessels are situated beneath the epithelium, and also somewhat deeper, beneath the anterior elastic lamina. On closer examination, they will be found to consist of two sets. The one is a direct continuation of the conjunctival vessels, and is almost entirely venous. It forms a large-meshed, tortuous network of vessels, covering a considerable portion, or perhaps even the whole of the cornea, which is seen to be opaque and hazy between the meshes. The other vessels, which are chiefly arterial, are straight and parallel, and lie beneath those from the conjunctiva. They proceed from the anastomosis between the conjunctival and subconjunctival vessels, at the limbus conjunctivæ, where it forms a bright rosy zone. If the vascularity is considerable, these parallel vessels are very numerous, and give a very red appearance to the edge of the cornea, which is often also somewhat swollen. When the cornea is extremely vascular and opaque, so that it assumes a very red or even fleshy appearance, the disease is termed "*pannus crassus*," whereas if the blood-vessels are few and scattered, and the cloudiness inconsiderable, it is called "*pannus tenuis*."

In the acute form of the disease, there is often considerable photophobia, lachrymation, and ciliary neuralgia, accompanied by marked conjunctival and subconjunctival injection. But if the affection runs a

very protracted and chronic course, the irritability of the eye is generally but slight, except if acute exacerbations occur. The surface of the cornea gradually becomes more opaque, rough, and irregular, and its epithelial layer hypertrophied and thickened, so that the cornea may finally assume almost a cuticular appearance. Or the epithelium may be shed at different points, giving rise to superficial facets and irregularities. But the loss of substance may extend much deeper, and extensive ulcers be formed, which may even lead to perforation of the cornea, and subsequently to anterior synechia, staphyloma, etc. After the pannus has existed for some time, the cornea is apt to become somewhat thinned, and yielding gradually to the intra-ocular pressure, lose its normal curvature, and become bulged forward. This fact is of great practical importance, for even although the cornea should hereafter regain much of its transparency, this faultiness in its curvature will produce considerable deterioration of vision.

Amongst the causes which may produce pannus, granular ophthalmia is by far the most frequent; in fact, in the vast majority of those cases in which the opacity is confined to the upper half of the cornea, it is due to granular lids. When speaking of granular ophthalmia, I mentioned that pannus might be produced by the friction of the roughened surface of the lid on the cornea, or by a direct extension of the granulations on to the ocular conjunctiva, and from thence on to the cornea. In the latter case, small grey or yellow infiltrations appear near the margin of the cornea, and if the attack be acute, may even extend over the whole of the cornea. Between these infiltrations blood-vessels are seen to be passing.

Phlyctenular or purulent ophthalmia may also give rise to pannus. In the former case, the opacity and vascularity are not considerable in extent, and the affection is chiefly characterised by the appearance of scattered phlyctenulæ, or small infiltrations on the surface of the cornea.

The disease may also be produced by the constant friction and irritation of the cornea, caused by inverted eyelashes, with or without entropion, by cretification of the Meibomian glands (chalazion), by the desiccation and exposure of the cornea to external irritants, as in cases of lagophthalmus, etc. In such cases the disease may be termed "traumatic pannus." In the chronic form, pannus may exist for many years without undergoing any particular change, except perhaps thinning and prominence of the cornea. Inflammatory exacerbations may, however, occur again and again, and each time leave the sight and the opacity of the cornea in a worse condition.

The prognosis is favourable in proportion as the pannus is inconsiderable and of recent origin, and the cause remediable. In very chronic cases, especially of the pannus crassus, the disease, even if

eventually cured, generally leaves behind it extensive and dense opacities. If there is a central leucoma, or if iritis has occurred during the progress of the disease, and the pupil is closed, it will be necessary to perform iridectomy.

The treatment to be adopted must depend upon the cause, for if the latter can be cured, the pannus will also disappear. As I have already in the article upon granular ophthalmia entered very fully into the mode of treating pannus produced by that disease, I need not recur to this subject. In cases of traumatic pannus, our efforts must be at once directed to the removal of the cause, *e.g.*, the entropion, inverted lashes, chalazion, etc. The opacity of the cornea which may remain after the disappearance of the original disease, must be treated by mild local irritants, amongst which may be especially recommended insufflation of calomel, the application of the red or yellow precipitate ointment, vinum opii, oil of turpentine, sulphate of copper, etc. These applications hasten the absorption of the morbid products, by producing a temporary inflammatory congestion of the blood-vessels.

2.—PHLYCTENULAR CORNEITIS (HERPES CORNEÆ).

This disease often accompanies phlyctenular ophthalmia. In fact the two affections are alike in character, and demand a very similar mode of treatment.

As in phlyctenular ophthalmia, the appearance of the vesicles on the cornea is generally preceded by a sensation of heat and itching in the eyelids, which is soon followed by conjunctival and sub-conjunctival injection, photophobia, lachrymation, and ciliary neuralgia. The latter, which is often but slight when the affection is confined to the conjunctiva, is frequently very severe in herpes corneæ. The same is the case with the photophobia, which is often most intense and persistent. The characteristic little phlyctenulæ soon make their appearance on the surface of the cornea. Their number and mode of distribution vary greatly. Sometimes, there are but one or two near the margin of the cornea, in other cases they are more numerous, and are either scattered freely over the surface of the cornea, or are chiefly confined to one part. Or again, they may be ranged along its edge in single file, surrounding a more or less considerable portion of the cornea like a string of beads. If the phlyctenulæ are numerous, and extend over a considerable expanse of the cornea (pannus scrofulosus), the vascularity is general, and the cornea is surrounded by a bright, rosy zone of vessels; whereas, if the pustules are confined to one portion of the cornea, the injection is generally also partial. Sometimes, the phlyctenulæ are very superficial, and appear in the form of small, transparent vesicles or blisters, whose

epithelial covering is soon shed, leaving a small excoriation, which may easily escape detection, and lead to an erroneous diagnosis and mode of treatment. Generally, however, the phlyctenula is more apparent, and is imbedded in the cornea, its summit rising slightly above the surface. It appears in the form of a small, circumscribed, grey infiltration, surrounded by a zone of slightly opaque and swollen cornea, the latter being especially the case if several phlyctenulæ are situated close together. At its apex a little transparent vesicle often forms, which bursts and leaves an excoriated surface, the bottom of which is opaque, and of a grey or greyish-yellow colour. This excoriation may gradually extend somewhat in circumference and depth, and assume the character of a small ulcer. This is especially apt to occur if the phlyctenula is situated near the centre of the cornea, and the affection has been injudiciously treated by strong astringents. If no transparent vesicle forms at the apex of the phlyctenula, this becomes somewhat more opaque and infiltrated, and then, losing its epithelial covering, becomes changed into a superficial yellowish grey ulcer. These ulcers generally run a very favourable course if they are judiciously treated, and show little or no tendency to extend much either in circumference or depth. The ulcer becomes covered by a layer of epithelium, and gradually fills up, and the cornea regains more or less of its transparency. But if the infiltrations are situated very close to each other, two or three may coalesce, and thus give rise to one extensive ulcer, which may increase in depth, and even lead to perforation. This may also occur if the infiltrations are situated somewhat deeply in the cornea, and if strong local irritants (nitrate of silver, sulphate of copper, etc.) are employed. In the majority of cases there is no fear of this complication, for under judicious treatment the excoriations or little ulcers soon fill up, the corneal substance is regenerated, and perhaps no opacity is finally left. In other cases the result is not so favourable, for a more or less dense opacity may remain behind.

There is a great tendency to relapses. Just as the symptoms of irritation and vascularity are subsiding, the phlyctenulæ disappearing, and the disease seems to be almost cured, all the acute symptoms of irritation return, a fresh crop of pustules makes its appearance, and a severe relapse takes place. This may occur again and again, and the affection gradually assume a chronic character; vessels are developed upon the cornea, which run towards the infiltration, and this condition might be mistaken by a superficial observer for that of fascicular corneitis. On closer examination it will, however, be seen that the blood-vessels are few in number, and more scattered, do not rise prominently above the surface of the cornea, and do not push along the infiltration before them, but rather stop short of it. When numerous phlyctenulæ are crowded together on the cornea, and interspersed with

blood-vessels, it is often termed herpetic or scrofulous pannus, more especially if they are situated in the upper half of the cornea.

The *causes* which may produce this affection are the same as those which give rise to phlyctenular ophthalmia, and it also occurs most frequently amongst children and young persons of a weakly, scrofulous constitution, and nervous, excitable temperament.

The *treatment* should also be similar to that which was recommended for phlyctenular ophthalmia. I must here lay the greatest stress upon the necessity of avoiding the use of caustics, more especially the nitrate of silver, for this greatly increases the irritability of the eye, aggravates the character of the disease, and augments any tendency to necrosis and breaking down of the corneal tissue. It may also cause the inflammation to extend to the iris and ciliary body. Indeed it may be laid down as a rule, that in all affections of the cornea, except those of a very chronic character, the use of caustics should be most strictly avoided. In phlyctenular corneitis our chief endeavour must be to diminish the great irritability of the eye, to prevent the extension of the phlyctenulæ or ulcers, and to facilitate and assist the regeneration of the corneal tissue. The agent which we shall find of the greatest service for these purposes is atropine. Indeed this remedy is invaluable in the treatment of affections of the cornea and iris. It exerts a beneficial influence upon the cornea, by acting as a local anæsthetic during its passage through the cornea into the aqueous humour, thus greatly diminishing the irritability of the cornea and of the ciliary nerves. This is often witnessed when a drop of atropine is applied to an eye affected with acute corneitis, accompanied by intense symptoms of irritation; for if such an eye is examined half-an-hour after the application of the atropine, we find a very marked diminution in all these symptoms; the patient expressing himself greatly relieved. The atropine also acts by decreasing the intra-ocular tension, and thus relieving the cornea of a certain degree of pressure; hence its nutrition and the regeneration of its substance are greatly facilitated. This diminution in the intra-ocular tension is of special advantage in deep ulcers of the cornea, as will be readily understood when we remember that the thinnest portion of the cornea (the bottom of the ulcer) has to sustain the same degree of intra-ocular pressure as the healthy part.* The

* I must, however, strongly insist upon the absolute necessity of the solution of atropine being quite pure, and perfectly free from any admixture of strong acid or spirits of wine. A few drops of strong sulphuric acid are sometimes added by chemists when the sulphate of atropine is not quite neutral, and therefore imperfectly soluble. I have met with several instances in which a pure solution of atropine proved of the greatest benefit in allaying the irritability of the eye and in alleviating the inflammation, and in which a fresh supply of atropine (made up after the same prescription, but obtained from a different chemist) has at once set up severe irritation of the eye, accompanied by considerable pain, redness, lachryma-

solution of atropine (gr. ij. ad ℥j of water) should be applied to the eye three or four times a day. If it should, after a time, be found rather to increase than alleviate the irritation, a collyrium of belladonna must be substituted. If it has already produced considerable irritation of the conjunctiva, and a crop of vesicular granulations, an astringent collyrium of alum, borax, or nitrate of silver (gr. j. ad ℥j) should be employed. The compound belladonna is to be rubbed on the forehead three or four times daily, until a slight papular eruption is produced. If there is much pain in and around the eye, and more especially if the latter is very painful to the touch, much relief is often experienced from the application of two or three leeches to the temple, or a blister may be applied behind the ear. If, together with the photophobia and lachrymation, the temperature of the lid is much increased, I have often found very marked benefit from the periodical application of cold compresses. These are to be applied three or four times a day, for a space of 20 or 30 minutes, and are to be changed every two or three minutes, as soon as they get the least warm. The photophobia is often, however, very obstinate and intractable. When it is chiefly due to an abrasion of the epithelium and exposure of the corneal nerves, a compress bandage should be applied. But sometimes it resists all remedies, and a severe spasm of the lids (blepharospasm) remains even after the affection of the cornea is cured. In such cases the different remedies which I have mentioned in the article on phlyctenular ophthalmia, should be tried, viz., subcutaneous injection of morphia, immersion of the face in cold water, and if all these fail, and the spasm is arrested by pressure upon the supra-orbital nerve, we must have recourse to a division of this nerve. I have often found that a prolonged stay at the sea-side, together with sea-bathing, tonics, a generous diet, and plenty of out-of-door exercise, will cure cases of photophobia, which have obstinately resisted all other remedies.

tion, etc., but these symptoms soon disappeared again on the use of a *pure* solution of atropine. On examination, the impure solution was found to contain a small quantity of strong sulphuric acid. Such cases as this completely disprove the theory that a small quantity of strong acid or of alcohol can have no prejudicial effect upon the eye, even although there may be much ciliary irritation and a severe inflammation of the cornea or iris. I must state, however, that we occasionally meet with exceptional cases, in which there exists a peculiar idiosyncrasy which renders the patient most intolerant of the use of even a weak and perfectly pure solution of atropine. I have seen instances in which a drop of a weak and quite pure solution of atropine has produced great irritation and pain, or even an erysipelatous condition of the eyelids and cheek accompanied by redness and chemotic swelling of the conjunctiva. This is, however, a very exceptional occurrence, and bears not the least analogy to those cases in which the irritation is caused by the impurity of the atropine, for in such cases a pure solution of atropine is not only well borne, but greatly alleviates the ciliary irritation and the inflammatory symptoms. Mr. Lawson also mentions some interesting instances of this peculiar idiosyncrasy, in a paper in the "R. L. O. H. Reports," vi, 119.

Small doses of tartar emetic sometimes prove useful in alleviating the photophobia and ciliary irritation during the acute stage of the disease. But this remedy should not be persisted in if it does not produce any benefit in the course of a few days, as its prolonged use is apt to weaken and debilitate the patient. Arsenic has also been strongly recommended in this form of corneitis on the supposition of its similarity to eczema. This remedy often proves very serviceable, especially if the corneitis is accompanied by an eczematous eruption of the forehead and face. In the latter case the lotion of acetate of lead and glycerine (p. 67) should be applied to the face. The patient's general health should be attended to, and if he is of a weakly and scrofulous habit, tonics, cod-liver oil, and a nutritious and generous diet, together with the use of ale and wine, should be prescribed. The bowels should be kept well regulated, and special attention should be paid to the free action of the skin, as this exerts a marked influence upon the symptoms of ciliary irritation, especially the photophobia. When the acute symptoms have subsided, we must have recourse to the insufflation of calomel, and if this is well borne the yellow oxide of mercury ointment (gr. iv—viii, ad adip ʒj) should be applied; this will not only hasten the absorption of any remaining opacity, but check the tendency to relapses. In chronic and very obstinate cases, especially if they are accompanied by much vascularity of the cornea, great benefit is often experienced from a seton.

In rare instances we meet with a peculiar formation of transparent vesicles upon the surface of the cornea, which are produced by slight elevations of the epithelial layer and the anterior elastic lamina from the surface of the cornea proper. The appearance presented by these little blisters is very characteristic, and is generally accompanied by very severe symptoms of irritation, especially photophobia and lachrymation. These symptoms subside when the vesicles burst, but a fresh crop of the latter is generally formed every three or four days. In a case mentioned by Mooren the disease assumed the character of a regular tertian type, and was cured by the energetic use of quinine; indeed this remedy, combined perhaps with steel, should be given in all cases; atropine and a compress bandage being applied to the eye.

3.—FASCICULAR CORNEITIS.

This peculiar form of corneitis, which is very common in Germany, is extremely rare in England, for whilst I saw many instances of it in Berlin, I only remember having met with four pure cases in England during the last eight years.

The symptoms of this affection are very characteristic and easily recognised. The attack is generally ushered in by considerable photophobia, lachrymation, and ciliary neuralgia. On examining the eye, the ocular conjunctiva is found to be injected, and there is also seen a bright rosy zone of subconjunctival vessels around the cornea. Near the edge of the latter, may perhaps be noticed at one spot a few small phlyctenulæ, and the limbus conjunctivæ is at this point also somewhat swollen. The parallel subconjunctival vessels are seen at this spot to pass on to the cornea and extend more or less on to its surface, forming a narrow bundle or leash of vessels (hence the term "fascicular" corneitis), which lies in a somewhat swollen and elevated portion of the cornea. This fasciculus of vessels consists both of veins and arteries; at its apex, and rising somewhat above the level of the vessels, is noticed a small, crescentic, yellowish-grey infiltration, surrounded by a somewhat opaque and swollen portion of cornea. As the disease progresses, the infiltration is gradually pushed further and further on to the cornea in front of the vessels; its epithelial covering is shed, it assumes a yellowish tint and becomes changed into a small superficial ulcer. In some instances the original leash of vessels may bifurcate, so that it assumes a Y shape, having a separate infiltration at each apex. The disease may extend far on to the cornea, and prove dangerous from its leaving a dense opacity in the centre of the cornea just over the pupil, but the ulcer generally remains superficial, and does not extend very deeply into the cornea or lead to perforation. During the progressive stage, the symptoms of irritation are very marked and obstinate. When the disease has reached its acme, it generally remains stationary for some little time (perhaps even several weeks) and then gradually diminishes in intensity and slowly retrogrades, the symptoms of irritation rapidly disappearing. The time which elapses during these several stages, will depend upon the size of the fasciculus of vessels and of the infiltration. The vascularity gradually diminishes, the ulcer is again covered by a layer of epithelium and begins to fill up from the periphery towards the centre; the corneal tissue is more or less regenerated, and after a time but little opacity may be left.

This disease is generally due to the same causes as phlyctenular ophthalmia, and is most frequently met with in weakly and scrofulous persons, and in them it is very apt to run a most protracted course.

If the symptoms of irritation are very acute only soothing remedies should be applied. Atropine should be dropped into the eye, the compound belladonna ointment should be rubbed in over the forehead, a blister should be applied behind the ear, and a leech or two to the temple if the eye is very painful to the touch. If the vascularity is very marked and the case severe, benefit is often derived from dividing the bundle of vessels close to the cornea either with a

small scalpel or a pair of curved scissors; after this has been done, the blood-vessels on the cornea and the infiltration are found to shrink and diminish in size. When the acute symptoms of irritation have considerably subsided, the insufflation of calomel should be at once commenced, or the yellow oxide of mercury ointment (gr. ij—viii ad ℥j) should be applied. Both these remedies, but more especially the yellow oxide, are almost specifics for this disease. The ointment may be applied from the very commencement, if the symptoms of irritation are not very marked; it must, however, be used with care, and its effect should be closely watched. If we find the next day that it has excited considerable redness and irritation, its use should be temporarily abstained from, and calomel should be substituted. It is also of much use in checking the tendency to relapses, in cutting these short, and in hastening the absorption of the corneal opacity. Frequently, we must ring the changes between the ointment and the calomel, as after a time they temporarily lose some of their effect.

A seton at the temple sometimes also proves of much benefit in this affection, not only in shortening the course of the disease, but also in preventing the occurrence of relapses.

4.—SUPPURATIVE CORNEITIS.

Practically it is of importance to distinguish two principal forms of suppurative corneitis. The one is accompanied by more or less marked inflammatory symptoms, whilst in the other these are entirely absent, and the chief danger of the disease is found in their absence, as the suppuration spreads very rapidly and an extensive abscess or slough of the cornea speedily ensues. These two forms also demand a totally opposite plan of treatment. In the inflammatory, we must endeavour to check and subdue the symptoms of irritation and inflammation by local antiphlogistics; whereas in the torpid, non-inflammatory form, we must most carefully eschew such treatment, and at once attempt to produce a certain degree of inflammation, in order to check the tendency to necrosis and purulent infiltration.

Whilst drawing special attention to these two opposite types of the disease, I must state that in practice we constantly meet with mixed forms, showing some of the symptoms of each type. Indeed the surgeon will chiefly display his skill and judgment, by distinguishing whether any of the symptoms have attained an undue prominence and require to be checked, in order that a just balance may be maintained between the necessary degree of inflammation and the suppurative condition of the cornea; so that whilst on the one hand, the inflammatory symptoms are not allowed to become excessive, they are, on the other, not too much suppressed.

The inflammatory suppurative corneitis is often accompanied by great photophobia, lachrymation, and intense ciliary neuralgia; there is also much conjunctival and subconjunctival injection, the cornea being surrounded by a bright rosy zone, accompanied perhaps by some chemosis. On account of the irritation of the ciliary nerves, the pupil is often greatly contracted. On examining the cornea we notice a small circumscribed infiltration, which is generally situated near the centre, but sometimes at the periphery of the cornea. Its position varies, sometimes it is situated in the superficial layers of the cornea, and then the latter may become somewhat raised above the level at this point, or it may lie in the central or deeper portion of the cornea, in which case the surface remains unaltered. The infiltration soon increases in density and assumes a creamy yellowish-grey colour, being surrounded by a well marked line of demarcation in the form of a light grey zone, which gradually shades off into the transparent cornea; the latter also shows a certain degree of inflammatory swelling at the point occupied by this zone. The epithelium may be shed, and a portion of the contents of the infiltration break down and be thrown off, so that a more or less deep ulcer is formed. Although the subconjunctival vessels may pass slightly on to the cornea, they never reach the ulcer, even when this is situated near the periphery. When it is in the centre of the cornea, the latter appears quite free from blood-vessels, except a few which may just pass over its margin. The retrogressive stage generally soon sets in, the infiltration changes its yellow hue for a light grey tint, and becomes gradually absorbed, leaving perhaps hardly any opacity behind. The disease as a rule shows a tendency to remain localised, and not to extend superficially, but rather in depth. Relapses are apt to occur and the affection may thus assume a chronic character.

But the disease does not always run so favourable a course. Thus, several superficial infiltrations may be formed close to each other, and gradually extending in circumference and depth, may coalesce and thus give rise to a considerable abscess of the cornea. Their contents undergo suppurative and fatty degeneration, the cells and nuclei break down, the infiltration assumes a yellow colour, surrounded, however, by a greyish-white zone of demarcation. If this occurs near the centre of the cornea, it may prove dangerous from its leaving a dense opacity just over the pupil, or from its perhaps leading to an extensive slough of the cornea. Again, if the infiltration is situated deeply in the cornea, it may lead to perforation of the latter, or give rise to onyx, hypopyon, and iritis. The pus may sink down between the lamellæ of the cornea to its lower margin, and thus give rise to a peculiar opacity, termed onyx or unguis, on account of its supposed resemblance to the white lunula of the finger-nail. If the onyx is but small, and confined to the very edge of the cornea, it may easily be overlooked, more

especially if it be somewhat covered by the swollen limbus conjunctivæ. If it is more considerable, so that it reaches nearly up to one-third of the cornea, or even higher, it may be mistaken for an hypopyon. But on careful examination (more especially with the oblique illumination) it will not be difficult to distinguish it from the latter, for it will be seen to lie on the corneal side of the anterior chamber, a portion of transparent cornea perhaps dividing it from the latter, and it is situated at some distance from the iris. But the differential diagnosis is of course more difficult if, as is sometimes the case, an hypopyon co-exists with the onyx.

The hypopyon which not unfrequently accompanies suppurative corneitis (more especially the non-inflammatory form) may be produced either from the iris or from the cornea in the following ways:—

1. An inflammation of the iris may supervene upon the corneitis, lymph be effused into the aqueous humour, and, falling to the bottom of the anterior chamber, thus produce an hypopyon.

2. The abscess may perforate the cornea, and its purulent contents be carried into the aqueous humour and be precipitated at the bottom of the anterior chamber. Sometimes such a mode of production of hypopyon is completely overlooked, from the fact that the communication between the anterior chamber and the abscess in the cornea is not large and direct, but is brought about by a small sloping canal, through which the contents of the abscess have made their way into the anterior chamber. Special attention has been called to this fact by Weber,* who has, moreover, frequently passed a minute probe from the ulcer through the canal into the anterior chamber, and thus verified the communication. With the oblique illumination, this little canal appears like a white streak, running from the abscess to the anterior chamber.

3. When the abscess is situated deeply in the cornea, near the membrane of Descemet, inflammatory proliferation and fatty degeneration of the epithelial cells, lining the posterior portion of the cornea, may occur. They are thrown off, and, mixing with the aqueous humour, render this turbid, and if these deposits are considerable in quantity, they may fall down to the bottom of the anterior chamber and thus produce an hypopyon. It has been also supposed that the latter is often due to a transudation of some of the contents of the deep-seated abscess into the aqueous humour.† Weber, however, asserts that he has never met with an instance in which the communication between the abscess and the anterior chamber could not be distinctly proved by means of probing. I have, however, met with cases of abscess in the middle portion of the cornea, which have been accompanied by an infiltration

* "A. f. O.," viii, 1, 322.

† Roser, ibid., ii, 2, 151.

situated at the membrane of Descemet, and an hypopyon evidently produced by the latter (for there was no iritis), and in which I have failed, on the most careful examination by the oblique illumination, to trace any communication between the abscess and the posterior infiltration.

Inflammatory suppurative corneitis is met with in severe and aggravated cases of phlyctenular corneitis, and also in severe cases of purulent, granular, and diphtheritic ophthalmia. It is very frequently caused by mechanical and chemical injuries, such as the lodgment of chips of steel, a bit of wheat ear, etc., in the substance of the cornea, which perhaps remain there undiscovered. This is especially the case in old or very feeble persons. It may also follow operations upon the eye, more particularly those for cataract.

In the milder cases of inflammatory suppurative corneitis, atropine should be applied three or four times daily, and the compress bandage employed. If there is much irritability and ciliary neuralgia, and if the eye is very painful to the touch, two or three leeches should be applied to the temple. Subcutaneous injections of morphia may also be employed with great advantage. If the abscess resists all treatment, great benefit is often derived from slightly opening it with the point of an extraction knife. But if it is deep seated, and threatens to perforate the cornea, paracentesis should be performed by passing a fine needle into the anterior chamber through the bottom of the abscess. If a considerable hypopyon exists paracentesis should also be performed, but with a broad needle, the object of this operation being not so much to remove the lymph from the anterior chamber as to diminish the intra-ocular pressure, and thus to arrest the progress of the disease, to hasten the absorption of the infiltration, and facilitate the regeneration of the corneal tissue. This operation may have to be repeated several times (vide treatment of ulcers of the cornea by paracentesis). In order to diminish the intra-ocular pressure still more completely, and more effectually to subdue the inflammation, it may be very advisable to perform iridectomy in cases in which suppurative corneitis is extensive, threatens perforation, and is accompanied by hypopyon. This is more especially the case if the abscess is deep, and situated in the centre of the cornea, for even if it should not perforate, it will leave a dense leucoma, which will subsequently necessitate the formation of an artificial pupil. It is, therefore, much wiser to make an iridectomy at once, as this will exert a beneficial influence upon the course of the disease, and leave an artificial pupil opposite a clear portion of the cornea.

5.—NON-INFLAMMATORY SUPPURATIVE CORNEITIS.

In this disease there is generally a very marked absence of all the usual symptoms of irritation and inflammation. There is no photophobia, lachrymation, or pain, and the eye appears, in fact, abnormally insensible to external irritation (bright light, etc.) It may, however, supervene upon a circumscribed infiltration of the cornea, accompanied by severe symptoms of irritation and intense ciliary neuralgia. These symptoms suddenly yield, and the abscess shows a tendency to necrosis, extending quickly in circumference and depth. There is formed very rapidly, often in the course of a few hours, in the centre of the cornea, a small yellow spot, which is sharply defined against the clear and transparent cornea, and is not surrounded by an opaque grey zone, as is the case with the inflammatory infiltration. Indeed, the adjoining portion of cornea may even appear abnormally lustrous, which is probably due to serous infiltration. The yellow colour is also more deep and pronounced than in the inflammatory infiltration. The disease rapidly extends in circumference, and consecutive yellow layers are formed around the original infiltration. The tissue of the cornea becomes quickly broken down, undergoes fatty degeneration, and pus cells are formed in large quantity, and the abscess soon gains a considerable extent, both on the surface and in depth, reaching, perhaps, nearly to the membrane of Descemet. When the suppuration has attained a certain depth, the epithelial cells lining the membrane of Descemet undergo inflammatory proliferation, and being thrown off mix with the aqueous humour, rendering this turbid, and perhaps sinking down in the anterior chamber in the form of an hypopyon. The iris becomes swollen, hyperæmic, and of a yellowish red colour, due probably in part to the hyperæmia, and in part to a purulent infiltration of its tissue. There are generally no adhesions between the edge of the pupil and the capsule of the lens. The tendency of this non-inflammatory form of suppurative corneitis is to extend rather in circumference than in depth, so that it leads to very considerable opacity or even extensive suppuration of the cornea, with all its dangerous consequences.

When the process of reparation sets in, we find that the yellow and sharply defined infiltration becomes surrounded by a greyish zone, and that there is at the same time an increase in the vascularity of the eye. Much of the danger is now past, for the disease assumes more of the character of inflammatory suppurative corneitis, and shows a tendency to become limited, and there is, consequently, much less fear of purulent necrosis and sloughing of the cornea. Gradually the yellow colour is changed to a whitish grey, the purulent infiltration breaks down and is

absorbed, and the corneal tissue is regenerated. It may, after a time, even regain its normal transparency, especially in children, and if the infiltration was but small and superficial. Otherwise, a more or less dense opacity is left behind, which, if it be situated in the centre, may cause great impairment of vision. But if a sufficient portion of the margin of the cornea is transparent and of normal curvature, excellent sight may often be restored by the formation of an artificial pupil. But, unfortunately, so favourable a result is not always obtained in severe and extensive suppurative corneitis. Perforation of the cornea but too frequently takes place, followed by anterior synechia or staphyloma, or the inflammation extends to the other tissues of the eyeball, and panophthalmitis occurs, ending in atrophy of the globe.

Inflammatory suppurative corneitis occurs frequently in very aged and feeble persons, more especially after operations involving the cornea (such as those for cataract, especially the flap operation), or after injuries to the cornea from foreign bodies striking it or becoming lodged upon it. Thus, it is not unfrequently met with amongst aged country people if a bit of wheat ear, or, perhaps the wing of an insect, becomes imbedded in the cornea and is not removed at once. I have seen it produced sometimes by concussion from a simple blow against the eye by a bit of wood, the bough of a tree, etc., without any wound of the cornea. It sometimes occurs amongst young children, and may then assume even an epidemic character (Von Graefe, Roser). It may also supervene upon severe constitutional diseases, which have greatly weakened the general health, such as typhus fever, cholera, encephalitis, diabetes, etc.

It may likewise follow paralysis of the fifth nerve, and is then termed neuro-paralytic ophthalmia. The affection of the cornea is generally chronic, and occurs some time after the paralysis. If the latter is partial, the cornea is but rarely affected, and then only partially, and not to a severe extent. The eye loses its sensibility, so that when irritants (*e.g.*, astringent collyria) are applied to it, they excite redness, but no feeling of pain or discomfort, indeed their presence is unfelt. The cornea then becomes opaque, ulcers may form, and suppuration may take place, leading perhaps to perforation, hypopyon, etc., and the inflammation may even extend to the iris. The epithelium of the cornea and conjunctiva becomes rough and dessicated, so that a certain degree of xerophthalmia is produced. One very interesting fact is, that paralysis of the fifth nerve always produces a diminution of the intra-ocular tension, and this is a point of the utmost importance with regard to the whole question of glaucoma and increased intra-ocular tension.

The affection of the cornea which may ensue upon paralysis of the fifth nerve is apparently not due to mal-nutrition of the part, but

simply to mechanical injuries, caused by the action of external irritants (dust, sand, etc.) to which the eye is exposed, and whose presence, on account of its insensibility, it does not resent or feel. That this is so, has been uncontrovertibly proved by the experiments of Snellen and others. Snellen divided the fifth nerve in rabbits, and sewed their ears over the eyes, so as to protect the latter from all external irritants, and he found that when this was done the cornea did not become affected, whereas, it began to become opaque the very day after the eye was left uncovered. More lately he has reported* a very interesting case, which fully bears out this view. A man, 36 years of age, was affected with complete paralysis of the left fifth nerve, together with paralysis of the sixth nerve of the same side. In consequence of the latter, there existed a convergent squint of the left eye, and on the outer side of the cornea there was a superficial ulcer, surrounded by a tolerably broad grey zone. The eye was quite insensible, and the acuteness of vision diminished to $\frac{11}{200}$, and its tension was much decreased. In order to ascertain with certainty whether the affection of the cornea was due to mal-nutrition of the eye, or to its exposure to external irritants, Snellen fastened, by means of strips of plaster, a stenopaic shell over the eye, in order to protect it. A small central aperture was left for the patient to see through, so that he might ascertain whether the shell retained its proper position, for from the want of sensibility of the eye, he could not determine it otherwise. The shell was removed twice a day in order that the eye might be washed and cleansed. The improvement in the condition of the cornea and the sight was very marked, for within two days the vision $= \frac{20}{70}$, and the cornea cleared so rapidly, that in eight days after the application of the shell the acuteness of vision was normal, viz., $= \frac{20}{20}$. Only a small opacity remained at the outer side of the cornea, but the loss of sensibility and the diminished tension continued. The application of turpentine and nitrate of silver produced the same symptoms of congestion as in a normal eye, without, however, being felt by the patient. The stenopaic cup was left off, and the eye exposed; within two days the eye became again more inflamed, and the vision became diminished to $\frac{20}{100}$. It shortly regained its normal standard after the re-application of the shell.

Meissner† is, however, of opinion that this tendency to inflammation of the cornea is not altogether due to the loss of sensibility, for he has observed three cases in which no corneitis ensued after division of the fifth nerve, although the eye was quite insensible, and not guarded against external irritants. On examination, it was found that in all these instances the innermost portion of the nerve had

* "Jaarlijksch Verslag, etc.," 1863.

† Henle and Pfeuffer's "Ztschr," (3), xxix, 96.

escaped division. He, therefore, considers it probable that the fibres of this portion of the nerve render the eye more able to resist the effect of external irritants, etc. This supposition is strengthened by another case, in which Meissner incompletely divided the fifth nerve in a rabbit, and although the sensibility of the eye was not impaired, the inflammation of the cornea ensued in the customary manner. On examination, it was found that only the median (innermost) portion of the nerve had been divided. Schiff* has repeated these experiments with exactly the same results.

The very dangerous character of non-inflammatory suppurative corneitis is chiefly due to the rapidity with which the infiltration extends, more especially in circumference, and to the great tendency to purulent necrosis of the corneal tissue, which leads but too frequently to very extensive suppuration of the cornea, or even to purulent disorganization of the eyeball. This disease proves especially disastrous if it be treated by the ordinary antiphlogistics, *e.g.*, cold compresses, leeches, etc., more particularly in severe cases. Thus Von Graefe found, that when he pursued this mode of treatment he lost about three-fourths of the severer cases. Whereas, his success was very marked as soon as he substituted warm fomentations and the compress bandage. The object of the warm fomentations is to excite a certain degree of inflammatory reaction and swelling in the conjunctiva and cornea; for in the total absence of these is to be sought the chief danger of the disease. They also hasten the limitation of the suppuration, expedite the absorption of the infiltration, and favour the process of reparation. After their application the eye becomes more injected, and this is accompanied by inflammatory swelling of the conjunctiva. The vascularity also extends more or less on to the cornea. The infiltration is no longer sharply defined against the transparent cornea, but a grey halo appears around it, and this portion of the cornea is somewhat swollen, and the line of demarcation soon becomes well marked. If an hypopyon exists, and is not very considerable in extent, we often find that it becomes rapidly absorbed after the use of warm fomentations. Von Graefe† generally uses warm camomile fomentations, varying in temperature from about 90° to 104° of Fahrenheit, according to the condition of the eye. The less the symptoms of inflammatory irritation, the higher should the temperature be. They should be changed every five minutes, and their use suspended for one quarter in every hour. The temperature should be lowered and the fomentations changed less frequently, or a longer interval be allowed to elapse between their application, as soon as the zone of demarcation and the inflammatory swelling

* Henle and Pfeuffer's "Ztschr," (3), xxix, p. 217.

† "A. f. O.," vi, 2, 133. Vide also the author's abstract of this paper in "Roy. Lond. Ophth. Hosp. Reports," vol. iii, 128.

make their appearance, and the necrosed portions of cornea begin to be thrown off. If these points are not attended to, we may set up too great an inflammatory reaction, so that it may even become necessary to check it by antiphlogistic applications (cold compresses, leeches, etc.). Sämisch,* who has extensively studied the effect of warm fomentations, advocates their continuation for a somewhat longer period in certain cases, in order to promote the exfoliation of the necrosed portions, and to expedite the absorption of the morbid products. Their effect must then, however, be closely watched, in order that too much inflammation is not set up. Indeed, the employment of warm fomentations requires great circumspection and attention, and cannot be entrusted to a stupid or careless nurse, for if they are applied too hot, changed too frequently, or continued too long, they may produce an excess of inflammation; or if, on the other hand, they are permitted to get cold, they are even still more injurious, by diminishing the vitality of the part, and thus increasing the tendency to necrosis. Where I cannot rely upon the care and attention of the nurse, I am in the habit of ordering the occasional use of warm poppy or camomile fomentations at stated periods. For instance, three or four times a day for the period of half an hour; the fomentations being changed every five minutes during that time. In this way considerable benefit may be derived from their use, without incurring any risk.

Warm fomentations are indicated in all forms of non-inflammatory suppurative corneitis, whether of spontaneous origin, or caused by injuries to the eye or operations (especially those for the removal of cataract). They may also be necessary in cases of inflammatory suppurative corneitis if the symptoms of inflammation have sunk below a certain point.

Great advantage is also experienced from the use of a firm compress or the "pressure bandage" (*vide* p. 13), for this is of much service in limiting the extent of the suppuration and hastening the formation of the zone of demarcation. Its application should alternate with the warm fomentations.† Even a certain degree of iritis does not contra-indicate its use. According to Von Graefe, it is not, however, applicable in those cases in which the purulent necrosis occurs rapidly, after the sudden cessation of severe symptoms of irritation and ciliary neuralgia, with which the disease was ushered in. After the pain had been alleviated by subcutaneous injection of morphia, and warm fomentations had been applied, Von Graefe then found much benefit from the use of chlorine water.‡ If there is any iritis and the aqueous humour is turbid, with or without the presence of hypopyon, it is most advisable

* "Klinische Beobachtungen von Pagenstecher and Sämisch," 2, 102; 1862.

† "A. f. O.," vol. ix, 2, 151.

‡ Ibid., vol. x, 2, 205.

to perform iridectomy without delay. This will generally at once cut short the progress of the disease and stop the extension of the suppuration. But if it is found that this improvement is but temporary, and lasts but for a few days, Von Graefe advises that the chlorine water should be again applied. He has done this even within thirty hours after the operation, if fresh crescentic infiltrations showed themselves around the original abscess, and he found that their extension was decidedly and markedly checked by this remedy.

In the neuro-paralytic form of corneitis, a light bandage should be applied over the eye so as to protect it against all external irritants. It should be removed two or three times daily, and the eye washed and cleansed. If the case be seen sufficiently early and before any considerable mischief has been done, this remedy will generally suffice rapidly to cure the affection of the cornea.

Atropine drops should always be applied, as they not only act as an anodyne, but also diminish the intra-ocular tension. They are of especial importance if there is any iritis.

If perforation of the cornea appears imminent, and the ulcer is not of considerable size, a paracentesis should be made with a fine needle through the bottom of the ulcer, so as to allow the aqueous humour to flow off very slowly. This will diminish the intra-ocular tension and facilitate the absorption of the infiltration, and the filling up of the ulcer. But if the infiltration or ulcer is deep seated, of considerable extent, and shows a tendency to increase still more, or to perforate the cornea, paracentesis should be at once performed. It is also indicated if a certain degree of hypopyon is present, with or without iritis. It has been already stated that our object in tapping the anterior chamber is less to remove the lymph than to diminish the intra-ocular pressure, and thus to stop the progress of the disease, hasten the absorption of the morbid products, and facilitate the regeneration of the corneal tissue. The incision is to be made with a broad needle in the cornea near its lower edge, and the aqueous humour should be allowed to flow off very slowly indeed. It may be necessary to repeat the operation several times, or, in order that its effect may be more lasting, the little wound may be kept patent by the occasional insertion of a small probe once or twice a day.

But if the hypopyon is considerable in size, occupying perhaps one-third or one-half of the anterior chamber, if there is much iritis, or if the abscess in the cornea extends very deeply, and threatens to cause an extensive perforation, it is of great importance that an iridectomy should be made without loss of time. For the intra-ocular tension will be thus more completely diminished and for a longer period, than by the paracentesis. We generally find that the iridectomy exerts a most beneficial influence upon the suppuration of the cornea, and also

as an antiphlogistic upon the inflammation of the iris. The progress of the suppuration, both in circumference and depth, is arrested, the deeper layers of the cornea do not become necrosed, and the absorption of morbid products, and the process of repair are hastened. Indeed, I think that an iridectomy should generally be preferred to a paracentesis if the disease be at all severe and threatening perforation, more especially if the abscess or ulcer be of considerable size and situated in the centre of the cornea, for then it will leave a dense opacity behind it, and, after all, necessitate the formation of an artificial pupil.

If there is a considerable hypopyon, the iridectomy should be made downwards, or downwards and inwards, in order that the lymph may escape with the aqueous humour through the large incision. If it does not do so readily, it is better to leave some of it in the anterior chamber than to pull and drag upon it in the endeavour to remove it, for this may set up great irritation. I think that this is to be preferred to making the iridectomy upwards and then endeavouring to remove the lymph by a pair of forceps, for this will drag upon the lower portion of the iris, and may produce much irritation and increase the inflammation.

Weber strongly recommends that the paracentesis should be made with a broad needle through the bottom of the abscess, so that it may be split across; the gush of aqueous humour through the incision will carry with it more or less of the contents of the abscess, and thus cleanse it and favour its filling up.

In the non-inflammatory suppurative corneitis it is of great importance to keep up the patient's general health. As this affection is most prone to occur in delicate, weakly children and in old and feeble individuals, tonics and diffusible stimulants should be freely administered, and the patient be placed upon a generous diet, with wine or malt liquor. I have been occasionally obliged to treat cases of this kind as hospital out-patients, and have sometimes succeeded in obtaining very successful results, even although the suppuration was already extensive and accompanied by some hypopyon and iritis. In such cases I have always applied atropine, warm poppy fomentations three or four times daily, and a compress bandage, and performed paracentesis (perhaps repeatedly) when the hypopyon had reached to more than one-fourth of the anterior chamber. I have at the same time prescribed full doses of quinine and steel, combined perhaps with ammonia or mixed acids, a good diet, and stimulants.

But only absolute necessity should induce us to treat such cases as out-patients, as the disease is of the gravest nature, and demands the frequent attention of the surgeon and the constant care of a good nurse.

6.—ULCERS OF THE CORNEA.

Ulcers of the cornea vary much in importance and danger according to their extent and their situation; in some cases their course is acute and rapid, in others very chronic and protracted, obstinately defying almost every remedy. The superficial are less important and dangerous than the deep-seated ulcers. In the former, we should not include mere abrasions of the epithelium such as may occur after slight injuries from foreign bodies, or from the bursting of the vesicle in phlyctenular corneitis. The term ulcer should, I think, be confined to cases in which there is a breaking down and elimination of the affected corneal tissue, so that there is a distinct loss of substance.

When speaking of phlyctenulæ, and the inflammatory infiltrations of the cornea, it was mentioned that their contents often break down, soften, and are thrown off, giving rise to an ulcer, which may either remain superficial or extend somewhat deeply into the corneal tissue. But the tendency to ulceration may also show itself from the outset. Then there is noticed, near the centre or the margin of the cornea, a small opacity, the edges of which are somewhat irregular, swollen, and of a grey colour, which shades off to a lighter tint towards the centre, so that the latter may even seem quite transparent. The ulcer, whose epithelial covering is lost, is surrounded by a zone of grey and somewhat swollen cornea; it gradually assumes a more yellow tint, and extends in depth and circumference, its contents breaking down and being cast off, so that it may reach a considerable extent before its progress can be stopped. It is often accompanied by severe symptoms of irritation, great photophobia, lachrymation, and ciliary neuralgia. When the process of reparation sets in we notice that the epithelial layer is gradually formed, this reparation commencing from the periphery. The ulcer assumes a greyer tint and is gradually filled up by new tissue, which may resemble very greatly the normal corneal tissue, although the intercellular substance is apt to be not quite transparent, thus giving rise to a certain amount of opacity. Sometimes the process of repair is extremely slow and many months elapse before the ulcer is healed. As soon as the layer of epithelium is regenerated the symptoms of irritation, more especially the pain and photophobia, rapidly subside. Blood-vessels (both venous and arterial) appear upon the cornea and run towards the ulcer, hastening the process of reparation and absorption, and dwindling down and disappearing when their task is done. Sometimes the reparative process is incomplete, and a more or less deep opaque depression or facet of a somewhat cicatricial appearance remains behind.

We sometimes meet with a peculiar form of funnel-shaped ulcer, which shows a very marked tendency to extend in depth and perforate

the cornea, obstinately and persistently resisting all and every kind of treatment until perforation has taken place, when it at once begins to heal.

Another and very dangerous form is the crescentic ulcer, which commences near the edge of the cornea, and looks as if a little portion had been chipped out with the finger-nail. It shows a great tendency to extend more and more round the edge of the cornea like a trench (in which the cornea is much thinned), until it may even encircle the whole cornea. The vitality of the central portion is generally greatly impaired, and it becomes more and more opaque and shrivels up until it may look like a yellow, dry, friable or cheesy substance, portions of the surface of which may be thrown off, or it may give way and a very extensive rupture of the cornea take place. This crescentic ulcer is extremely dangerous and intractable, resisting often most obstinately every form of treatment. In some cases great advantage has been derived from syndectomy, either partial if the ulcer was but of slight extent, or complete if a considerable portion of the cornea had become involved. In other cases I have, however, seen it do but very little good. Iridectomy has also been sometimes found of benefit, and should be preferred to paracentesis. The patient should be placed upon a very nutritious and generous diet, and tonics, together perhaps with mixed acids, should be administered.

Whilst these different forms of corneal ulcer are always accompanied by more or less irritation and inflammation, there are also some forms in which the inflammatory symptoms are almost entirely absent; they, indeed, in their character and course may closely resemble the non-inflammatory suppurative corneitis. We notice that the ulcer is white in colour and clearly defined against the transparent cornea, and not surrounded by a grey swollen zone of demarcation. It is accompanied by very little, if indeed any, photophobia, lachrymation, redness, or pain; there is also more tendency to necrosis, and extension in circumference than in the other forms.

One peculiar and very dangerous kind of non-inflammatory or indolent ulcer is that which is often met with in very aged and decrepid individuals, and is generally accompanied by hypopyon. In character it closely resembles the non-inflammatory suppurative corneitis, in fact the latter very frequently passes over into this form of ulcer. Like it, it commences with a small greyish-white spot, perhaps in the centre of the cornea, which soon passes over into an ulcer and extends very rapidly in circumference, the affected tissue breaking down and being cast off until a large superficial sloughing ulcer is the result. When it has reached a certain depth it very frequently becomes complicated with hypopyon, which may be due to iritis, to inflammation of the posterior layers of the cornea and proliferation of the epithelial cells,

or to perforation of the ulcer and a discharge of its contents into the anterior chamber. There is a marked absence of all inflammatory symptoms, and in this consists its chief danger, as it leads to rapid and extensive sloughing of the cornea.

Sometimes we may observe a peculiar transparent ulcer of the cornea, in which both the margins and the bottom of the ulcer are quite transparent, and free from any opaque halo; there is also an absence of vascularity. These ulcers are very intractable and may persist for a long time. They may, however, heal rapidly if a sufficient degree of vascularity can be established.

The complications to which ulcers of the cornea may give rise are often very serious and may even prove destructive to the eye. If the ulcer is superficial, of but slight extent, and occurs in a young healthy subject, it may heal perfectly, and finally leave hardly any, if indeed any, opacity behind; the cornea in time regaining its normal transparency. Indeed, even small perforating ulcers which have given rise to anterior capsular cataract, may gradually disappear without leaving almost any trace behind them. I have not unfrequently met with cases of central capsular cataract in old persons whose cornea was apparently clear, and it was not until it was examined by a strong light or with the oblique illumination, that a small opacity of the cornea could be detected just opposite the centre of the lens; then, on enquiry, it was perhaps ascertained that the patient had as a child suffered from inflammation of the eye.

When the ulcer has extended very deeply into the cornea nearly as far as the membrane of Descemet, the latter may yield before the intraocular pressure and bulge forward, looking like a small transparent vesicle at the bottom of the ulcer. This condition has been termed hernia of the cornea or "keratocele." If the membrane of Descemet be very tough and elastic it may protrude even beyond the level of the cornea, and give rise to a transparent prominent vesicle like a tear drop. This generally soon bursts, and gives rise to an ulcer, or a fistulous opening may remain, and prove very intractable; but it may exist for weeks or even months, when it gradually becomes thicker, flatter, more opaque, and changed into a kind of cicatricial tissue. It was generally supposed that the walls of this vesicle consist only of the membrane of Descemet pushed forward by the aqueous humour, but Stellwag states that they also always include some of the deepest layers of the cornea, traces of which may even be found at the sides of the vesicle, and sometimes also at the apex.

The chief danger of the ulcers, apart from the dense opacities which they may leave behind, is to be found in their perforating the cornea, and the degree of this danger varies with the extent and situation of the perforation.

If the perforation is but small, the iris will fall against it when the aqueous humour flows off, without protruding through it; plastic lymph will be effused at the bottom of the ulcer and this may at once commence to heal, the iris becoming slightly glued against the cornea. The aqueous humour re-accumulates, and if the adhesion between the iris and cornea is but very slight, it will yield before the pressure of the aqueous, and the iris be liberated and fall back to its normal plane. The muscular action of the sphincter and dilator of the iris during the action of the pupil will also assist in breaking through the adhesion, but if the latter is at all considerable and firm, the iris will remain adherent to the cornea, and a more or less extensive anterior synechia be formed. If the perforation is large, as it must be if the iris falls into it and protrudes through it, this protrusion may gain a considerable size by the collection of aqueous humour behind it, which causes it gradually to distend and bulge more and more. The colour of the prolapse is soon changed from black to a dirty, dusky grey tint, and its base is surrounded by a zone of opaque cornea. The portion of protruding iris which lies against the edges of the ulcer, generally becomes united to the latter by an effusion of plastic lymph, the aqueous humour is again retained, and the anterior chamber re-established, with the exception of the portion in the vicinity of the prolapse, for here the iris is lifted away from the anterior surface of the lens, and a more or less considerable posterior chamber is formed. The pupil is distorted and dragged towards the perforation, and the extent of this distortion varies with the size and situation of the prolapse. If a portion of the pupil is included in the prolapse it will be irregularly displaced and dragged towards the latter, and diminished in size correspondingly to the amount of the pupil which is involved. When the whole pupil is included the iris will be tensely stretched towards the perforation; if the latter is considerable in size and the aqueous humour has gushed forth with much force, the lens and even some of the vitreous humour may be lost. If the prolapse is small and seen shortly after it has taken place, it may often be replaced under judicious treatment, and the ulcer perhaps heal without even an anterior synechia remaining behind, but if it is considerable in size the result will be much less favourable, for the protruding portion of iris, exposed to the action of external irritants, *e.g.*, the air, movements of the lids, etc., becomes inflamed and covered by a thin greyish-white layer of exudation, which gradually becomes thicker and more organized, and assumes a cicatricial texture. Now, if this cicatricial covering and the adhesions of the iris to the edges of the ulcer are not sufficiently strong to withstand the intra-ocular pressure, the prolapse will gradually increase in size, and the surrounding portions of the cornea will also bulge more and more until an extensive staphyloma may be produced. If the cornea is perforated

at several points, through which small portions of iris protude, it is termed "Staphyloma racemosum."

If the perforation is very small, and situated at or near the centre of the cornea, capsular cataract may be produced in the manner already described. Again, the sudden escape of the aqueous humour, and falling forward of the lens, may cause a rupture of the capsule, and thus give rise to lenticular cataract.

With regard to the treatment of ulcers of the cornea we must be chiefly guided by the amount of inflammation which is present. Whilst we endeavour to check an undue degree of inflammation, we must be on our guard not to subdue it too much, as this would favour the tendency to necrosis, and protract the process of reparation. In the progressive stage of an acute inflammatory ulcer, the patient should be kept in a somewhat darkened, but well ventilated room, and be guarded against the effects of bright light, cold wind and other external irritants. It may be necessary to administer a brisk purgative and saline diuretics, together with a light, non-stimulating diet, if there are marked inflammatory symptoms and the patient is of a strong plethoric habit. But we must be upon our guard not to prescribe this kind of treatment in all cases, for very frequently ulcers of the cornea occur in persons of delicate, feeble health, and then it would prove injudicious and injurious, for it would increase the tendency to necrosis, and retard the filling up of the ulcer. In such cases the patient should be placed on tonics, and a very nutritious diet. When the process of repair has set in, he should be permitted to get into the open air, indeed this is especially indicated if the disease shows a tendency to become indolent and chronic. Much benefit is then experienced from out-of-door exercise, and a residence in the country or at the sea-side.

The object of our local treatment must be to endeavour to diminish marked symptoms of inflammatory irritation, to stop the progress of the ulcer, and to hasten its repair and the absorption of the morbid products. If there is much injection, photophobia, lachrymation, and ciliary neuralgia, atropine should be dropped into the eye, the compound belladonna ointment should be rubbed over the forehead, and perhaps a blister applied behind the ear. If the pain in and around the eye is very great, and especially if the latter is very tender to the touch, two or three leeches should be applied to the temple. Much relief will also be experienced from the subcutaneous injection of morphia. A great amount of mischief is but too often caused by the use of strong caustic or astringent lotions, during the acute progressive stage of the ulceration. Not only do they greatly augment the irritation, but they increase the tendency to necrosis and extension of the ulcer. It is only in the chronic, torpid ulcer which has already become covered by epithelium,

that caustics are at all applicable, and even then they must be used with great caution and circumspection. In the chronic, indolent, non-inflammatory ulcer we must apply atropine, a compress bandage, and above all, warm fomentations, in order to excite a certain degree of inflammatory swelling; or the yellow oxide of mercury ointment may be employed, for this remedy hastens the process of absorption and tends to prevent relapses. The patient's health must be invigorated by tonics, a generous diet, and stimulants; indeed the same line of local and general treatment must be adopted as in the non-inflammatory suppurative corneitis. We must never forget to apply a compress bandage over the eye, in order not only to guard it against external irritants, but to support the thinned ulcerated portion of the cornea against the intra-ocular pressure, and to prevent the constant movements of the eyelids, which greatly impede the formation of an epithelial covering over the ulcer; which, as we have seen, forms the commencement of the retrogressive and reparative stage.

In all ulcers of the cornea, but more especially in those which extend deeply into its substance, the process of repair is greatly retarded by the high amount of intra-ocular pressure which the thinned portion of the cornea at the bottom of the ulcer has to bear. In consequence of this, the latter is very apt either to give way completely, and to perforate; or else it yields somewhat before the intra-ocular pressure, bulges forwards, sloughs, and is partly thrown off, and thus the process of repair is much impeded. Now we possess three principal means of diminishing the intra-ocular pressure, viz., atropine, paracentesis, and iridectomy. The beneficial action of atropine, both as a direct sedative, and in reducing the intra-ocular tension, has been already explained.

If the ulcer has extended so deeply into the substance of the cornea as to threaten perforation, no time should be lost in performing paracentesis at the bottom of the ulcer; for by so doing, we shall be able to limit the perforation to a very small extent; for if we permit the spontaneous perforation of the ulcer, we find that before this occurs the bottom of the ulcer extends somewhat in circumference, and thus a considerable ragged opening may result, and the latter will certainly be much larger than if it had simply been made with a fine needle. Moreover, the escape of the aqueous humour will, in the former case, be more sudden and forcible, which is apt to produce considerable hyperæmia *ex vacuo* of the deeper tunics of the eyeball; prolapse of the iris, which may lead to suppurative iritis or irido-choroiditis; or rupture of the capsule, and consequent cataract; or again, the suspensory ligament of the lens may be torn, and the lens partially dislocated. The paracentesis should not be postponed until the deepest layers of the cornea are implicated, for we then run the risk of a large spontaneous perforation

occurring before we have time to interfere. The puncture should be made with a fine needle at the deepest portion of the ulcer, and the aqueous humour allowed to flow off as gently as possible. The iris will gradually move forward, and come in contact with the back of the cornea; a thin layer of lymph will be effused at the bottom of the ulcer, under which the regeneration of the corneal tissue will take place, the iris being generally more or less glued to the perforation by the effusion of lymph. As soon as the opening is stopped by this plug of lymph, the aqueous humour will re-accumulate, and if the adhesion between the iris and cornea is but slight, it will readily yield to, and be torn away by, the force of the aqueous humour and the action of the muscles of the iris. But if the layer of lymph at the bottom of the ulcer is thin and weak, the force of the intra-ocular pressure may rupture it, or may cause it to bulge forward, and thus necessitate a repetition of the paracentesis. The latter should also be repeated, perhaps even several times, if we notice that the process of repair becomes arrested, and that the ulcer again shows a tendency to increase in depth. After the operation a compress bandage should be applied. If the ulcer is extensive, and if hypopyon or iritis co-exist, the puncture should be made with a broad needle at the edge of the cornea, or an iridectomy should be substituted. The indications which should guide us in selecting between these two operations have already been considered in the article upon suppurative corneitis. In cases of obstinate ulceration of the cornea, confined especially or entirely to one portion of the latter, much benefit is sometimes derived from syndectomy of the corresponding segment of the sclerotic; so that the blood supply of the affected portion of the cornea may be more or less cut off. In obstinate chronic vascular ulcers of the cornea, which have long resisted every form of treatment, and show a great tendency to recur, the insertion of a seton at the temple often renders the most marked and striking benefit, the disease being rapidly cured, and the relapses prevented, if the seton is worn for some time after the corneal ulcer is healed.

We are especially indebted to Mr. Critchett for introducing this mode of treatment* in certain cases of chronic vascular ulcers of the cornea, which are especially characterised by their protracted course, their great tendency to recur, and the obstinacy with which they resist all ordinary methods of treatment. Mr. Critchett has favoured me with the following description of the manner in which the seton is to be applied:—

"I generally use rather stout silk or fine twine, such as a large suture needle will carry. I select a spot near the temporal region

* Mr. Spencer Watson has also published some able papers upon this subject in the "R. L. O. H. Rep.," and in the "Medical Mirror."

under the hair, so as to avoid as far as possible a visible scar. Care is required not to wound the temporal artery; this may generally be avoided by drawing the skin well away from the temporal fascia, holding it firmly by the hair. The needle is thus passed through at a level anterior to the artery; about an inch is usually included, and a loose loop is formed, which may be placed behind the ear; it requires to be dressed and moved daily; it usually continues to discharge for two or three months, and then either cuts its way through, or dries up. In severe and obstinate cases, where it is necessary, it may be renewed, selecting a spot near to the previous scar. I have sometimes found it desirable to continue the influence of a seton for 12 months. There are certain inconveniences that occasionally arise to which I may briefly allude. It will sometimes happen that in spite of every care and precaution a branch of the temporal artery is pricked by the point of the needle as it traverses the skin; this accident is at once recognised by the rapid outflow of arterial blood from one or both openings, through which the silk passes. In the event of such an accident, it is better at once to remove the silk, and then moderate pressure checks the bleeding, and in a few days a neighbouring spot may be selected for the re-introduction of the silk; but if this precaution be not taken, and if an effort be made to retain the seton in spite of the hœmorrhage, there is a great liability to secondary bleeding, to extravasation of blood beneath the scalp, burrowing abscesses, and other untoward casualties, and in one instance I observed the formation of a small traumatic aneurism. In certain exceptional cases the introduction of the seton is followed by considerable swelling of the surrounding parts, with a tendency to erysipelas, and suppurative inflammation cannot be established. As soon as these symptoms show themselves the silk should be removed."

If an ulcer is situated at or near the centre of the cornea, and perforation appears inevitable, the pupil must be kept widely dilated with atropine, in order that when the cornea gives way and the aqueous humour escapes, the edge of the pupil may not be involved in the perforation. On the other hand, if the ulcer is situated near the margin of the cornea, the reverse is indicated, and the pupil should be allowed to remain undilated, or even stimulated to extreme contraction, by the application of the extract of the Calabar bean, in order to remove the edge of the pupil as far as possible from the situation of the threatening perforation. Either of these remedies is also indicated when a slight adhesion exists between the cornea and iris (anterior synechia), for, by the strong action of the muscles of the iris which they produce, the adhesion may be forcibly torn through.

If a slight prolapse has occurred, we must at once attempt to replace it by pressing it gently back with a spatula or probe, or we may endeavour to cause it to recede by widely dilating the pupil by

atropine. A firm compress should be applied in all cases of prolapse, for it will favour the consolidation of the wound by the formation of a layer of lymph over the prolapse, and will prevent the latter from yielding to the intra-ocular pressure and increasing in size. The protruding portion of iris should also be pricked with a fine needle, and the aqueous humour be allowed to escape; for this will cause the prolapse to shrink and gradually dwindle down. This operation may be repeated several times, and generally with the best results; but if the prolapse is large and prominent, it should be first pricked with the needle, and then, when the escape of the aqueous humour has caused it to collapse, it should be seized with a pair of iridectomy forceps, and snipped off with a pair of curved scissors quite close to the cornea, a firm compress being at once applied. The same treatment is to be pursued in staphyloma iridis.

Some surgeons recommend that the prolapse should be touched with a point of nitrate of silver, or with a little vinum opii; but this is apt to set up great irritation, and may even produce severe iritis. If it be done at all, a weak solution of nitrate of silver should be lightly applied to the apex of the prolapse, with a fine camel's hair brush. In a considerable and obstinate prolapse, much benefit is generally derived from making a large iridectomy in an opposite direction, for this will often cause the prolapse to recede and flatten. This operation is also indicated when the pupil is partly or wholly implicated in the prolapse or anterior synechia; also, when there is a partial staphyloma, and, above all, when this is accompanied by an increase in the intra-ocular tension. For, as has been pointed out by Von Graefe, in cases of partial or complete staphyloma, or of leucoma prominens, the degree of blindness is frequently quite disproportionate to the optical condition. In such cases there is often contraction of the visual field, eccentric fixation, increase in the intra-ocular pressure, and excavation of the optic nerve. When glaucomatous symptoms supervene upon partial staphyloma, or leucoma prominens, we find the cornea becomes at this point markedly prominent, even after it has already become thickened and consolidated.

Fistula of the Cornea often proves very obstinate and intractable, and even dangerous to the eye, leading perhaps finally to irido-choroiditis and atrophy of the eyeball. A fistulous opening of the cornea may result from a small perforating ulcer of the cornea, or from a wound of the latter, with or without injury to the lens. The fistulous opening may become temporarily closed, so that the aqueous humour re-accumulates, but after a short interval it again gives way, the aqueous flows off, and the anterior chamber is obliterated. This may occur over and over again. When fistula of the cornea exists, the eye remains irritable and injected, the intra-ocular tension is greatly

diminished, the anterior chamber obliterated, and a small drop of fluid may be noticed exuding through the aperture in the cornea. Various modes of treatment have been advocated. At the outset a firm compress bandage should be applied, as well as a strong solution of atropine, and if this fails to heal the fistula, the latter may be touched with the point of a fine camel's hair brush dipped in a weak solution of nitrate of silver, this being repeated several times at an interval of a day or two. The disadvantage of this mode of treatment is, however, that it often produces an indelible cicatrix. An iridectomy frequently proves of more service. Wecker* considers that the fistula is due to an eversion of the membrane of Descemet at this point, and has therefore devised the following treatment. He introduces into the opening a very fine smooth-pointed straight pair of forceps, and, seizing the wall of the fistulous track, bruises its lining, and thus denudes the corneal tissue. This having been done at several points, atropine and a compress bandage must be applied. Great care and delicacy are required not to rupture the capsule with the point of the forceps. He has thus cured a case of fistula of the cornea, which had resisted for ten months different modes of treatment. Zehender† has found the prolonged use of the extract of Calabar bean of great service in curing a corneal fistula.

7.—DIFFUSE CORNEITIS (PARENCHYMATOUS, INTERSTITIAL, SYPHILITIC).

In this disease we may also distinguish two principal forms. The one is accompanied by marked symptoms of inflammation, and is hence called "vascular diffuse corneitis." In the other, or "non-vascular" form, these symptoms are entirely absent.

1. In the *vascular diffuse corneitis* we notice, together with a certain varying degree of conjunctival and subconjunctival injection, a zone of vessels passing from the margin of the cornea more or less towards the centre, where they terminate in a sharply defined line. They are not situated on the surface of the cornea, as those in pannus, but enter deeply into its substance. They consist in part of vessels derived from the junction of the conjunctival and subconjunctival vessels near the margin of the cornea, and in part also of branches coming from the blood-vessels of the ciliary body. Sometimes the vascularity at the edge of the cornea is so great, that it looks like a bright red zone of extravasated blood. Soon there is noticed at one or more points, a slight opacity of the cornea, which generally commences at the margin

* "Annales d'Oculistique," vol. 56, 305.

† "Kl. Monatsbl.," 1868, 35.

where its density is greatest, and gradually shades off towards the centre into transparent cornea. Sometimes, however, the opacity begins at the centre, whence it slowly extends towards the periphery. The cloudiness gradually increases in extent and thickness, until the whole surface of the cornea may become diffusely opaque. The density and colour of the opacity vary a good deal. Thus, it may be but thin, and of a greyish white colour, having very much the appearance of frosted glass, or it may be thicker and of a yellowish creamy tint, more especially in the centre of the cornea. Indeed, at this point we not unfrequently see a large circular patch of a pale yellow colour, which is evidently deeply seated in the substance of the cornea. This central patch may gain a considerable size, even of two or three lines in diameter. Sometimes several such denser patches may be noticed at different points. The epithelial layer at first retains its normal smoothness, but after a time it becomes somewhat rough and thickened, as if it had been lightly pricked by a pin, or a fine powder had been strewn over it. The disease shows very little tendency to ulceration or to purulent necrosis, unless it has been very injudiciously treated by caustics or strong astringent collyria. But the whole surface of the cornea may be swollen and become somewhat prominent, yielding here and there to the intra-ocular pressure and bulging forward. Generally these prominences disappear with the infiltration, but if they have been considerable, they may leave behind some impairment of the true curvature of the cornea. The amount of inflammation and ciliary irritation vary very much. Sometimes there is very considerable and obstinately persistent photophobia, together with lachrymation and a certain degree of ciliary neuralgia. In other cases these symptoms never assume any particular prominence. The sight is always greatly impaired, so that the patient can hardly see a hand moving, which is due to the diffuse character of the opacity, for it is as if he were looking through a piece of ground glass. If both eyes become affected, which is generally the case, the effect of this total loss of sight is most depressing, and demands the greatest confidence in the surgeon to prevent the patient from seeking other and perhaps injudicious advice. For the disease runs a most slow and protracted course; months and months elapse before any, even slight, improvement begins to show itself, and during all this time no treatment appears of any special service. We can but let the disease run its course, and endeavour to guide it in its progress. It may take from six to eight weeks until it has reached its acme; the cornea being then, perhaps, almost covered with closely crowded blood-vessels, which reach almost up to its very centre, where is seen a thick yellow infiltration. The red appearance of the cornea is often increased by small extravasations of blood, caused by the giving way of some of the vessels. The disease may

now remain stationary for a few weeks, and then the process of reparation sets in. The vascularity diminishes; the vessels are less closely arranged at the edge of the cornea, and show more or less considerable gaps between them; and the infiltration becomes thinner and lighter in colour, gradually disappearing more and more from the periphery towards the centre, which is the last to clear up.

The *prognosis* of the disease is, on the whole favourable, for although it runs a most protracted course, which may extend over many months, and although the opacity of the cornea may be so dense as to prevent the patient from even counting fingers, there is no tendency to ulceration of the cornea, and the opacity gradually disappears until there is finally perhaps only a slight cloudiness left. Both eyes are generally affected, and this renders the affection of course the more harassing and alarming to the patient, who may thus remain for many weeks almost totally blind. Iritis is a frequent accompaniment of the inflammation of the cornea, and may be quite unsuspected during the progress of the case, as the iris is hidden from view by the opacity of the cornea; and it is only when the latter becomes clearer that the iris is found somewhat discoloured, and the pupil irregular and adherent. But a still graver and more dangerous complication is inflammation of the ciliary body, which is especially apt to occur if the case has been carelessly treated, or caustic or strong astringent collyria have been applied. We must suspect this complication, if the symptoms of inflammatory irritation are greatly increased in intensity, if the vascularity, photophobia, lachrymation, and ciliary neuralgia are severe, if the sight is rapidly diminished, and the field of vision markedly contracted, and if the eye at the region of the ciliary body is extremely sensitive to the touch.

Diffuse corneitis is especially apt to occur between the ages of five and twenty, but it may be met with up to thirty-five or forty. It generally occurs in persons in a feeble, delicate state of health, which may be due to numerous causes, such as want and privation, very hard and fatiguing work, more especially in a confined or vitiated atmosphere; and it is often met with in persons affected with a scrofulous diathesis, or with inherited syphilis. I cannot at all agree with the view that diffuse corneitis is always due to inherited syphilis, for although I have often seen it associated with the latter, yet it many cases not the slightest trace of a syphilitic taint could be ascertained, and there was a marked and complete absence of the peculiar syphilitic features and the notched teeth. Indeed, I think that we are often too apt hastily to jump to the conclusion that hereditary syphilis exists, when on a more careful and searching examination into some of these histories, it would be found that the miscarriages, early deaths of the children, etc., were due to perfectly natural causes, and quite inde-

pendent of any syphilitic taint. I may of course be met with the constantly recurring argument that it is impossible to get at the truth of the history, but I think that we are justified in giving the patient and his parents the benefit of the doubt, if no reliable proof of the presence of inherited syphilis can be made out. For this reason, I must completely disagree with those authors who term this disease "syphilitic corneitis." For, as I have already stated, it is frequently met with in persons, in whom not the slightest trace of a syphilitic taint can be detected. Whilst combating some of these views, I must, however, seize this opportunity to express my admiration for the very important and interesting researches of Mr. Jonathan Hutchinson,* into the frequent connection between inherited syphilis and many of the diseases of the eye, a discovery which has proved of great importance and use in the treatment of these affections.

In the *treatment* of this disease, we must be chiefly contented with guarding the eye against all noxious influences, such as bright light, wind, draughts, etc., and must endeavour to prevent the inflammatory symptoms from gaining an undue prominence. Unfortunately we do not at present know of any means of checking the progress and development of the disease, or of curtailing its protracted course. The use of caustics or astringent collyria must be most carefully avoided, as they only tend to increase the inflammatory irritation and to produce complications, such as ulcers of the cornea, or inflammation of the iris or ciliary body. At the outset, atropine should always be applied, although when the cornea becomes diffusely clouded, it is but of little use, as it is not absorbed, and it is apt to increase the inflammation if it be too long continued. But when the cornea begins to clear, atropine or the belladonna collyrium should be again applied. Local depletion and very antiphlogistic treatment are not well borne on account of the weakly and feeble health of the patient. Moreover, they tend to impede the formation of blood-vessels on the cornea, and to protract the course of the disease. But if symptoms of cyclitis make their appearance, leeches should be applied to the temple, and paracentesis should be performed; and if the sight deteriorates greatly, the field becomes contracted, and especially if the intra-ocular tension increases, an iridectomy should be made at once. When the cornea is beginning to clear up, the absorption of the morbid products may be hastened by applying slight irritants. The best to commence with, is the insufflation of calomel, which should be employed once daily. If the eye bears this well without becoming too much irritated, the yellow precipitate ointment should be substituted for it. At first I generally

* Vide Mr. Hutchinson's admirable work, "Syphilitic Diseases of the Eye and Ear."

employ it of about the strength of two grains to the drachm, and use but a very small quantity. If it excites much irritation, I use a still weaker mixture, or postpone its use for a few days. I have found it by far the best remedy for accelerating the absorption of opacities of the cornea. A collyrium of iodide of potassium (gr. ij ad ℥j) is also serviceable for this purpose. Hasner has practised paracentesis in some of these cases of diffuse corneitis.

It is of great importance to attend to the general health of the patients, as they are as a rule of a feeble cachectic habit. Tonics, especially the syrup of the iodide of iron, quinine, or the citrate of quinine and steel should be administered. Cod-liver oil, with or without quinine or steel is also of much benefit. If a syphilitic taint is suspected, the iodide and bromide of potassium in combination with the bichloride of mercury and cinchona, may be given with much advantage. The diet should be nutritious and easily digestible. Meat may be allowed two or three times daily, and wine and malt liquor may be freely administered. In fact everything should be done to strengthen the patient. In hospital practice, I have often been obliged to take such patients into the house for many months, in order that they might have more attention, and a more generous diet than they would have obtained at home. When the acute stage is past, and the cornea is beginning to clear, the patient should, if possible, be sent into the country, or still better to the sea side, and enjoy a great deal of out-of-door exercise. The obstinate photophobia and chronic irritability of the eye, which often prove so troublesome, yield sometimes most rapidly to change of air.

2. In the *non-vascular diffuse corneitis*, we notice that a small cloud appears in the centre of the cornea, unaccompanied by any but the slightest symptoms of irritation, and there is only a very faint rosy injection around the cornea, but not extending on to it. In the course of ten or fourteen days the opacity extends over the whole surface of the cornea, giving it the appearance of ground glass, or of a mirror that has been lightly breathed upon. The symptoms of irritation, especially the photophobia, may now increase somewhat, but the vascularity remains slight. The vessels never become very numerous or closely crowded together, as is the case in the vascular form; but individual vessels straggle on towards the infiltration, and do not terminate uniformly in a defined line. The opacity gradually becomes somewhat more dense and yellow towards the centre, and then, after a time, clears up at the periphery, and the infiltration slowly disappears in a centripetal direction. The course of this form is also extremely protracted, and many months may elapse until the cornea regains its transparency. The prognosis is still more favourable than in the vascular form, for there is far less tendency to complications with inflammation of the iris

or ciliary body, or to ulceration of the cornea; although the latter may be produced if strong caustics or astringents be employed.

The causes are the same as in the vascular form. If there is any marked irritability of the eye, this should be treated by atropine, cold compresses, blisters, etc. But in the majority of the cases just the reverse obtains, the progress of the affection languishes and becomes torpid, and there is a complete absence of all symptoms of inflammatory irritation. In such cases it is advisable to apply a slight irritant, more especially the yellow oxide of mercury ointment every day for a few days. This will excite a little irritation, the central portion of the inflammation will become somewhat more thick and yellow, and the progress of the disease will become accelerated. It has often been noticed that a certain amount of conjunctivitis is very favourable. Thus, if the patient suffering from this form of corneitis, by accident contracts catarrhal ophthalmia, the progress of the affection of the cornea will be greatly hastened, and an infiltration disappear in a few weeks, which would otherwise have taken many months before it had become absorbed. This fact led Von Graefe to employ warm fomentations in these cases, in order to excite a certain degree of inflammatory swelling of the conjunctiva. They are indicated if the vascularity and irritation are but very slight, and the progress of the disease extremely protracted and sluggish. They must be employed with care and circumspection, so that they may not excite too much inflammation of the conjunctiva, which would retard instead of hastening the absorption of the infiltration, and perhaps leave it incomplete.

8.—OPACITIES OF THE CORNEA.

These vary much in situation, extent, and thickness. If they are quite superficial and thin, looking like a faint greyish blue cloud, they are termed nebulæ. If the opacity is of a denser, white, pearly, tendinous appearance, and situated more deeply in the substance of the cornea, it is called an albugo or leucoma.

A temporary diffuse opacity of the cornea may be produced by sudden increase of the intra-ocular pressure, as in certain forms of glaucoma, etc. This opacity is probably due in part to a displacement of some of the corneal elements, and also, perhaps, to a disturbance of the nutrition of the cornea from the compression of the nerves.

We meet with a very superficial opacity of the cornea, which is due to changes in the epithelial layer. Here and there the epithelial cells become thickened, aggregated together, and opaque, their contents having perhaps undergone fatty degeneration. These opacities are of a faint grey, or bluish grey colour, with an irregular margin. In

their centre, the reflection of an object, for instance a window, will be found indistinct, or more or less distorted. Generally they are easily observable. They may, however, be so slight as to escape detection, but become very evident with the oblique illumination. They occur after the superficial forms of corneitis, especially pannus due to distichiasis or granular lids, and also after superficial ulcers of the cornea.

The deeper opacities, which are situated in the substance of the cornea itself, may be confined to a certain portion of it (partial leucoma) or extend over its whole surface (total leucoma). The cloudiness may either be of a uniform greyish blue, or greyish white colour, or may be made up of several opaque white patches or spots of varying extent and shape. The outline of these opacities is irregular and not sharply defined, being shaded gradually off into the normally transparent cornea. Their thickness and colour also vary much, from a greyish blue to a yellowish white and densely opaque tint. The epithelial layer is often irregular and punctated, as if a fine powder had been dusted over it, and this causes a distortion of the reflected image. Or, again, the opacities may look like little opaque chalky nodules strewn about on different portions of the cornea (generally near its surface), and are the remains of phlyctenulæ.

Fine punctated opacities are also met with on the posterior surface of the cornea. They are generally arranged in the form of a pyramid, with its base downwards, and are chiefly due to a precipitation of lymph on the posterior wall of the cornea, but also perhaps to inflammatory changes in the posterior epithelial layer. These peculiar opacities are observed in serous iritis (sometimes termed aquo capsulitis, corneitis punctata, etc.), and also in inflammations of the deeper tunics of the eyeball, and sympathetic ophthalmia. In the latter cases, similar punctated opacities may also occur on the anterior surface of the cornea. The different opacities which we have mentioned are chiefly due to inflammatory changes in the corneal and epithelial cells, and are capable of undergoing almost complete absorption, so that they may hardly leave a trace behind them. It is necessary to distinguish from them another form of opacity which is dependent upon permanent change, often of a tendinous or cicatricial nature, and hence does not undergo absorption, but remains indelible. These opacities are more regular and sharply defined in their outline, and have a more uniform tendinous, glistening white or chalky appearance, having, perhaps, a deposit of fatty or earthy matter in the centre. The epithelial layer is smooth and not irregular. These cicatrices vary in extent and shape, in accordance with the size and depth of the original ulcer; they do not, however, correspond exactly to it, because a portion of the latter is very frequently filled up by transparent corneal tissue. These cicatricial

opacities occur very frequently together with those due to inflammatory changes, so that we have the two forms existing together. The cicatrix, instead of being sharply defined, is then surrounded by a more or less wide opaque areola of inflammatory infiltration. The latter may in time become completely absorbed and transparent, and leave only the cicatricial opacity, which will, of course, be now considerably less in size than the original leucoma.

In cases of perforating ulcer of the cornea, accompanied with anterior synechia, the cicatrix to which the iris remains attached is termed *leucoma adherens*. If it be situated near the centre of the cornea, a portion of the pupil will be included in it, leaving, perhaps, the other part of the pupil free, and opposite a transparent portion of the cornea.

A peculiar superficial opacity of the cornea is sometimes met with, which is due to calcareous deposits (consisting of phosphate and carbonate of lime) in the anterior elastic lamina. These opacities are of a mottled brownish hue, with an indistinct margin, which shades off, more or less abruptly, into the healthy cornea. Their course is very protracted, and they are apt simultaneously to affect both eyes. Two very interesting cases of this peculiar opacity, which occurred about the same time, have been described by Mr. Dixon* and Mr. Bowman.† In each of these cases a portion of the opacity opposite the pupil was scraped off with a scalpel, and was found to consist of hard gritty matter, situated just beneath the epithelium. The result of the operation upon the sight was excellent. Sometimes earthy or metallic incrustations are formed upon the cornea, and give rise to peculiar opaque or chalky-looking specks. This occasionally occurs from the contact of quicklime or the deposits formed from lead lotion in cases of ulcers or abrasions of the cornea.

The *prognosis* in cases of opacity of the cornea will depend very much upon the age and constitution of the patient, and upon the duration, extent, situation, and nature of the opacity. Thus, in children and young persons in good health, opacities, the result even of extensive corneitis or deep ulcers, may in time disappear almost completely, without leaving, perhaps, any trace behind. I have already stated that this may even occur in small perforating ulcers which have given rise to central capsular cataract. With regard to the opacities due to inflammatory changes in the corneal tissue, it may be laid down as a general rule that the more recent, superficial, and limited such opacities are, the more rapidly and completely do they disappear. By the application of irritants to the eye, we may greatly assist in removing the cloudiness due to inflammatory changes in the corneal and epithe-

* "Diseases of the Eye," 3rd edition, p. 114.

† "Lectures on parts concerned in the Operations on the Eye," pp. 38 and 117.

lial cells. We thus excite hyperæmia of the parts, increase the interchange of material, and accelerate and stimulate the process of absorption. When the opacities are due to permanent cicatricial changes, these applications are of no avail, and we must then have recourse to other remedies if the opacity causes any impairment of vision. If the opacity is dense and situated in or very near the centre of the cornea, the sight may be very considerably affected, as it will more or less cover the pupil. But even slighter opacities may somewhat impair and confuse the vision, by the diffusion and irregular refraction of the rays of light which they produce. But, apart from this effect upon the sight, these opacities may give rise to other complications. Thus, on account of the indistinctness of the retinal image produced by the cloudy state of the cornea, the patient will bring small objects (as in reading, sewing, etc.) very close to the eye, in order to gain a larger and more distinct image. But this constant accommodation for a very near point, after a time causes the lens to forfeit some of its elasticity, so that it cannot resume its original form, and the accommodation cannot relax itself completely when the eye is looking at distant objects. The lens remains too convex, and the eye has become myopic. The latter may be also in part due to a change in the shape of the eyeball, produced by constant and long-continued accommodation for near objects (*vide* article "Myopia"). Opacities of the cornea may also give rise to oscillation of the eyeballs, and to strabismus.

Innumerable local remedies have been recommended for the dispersion of opacities of the cornea. From amongst these we may select the following as the most trustworthy and efficacious :—The insufflation of calomel, the red or yellow oxide of mercury ointment, collyria of iodide of potassium, vinum opii, nitrate of silver, sulphate of copper, and the sulphate of soda. Together with the use of any of these agents, atropine should be applied, as it diminishes the intra-ocular pressure, and thus facilitates the interchange of material and the process of absorption. I have generally found it best first to dust in calomel for a few days, in order to see how the eye bears this, and then, if it does not excite too much irritation, to employ a stronger irritant, especially the red or yellow oxide of mercury ointment. At first its strength should not, I think, exceed one or two grains to the drachm of lard. A little portion, about the size of a couple of pins' heads, should be placed on the inside of the lower eyelid, by means of a probe, and the lids should then be well rubbed over the cornea, so that the ointment may come well in contact with it. If the yellow precipitate ointment be used of greater strength than that mentioned above, it should be removed after a few minutes, otherwise it may produce too much irritation. If it is found that the ointment excites a great deal of irritation, redness, and pain, a smaller quantity, or a weaker prepara-

tion should be used, or the calomel should be again substituted for a few days. Generally it is better if the surgeon can himself apply these remedies, as he is then able to watch their action upon the eye; but if the proper mode of using the calomel and the ointment be explained and shown to the patient, I have found no difficulty in getting these remedies applied by the patient himself, or his friends. I have also found advantage from the application of iodide of potassium, either in a collyrium or mixed with the yellow precipitate, in the following proportion:—Iodide of Potassium gr. j., Yellow Oxide of Mercury gr. ij., Adipis ʒj.—ʒij. The instillation of a little vinum opii also proves very useful. The nitrate of silver or sulphate of copper are only indicated when there is any inflammatory swelling of the conjunctiva, accompanied by some muco-purulent discharge. After any of these remedies have been used for some length of time, they should be exchanged for some other agent, as the eye gets accustomed to them, and they appear temporarily to lose their effect.

Electricity was formerly in vogue for the cure of opacities of the cornea. It has now, however, fallen into disuse.

Dr. Rothmund,* of Munich, has lately strongly recommended the subconjunctival injection of salt and water in cases of dense non-vascular opacities, such as often remain after diffuse corneitis. The strength of his solution varies from ℈j.—ʒj. of Salt to ʒj. of Water. He injects this fluid, which is slightly warmed, very gradually beneath the conjunctiva, at a distance of about one and a half or two lines from the edge of the cornea, around which it soon produces considerable chemotic swelling. It causes very little pain. After the injection he applies a compress bandage, and in the course of five or six hours the chemosis has generally entirely disappeared from absorption of the fluid. But the eye now looks red, and there is more or less conjunctival and subconjunctival irritation, together with some amount of ciliary neuralgia and photophobia. These symptoms of irritation disappear entirely in the course of five or six days. From parallel experiments instituted by Dr. Rothmund, in cases in which the corneæ of both eyes were completely opaque, it seems that this remedy is extremely serviceable in hastening absorption.

The chalky incrustations, or deposits of lead upon the cornea, should be carefully scraped off with a cataract or sickle-shaped knife. If they are extensive, the whole need not be removed, but only a portion sufficiently large to uncover the pupil. As this operation is sometimes very painful, it had better be done under chloroform, especially in children. Afterwards, a little olive oil or atropine should be applied to the eye.

But if the opacity resists all these remedies, and materially impairs

* "Klinische Monatsblatter f. Augenheilkunde," 1866, p. 161.

the sight, we must endeavour to improve vision, either perhaps by some optical arrangement, or by the formation of an artificial pupil opposite a clear portion of the cornea. In order to diminish the effect of the diffusion and irregular refraction of the rays produced by the cloudiness, great advantage is often experienced from the use of stenopaic spectacles (Donders)*. These consist of an oval metal plate, having a small central aperture. The effect of this is to permit only the central rays, which fall in the optic axis, to pass, whereas all the peripheral, diffused light is excluded. If necessary, convex or concave lenses may be applied behind the apparatus. Although these stenopaic spectacles often answer admirably for any employment at near objects, *e.g.*, reading, sewing, engraving, etc., they cannot be used for walking about, as they produce too great a contraction of the field of vision.

An artificial pupil may be made either by means of an iridectomy, or an iridodesis. If the opacity is confined to the centre of the cornea, it will be best to perform iridodesis, for, by so doing, we can draw the iris somewhat forward opposite the opacity, and thus diminish the diffusion of light produced by the latter; moreover, the apex of the artificial pupil will be opposite the edge of the lens, and will thus obviate the irregular refraction which would be caused if the periphery of the lens were widely exposed by an iridectomy. But if the opacity is more considerable, and does not leave a wide margin of clear cornea, the artificial pupil thus made would be insufficient, more especially with regard to the amount of light admitted into the eye, and in such cases it is better to make an iridectomy, which should, however, be but small. If the margin of transparent cornea is very narrow, there is always the danger that the wound made in the performance of iridectomy may produce a certain degree of fresh opacity of the small portion of clear cornea near it, and thus militate against the benefit derived from the operation. In order to obviate this danger, we may make the artificial pupil by corydialysis, which would, of course, produce no cloudiness of the cornea opposite to the new pupil, the incision being made at another portion of the cornea. An artificial pupil should always be made opposite that portion of the cornea which is the most clear, and has the truest curvature. The direction inwards, or slightly downwards and inwards, is by far the best for optical purposes, for not only does the artificial pupil then correspond to the visual line, but it also assists better in the mutual act of vision (Gemeinshaftlicher Sehact) with the other eye. If any anterior synechia exists, and its extent is but small, it may be divided with the point of the broad needle or iridectomy knife, in the performance of iridodesis or iridectomy. If it is of recent formation (as after an incised

* "Archiv. f. Ophthalmologie," i, 1, 251 ; vide also Donders' "Anomalies of Accommodation and Refraction of the Eye." New. Syden. Society, p. 128.

or punctured wound of the cornea), the adhesion is often so slight that it may easily be detached with a blunt hook or a small spud.

I need hardly say that the experiments made by Nussbaum and others to cut a hole in the opaque cornea and insert a piece of glass, have completely failed.

9.—ARCUS SENILIS.

This peculiar marginal opacity of the cornea is due to fatty degeneration of the corneal tissue, which generally commences first in the upper portion of the cornea. It then shows itself in the lower, and the extremities of the two arcs increase more and more, until at last they meet and encircle the whole cornea. We are chiefly indebted to Mr. Canton* for an exact and extensive knowledge of this condition; he has found that it generally occurs about the age of 50, but that it may appear at a much earlier age, especially in families in which it appears to be hereditary. He also considers that the arcus senilis affords us the best indication of the proneness of other tissues to fatty degeneration.

The opacity is at first of a light grey colour, appearing like a narrow silvery rim near the edge of the cornea, but not reaching quite up to the latter, being always divided from it by a transparent portion of cornea. At a later period the opacity assumes a denser and more creamy tint, and increases in depth and width, being generally broader above and below than at the sides. It might be supposed that the fatty degeneration of the corneal tissue would impede or prevent the union of an incision lying in this part of the cornea. This is, however, not the case, for we find that a section carried through the arcus senilis heals perfectly, as may be often observed in cases of extraction of cataract.

10.—CONICAL CORNEA.

When this affection is but slight, a cursory observer may easily overlook it, and mistake it, perhaps, for a case of myopia, complicated with weakness of sight (amblyopia). But a marked case cannot well be overlooked. On regarding such an eye from the front, we notice that the centre of the cornea appears unusually glistening and bright, as if a tear-drop were suspended from it. If we then look at it in profile, the size and shape of the conicity will become at once apparent. Sometimes the conicity is not in the centre, but nearer the margin of the cornea. But by means of the ophthalmoscope, even the slightest

* Vide Mr. Edwin Canton's work, "On the Arcus Senilis," London, 1863.

cases of conical cornea may be diagnosed with certainty, as was first pointed out by Mr. Bowman.* For this purpose the mirror alone is to be used, without the convex lens in front. On throwing the light upon the cornea, we receive a bright red reflection through the centre of the cornea, which gradually shades off, and becomes darker towards the base, so that the central bright red spot is surrounded by a dark zone, which in its turn is again encircled by a red ring. If we throw the light upon the centre of the cornea at different angles, the side of the cone opposite to the light is darkened. The central red zone (in which we obtain a reverse image of the disc, etc.) is due to the reflection of the fundus through the central conical portion of the cornea, and the outer red ring to the reflection through the normal peripheral portion of the cornea. The dark zone between the two is, according to Knapp,† due to the diffusion and complete reflection of the rays of light at the base of the cone, where it passes over into the normal curvature of the cornea.

On the ophthalmoscopic examination of the fundus of an eye affected with conical cornea, we notice a considerable parallax on moving the convex lens in front of the patient's eye.‡ In this way we can produce a distortion and displacement of a certain portion of the disc and retinal vessels, whilst the other part of the disc remains immovable, just as occurs in glaucomatous excavation of the optic nerve.

Even in slight cases of conical cornea, the patients already complain of considerable, and often great impairment of sight. On account of the conicity of the central portion of the cornea, the antero-posterior axis is increased in length, and hence the eye has become more or less myopic, and the patient consequently holds small objects (as in reading, etc.) very close to the eye. But the impairment of sight is chiefly due to the astigmatism caused by the irregular curvature of the cornea, which gives rise to great distortion and confusion of the retinal images. Concave spherical lenses, therefore, generally produce but slight improvement, but some benefit is occasionally derived from cylindrical glasses, although the astigmatism is as a rule too irregular to admit of much correction. More improvement is found from the use of a circular or slit-shaped stenopaic apparatus, fitted, perhaps, with a suitable concave lens, as this diminishes the circles of diffusion upon the retina by cutting off the peripheral rays of light. We often notice that the patients endeavour to accomplish this for themselves by nipping their eyelids together, so as to change the palpebral aperture into a

* "Royal Lond. Ophth. Hosp. Reports," vol. ii, p. 154.

† "Klinische Monatsblätter," 1864, 313.

‡ Donders, "Archiv. f. Ophth.," 7, 199; also Donders, "On the Anomalies of Accommodation and Refraction," 551. New Sydenham Society.

narrow slit. After the disease has existed a certain time, and reached a high degree of development, the apex of the cone often becomes opaque, and thus the sight is still more deteriorated.

The bulging forward of the cornea is not due to an increase in the intra-ocular tension (which is indeed rather slackened), but to a diminution in the power of resistance of the cornea, and as this bulging increases, the portion of cornea embraced in it becomes thinner and thinner. It is an interesting fact, that however attenuated the apex may become, it never gives way, except through an accidental injury. Mr. Bowman thinks that the reason of this is, that "as the cornea becomes thinner, the escape of the aqueous humour by exosmose is facilitated, and thus the internal pressure is reduced, so as to be no longer in excess of the diminished resisting power of the cornea. A balance is established like that of health, only that there is a more than ordinary outflow of the aqueous humour by transudation through the cornea. This accords with my previous observation, as to such eyes being rather unduly soft."

The progress of the disease is generally very slow. It may become stationary at any point, stopping short when the conicity is still but slight, or going on until it is very considerable and the apex has become clouded. It generally sooner or later attacks both eyes. It occurs frequently, but not always, in persons of a delicate constitution, and commences chiefly between the ages of 15 and 30. Mr. Bowman has observed a very few cases in which it occurred in more than one member of the same family. Any considerable and protracted use or straining of the eye in reading, sewing, etc., will tend to increase its development and produce local irritation and congestion.

Innumerable remedies have been suggested and tried for the relief and cure of conical cornea, but almost all of them without success. If the patient is in delicate health, tonics and a nutritious diet with plenty of fresh air and exercise, should be prescribed, and the use of the eyes for reading, etc., should be forbidden if both are affected. In order to neutralise the myopia produced by the conicity of the cornea, Sir W. Adams removed the lens. Mr. Wardrop recommended frequent tapping of the anterior chamber. Mr. Tyrrel was the first to make an artificial pupil in this disease, and this is the treatment which has hitherto proved most successful. The purpose we have in view in making an artificial pupil is twofold: 1st. To improve vision by making a pupil opposite a portion of the cornea which has retained its normal curvature; 2nd. To arrest the progress of the disease, and, if possible, to cause it to retrograde somewhat by diminishing the intra-ocular pressure.

The artificial pupil may be made either by an iridectomy or an iridodesis. By the former operation we certainly bring the pupil

opposite a marginal portion of the cornea, but there is this disadvantage, that the original pupil remains opposite the conicity, and therefore the rays which pass through it are diffused and irregularly refracted, and thus confuse the retinal image and diminish its distinctness; whereas, by means of an iridodesis we can draw the iris well forward towards the incision, and thus displace the pupil towards a portion of the cornea, which is less irregularly curved, and bring the iris opposite the cone. The incision should be made slightly in the sclerotic, so that the plane of the iris may not be moved away from the lens. The best direction for the iridodesis is slightly downwards and inwards. In order to obtain the advantages which are derived from a slit-shaped stenopaic apparatus, Mr. Bowman has made a double iridodesis, so that an oblong slit-shaped pupil is obtained. This may be made either vertical or horizontal. In the former case, we have the advantage that a considerable portion of the angles of the slit is covered by the lids, which renders it much less unsightly, more especially if the irides are light in colour, than the horizontal slit, which gives the appearance of a cat's-eye. The operation should not be performed in opposite directions at the same sitting, as the point first tied is apt to yield and be drawn into the anterior chamber again, when the iris is drawn towards the opposite incision. It is best to make the second iridodesis about eight or ten days after the first. The incision should be made in the sclerotic so as to retain the normal plane of the iris.

Not only does this operation produce a beneficial effect in an optical point of view, but it also sometimes causes a considerable diminution in the bulge of the cornea and the progress of the disease. At present it is very difficult to decide upon the point as to which operation is really the best, as the results have varied considerable. For instance, in some cases benefit has been produced in the sight by the second iridodesis, whereas in others again this has not been the case. The improvement is, however, never so conspicuous as after the first operation. My own experience rather tends to the opinion that on the whole the progress of the disease is most arrested and the bulging of the cornea most diminished by an iridectomy. Care must, however, be taken to make it only moderate in size, and perhaps slightly upwards and inwards, so that a part of the base of the artificial pupil may be covered by the upper lid. In slight cases, in which the conicity is either almost stationary or but very slowly progressive, I think iridodesis is indicated, whereas if it is considerable and markedly progressive, an iridectomy is to be preferred.

Von Graefe has lately published a very interesting case of conical cornea, in which he produced ulceration of the apex of the cone, and subsequent contraction and flattening of the cicatrix.* The fact that the

* "A. f. O.," 12, 2, 215. More recently Von Graefe has published an elaborate

cicatricial contraction which follows extensive ulcers or infiltrations of the cornea always produces a certain degree of diminution or flattening of the curvature of the cornea, led Von Graefe to the idea that a similar effect might be brought about in severe cases of conical cornea, by the artificial production of a little ulcer. The operation is to be performed in the following manner:—The point of a very small knife, made of the shape of Von Graefe's narrow cataract knife, but smaller in size, is to be passed into the middle layers of the cornea, just at the apex of the cone, to the extent of about a line, and then brought out again; so that a very small superficial flap may be formed, which is then to be seized with a very fine pair of forceps and snipped off at its base with a pair of curved scissors, thus leaving a superficial gap at this point. Great care must be taken that the knife does not penetrate the cornea, of which there is the greater risk on account of the extreme tenuity of the cornea at the apex of the cone. Should, however, perforation occur, the operation should be postponed for a few days, until the aperture is closed. The day after the operation, the floor of the gap is to be lightly touched, at two or three points, with a finely pointed crayon of mitigated nitrate of silver (nitrate of silver 1 part, nitrate of potash 2 parts), the effect of the cauterization being *at once* neutralized by the application of salt and water. The application of the caustic is to be repeated at intervals of from three to six days, until a slight faintly-yellowish infiltration is formed, with but a moderate degree of pericorneal injection, when we may consider the effect as sufficient, and simply apply atropine to the eye and guard it against exposure. The cauterization generally produces but very little irritation. Should the infiltration show a tendency to assume the character of a perforating ulcer, the compress bandage must be employed alternately with warm aromatic fomentations, and it may even be necessary to perform paracentesis. The improvement of the sight will not be at once apparent, indeed at first it may even be deteriorated, but at the end of five or six weeks, when the infiltration begins to contract, it rapidly increases, the little cicatricial opacity gradually diminishes in size and density, and leaves the sight greatly improved. Von Graefe has performed this operation with great success in several cases of severe conical cornea, and has gained much better results than from the formation of an artificial pupil.

11.—KERATO-GLOBUS (HYDROPHTHALMIA ANTERIOR, HYDROPS OF THE ANTERIOR CHAMBER).

This disease is characterised by a uniform spherical bulging of the whole cornea, so that it is increased in size in all its diameters.

and interesting paper upon this subject in the "Berliner Klinische Wochenschrift," 1868, No. 23.

Generally, however, this increase in size is not confined to the cornea, but extends to the neighbouring portion of the sclerotic. The augmentation in the size of the anterior half of the eyeball is often so considerable, that the eye protrudes between the palpebral aperture, and prevents the easy closure of the eyelids. On account of the peculiar staring appearance which this gives to the eye, the disease has also been termed "*buphthalmos*."

The cornea may either remain transparent or become slightly opaque near the periphery; in other cases the cloudiness may be more considerable, and extend over the greater portion of the surface of the cornea. The anterior portion of the sclerotic is much thinned and of a blue tint, which is due to a shining through of the choroid. The size of the anterior chamber is much increased, both in depth and circumference. The aqueous humour is generally clear. The iris is also enlarged, and the fibres near its ciliary margin are stretched and opened up; the pupil is generally somewhat dilated and sluggish, and perhaps here and there adherent to the capsule. The iris is often somewhat cupped back, which increases still more the depth of the anterior chamber, and it may also be tremulous, which may be either due to dislocation of the lens, caused by a stretching and giving way of its suspensory ligament; or to the iris being no longer in contact with the anterior surface of the lens, but divided from it by a collection of fluid in the posterior chamber. Sometimes, however, the iris is bulged forwards. The state of the sight varies very considerably. In some cases the patient can still decipher moderate sized print; in others it is greatly impaired, which may be due to the opacity of the cornea, or to inflammation of the deeper tunics of the eye.

The disease does not appear to be due to an increased secretion of the aqueous humour, but to a thinning and diminution in the power of resistance of the cornea, following generally upon severe and extensive inflammations of the cornea, as, for instance, vascular corneitis or pannus. The opacity may afterwards disappear, but the bulging remains, and even gradually augments. Treatment, unfortunately, is but too often of little avail. The most is to be expected from a large iridectomy. I have lately seen a case under Mr. Critchett's care in which this operation was performed with much benefit. The patient's general health should be strengthened, and the eyes be but moderately employed. If the protrusion is very considerable, the cornea opaque, and the sight almost entirely gone, an operation for staphyloma may be indicated, not only for the sake of appearance of the eye, but also to alleviate the inconvenience and constant irritation kept up by the incomplete closure of the eyelids.

12.—STAPHYLOMA OF THE CORNEA AND IRIS.

We have already seen that when an ulcer of the cornea causes perforation of the latter, the aqueous humour flows off, the iris falls forward, and may become adherent to the cornea. If the perforation is but of slight extent, an anterior synechia will be produced, without perhaps any bulging of the cornea at this point. But if the opening is large, a considerable portion of iris will fall against or into the gap, and perhaps protrude through it, giving rise to a more or less extensive prolapse. This is soon covered with a layer of lymph, which becomes organized, gradually assumes a cicatricial character, and replaces the cornea at this point, to which it may indeed bear a certain outward resemblance. It is, however, much weaker and less elastic, so that it readily yields to the intra-ocular pressure, gradually bulges forward, and gives rise to a partial staphyloma. If the latter is situated at the margin of the cornea, the pupil may remain partially or entirely free, and a certain amount of sight be preserved. But if the prolapse occurs in the centre, the whole pupil will be involved. A partial staphyloma may gradually increase in size until it implicates the surrounding cornea to a considerable extent, and if the perforation was originally of large size, it may, finally, even involve the whole cornea, and become changed into a total staphyloma. When the projection has become at all considerable, so as to protrude somewhat between the lids, its exposure to the action of external irritants is apt to produce occasional inflammatory exacerbations, which tend to cause a still greater increase in the size of the staphyloma.

The most frequent causes of partial staphyloma are sloughs and ulcers of the cornea, wounds and injuries, and also certain operations upon the eye, as for instance, flap extraction, which may be followed by considerable prolapse of the iris and the formation of a partial staphyloma.

No time should be allowed to elapse before the tendency to staphyloma is checked. Thus if a prolapse of the iris has occurred, it should be treated at once by the proper remedies. The best treatment for partial staphyloma is undoubtedly by iridectomy, as this, by diminishing the intra-ocular pressure, not only prevents the increase of the bulging, but generally also causes it to decrease in size. The artificial pupil should be made opposite to the most transparent portion of cornea. I must here again mention the very important fact that cases of partial or complete staphyloma are sometimes accompanied by marked increase of tension, so that the eye is in a glaucomatous condition, and the degree of impairment of vision quite disproportionate to the amount of staphyloma and opacity of the cornea. In such cases there will be

increase of tension, accompanied perhaps by contraction of the field, eccentric fixation, and excavation of the optic nerve. In all cases of staphyloma the degree of tension, the state of the sight, and of the field of vision must therefore be carefully watched, and an iridectomy must be on no account delayed if symptoms of glaucoma supervene. I think this treatment of partial staphyloma by iridectomy greatly preferable to that which was formerly much in vogue, viz., the touching the protrusion with nitrate of silver, and thus changing it into an ulcer which, on cicatrizing, would produce a flattening and shrinking of the staphylomatous tissue. This is apt to set up considerable irritation, and proves far less efficacious than an iridectomy. Partial abscission may also be performed by a modification of Critchett's operation.

13.—TOTAL STAPHYLOMA OF THE CORNEA AND IRIS.

This only occurs in cases in which there has been an almost total destruction of the cornea by sloughing or ulceration. Its shape is generally spherical, although occasionally it may be conical. The neighbouring portion of the sclerotic mostly becomes implicated in the process, and the staphyloma may, in time, involve the anterior half of the eyeball. The lens may either have escaped at the time of the perforation, or have remained behind, in which case it often becomes opaque. Its position within the eye varies; it generally lies in close contact with the iris and the cicatricial tissue, to which it becomes adherent; it may, however, be separated from the iris by a considerable amount of aqueous humour, which forms a large posterior chamber; or, again, it may have become detached from the suspensory ligament and sink down into the vitreous humour.

The presence or absence of the lens after an extensive perforation of the cornea exerts great influence upon the formation of a staphyloma. If the lens escaped at the giving way of the cornea, a firm cicatrix is formed, which will generally resist the intra-ocular pressure, and not bulge forward, but will often become consolidated, contract, and lead, perhaps, to a certain degree of shrinking of the globe. It is different, however, if the lens has remained within the eye, for it then bulges forward, and presses upon the newly formed cicatricial tissue, which gradually yields and becomes staphylomatous. If, therefore, a case of extensive perforation of the cornea, with a tendency to staphyloma, is seen at an early stage, and the lens is found pressing against the cicatrix, it is best to remove it at once, so as to allow the cicatrix to become firm and consolidated. The lens may be removed by making an incision into the staphyloma with Graefe's cataract knife, dividing the capsule, and allowing the lens to escape. Or, it may be done according to the following proceeding of Mr. Bowman, which I have

seen answer remarkably well in several cases. He passes a broad needle through the staphyloma into the lens, and breaks this freely up. The needle having been withdrawn, a curette is passed through the same opening, and the soft lens matter allowed to escape. The breaking up of the lens may be repeated at intervals of a few days. The staphylomatous protrusion will gradually subside, the cicatrix will become firm and consolidated, and the eye perhaps shrink somewhat. When all symptoms of irritation have subsided, an artificial eye may often be worn without the necessity of any further operation.

As we cannot restore any sight in cases of total staphyloma, the object of our treatment must be to remove the protrusion, so as to free the patient from the pain and inconvenience which generally attend this disease, and also to improve the personal appearance and permit of the adaptation of an artificial eye. There are numerous modes of operating for staphyloma, of which the following only require mention :—1, Excision. 2, Mr. Critchett's operation of abscission. 3, Graefe's seton operation. 4, Borelli's operation.

1. *Excision.*—This is best performed in the following manner. The point of a cataract knife (the edge of which is turned downwards, as in fig. 10), is to be passed into the sclerotic, near the edge of the staphyloma, and somewhat above its horizontal diameter, so that about $\frac{2}{3}$ of the staphyloma may be included in the incision. The blade of the knife is to be carried on parallel to the base of the tumour, until its point makes its exit at the opposite side, at a spot corresponding to the puncture. The knife should then be pushed slowly on, until it has cut its way out and divided the lower $\frac{2}{3}$ of the staphyloma, by a large flap-shaped incision. The remaining portion is then to be divided by the aid of a pair of scissors. A bandage is then to be applied, either together with water dressing or a simple pledget of lint. Lymph will be effused from the edges of the incision, and a more or less firm cicatrix result; the eyeball will shrink somewhat, but leave perhaps a tolerable good stump for the application of the artificial eye. The result of the operation is not, however, always so favourable. A considerable gush of vitreous humour may follow upon the excision of the anterior portion of the eye,

Fig. 10.

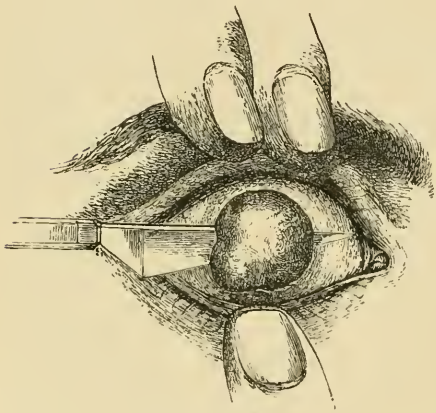

After Stellwag.

and intra-ocular hœmorrhage ensue. Or, again, suppuration of the eye may take place, accompanied, perhaps, by very violent pain and inflammation. The eyeball then shrinks and dwindles down, leaving but a very small and inefficient stump, with a slight degree of movement, for the application of an artificial eye. To obviate these disadvantages, Mr. Critchett has employed the following ingenious and valuable operation of abscission, which leaves an excellent, large moveable stump.

2. Mr. Critchett's* operation of abscission is to be performed thus: "The patient being placed under the influence of chloroform, the staphyloma is freely exposed by means of a wire speculum; a series of four or five rather small needles, with a semicircular curve, are passed through the mass, about equi-distant from each other, and at such points as the lines of incisions are intended to traverse (fig. 11). These needles are

Fig. 11.

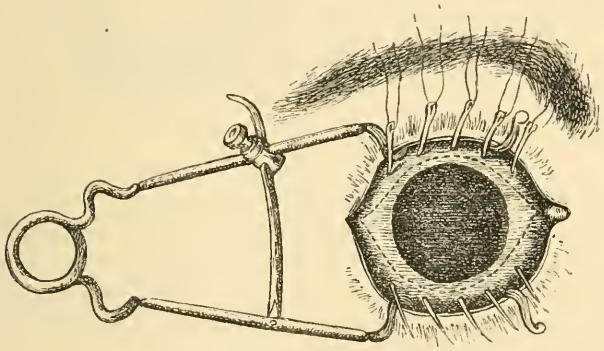

After Lawson.

left in this position, with both extremities protruding to an equal extent from the staphyloma. The advantages gained by this part of the proceeding are:—1. That a small quantity of the fluid parts of the distended globe escapes, thus diminishing pressure, and preventing a sudden gush of the contents, when the anterior part is removed. 2. That the points of emergence indicate the lines of incision. 3. That the presence of the needles prevents, or rather restrains, to some extent, the escape of the lens and vitreous humour, after the anterior part of the staphyloma has been removed. The next stage of the proceeding is to remove the anterior part of the staphyloma. This requires some judgment and modification in size and form, in accordance with the extent of the enlargement, so as to leave a convenient bulb. My usual plan is to make an opening in the sclerotic, about two lines in

* "Roy. Lond. Ophth. Hosp. Reports," iv, 1.

extent, just anterior to the tendinous insertion of the external rectus, made with a Beer's knife. Into this opening I insert a pair of small probe-pointed scissors, and cut out an elliptical piece, just within the points where the needles have entered and emerged. The needles, armed with fine black silk, are then drawn through each in its turn, and the sutures are carefully tied so as to approximate as closely as possible the divided edges of the sclerotic and conjunctiva (fig. 12).

Fig. 12.

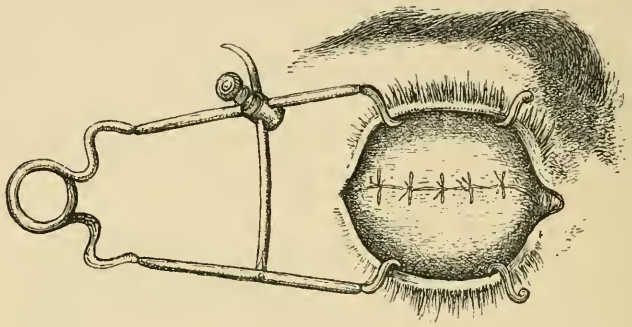

After Lawson.

The operation is now finished; the speculum may be removed so as to allow the lids to close, and wet lint may be applied to keep the parts cool. In a large majority of cases, union of the divided edges takes place by the first intention" . . . . "I generally leave the sutures in for some weeks. Sometimes they come away spontaneously, and when this is not the case, they may readily be removed after all irritation has passed away, and after firm union has taken place. If the case be examined three or four months after the operation, a moveable bulb is seen with a flattened anterior surface, traversed by a white line of cicatrix, and having rather a prominent external angle. Upon this an artificial eye can be readily adapted, which moves to a greater extent than I have observed previous to adoption of my present method."

Care must be taken in making the incision, so to slope and bevel off the angles that the lips of the wound here fit very accurately and neatly, otherwise an awkward pucker may be left at these points, which will interfere materially with the comfort of wearing an artificial eye. It is always best, except perhaps in young children, or where the staphyloma is small, to employ five sutures, in order that too great an interval may not be left between them, for if this be the case, beads of vitreous will protrude, become covered with granulations and suppurate somewhat. My experience of Mr. Critchett's operation has certainly been most favourable, and I can entirely endorse his state-

ment, that we gain by it a better and more perfectly moveable stump for an artificial eye, than by any other operation. I do not, however, think it indicated in those cases in which the disease is not confined to the anterior portion of the eyeball, but the inflammation has extended to the retina and choroid. For in such cases, the operation is not only often followed by perhaps immediate and severe intra-ocular hœmorrhage leading to suppuration of the globe, but we leave behind a part of the diseased structure, which may not only become again inflamed, but, what is still more to be dreaded, be the cause of sympathetic inflammation in the other eye. In all such cases, it is therefore undoubtedly by far the safest plan to remove the whole eyeball, as this frees us from all fear of sympathetic ophthalmia. If the patient is in good circumstances, and is so situated that he can at once apply to a surgeon if the stump becomes inflamed, or symptoms of sympathetic irritation show themselves, and if he is extremely anxious about his personal appearance, abscission may be performed, otherwise it is safest to remove the staphylomatous eye altogether. I must here state, that in the "Dublin Quarterly Journal of Medical Science" for 1847, Vol. iii., p. 242, Mr. (now Sir William) Wilde, drew attention to a new operation which he had devised for the removal of staphyloma. This consisted in the introduction of a curved needle through the base of the staphyloma, then removing the conical projection with a cataract knife and scissors, drawing the needle through, and tying the ligature. Sir William Wilde subsequently sometimes employed several ligatures.

3. *Von Graefe's** *operation by seton* consists in passing a double thread parallel to the cornea, through the coats of the eyeball (but not where they are thinned) and the vitreous humour, so as to include them within a suture to an extent of four or five lines. The threads are not to be tied tightly, but left in a loose loop, and their ends are to be snipped off close to the knot. A light compress is to be applied to the lids. Within 16 to 32 hours, acute symptoms of suppurative choroiditis generally supervene, accompanied by subconjunctival chemosis, slight immobility in the lateral movements of the eye, and perhaps a certain degree of protrusion of the globe. The threads are then to be removed, and warm camomile or poppy fomentations should be applied to alleviate the pain. The eyeball after a time becomes shrunk and atrophied. I have seen one case successfully treated by Mr. Bowman in a somewhat similar manner. The threads were, however, left in for some time and occasionally moved. There were no severe symptoms of inflammation, and the eye gradually diminished to about half its original size, and an artificial eye is now worn with comfort. The great advantage of this proceeding is that there is no tendency to sympathetic

* "Archiv. f. Ophthalmologie," ix, 2, 105.

inflammation, which appears never to ensue upon suppurative choroiditis.

4. Dr. Borelli transfixes the staphyloma by two needles, which are passed through the base of the protrusion, so as to cross each other at right angles. The one is entered at the temporal side, midway between the vertical and horizontal meridian of the cornea, passed beneath the tumour, and brought out at a corresponding point at the opposite side. This pin may be entered either above or below the horizontal meridian, as appears most convenient to the operator. The second pin is then to be introduced at right angles to the first, so that they form a cross (×). A thread is then passed round the staphyloma behind the pins, and tightly tied ; the ends may be twisted and fastened to the cheek. Simple cerate dressing and a compress bandage should be applied. At the end of the third day the protrusion, together with the pins and thread, are generally found to be detached, and on the eighth or ninth day the wound is firmly cicatrized. If the staphyloma is total or large, as little as possible should be included between the pins, and the threads should not be drawn too tight, lest the strangulated portion might give way, or severe ophthalmitis be set up. In partial staphyloma its whole base should be included, and the threads tied close and tight within the remaining cornea. I have had no personal experience of this operation, but it has been strongly recommended by several eminent surgeons, more especially for partial staphyloma, as it leaves a good portion of clear cornea behind which to make an artificial pupil. The operation is almost free from danger, and leaves, at the worst, a firm, moveable stump for an artificial eye.*

14.—INJURIES AND WOUNDS OF THE CORNEA.

Foreign bodies are frequently met with on the cornea, and amongst the most common are chips or splinters of iron, steel, wood, glass, etc., which have become lodged or impacted on the surface, or more or less deeply in the substance of the cornea. The presence of a foreign body on the cornea generally at once excites considerable reaction. The eye becomes flushed and painful, and this is accompanied by photophobia and lachrymation. There is a well-marked rosy zone around the cornea, and on account of the ciliary irritation the pupil is contracted. There is generally no difficulty in detecting the presence of a foreign body in the cornea, more especially if the former is dark (*e.g.*, a chip of steel or iron), and if the eye is turned sideways to the light. But if any doubt exists as to the presence and exact situation of a foreign body, atropine

* Vide an excellent description of this operation in the French Translation of Mackenzie's Diseases of the Eye, vol. iii, 1867.

should be applied, and the eye examined with the oblique illumination, and, if necessary, with the aid of a magnifying glass. The advantage of employing atropine is, that the dark background afforded by the widely dilated pupil throws the cornea into strong relief, and thus facilitates the detection of a foreign body, particularly if this be light coloured, as, for instance, a splinter of glass.

If the foreign body is situated superficially, and is early removed, no trace of its presence may remain. If, however, it has escaped detection, or the patient has not sought relief, and the foreign body is allowed to remain in the cornea, it may set up very considerable corneitis, and even iritis, accompanied, perhaps, with hypopyon. The cornea around the foreign body becomes infiltrated, and even a more or less extensive ulcer may be formed, or suppurative corneitis may supervene, with hypopyon, iritis, and sloughing of the cornea. This is often observed in aged and decrepid individuals, when a foreign body (*e.g.*, a portion of wheat ear, a splinter of glass) has become impacted in the substance of the cornea. In other and rarer instances, a layer of lymph surrounds and encapsules the foreign body, which remains innocuous in the very substance of the cornea. Sometimes a splinter of steel or iron passes partly through the cornea, and projects somewhat into the anterior chamber, lying half in the latter, and half in the cornea.

There is generally no difficulty in removing chips of steel, iron, or glass lodged upon the anterior surface of the cornea, close beneath the epithelial layer. As a rule, I always prefer to keep the eyelids apart with the stop speculum, and to fix the eye with a pair of forceps. By so doing we avoid all risk from any sudden movement or start of the patient, and can accomplish the removal of the foreign body very quickly and efficiently. The application of the speculum and forceps undoubtedly causes some degree of pain, but this is more than counterbalanced by the advantage of having the eye completely under our control. I have but too often seen that after numerous ineffectual and painful attempts to remove the foreign body, recourse had, after all, to be had to them. The patient should sit on a chair either directly facing the light, or if the foreign body can be better seen, with the face turned sideways towards it, and his head should lean back against the breast of the operator, who should stand behind him. Having applied the speculum, the surgeon steadies the eyeball with a pair of forceps, held in his left hand, and endeavours to remove the foreign body with the spud by passing the instrument behind it and thus lifting it out. If the foreign body is impacted deeply in the substance of the cornea, there arises the danger that in our endeavours to remove it we should push it further in, or cause it to perforate and fall into the anterior chamber. A broad needle should in such a case be carefully passed behind the foreign body, and this be lifted out. If it lies very near the

posterior wall of the cornea, the needle may be passed into the anterior chamber and the broad part of its blade pressed against that portion of the posterior wall of the cornea which is opposite the foreign body, so as to steady this, and then it may be removed with another needle or a very fine pair of forceps. A similar proceeding is to be adopted if the foreign body protrudes partly into the anterior chamber, for then an iridectomy knife or a broad needle should be passed into the latter and pushed behind the foreign body, gently pressing this back into the cornea; its anterior end should be seized with a pair of forceps, and in this way it may be readily extracted. If a bit of steel is situated on the surface of the cornea, it may also be removed with a magnet. After the removal of a foreign body from the cornea, a drop or two of castor-oil should be applied to the eye to lubricate the parts. Afterwards atropine should be applied, in order to allay the irritation. If the latter is considerable, and accompanied by severe ciliary neuralgia, cold compresses, and leeches are indicated, followed by warm poppy fomentations. The use of the eyes must be forbidden until all symptoms of irritation have subsided.

The effects which burns, injuries from quick-lime, molten lead, and chemical agents may have upon the cornea have already been described under the injuries to the conjunctiva (p. 81), and the same course of treatment is to be pursued as was advocated there.

Wounds of the Cornea.—The danger to be feared from these varies according to their extent, situation, and nature. It occasionally happens that a very superficial cut with a sharp instrument does not perforate the cornea, but simply penetrates into its substance, and forms a small flap, which may heal readily by the first intention, without leaving any trace. Thus a small, clean cut or puncture of the cornea frequently heals without leaving any mark behind, as is daily evidenced by operations upon the cornea, as, for instance, those for cataract, either performed with a knife or by the needle. The chief danger of penetrating wounds of the cornea is that they may cause considerable prolapse of the iris, or that they should implicate the iris and lens, and thus set up severe iritis or traumatic cataract. In such cases the condition not only of the cornea, but also of the iris and lens, must be carefully watched, for any implication of these structures of course greatly enhances the danger of the accident. Bruises of the cornea by blunt instruments also often prove very dangerous, as, on account of the contusion of the injured part and its vicinity, severe inflammation, perhaps of a suppurative character, is set up, which may even lead to suppuration of the cornea.

In the treatment of injuries or wounds of the cornea the first indication is to subdue the symptoms of irritation and inflammation. If there is great pain, cold compresses should be sedulously employed, or

a few leeches should be applied to the temple, followed by hot poppy fomentations, so that free after-bleeding may be encouraged. A strong solution of atropine should be prescribed, the compound belladonna ointment be rubbed over the forehead, and a light, though firm compress bandage be applied, in order that the parts may be kept perfectly at rest. If the symptoms of inflammation do not readily yield to such treatment, the eye should be again most carefully examined in order that it may be ascertained whether a little foreign body has not remained undetected in the cornea, anterior chamber, or iris. The various complications, such as prolapse of the iris, iritis, traumatic cataract, etc., must be treated according to the general rules laid down in the sections in which these affections are described. If an incised wound is situated partly in the cornea and partly in the sclerotic, it occurs sometimes that the portion in the latter situation does not heal readily, and that a little fistulous opening may remain. In such cases the treatment is to unite the wound in the sclerotic by means of one or two fine sutures, according to its extent. This will keep the lips of the incision in contact, plastic lymph will be effused, and a firm union will soon be effected. The thread should carry a needle at each end, so that we may be able to insert the suture into the sclerotic from *within outwards*, otherwise a sudden start of the patient might cause the point of the needle to penetrate the eye.

Tumours of the cornea are very rarely indeed met with as originating in the tissue of the cornea itself, and almost always pass over on to it from the conjunctiva. The dermoid tumour is of most frequent occurrence, and has been already described at length in the article upon tumours of the conjunctiva (p. 84). Stellwag* describes a case of primary cancer of the cornea, and this is, I believe, the only case of the kind on record.

* "Die Ophthalmologie vom naturw. Standp." I, 347.

Chapter III.

DISEASES OF THE IRIS.

1.—HYPERÆMIA OF THE IRIS.

Hyperæmia of the iris is of far more frequent occurrence than is generally supposed. Nor can we be surprised at this when we remember the close connection which exists between the iris and cornea on the one hand, and the iris, ciliary body, and choroid on the other. Indeed, we may regard the iris as the anterior termination of the ciliary body and choroid, the whole forming, in reality, one tissue, the uveal tract. Hence the frequency with which inflammation of the iris extends to the ciliary body and choroid, and *vice versâ*. In a hyperæmic condition of the iris, we find that there is more or less marked subconjunctival injection; that the pupil is somewhat contracted and sluggish, not re-acting freely on the application of atropine; and that the iris is discoloured, which is due to the increased vascularity imparting a reddish tint to the natural colour of the iris. Thus a blue iris will become somewhat green, and a brown iris assume a slight admixture of red.

All causes which produce congestion of the deeper tunics of the eye may excite hyperæmia of the iris. Of these the most frequent are over-exertion of the eyes in reading, engraving, etc., and inflammatory affections of the choroid, ciliary body, and cornea. But this condition may even be produced in acute granular ophthalmia, if this is injudiciously treated by caustics and strong astringent collyria.

The treatment must be chiefly directed towards a removal of the cause, and an alleviation of the irritation; hence strict and prolonged rest of the eyes should be enforced, and they should also be guarded against exposure to strong light, cold, etc. Atropine should be applied to diminish the irritability of the eye.

2.—INFLAMMATION OF THE IRIS.

In iritis there are superadded to the symptoms of hyperæmia of the iris those of an effusion of plastic lymph at the edge of the pupil, or on the surface and into the stroma of the iris.

Formerly the inflammations of the iris were classified according to the dyscrasiæ of which they were supposed to be pathognomonic, and a formidable array of different forms of iritis was in this way established. By chiefly basing our classification on pathological anatomy, we can, however, greatly simplify the subject and so embrace all shades of iritis within the following four groups. 1. Simple idiopathic iritis. 2. Serous iritis (Descemetitis, etc). 3. Parenchymatous iritis. 4. Syphilitic iritis.

In order to avoid unnecessary repetition, I shall first describe the various symptoms which more or less accompany all inflammations of the iris, and then call attention to those which characterise the special forms.

Amongst the earliest symptoms of iritis are conjunctival, and especially subconjunctival injection, ciliary neuralgia, contraction and sluggishness of the pupil, and a discoloured, dull, lack-lustre appearance of the iris.

There is generally some injection of the conjunctiva, which may be chiefly confined to the palpebral portion, or extend also to the ocular conjunctiva in the vicinity of the cornea. But a far more constant symptom is the subconjunctival vascularity, giving rise to a more or less broad rosy zone of parallel vessels, closely ranged round the cornea. This zone is generally of a bright rose colour, and consists chiefly of small arterial twigs. It may, however, assume a somewhat blue or brownish tint. The latter was formerly erroneously supposed to be symptomatic of syphilitic iritis. Although marked subconjunctival injection is present in the great majority of cases of iritis, we occasionally meet with severe cases in which it is not very conspicuous, as in typhus fever, pyæmia, etc. (Stellwag). There is also more or less chemosis, and this may be so considerable that the conjunctiva is raised like a red or bluish-red mound round the cornea. The eyelids are often also swollen and puffy. In the milder cases they may retain their normal appearance, but if the attack is severe, the upper lid generally becomes red, glistening, and very œdematous and swollen. This is more especially the case in suppurative iritis or irido-cyclitis.

The intensity of the pain is very variable, for although it is generally severe, and often extremely so, it may in some cases be nearly entirely absent. The patient may at first only experience a feeling of itching and burning in the eye, but soon the pain becomes more severe, and assumes a sharp, cutting, lancinating character. It may be chiefly situated deeply in the eyeball, or extend to the forehead, temple, and corresponding side of the nose (ciliary neuralgia). Sometimes there is very intense neuralgia of the branches of the fifth nerve, extending over the corresponding side of the face and head, even as far as the occiput. The pain always increases in intensity towards evening,

remaining very severe during the night, and diminishing towards morning. Although the patient may experience very acute pain in iritis, it is important to remember that the eye is not painful to the touch in a case of simple uncomplicated iritis. If sharp pain is caused when the ciliary region is pressed by the finger, it is indicative of the co-existence of inflammation of the ciliary body (cyclitis). Very frequently this tenderness is partial, and confined to the upper portion of the ciliary region.

The severity of the pain may give rise to some constitutional disturbance, and the exacerbations be accompanied by feverishness, a loaded tongue, impairment of appetite, and a tendency to retching and vomiting, which not unfrequently causes the disease to be mistaken for a severe bilious attack.

Although considerable photophobia and lachrymation may accompany iritis, they are seldom so severe and marked as in certain forms of corneitis.

We now come to the symptoms presented by the iris itself. Amongst the earliest are discoloration and dulness of the iris, and contraction of the pupil. The discoloration of the iris is partly due to hyperæmia and partly to an effusion into its structure. In order to estimate rightly the changes in colour, we must always compare the affected with the other eye (if this be sound), otherwise an error may easily occur. We must also be upon our guard not to mistake the dullness and change in the tint of the iris, which may be produced by cloudiness of the cornea and of the aqueous humour, as being resident in the iris itself. Besides the discoloration, the iris presents a peculiar dull, lack-lustre appearance, its surface having lost its natural bright, glistening aspect, and appearing hazy and dull, as if covered by a fine veil. Its fibrillæ are also not sharply defined, but indistinct and blurred. This depends in a great measure upon the hypertrophy of the connective tissue elements of the iris, and upon the effusion of lymph into the stroma and upon the surface of the iris.

The pupil is sluggish and more or less contracted. This generally occurs in all but the very slightest cases of iritis, or in those in which there is a tendency to increase in the intra-ocular tension. This immobility of the pupil is partly caused by the hyperæmia of the vessels, but chiefly by the serous or plastic effusion which has taken place into the stroma of the iris, and impedes the action of the circular fibres of the iris. If the inflammation is but partial, the immobility of the pupil may be the same. In testing the mobility of the pupil, the patient should be placed so that the light falls sideways upon the eye. The other must be firmly closed with our hand, or by a handkerchief. The affected eye is to be shaded with the palm of our hand, which is then to be rapidly removed so as to admit the light, and the behaviour of the pupil accu-

rately watched, so that its size, mobility, and the extent of its contractions may be ascertained. It must be remembered that contraction and impaired mobility of the pupil may exist without any iritis; for it may be seen in corneitis, hyperæmia of the iris, or if a foreign body is lodged on the cornea, and is in these cases due to irritation of the ciliary nerves.

The edge of the pupil generally soon loses its circular form and becomes somewhat irregular, and we may notice along it small exudations or beads of plastic lymph, which tie it down to the anterior capsule. These may, however, be so minute as to escape detection until the pupil is examined with the oblique illumination, or atropine is applied. The individual exudations often increase in size and coalesce, and, more lymph being effused, the whole circumference of the pupil may become fringed with them and be tied down to the capsule of the lens, the centre of the pupil perhaps remaining clear and thus still permitting of good vision. This condition is termed "*circular*" or "*annular*" synechia, or "*exclusion of the pupil.*" We must distinguish this from the condition in which the effusion invades the area of the pupil, so that a more or less considerable portion of it is covered by a film of lymph, or even the whole of it occluded by a thick nodule of exudation, the sight being of course proportionately deteriorated; this is called *occlusion* of the pupil. The exudation of lymph between the iris and the capsule of the lens is not always limited to the edge of the pupil, but may extend further back along the posterior surface of the iris, and thus produce broad and very firm adhesions. We shall see hereafter, that this fact is of great importance in the performance of iridectomy for chronic iritis or irido-choroiditis. The partial adhesions between the pupil and capsule vary greatly in thickness, extent, and number, and become very apparent when atropine is applied, as they then give rise to various irregularities in the shape of the pupil.

The surface of the iris may become covered with a film of exudation, or the lymph may mix with the aqueous humour and render this turbid and clouded; or it may be precipitated against the posterior wall of the cornea in the form of small whitish opacities; or again, it may sink to the bottom of the anterior chamber, where it collects in the form of an hypopyon. The amount of this yellowish deposit varies; it may be so slight as easily to escape detection, appearing simply like a small yellow fringe along the lower edge of the anterior chamber; or it may attain such a size that it fills half or even more of the anterior chamber.

In simple iritis the cornea is generally quite transparent, or shows but the faintest amount of cloudiness. Small portions of lymph may, however, be deposited from the aqueous humour upon the posterior wall of the cornea, giving rise to a punctated appearance. This occurs especially

in the serous form of iritis. But the cornea may, also, become implicated in the inflammatory process.

Vision is often considerably impaired. This may be partly due to the cloudiness of the aqueous humour and of the area of the pupil. If the sight is much affected and the pupil not occluded, we must suspect the co-existence of cyclitis, which is often accompanied by diffuse opacity of the vitreous humour. The power of accommodation is then, moreover, also affected. It is, therefore, very necessary accurately to test the degree of vision at the commencement of an iritis, in order that we may at once detect any marked deterioration, and ascertain to what cause this is due. The tension of the eyeball is normal in a case of common iritis, and the field of vision, although it may be somewhat contracted on account of the smallness of the pupil, or the presence of synechiæ, does not show the contraction peculiar to a glaucomatous condition of the eye.

We must now consider the symptoms by which the special forms of iritis are characterised.

1. *The Simple Idiopathic Iritis* is sometimes very slight in degree, and accompanied by only a very moderate amount of subconjunctival injection, photophobia, pain, or discolouration of the iris; indeed, its existence may remain quite unsuspected until atropine is applied, when the pupil is found to be irregular, and shows here and there a slender adhesion to the capsule. This mild form of iritis is often met with after operations upon the eye (*e.g.*, cataract operations), or after injuries. The affection may, however, be more severe, and there is much pain, swelling of the lids, injection of the conjunctiva and subconjunctival tissue, chemosis, photophobia, and lachrymation. The iris is discoloured, the pupil contracted and inactive, having deposits of lymph at its edge and perhaps also in its area. A film of exudation covers the surface of the iris, rendering it dull and hazy, the aqueous humour is somewhat turbid, and the posterior surface of the cornea perhaps mottled with small deposits of lymph.

2. *Serous Iritis* (syn. Descemetitis, aquo-capsulitis, keratitis punctata, etc.) is chiefly distinguished by the absence of plastic exudation, and by the great tendency to hypersecretion of the aqueous humour. The symptoms of acute iritis are generally not very pronounced. The aqueous humour is secreted in greater quantity, and is somewhat clouded and turbid, and on closer observation we can often notice small particles of lymph floating about in it, before becoming deposited on the posterior surface of the cornea, or at the bottom of the anterior chamber. The latter is often markedly deepened, and the cornea appears somewhat bulged forward. The cloudiness of the aqueous humour often varies considerably and rapidly within the course of a few hours. The cornea may at first appear abnormally brilliant, but it soon loses its lustre and

becomes slightly clouded, and small punctated opacities make their appearance upon its posterior surface. These are sometimes situated opposite the pupil and are grouped in a small circle; but they are generally arranged in the form of a pyramid, the base of which is turned towards the periphery of the cornea, and its apex towards the centre. The smaller opacities being situated at the apex and the larger and coarser ones at the base. This proves that the opacities are composed of small masses of lymph, deposited from the aqueous humour upon the posterior wall of the cornea, and that they arrange themselves according to their size and weight, the larger and heavier ones gravitating downwards. The truth of this assertion has moreover been proved experimentally by Arlt. He placed the head of the patient in different directions, sometimes keeping it for a length of time turned to the right side, sometimes to the left, and he found that the base of the pyramid always corresponded to the side of the eye which had been maintained in the lowest position. But some of the opacities met with at the posterior portion of the cornea are not due to these deposits from the aqueous humour, but are caused by inflammatory changes in the epithelial layer, or even in the posterior portion of the cornea proper.

The iris is but slightly discoloured, and the pupil, instead of being contracted, as is generally the case in iritis, is somewhat dilated, often markedly so. This is due to an increase in the intra-ocular tension, which is often present in this disease, and the manifestation of which must be watched with the greatest care, for this serous form of inflammation shows a great tendency to extend to the ciliary body and choroid, which is accompanied by an hypersecretion of the vitreous humour, marked increase in the intra-ocular tension, and a glaucomatous condition of the eye. The degree of eye tension, the state of the sight and of the field of vision must, therefore, be frequently and carefully examined during the course of the disease, in order that the earliest symptoms of a glaucomatous complication may be detected and at once arrested. Adhesions between the edge of the pupil and the capsule are not of frequent occurrence in this form.

Serous iritis occasionally accompanies deep-seated inflammations of the eye, more especially chronic irido-choroiditis, and choroido-retinitis. Moreover, sympathetic ophthalmia sometimes appears in the form of serous iritis. It has also been supposed to be due to constitutional or hereditary syphilis.

3. *Parenchymatous or suppurative iritis.*—In this affection the inflammation attacks the tissue of the iris, and its fibrillæ become much swollen and thickened. The plastic exudation is poured out into the parenchyma of the iris, along the edge and into the area of the pupil, and also on the posterior surface of the iris, giving rise to thick broad adhesions between it and the capsule of the lens. On account of the

exudation into the stroma of the iris, and the swollen and thickened condition of its fibrillæ, the circulation is generally considerably impeded, and large tortuous veins make their appearance on its surface. Along the edge of the contracted pupil are noticed a number of thick firm nodules of exudation, of a creamy or reddish-brown colour, tying down the edge of the pupil to the capsule; or they may even extend around the whole edge of the pupil, and thus give rise to a circular synechia (exclusion of the pupil). The effusion generally also invades the area of the pupil, indeed the latter may be completely blocked up by a thick yellow nodule of purulent exudation. The surface of the iris appears indistinct and hazy, its fibrillæ are swollen, and its anterior surface is covered by a layer of exudation which varies considerably in appearance. In some cases it looks simply like a thin grey veil covering different portions or even the whole of the iris, in others it assumes a thick, creamy, purulent appearance, with small extravasations of blood scattered about here and there. Little yellow nodules (which are not to be confounded with the syphilitic tubercles) may also appear strewn about on the surface of the iris. On account of the detachment of some of these nodules, and the effusion of lymph and purulent exudation into the aqueous humour, the latter becomes turbid and discoloured. Flakes of purulent lymph and globules of pus are seen floating about in it, and sinking down, give rise to an hypopyon, which may be so small as to appear only like a narrow yellow belt along the lower edge of the anterior chamber, or may be so considerable as to occupy one-half or more of the anterior chamber, reaching perhaps above the upper edge of the pupil. This parenchymatous or suppurative iritis, may be accompanied by a similar form of inflammation of the ciliary body and choroid.

4. *Syphilitic iritis* generally assumes the parenchymatous form. It is, however, especially characterised by the formation of peculiar tuberculous nodules (gummy tubercles, Virchow). These are scattered about singly over a certain portion, or even the whole, of the surface of the iris, in the form of yellowish-red condylomatous nodules. They appear at first deeply imbedded in the parenchyma of the iris (originating in the deeper portion of its connective tissue), and as they increase in size, they push aside the fibrillæ of the iris, and protrude between them into the anterior chamber. They may attain a very considerable size, their apex even touching the posterior wall of the cornea. They (according to Colbert) exactly resemble in structure the gummy tubercles (gummata) of Virchow. On account of the presence of pigment cells, and the great vascularity, the nodules frequently assume a dark reddish-brown sarcomatous appearance. They often undergo fatty and purulent degeneration, breaking down into a yellow grumous, purulent mass, which becomes mixed with the aqueous humour. They may, however,

undergo rapid absorption. These tubercles, or condylomata as they are sometimes called, frequently remain confined to one portion of the iris, in which the inflammatory changes are moreover also more pronounced, so that the disease assumes a somewhat partial character, which is peculiar to the syphilitic form. We find, in such cases, that although the whole cornea may be surrounded by a pink zone of vessels, that this is most pronounced at one point, and that the corresponding segment of iris is the most thickened and swollen, and that the condylomata are chiefly or entirely confined to this portion.

It must be distinctly remembered that, although the name of syphilitic iritis is given to the form of inflammation above described, the iritis which may occur in the course of, and be entirely due to, syphilis, does not necessarily always assume this type. For it may appear as a simple idiopathic iritis, or in a more or less severe parenchymatous form, so that the absence of the peculiar gummy tubercles does not exclude the presence of syphilis in the system, or its being the cause of the iritis. But on the other hand, the existence of these tubercles may, in the vast majority of cases, be taken as a certain indication of the syphilitic nature of the inflammation. I can only remember having seen one case (a patient of Mr. Critchett's) in which there were well marked condylomata without the slightest evidence of syphilis. Some authors have stated that in syphilitic iritis the circumcorneal zone of injection is of a brownish tint, and that the pupil is displaced upwards and inwards. This is, however, not the case, for both these appearances may be met with apart from syphilis.

Amongst the *causes* of iritis, a very frequent one is exposure to sudden changes of temperature, cold draughts of air, rain, wind, etc. The disease is, in such cases, often termed rheumatic iritis. It may also accompany rheumatism in other parts of the body, being evidently produced by the same cause. It is erroneous, however, to speak of rheumatic iritis as a special form of the disease, for it has, in truth, no characteristic symptoms; it generally assumes the form of simple iritis, and may vary greatly in severity, but is not, as a rule, accompanied by extensive exudative changes in the parenchyma of the iris, or by considerable hypopyon. The pain is frequently extremely severe, and may extend over the corresponding side of the head and face. The disease often runs a chronic and very protracted course, and relapses may take place on a recurrence of the rheumatic attack.

Iritis is also often of *traumatic origin*, being caused by mechanical or chemical injuries, which either affect the iris directly or secondarily. Thus, foreign bodies may remain lodged for some time in the conjunctiva, cornea, anterior chamber, or in the deeper tunics of the eye, and then set up iritis. Clean incised wounds of the iris are not prone to give rise to it, as is proved by the operation of iridectomy, nor does

strangulation or compression generally do so, as is evidenced by iridodesis. Wounds which bruise and lacerate the iris are the most apt to set up iritis. Injury of the lens, followed by traumatic cataract, very often produces it, more especially if the iris has been implicated in the injury, or the lens swells up very considerably and presses upon the iris. It also often supervenes secondarily upon other inflammations of the eye. Thus corneitis, especially the diffuse and suppurative forms, and deep or perforating ulcers of the cornea, are frequently accompanied by iritis; this is still more the case in inflammations of the choroid and ciliary body.

Syphilis is a very frequent cause. When primary iritis occurs in infants or young children, it is almost always due to syphilis, and in such cases we generally meet with other symptoms pathognomonic of the syphilitic taint, such as condylomata about the anus, specific eruptions, etc. In adults it but seldom occurs together with the primary symptoms, but generally during the secondary or tertiary stage, being often the precursor of these symptoms, when the primary have disappeared. The iritis frequently occurs simultaneously with the syphilitic eruptions of the skin.

Some authors have asserted that gonorrhœa is sometimes the cause of iritis. Thus, Mackenzie* describes a special form, under the name of "gonorrhœal iritis." Mr. Wordsworth† has also narrated three cases in which iritis occurred together with gonorrhœa. It must, however, be stated that all three were complicated with rheumatism. I have myself never met with a case of iritis associated with gonorrhœa alone; but have only observed it in cases in which the gonorrhœa co-existed with syphilis or with rheumatism, either of which diseases, as I have already stated, is a frequent cause of iritis. Nor does the so-called "gonorrhœal iritis" present any special or pathognomonic features.

Sympathetic inflammation of the iris is apt to occur after injuries to the eye, or the lodgment of a foreign body within it, etc. The sympathetic iritis may assume the serous character, but generally appears in the form of suppurative irido-choroiditis. (*Vide* article on "Sympathetic Ophthalmia.")

Chronic iritis is especially distinguished by the fact that the inflammatory symptoms are generally but slightly marked, or are almost so entirely absent that the patient is not aware that there is anything the matter with his eye, except a slight weakness or "cold" in it, as he frequently expresses it. The ocular conjunctiva and subconjunctival tissue are but slightly injected; there is only a faint pink blush around the cornea; there is but little photophobia, lachrymation, or ciliary neuralgia. The pupil is somewhat contracted and sluggish,

* "Mackenzie on Diseases of the Eye," 552.

† "R. L. O. H. Rep.," iii, 301.

and, at certain points, perhaps immoveable. On examining it with the oblique illumination, we may frequently notice small adhesions between the edge and the capsule, which, as well as the irregularity of the pupil, become very evident upon the application of atropine. The colour of the iris becomes gradually more changed, and this alteration in its tint is permanent, whereas in acute iritis it passes off again with the subsidence of the disease, without, perhaps, eventually leaving any trace behind. The normal brightness and lustre of the iris become faded and dulled, its fibrillæ indistinct and obliterated, and in the later stages of the disease it presents a yellowish-grey, dirty-brown, or slate-coloured appearance, its tissue being thinned and atrophied, and traversed, perhaps, by enlarged and somewhat tortuous blood-vessels. The presence of such dilated vessels always indicates a state of congestion and stasis of the circulation in the iris and ciliary body. At this advanced stage the iritis is generally, however, no longer simple in character, but has become complicated with inflammation of the ciliary body and choroid. (*Vide* the article on "Irido-choroiditis.")

Chronic iritis may supervene upon a more acute form of iritis, or the disease may manifest this chronic and insidious character from the very outset. It also frequently accompanies inflammations of the cornea, more especially the diffuse corneitis. Relapses are very apt to occur in chronic iritis; these recurrent inflammatory exacerbations being often produced by very slight causes, such as undue use of the eyes, particularly by artificial light, exposure to cold, wet, etc. This tendency to recurrence is especially marked in those cases in which numerous or extensive posterior synechiæ exist. For their presence is a constant source of irritation and teasing, as they prove a check to the free, spontaneous movements of the pupil, and in such cases a slight cause will suffice to rekindle the inflammation. During the recurrence of the inflammation, fresh lymph will be effused, and the posterior synechiæ will increase still further in number and firmness, until finally, after perhaps frequent relapses, the whole circumference of the pupil is firmly tied down to the capsule, and the communication between the anterior and posterior chamber is completely interrupted. It will be seen hereafter that such an exclusion of the pupil (circular synechia) is one of the most frequent causes of irido-choroiditis.

The *prognosis of iritis* will depend very much upon the severity and the cause of the inflammation. If the disease be seen at a very early stage, before any adhesions have been formed between the edge of the pupil and the capsule of the lens, or whilst these are yet so slight and brittle, as to be readily torn through by the energetic use of atropine, the prognosis is in every way very much more favourable than if numerous firm posterior synechiæ have already been established, and resist the action of atropine. Parenchymatous and syphilitic iritis, which are

generally accompanied by very considerable exudations of lymph at the edge of the pupil, on the surface and into the structure of the iris, and into the anterior chamber, afford a less favourable prognosis than the simple or serous iritis. The tendency to implication of the cornea, or the deeper tunics of the eyeball must also be borne in mind. In traumatic iritis, the nature and extent of the injury, the presence of traumatic cataract, or the co-existence of inflammation of the ciliary body or choroid must all be taken into consideration in framing the prognosis.

Treatment.—The patient should be carefully guarded against the injurious influences of bright light, and sudden changes of temperature, as well as cold and wet. Perfect rest of both eyes must also be enjoined, and if the patient has to leave the house, a bandage should be placed over the affected eye, and a shade over the other, or goggles should be worn. But if the disease is very severe, strict orders must be given that the patient is to keep in a darkened room. We are, however, very frequently obliged to treat even severe cases of iritis as out-patients, and may even in such instances frequently succeed in affecting an excellent cure. This mode of treatment should however only be adopted from necessity, and not from choice, and strict injunctions should be given to the patients to guard their eyes as much as possible against all noxious influences during the intervals of their visits.

The point of the very greatest importance in the treatment of iritis is to obtain a wide dilatation of the pupil as soon as possible, and hence a strong solution of atropine should be at once energetically applied to the eye. The beneficial effect of atropine is three-fold:—1. Wide dilatation of the pupil is produced, and the iris is, therefore, removed from the contact with the anterior capsule of the lens, so that no adhesions can be formed between them at the edge of the pupil, or on the posterior surface of the iris. Thus one of the chief dangers of iritis, the formation of extensive posterior synechiæ, is prevented, and the numerous evil consequences or dangerous complications to which they may give rise, are obviated. 2. Rest will be afforded to the inflamed muscular tissue of the iris by a wide dilatation of the pupil; for if the constrictor pupillæ is not paralysed, its constant action in endeavouring to regulate the size of the pupil according to the stimulus of light, must of necessity tend to increase the inflammation, just as would be the case in any other inflamed muscular tissue, if this could not be kept perfectly at rest. 3. The tension of the eye will be diminished, and the intra-ocular circulation relieved, which will diminish the state of congestion of the iris and ciliary body. Moreover, the irritation of the eye and the ciliary neuralgia will generally be alleviated in a very marked manner. It is, however, absolutely necessary that the solution of atropine should be of a sufficient strength, and should be energetically employed. In

the normal condition of the eye, an extremely weak solution (gr. j.—℥viij of water) will suffice to produce a wide dilatation of the pupil, but in iritis it is very different. On account of the inflamed and swollen condition of the tissue of the iris, of the lymph effused into its meshes, and of the hyperæmia, great resistance is offered to the action of the atropine; hence a very strong solution must be used, and the application repeated very frequently before we can thoroughly overcome this resistance. I am in the habit of employing a solution of from four to six grains of atropine to the ounce of water, and of applying it at the interval of five minutes for half-an-hour at a time, this being repeated, if necessary, three or four times a-day, so that altogether the atropine may have to be applied from eighteen to twenty-four times a-day, in order to produce and maintain a sufficient dilatation of the pupil. If the case is seen early, before any adhesions, or only very slight and brittle ones, are formed, we may generally succeed in producing a wide dilatation at the end of a few hours, and then it is not difficult to maintain it. I find that patients apply the atropine with much greater regularity and exactitude, if they are told to use it for half-an-hour at a time, at intervals of five minutes, and to repeat this at stated periods, three times a-day, than if they are only directed in general terms to apply it fifteen or eighteen times a-day. As we have frequently at the hospital to treat even severe cases of iritis as out-patients, I invariably apply the atropine myself at the interval of a few minutes, until either a decided effect has been produced upon the pupil, or the result is negative. In the former case, the patient will himself experience the great relief to the pain and irritability of the eye which has been produced by the instillations, and will readily and gladly carry out the treatment with regularity at home. Moreover, the dilatation thus effected can generally be maintained until the next visit, even if the remedy is not applied in the interval quite as frequently as directed. I have often been able to treat even severe cases of iritis with great success by this simple means, without the employment of almost any other remedy, except perhaps the use of warm poppy fomentations; the result being a perfectly circular pupil without any, or only the very slightest adhesions. I would again, therefore, urge in the very strongest terms the energetic use of atropine in iritis, a line of treatment at present, unfortunately, but too much neglected in English ophthalmic practice, the evil results of which neglect are constantly evidenced by the numerous cases of recurrent iritis, chronic irido-choroiditis, etc., which we but too frequently meet with, and which might have been to a very great extent prevented by the early and efficient use of atropine. It is quite useless to prescribe a weak solution of atropine (gr. ss—j. ad ℥j) to be used a few times in the course of the day; this cannot produce a dilatation of the pupil when the tissue of the iris is inflamed, its effect will be

nil, as can be easily seen by watching the state of the pupil in cases where such weak solutions are employed.

But we sometimes find that the action of even a strong solution of atropine, frequently applied, is resisted, and that it produces little or no effect, and increases rather than diminishes the irritability of the eye. In such cases its use must be desisted from until the irritation is relieved by the application of a few leeches to the temple, or perhaps by paracentesis of the anterior chamber. This relief of the inflammatory irritation and intra-ocular tension, permits of a freer absorption through the cornea, and hence the effect of atropine will now be often very marked and rapid. This effect, as Von Graefe has pointed out, is sometimes noticed without the re-application of the remedy. Thus atropine may have been applied in cases of iritis or corneitis without producing any dilatation of the pupil, but many hours afterwards this has ensued after the application of leeches. We sometimes notice, also, that although dilatation of the pupil may have been produced, yet that it cannot be thoroughly maintained, the atropine appearing to lose its effect. In such cases it will be found that this likewise is due to the great irritation of the eye and the increase in the intra-ocular tension, which prevent the absorption of the remedy through the cornea. Whereas, after the application of leeches or the performance of paracentesis the atropine will again regain its power over the iris. I need hardly mention, that if the pupil is firmly tied down by numerous and thick adhesions, the atropine should be applied only in moderation in order to soothe the irritability and diminish the tension of the eye. But if the posterior synechiæ are of recent origin, and not very broad and firm, but narrow and tongue-like, the long continued use of atropine often succeeds in tearing them through. But it is often found that when this remedy is employed for a considerable length of time it increases instead of allaying the irritability of the eye, and may even induce conjunctivitis or acute granulations. The latter are, however, less frequently met with, than a vascular condition of the lids accompanied by swelling of the conjunctiva and great irritation of the eye. In such cases the atropine must be stopped at once, and a mild astringent collyrium substituted for it. The strength and nature of the latter must vary with the degree of conjunctivitis. A solution of gr. j of alum, zinc, or nitrate of silver to the ounce of water will be found the best. In vesicular granulations a collyrium of vj to x grains of borax to 1 ounce of water often proves of much service. The irritability of the eye may also be allayed and the dilatation of the pupil tolerably maintained by the use of a collyrium of belladonna (Ext. Bellad. ʒss Aq. dist. ℥j), which is to be applied frequently in the course of the day. It is sometimes found that posterior synechiæ, which resist the action of atropine, soon tear through upon the application of

Calabar bean. Hence this remedy may be tried alternately with the atropine.

The use of atropine is to be continued even for some weeks after the subsidence of the iritis, so that the wide dilatation of the pupil may be maintained and the iris be kept in a state of rest. It has been urged by some, that the long continued use of a strong solution of atropine is apt to produce a permanent dilatation of the pupil from paralysis of the sphincter pupillæ. But this is a most rare and exceptional occurrence, and if any tendency to dilatation should remain, it may be easily overcome by the occasional use of the Calabar bean, which excites the action of this muscle. Although I am in the habit of using atropine most extensively in the treatment of iritis and other affections of the eye, I have never met with a case in which this condition of permanent dilatation was produced, nor have I ever observed a case of poisoning from the excessive use of atropine. Such cases do, however, sometimes occur, and are evidently produced by the passage of the atropine through the lachrymal puncta to the throat. The principal symptoms of poisoning by atropine are :—great increase in the frequency of the pulse, dryness of the throat, dysphagia, great irritability of the bladder and genital organs, impairment of memory, hallucinations, and exciting dreams. The pupils of the eyes are very widely dilated. Generally, these symptoms are only moderate in character when the poisoning has occurred in the mode above described, but their severity is very great if the atropine has been swallowed by mistake, and a considerable dose has thus been taken. The best and most rapid antidote is the subcutaneous injection of morphia* (gr. $\frac{1}{5}$ or $\frac{1}{4}$ of a grain), to be repeated, if necessary,—even several times—at intervals of a few hours. The effect of the remedy is very marked and rapid; within a few minutes the violence of the symptoms has greatly subsided, and the patient is calm and quiet. To avoid the danger of poisoning when strong collyria of atropine are used with great frequency, Von Graefe recommends the patients to close the eye directly after the application, and subsequently on re-opening the eye to wash it well. He also sometimes employs a subcutaneous injection of morphia at night, in order to prevent all risk.

I have already stated that we occasionally meet with persons whose eyes show an extraordinary antipathy to the use of atropine, and in whom even a drop of a very weak solution suffices to produce great irritation of the eye, and perhaps severe erysipelas of the lids and face. In such cases it should be stopped at once. My friend Dr. Seeley of Cin-

* Vide Dr. Bell, Edin. Med. Chir. Society, 1857, and Von Graefe's Article, "A. f. O.," ix, 2, 70; also a very interesting case of severe Poisoning by Atropine, reported by Dr. Schmid, "Kl. Monatsbl.," 1864, p. 158.

cinnati has informed me that he has found in such idiosyncrasies much benefit from combining the atropine with a weak solution of sulphate of zinc.

The severe ciliary neuralgia which so often accompanies iritis is most relieved by the application of leeches to the temple, and the use of hot poppy or laudanum fomentations. The leeches should be applied towards evening, so that the nocturnal exacerbations may be relieved. Free after-bleeding is to be encouraged by the use of hot fomentations or poultices. The nocturnal pain and restlessness of the patient are also much alleviated by the use of opium, and this remedy should never be omitted in such cases, as it is of much consequence that the patient should enjoy a good night's rest. I myself often employ the subcutaneous injection of morphia for this purpose.

A blister may be applied behind the ear, and kept open for a few days, and the compound belladonna ointment should be rubbed into the forehead.

If there is a considerable tendency to exudation of lymph or pus at the edge of the pupil, into the anterior chamber, on the surface of the iris or into its structure, the patient should be got rapidly under the influence of mercury. One grain of calomel in combination with one-fourth or one-fifth of a grain of opium should be given every two or three hours, until salivation is produced, which will generally occur in from 30 to 40 hours; even when this is produced, a slight degree of tenderness of the gums should be maintained. I, however, greatly prefer the treatment by inunction, as the digestive powers are thus not impaired, and the constitutional effects of the drug are, moreover, more rapidly and surely obtained. Indeed I have met with instances in which mercury had been given by the mouth for some time, without producing any constitutional effect, and where this rapidly supervened upon inunction. Half a drachm or a drachm of the strong mercurial ointment should be rubbed into the inside of the arms and thighs two or three times daily, until the mouth becomes sore. In order to prevent the staining of the skin the ointment may also be rubbed into the bottom of the feet, but here it is absorbed with less rapidity on account of the greater thickness of the skin. Mr. Pridgin Teale* recommends that the mercurial ointment should be smeared on a broad piece of flannel which is to be wrapped round each arm of the patient, who should remain in bed; a small quantity of fresh ointment being added every night. In syphilitic iritis with well marked buttons, the use of mercury should never be omitted, and I have also found much benefit in such cases from the constant use of hot water compresses, continued without intermission night and day for

* Vide Mr. Teale's interesting paper, "On the Relative Value of Atropine and of Mercury in the treatment of Acute Iritis." "R. L. O. H. Reports," V, 156.

several days. I first saw this mode of treatment employed last year by Dr. Wecker, and soon afterwards had the opportunity of trying it in a case of syphilitic iritis with numerous condylomata of considerable size, which had to a great extent resisted the action of mercury. I ordered hot water compresses to be applied to the eye of as high a temperature as the patient could bear, and these were changed every few minutes, and continued for a great part of the day and night. Within the course of two days the condylomata had diminished considerably in size, and within four or five days they had almost entirely disappeared. In another instance, the effect of the compresses was equally favourable. Of course it is only in exceptional cases that this remedy can be employed, for it requires the constant and undivided attention of a nurse; moreover, few patients will submit to the trouble and inconvenience. This remedy also greatly hastens the absorption of hypopyon.

Formerly it was very much the custom to place all cases of iritis under the influence of mercury, quite irrespective of the fact whether the necessity for its use really existed or not. Now, however, a more rational mode of treatment obtains, and mercury is only used in those cases in which there is much effusion of lymph. In specific cases the iodide and bromide of potassium, together with the decoction of bark, should be administered after the use of mercury. Whilst the latter remedy is being employed, it is also wise to maintain the patient's strength by the use of tonics, more especially preparations of steel and quinine.

In the rheumatic form of iritis benefit is often experienced from the use of oil of turpentine internally, as was first recommended by Dr. Carmichael. Although I have often employed it with advantage, I have frequently been obliged to give up its use on account of the derangement of the stomach which it produces. It should be given in doses of from half a drachm to one drachm two or three times daily, made into an emulsion, to which a little carbonate of soda is added to prevent the derangement of the digestive organs.

If the aqueous humour is very cloudy, or a considerable hypopyon is formed, paracentesis should be performed and, if necessary, repeated several times. The same should be done if the pain is very severe and does not yield to the usual remedies. The broad needle should be very slowly removed from the anterior chamber, so that the escape of the aqueous humour may not be very sudden, otherwise there may occur great *hyperæmia ex vacuo* of the inner tunics of the eye. In order to facilitate the escape of the stringy portion of the lymph, the needle should be slightly tilted sideways, so as to cause the section to gape, or the same may be done with a small curette or probe.

But if the iritis is very intense and obstinate, resisting all our

remedies, and more especially if the sight is much impaired, and there are considerable firm synechiæ, or complete exclusion of the pupil, and if the intra-ocular tension is markedly increased, a large iridectomy should be made at once. I have often seen this produce the most striking benefit, and it must be remembered that if the adhesions between the pupil and capsule are at all considerable and broad, or there is occlusion of the pupil from deposit of lymph within its area, an iridectomy will subsequently be necessary, and the condition of the eye will in all probability be much worse when the inflammation has run its course; and hence the result of an iridectomy be far less favourable than if it had been made at an earlier period, before the changes of structure had attained any considerable degree. Moreover, the iridectomy generally acts as the best antiphlogistic, the inflammation, which had before resisted all our remedial measures, rapidly subsiding after the operation.

In *iritis serosa* much benefit is often experienced from exciting the free action of the skin and kidneys by diaphoretic and diuretic remedies. Atropine should also be applied, as well as a suppurating blister behind the ear; but it must be confessed that local remedies often prove of little avail. The state of the intra-ocular tension, of the sight, and of the field of vision must be narrowly watched, and if symptoms of glaucoma supervene, no time should be lost in making a large iridectomy.

The treatment of *traumatic* iritis must vary according to the nature of the injury. If a foreign body has become implanted in the iris, it must be carefully extracted with or without the excision of the corresponding segment of the iris. If the lens has also been injured and a traumatic cataract has been formed, linear extraction, perhaps combined with iridectomy, should be at once performed if the lens becomes much swollen, sets up great irritation, or the intra-ocular tension is increased. If a portion of the iris prolapses through a small wound in the cornea, it should be pricked so that the aqueous humour may flow off, and the collapsed protruding portion of iris should then be excised, and a firm compress applied. After an injury to the iris the inflammation should be combated, according to circumstances, by cold or hot compresses, leeches, and atropine; and, if necessary, rapid salivation should be induced.

3.—FUNCTIONAL DISTURBANCES OF THE IRIS.

(1.) Mydriasis.

Although the dilatation of the pupil is generally considerable, it is not so extreme as that produced by a strong solution of atropine, where the iris is contracted to a very narrow, hardly perceptible rim. The dilatation of the pupil may be uniform and regular, so that the pupil retains its circular form, or it may be partial and irregular, the

pupil thus acquiring a somewhat ovoid shape. The pupil besides being dilated, is more or less immoveable, acting but slightly or not at all upon the influence of light, the effort of accommodation, or the convergence of the optic axes. The sight is also somewhat affected, which is due in part to the bright glare which is experienced on account of the wideness of the pupil, and also in part to the circles of diffusion formed upon the retina. If the impairment of sight be simply due to the mydriasis, it will be remedied if the patient looks through a small circular opening in a card or through the stenopaic apparatus, for then the glare will be diminished, and the formation of circles of diffusion prevented. But very frequently paralysis of the ciliary muscle co-exists with the dilatation of the pupil, and the impairment of vision is chiefly due to the loss of accommodation. The features which distinguish the symptoms due to loss of accommodation from those which are simply caused by mydriasis, are frequently overlooked by medical men, and thus much confusion is often produced in the narration of cases. Nor is it of unfrequent occurrence that the symptoms of amblyopia, produced by paralysis of accommodation, are referred to some serious intra-ocular or cerebral lesion. There is not, however, a necessary relation between the degree of dilatation of the pupil and the paralysis of the ciliary muscle, for the pupil may be widely dilated and the ciliary muscle but slightly, if at all, affected; the converse is, however, of less frequent occurrence.

When the pupil is widely dilated, it no longer presents its usual brilliantly black appearance, but assumes a somewhat greyish tint, which is due to the greater amount of light reflected from the lens and the fundus of the eye.

Mydriasis is generally monocular, unless it is due to some cerebral cause, or to a deep-seated intra-ocular lesion affecting both eyes. Monocular mydriasis often produces considerable disturbance of sight on account of the difference in the brightness of the two retinal images, and the presence of circles of diffusion. For the purpose of accurately measuring the size of the pupil, Mr. Zachariah Laurence's "Pupillometer" will be found very useful.

Causes.—Before entering upon the different causes which may produce mydriasis, it will be well briefly to consider the action of certain substances upon the condition of the pupil either in increasing or in diminishing its size. Certain substances, more especially belladonna, hyoscyamus, and stramonium, have the power of producing a marked dilatation of the pupil, and are hence termed *mydriatics*. We shall here, however, confine our attention to the action of atropine upon the pupil and the accommodation. In numerous experiments made by Donders,* it was found, that if a solution of four grains of

* Donders "Anomalies of Refraction and Accommodation," p. 585.

sulphate of atropine to an ounce of water was applied to the eye, the pupil began to dilate within fifteen minutes, arriving at the maximum degree of dilatation in from twenty to thirty-five minutes, and finally complete immobility ensued. The younger the individual, and the thinner the cornea, the more rapid was the action. The diminution in the power of accommodation commences somewhat later than the dilatation of the pupil, but gradually returns together with the mobility of the pupil after some days. After the lapse of forty-two hours there is generally a slight diminution in the size of the pupil, accompanied by some accommodation, which increases with tolerable rapidity up to the fourth day, but does not become perfect till about the eleventh day. The weaker the solution of atropine, the longer will it take to act, and the less and more transitory will be its effect. By employing an extremely weak solution (gr. j. to eight or ten ounces of water), we may dilate the pupil without affecting the accommodation. That the action of the atropine is due to its absorption through the cornea, is proved by the experiments of Von Graefe,* who withdrew some of the aqueous humour from the eye of a rabbit, the pupil of which was dilated by atropine, and applying it to the eye of another rabbit, it was found to produce dilatation of the pupil.

The action of the atropine appears to be two-fold; it produces dilatation of the pupil, partly by paralysing the sphincter pupillæ, which is supplied by the third nerve, and partly by exciting the radiating fibres of the iris, which are supplied by the sympathetic. The truth of this hypothesis appears to me to be incontrovertibly proved by Ruete's† observation, that in dilatation of the pupil due to complete paralysis of the third nerve, the application of atropine produced still further dilatation. This is certainly opposed to the theory advanced by some observers, viz., that the paralysis of the sphincter pupillæ permits the sympathetic nerve to exert an unopposed action in dilating the pupil. Moreover, it is found that in mydriasis due to paralysis of the third nerve, the pupil is not dilated *ad maximum*, even although the affection may have lasted some time; but on the application of atropine the widest dilatation at once ensues.

Calabar bean produces excessive contraction of the pupil, together with a contraction of the ciliary muscle, and an artificial myopia. Its action will be more fully explained in the article upon the "Affections of the Accommodation." I think there can be no doubt that it chiefly produces its effect upon the pupil by exciting the nerves to the sphincter pupillæ, although the myosis may also be in part due to the paralysis of the radiating fibres of the iris supplied by the sympathetic. But the

* A. f. O., I. 1, 462, note.

† Klin Beitrage z. Pathol. und Physiol. der Augen and Ohren. Braunschweig, 1843.

spasmodic contraction of the ciliary muscle speaks strongly in favour of the excitation of the third nerve.

Idiopathic mydriasis is not unfrequently due to rheumatic origin, the patient having been exposed to cold or wet, and it is in such cases probably caused by rheumatic inflammation of the nerve sheaths. It is generally accompanied by more or less complete paralysis, of some, or all the muscles supplied by the third nerve. It may be also due to syphilis.

It may likewise be caused by direct injury to, or compression of the nerves supplying the constrictor pupillæ, as for instance in consequence of severe blows upon the eye, or of an increase in the intra-ocular tension. In those cases in which it is caused by a blow, the mydriasis is not unfrequently partial, only a certain portion of the sphincter pupillæ being affected.

Mydriasis may also be due to irritation of the sympathetic, as may be seen in certain spinal diseases. The ephemeral dilatation of the pupil which occasionally occurs for a short time at different periods of the day is also probably due to this cause. Von Graefe has called attention to the interesting and important fact, that this ephemeral mydriasis is sometimes a premonitory symptom of insanity, more especially of ambitious monomania. The dilatation met with in helminthiasis may also be ascribed to irritation of the sympathetic.

Dilatation of the pupil is also a common symptom in certain diseases of the brain, *e.g.*, meningitis, hydrocephalus, and diseases of the cerebellum, also in many intra-ocular diseases, in which the sensitiveness of the retina is much diminished. In exceptional instances the pupil may still act perfectly, even although the eye is absolutely blind. In such cases, the conductibility of the optic nerve, and the reflex action which it produces on the ciliary nerves are unimpaired, but the image is not perceived by the brain.

Treatment.—In the rheumatic form of mydriasis a blister should be applied behind the ear, and iodide of potassium, or a preparation of guaiacum should be administered internally. I have, however, often found a far more marked and rapid effect to result upon the paralysis of the accommodation from the application of the blister, than upon the mydriasis. If the dilatation of the pupil does not yield to these remedies, but shows a tendency to become chronic, tincture of opium should be dropped into the eye, electricity should be applied, and the use of Calabar bean may be tried. The latter remedy should not however be applied of too great a strength, or too frequently, otherwise it will produce too much fatigue of the sphincter pupillæ, instead of simply moderately stimulating it. Frequent and firm closure of the eyelids, convergence of the optic axis, and repeated exercise in reading, etc., are also of advantage in stimulating the contraction of the pupil.

In very rare instances the faculty exists of voluntarily dilating the pupil. Seitz* mentions a case of a young student, who was able voluntarily to produce a dilatation of about three millimetres by taking a deep inspiration, and then holding his breath, at the same time making a strong effort, during which the muscles of the neck and back become very tense. The experiment succeeded best when he regarded an object lying but a short distance from the eye.

(2.) Myosis.

Idiopathic myosis is of rare occurrence. The pupil is in such cases often extremely contracted, perhaps to the size of a pin's head, or even less, and acts but very slightly on the stimulus of light. Even strong solutions of atropine produce but a very moderate degree of dilatation. On account of the extreme minuteness of the pupil, but little light is admitted into the eye; the retinal images are consequently but slightly illuminated, and the vision on this account more or less impaired. The small size of the pupil also causes a considerable contraction of the peripheral part of the field of vision.

The affection may be caused by a spastic affection of the sphincter pupillæ, or by a paralysis of the radiating fibres of the iris. The irritation of the branch of the third nerve which supplies the sphincter pupillæ may be due to some central cause, or to reflex action from the fifth nerve. Myosis may also be produced by too great and long continued a use of the eyes at very minute objects, such as watch-making, engraving, etc.; in consequence of which the sphincter pupillæ in time acquires a preponderating power over the dilator. The myosis due to paralysis of the dilator pupillæ is met with in those spinal lesions in which the sympathetic nerve is affected, so that its influence upon the radial fibres of the iris is impaired. A tumour† or aneurismal swelling‡ pressing upon the cervical portion of the sympathetic may also produce myosis.

In the peculiar condition termed *hippus* there is a chronic spasm of the iris, producing rapid contractions and dilatations of the pupil, which follow each other in quick succession and are independent of the influence of light. It is generally allied with nystagmus.

The treatment of myosis must of course vary with the cause, which is often situated at a distance from the eye. Periodic instillations of atropine should be tried, although they generally have but a slight and only temporary effect upon the myosis.

* "Augenheilkunde," p. 315.

† Willebrand, A. f. O., i, 1, 319.

‡ Gairdner "Monthly Journal of Medicine," 1855 (vol. xx, p. 75).

4.—TREMULOUS IRIS (IRIDODONESIS).

The most frequent cause of this condition is absence of the lens, or its partial or complete dislocation. In such cases the iris will be observed distinctly to oscillate and tremble when the eye is moved in different directions. In cases of partial dislocation of the lens, the tremulousness will be confined to that portion of the iris which has lost the support of the lens.

This condition may also be observed in those cases of hydrophthalmus in which the size of the anterior chamber is much increased, and the iris is stretched sideways, thus losing the support of the lens.

It was formerly supposed that a fluid condition of the vitreous humour produces undulation of the iris. That this is, however, not the case is proved by the ophthalmoscope, for we often meet with cases in which a fluid condition of a considerable portion or the whole of the vitreous humour may be diagnosed from the wide excursion made by the floating vitreous opacities, and yet the iris does not show the least tendency to tremulousness.

5.—WOUNDS OF THE IRIS, ETC.

Punctured or incised wounds of the iris are not generally followed by such serious consequences as might have been supposed, as long as the lens has escaped injury. That the iris is not very impatient of such wounds is sufficiently proved by the operation of iridectomy, or the accidental incision of the iris in the performance of extraction of cataract, or again, the puncture of the iris which may occur during the needle operation for the solution of cataract, or the division of remains of opaque capsule. Such operations are, as a rule, not followed by iritis. Wounds which have torn and dragged the iris, are more dangerous than those which have simply produced a clean cut.

Blows upon the eye from a blunt foreign body, such as a piece of wood, a cork from a ginger-beer or soda-water bottle, etc., may cause a rupture of the continuity of the iris, but more frequently still, a rupture at its great circumference, tearing it away from its ciliary attachment, and thus producing a more or less extensive coredialysis. This is the more likely to occur if the edge of the pupil is tied down by adhesions to the capsule. Such secondary pupils may be readily recognised with the oblique illumination, and still more easily with the ophthalmoscope, for the red reflex from the fundus oculi will appear likewise through this pupil. Such accidents, as well as the incised wounds of

the iris are generally accompanied by more or less effusion of blood into the anterior chamber.

Mr. Lawson* narrates an extraordinary case of "laceration of the iris, without injury to any of the external coats of the eye from the splash of a bullet, after it had hit the target, striking the eye," which was under the care of Mr. Critchett. The external coats of the eye were quite uninjured, and the outer part of the cornea only presented a slight unevenness of its epithelial surface, without, however, showing any opacity or any mark indicating the point which received the blow. On looking, however, within the eye, two distinct pupils are at once seen, the one immediately above the other; the lower is separated from the upper one by a bridge of iris; and the upper pupil is bounded by a border of iris, so that it is distinct from, and does not encroach on the ciliary attachment of the iris. The margins of the new pupil when carefully examined are found to be slightly lacerated and irregular.

Cases of rupture of the smaller circle of the iris accompanied by dilatation of the pupil have been narrated by Mr. White Cooper. Wecker has, however, seen a case in which the sphincter pupillæ was ruptured from a violent blow upon the eye, without any consecutive dilatation of the pupil.

A very peculiar and rare condition is that of retraction or depression of a portion of the iris, which is sometimes produced by blows upon the eye. The portion of the iris which is depressed is folded back upon itself, and the inner pupillary circle disappears at the point where this folding occurs, the peripheral portion of the iris is quite unapparent, having sunk back out of sight, so that the eye at this point presents the appearance as if an iridectomy had been made quite up to the ciliary attachment. On examining the eye with the oblique illumination, or with the ophthalmoscope, we cannot, however, detect a trace of the ciliary processes, as would be the case if the iris had been removed.†

In such cases the lens has generally been found partially dislocated or much diminished in size.

The treatment of injuries to the iris must be directed to diminishing any inflammatory symptoms which may supervene. Atropine should be frequently dropped into the eye, leeches should, if necessary, be applied to the temple, and for the first few hours after the accident, cold compresses will afford great relief and assist in checking a tendency to inflammation. If there is any prolapse of the iris through the corneal wound, or if the lens has been injured, the treatment laid down

* "Injuries of the Eye, Orbit, etc.," p. 123.

† For a description of cases of this interesting affection, vide "Mooren's Ophthalmiatrische Beobachtungen," p. 131, and Wecker's "Traité des Maladies des Yeux," vol. i, p. 425.

in the articles upon "Wounds of the Cornea" and "Traumatic Cataract" must be pursued.

Small foreign bodies, such as splinters of steel or glass, portions of gun-cap, etc., may become lodged in the iris, or may injure it in their passage to the back of the eye. The presence of even a minute foreign body in the tissue of the iris is a source of constant irritation, and consequently soon sets up more or less severe inflammatory complications, giving rise to corneo-iritis, or perhaps suppurative irido-choroiditis. It is, therefore, most advisable to extract a foreign body in the iris as soon as possible. The best mode of doing this is by an iridectomy, the segment of iris in which the foreign body is lodged being excised.

6.—TUMOURS OF THE IRIS, ETC.

Cysts of the iris are comparatively a rare affection, and are almost always the result of some injury to the iris. Thus they have been met with after the lodgement of foreign bodies in the iris, penetrating or incised wounds of the latter, blows upon the eye, or even after operations for cataract, such as the operation of division or the common flap extraction. Sometimes it is difficult to discover the exact cause, or to ascertain with certainty that any accident has ever occurred to the eye. In such cases, a very careful examination may, however, sometimes lead us to detect a slight opacity of the cornea, the remains of a former perforation.

The cysts generally appear in the form of small transparent vesicles, situated on the surface of the iris, from which they may spring from a broadish base, or a little pedicle. Their contents, instead of being limpid and transparent, may be opaque, causing the cyst to assume the appearance of a little pearl. Von Graefe* records a case in which the contents were sebaceous, soft, and pulpy, and in this cyst there were also found a number of short thick hairs. A similar case is described by Mr. White Cooper,† but in this the cyst was tough and hard, like cartilage, and was torn away bit by bit with the canula forceps. The little growth appeared to be made up of epithelial cells, closely packed together.

The presence of the cyst may not be productive of any particular inconvenience or impairment of the sight, except inasmuch as the latter may be interfered with by the cyst protruding more or less into the area of the pupil. But in other cases it sets up a considerable degree of irritation, accompanied by ciliary injection, photophobia,

* A. f. O., iii, 2, 412.

† "London Journal of Medicine," Sept., 1852.

lachrymation, etc., or it may even give rise to iritis. In a case narrated by Mr. Hulke* sympathetic inflammation of the other eye was set up, which yielded rapidly after the excision of the cyst.

In an interesting paper upon cysts of the iris, Mr. Hulke says:—"An examination of all the cases which I have been able to collect shows: I. that cysts, in relation with the iris projecting into the anterior chamber, originate in two situations—1, in the iris; and 2, in connection with the ciliary processes. The first lie between the uveal and the muscular stratum of the iris, and are distinguished by the presence of muscular fibres upon their anterior wall; the second lie behind the iris, and bear the uveal as well as the muscular strata on their front. II. It also shows that these cysts are of more than one kind; that there are—1, delicate membranous cysts, with an epithelial lining, and clear limpid contents; 2, thick walled cysts, with opaque thicker contents (whether these are generically distinct from 1 we are not yet in a position to determine, but it seems probable that they are so); 3, solid cystic collections of epithelium, wens or dermoid cysts; 4, cysts formed by deliquescence in myxomata."

The tissue of the iris covering the anterior cyst-wall generally becomes so stretched and attenuated, that the limpid contents of the latter are perfectly distinguishable, and we can often see quite through it to the posterior wall.

The best mode of treatment is the excision of the cyst, together with the segment of the iris to which it is attached. Puncturing or laceration generally proves unsuccessful, as the cyst very rapidly refills. But its excision combined with iridectomy is not always free from danger, as was shown in a case of Von Graefe's,† where the operation was followed by severe purulent cyclitis; probably from a portion of the cyst having been left behind, and becoming the source of the inflammatory complications.

Cysticerci of the iris will be treated of in the article upon "The changes in the contents of the Anterior Chamber."

Nævi of the iris are almost always congenital, and present the appearance of small black patches or elevations, which remain stationary and cause no irritation.

Teleangiectasis or nævus of the iris is an extremely rare affection. Mooren‡ describes a very extraordinary case of this kind in which a dark tumour, resembling a blackberry in size and appearance, was situated on the external portion of the iris, extending somewhat

* "R. L. O. H. Rep.," vi, p. 12.
† A. f. O., xii, 2, 230.
‡ "Ophthal. Beobachtungen," p. 125.

into the pupil, without, however, in the least impairing the sight. The tumour, whose anterior surface touched the cornea, was traversed by several dilated blood-vessels, which could be seen to shine through from the rusty brown back ground of the growth in the form of bright red wavy lines, to be again lost in it after a short course. The ophthalmoscope did not reveal the slightest change in the fundus. The most extraordinary feature of the case was that when the patient, after having shaken his head, stooped rapidly forward, the whole anterior chamber became filled with light coloured blood. The sight (which was a few moments before perfectly good) was at once reduced to a mere perception of the difference between light and dark. When the patient had held his head still for a few seconds, the hæmorrhage began at once to disappear, the upper portion of the iris became apparent, then the upper part of the pupil, and so on, until in the course of about a minute and a half every trace of the hæmorrhage had vanished, and the sight had resumed its normal standard. Each repetition of the experiment produced the same astonishing phenomena, nor was Mooren able, in spite of the most careful and minute examination, to detect the source of the hæmorrhage. The excision of the tumour was proposed, but refused by the patient. Four years later he again presented himself, the appearances of the eye having in the meantime undergone a considerable change. The hæmorrhage had entirely disappeared since about a year, the tumour had become reduced to about one-third of its original size, its colour had assumed a dirty grey tint, and instead of the dilated vessels, numerous isolated black deposits of pigment were now apparent. The intra-ocular tension had increased, and the sight diminished, to the spelling with difficulty letters of 16, and the field of vision was contracted. There was slight excavation of the optic nerve. The patient again refused an iridectomy. Some months later, the glaucomatous changes having led to a complete loss of sight, the patient submitted to an iridectomy, on account of the very severe ciliary neuralgia which had supervened. The little shrunken tumour was sent to Dr. Schweigger for examination, who, as Mooren says, doubtlessly did not receive it, as its receipt was never acknowledged by him. The other eye was subsequently affected with sympathetic irido-choroiditis, which yielded to an iridectomy.

Cancer of the iris is almost always due to an extension of the disease from the deeper tunics of the eye; it is extremely rare as a *primary* affection of the iris, and is then generally melanotic in character. It appears in the form of a small dark yellowish-brown elevation or tubercle at one point of the iris, perhaps somewhat resembling a little syphilitic button or condyloma. The tumour may remain stationary for a length of time, or rapidly increase more and more in size, and pro-

trude into the anterior chamber in the form of a dark brown or blackish mass, which either perforates the cornea or the anterior portion of the sclerotic, which becomes staphylomatous at this point, and gradually yielding, the tumour sprouts forth. As soon as the true nature of the disease is recognised, no time should be lost in excising the eyeball. This is much wiser than removing only the anterior half of the eye, as a similar disease may exist in the deeper tunics.

7.—CONGENITAL ANOMALIES OF THE IRIS.

Congenital Irideremia, or absence of the iris, is occasionally hereditary. I have seen one instance in which the iris was completely wanting in both eyes of the father, this condition being accompanied by a partial luxation and opacity of the crystalline lenses; and in the son (an infant of a few months old) there was total iridemia in both eyes, but the latter appeared otherwise quite normal. Sometimes the iris is not completely wanting; a small rudimentary portion of varying size, being apparent at the periphery. Absence of the iris is often accompanied by opacity or displacement of the lens, nystagmus, and imperfect development of the cornea, which perhaps does not acquire its normal size. The power of accommodation may also be impaired, but this is not due, as was formerly supposed, to the absence of the iris, but may be caused by an arrest in the development of the ciliary body. In those cases in which iridemia is not accompanied by any other affection, the sight may be very good, more especially if the glare of the light and the circles of diffusion upon the retina are diminished by the use of stenopaic spectacles.

Coloboma, or partial deficiency of the iris (cleft iris), is almost always accompanied by a cleft in the ciliary body and choroid. It is due to an arrest in the development of the iris, and may vary very much in size and shape. The coloboma is generally situated at the lower, or lower and inner portion of the iris, and is irregularly triangular or pyriform in shape, the base of the triangle being turned towards the pupil, the apex towards the periphery. Coloboma of the iris generally affects both eyes; sometimes it is confined to one, generally the left, and is often accompanied by other congenital anomalies of the eye, such as cleft of the eyelids, congenital cataract, microphthalmos, nystagmus, cleft palate, etc. The fissure in the iris does not necessarily extend quite up to the periphery, but at the latter point a margin of iris may exist, uniting the two edges of the cleft. Moreover, the area of the coloboma may be closed by a rudimentary, darkly pigmented membrane, which might cause the deficiency of the iris at this point to be altogether overlooked by a superficial observer (Seitz). If the

fibrous layer of the iris is deficient to a greater extent than the uveal layer, the edge of the cleft is fringed with a distinct black margin. In simple coloboma iridis the acuity of vision is generally not at all affected; it may be very different, however, if the affection is associated with a considerable cleft in the ciliary body and choroid.

Amongst the other congenital anomalies of the iris, we must call attention to the eccentric position of the pupil (*corectopia*), and to the case in which there exists more than one pupil (*polycoria*). The eccentric displacement of the pupil may sometimes be so slight that it is hardly observable, but in other cases it is well marked, there being only perhaps a small rim of iris at the side towards which the pupil is displaced. Sometimes both eyes are affected, and then the displacement of the pupil may be symmetrical. I have, at the present time, under my care at the Royal London Ophthalmic Hospital, two very interesting cases of corectopia, occurring in two sisters. In each eye the pupil is displaced, and the lens is also dislocated, both these conditions being congenital. The eyes of the parents are quite normal.

In cases of *polycoria* a second pupil may exist at some little distance from the original one, being separated from it by a more or less considerable band of iris, the second pupil being, in fact, a partial coloboma (annular) of the iris. In other cases several small pupils exist near the normal one, being separated from it and each other by narrow trabeculæ of iris, and this condition is evidently closely allied to that of persistent pupillary membrane. The existence of two or more pupils does not generally produce any impairment of sight, or give rise to monocular diplopia or polyopia.

Persistence of the pupillary membrane is a rare affection, and is characterised by the presence of one or more delicate fibrillar bands, springing from the larger circle of the iris, and passing over the smaller circle into the pupil, which they may either cross to be inserted at the other side into the larger circle of the iris, or they may pass over into a thin, pigmented, circumscribed membrane, situated in the area of the pupil and perhaps attached to the capsule of the lens. These large trabeculæ are often connected to each other by numerous cross-bars of delicate fibrillæ.* Weber† has described a very interesting case, in which the fibres formed a series of arcades. The fibrillæ were very thin and delicate, and were about 18 or 20 in number, and united by numerous thin fibrillar cross-bars. They sprung from the larger circle of the iris, and passed straight over the lesser circle to the centre of the pupil, which was occupied by a circumscribed, pigmented,

* For several interesting cases of this affection, as well as for a brief *résumé* of the cases hitherto described in ophthalmic literature, vide two articles of Cohn's in "Kl. Monatsbl." 1867, pp. 62 and 119.

† A. f. O., viii, 1, 337.

membranous patch, firmly attached to the capsule of the lens. Into this membrane the fibrillæ were inserted. The remaining portion of the capsule, as well as the edge of the pupil, were quite free from any deposits or adhesions, and the pupil acted perfectly under the influence of light. It appears probable that these remains of the pupillary membrane are more frequent in young children, giving way and disappearing as the person gets older. Their true nature is, moreover, sometimes overlooked, they being mistaken for simple adhesions between the pupil and the capsule of the lens.

8.—OPERATIONS FOR ARTIFICIAL PUPIL.

It is unnecessary to enter into a description of the various modes of making an artificial pupil which have been in vogue at different times, as they have now been all abandoned in favour of the following operations, of which that of iridectomy enjoys by far the widest and most varied application, and hence demands at our hands the most full and exact description.

(1.) IRIDECTOMY.

The following instruments are required for the operation:—

1. A silver wire speculum for keeping open the eyelids. Weiss's stop-speculum (Fig. 12) will be found the best, as by means of an easily-adjustable screw, it permits the eyelids to be kept fixedly apart at any desired distance, so that they cannot press the branches together, and thus narrow the aperture. This form of speculum is seen in Fig. 12. If the patient should strain very much, and the speculum presses upon the eyeball, an assistant should lift it forward a little, so as to remove it from the globe.

Fig. 12.

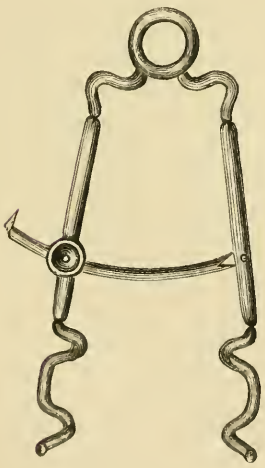

2. A pair of fixing forceps for steadying the eyeball. They must catch accurately, and the tooth should not be too sharp and pointed, otherwise it will easily tear through the conjunctiva. If the latter is thin and rotten (as is often the case in elderly persons) Waldau's fixation forceps are to be preferred, which, instead of being toothed are finely serrated, so that they obtain a firm hold of the conjunctiva without tearing through it.

3. A broad lance-shaped knife. It should be about the same width

as that represented in Fig. 13. If it is much broader the internal wound will be considerably smaller than the external, and in order to enlarge it to the same size as the latter, the edge of the knife must be much tilted in withdrawing the instrument from the anterior chamber. But this proceeding is often somewhat difficult, and may prove dangerous in the hands of an inexperienced operator. The shape of the knife must

Fig. 13.

Fig. 14.

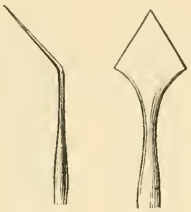

vary with the direction in which the iridectomy is to be made. If it is made outwards (to the temporal side) the straight knife is to be used. But if the iridectomy is made inwards or upwards, the blade must be bent at a more or less acute angle (Fig. 14), according to the prominence of the nose or of the upper edge of the orbit. If the anterior chamber is extremely shallow, so that the iris is nearly in contact with the cornea, and especially if the pupil is at the same time dilated, it will be better to make the incision with Von Graefe's narrow cataract knife than the lance-shaped one. For with the former we can skirt the edge of the anterior chamber, and make a large incision without any risk of wounding the lens.

4. The iris forceps should catch most accurately, and, when closed, should be perfectly smooth at the extremity; for if they are rough and irregular they will scratch and tear the iris and the lips of the incision, and thus perhaps set up some irritation. They may be straight (Fig. 15) when the iridectomy is made outwards, although I, even here, prefer to have them slightly bent. For the upward or inward operation they must be bent at a still more acute angle (Fig. 16).

5. The iris scissors (Fig. 17) should be bent at an angle, and, though sharp, should not be too finely pointed. Care should be taken that the blades close tightly, and do not over-ride each other, which may easily occur in such slight scissors, if the joint is not sufficiently

strong and firm. Instead of these, a pair of scissors curved on the flat (as shown in Fig. 19, p. 175) may also be used.

Fig. 16. Fig. 15. Fig. 17.

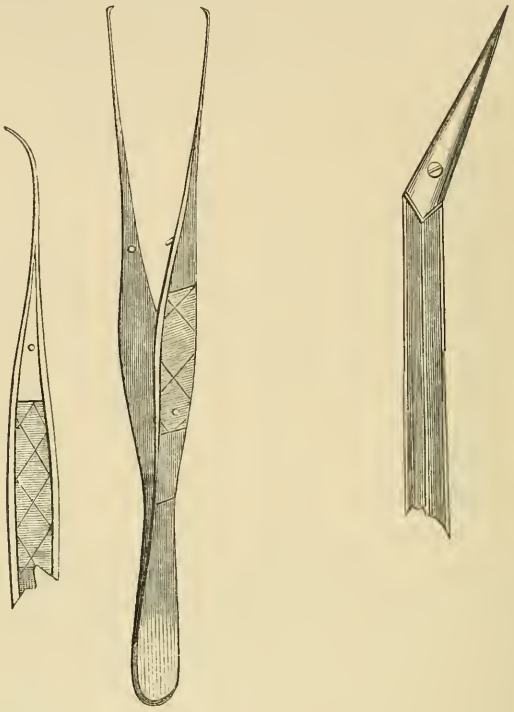

The operation is to be performed in the following manner:—The patient is to be placed in the recumbent position, either in bed or on a couch, the head being slightly elevated. Unless there be very exceptional reasons to the contrary, chloroform should always be administered. I prefer to use it in all cases of iridectomy, especially if the eye is acutely inflamed, for the operation is then often very painful; and, however courageous and determined the patient may be, he may find it impossible to control some sudden, involuntary movement of the eye or head, which may endanger the result of the operation, or even imperil the safety of the eye. But if chloroform is employed, it should be given so as to anæsthetise the patient completely, and render him quite passive, otherwise he may prove far more unruly than if none had been administered; and the operation is of so delicate a nature that absolute quietude of the eye is necessary. If sickness should supervene, the further steps of the operation must be delayed until this has passed away.

Let us now suppose that an outward iridectomy is to be performed upon the right eye for the cure of glaucoma. If the operator is ambidexter, he may seat himself upon the couch or bed in front of the patient, and make the incision with his left hand. If not, he should place himself behind the patient. The eyelids having been opened to the desired extent by the stop-speculum, the operator should seize with a pair of fixing forceps the conjunctiva near the inner side of the cornea, exactly opposite to the place where the incision is to be made. The straight iridectomy knife is then to be thrust into the sclerotic, about half a line from the sclero-corneal conjunctiva (Fig. 18), and the handle of the instrument being laid well back towards the temple, the point is to be passed into the anterior chamber at its very rim, and carried on slowly and steadily towards the opposite side until the incision is of the desired extent. The knife is then to be slowly and gently withdrawn, the aqueous humour being allowed to flow off as slowly as possible, so that the relief of the intra-ocular pressure may not be sudden, otherwise this will cause a rapid over-filling of the intra-ocular blood-vessels, and perhaps a rupture of the capillaries of the retina and choroid, producing sometimes very extensive hæmorrhage. When the knife has been nearly withdrawn from the anterior chamber, the handle is to be somewhat depressed, so that the upper edge of the blade is slightly elevated, and the upper angle of the internal incision should then be enlarged to a size corresponding to the external incision. The same proceeding may be repeated downwards, or the incision may be enlarged to the required extent with a pair of blunt-pointed scissors curved on the flat, the one point being introduced just within the anterior chamber, and the incision then enlarged upwards and downwards.

Fig. 18.

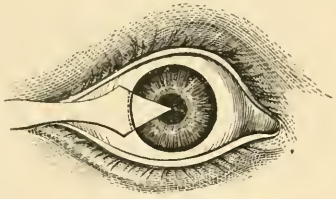

On the completion of the section, the forceps are to be handed over to an assistant, who should, if necessary, fix the eye, being careful at the same time not to press or drag upon the eyeball, but simply to rotate it gently in its bed. If the iris does not protrude through the lips of the wound, the operator should pass the iris forceps (closed) into the anterior chamber, and then, opening them somewhat widely, he should seize a fold of the iris, and draw it gently through the

Fig. 19.

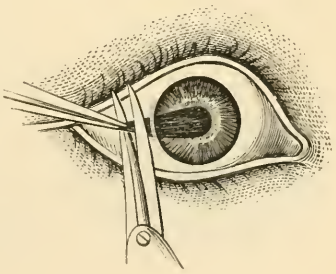

incision to the requisite extent, and cut it off with the scissors quite close to the lips of the wound (Fig. 19). The excision of the iris may be done either by the operator himself, or by an assistant. In the former case the iris forceps should be held in the left hand, and the scissors in the right, as it requires some practice to use the latter well with the left hand. If a portion of the iris protrudes into the incision, there will be no occasion to introduce the forceps into the anterior chamber, but the prolapsed portion is to be seized, and, if necessary, drawn forth somewhat further and divided.

The portion of iris may be excised by one cut, or else this may be done according to either of the following modifications introduced by Mr. Bowman.

The protruding portion of iris may be drawn to the right-hand angle of the incision, and partly divided close up to the angle, the other portion being then gently torn from its ciliary insertion (slight snips of the scissors aiding in the division), and drawn to the opposite angle, to be there completely cut off. This mode of operating is illustrated in Fig. 20, *a*, the prolapse drawn down to the lower (right hand) angle, *a'*, of the incision, where the inferior portion is to be divided, and the other drawn up in the direction of *b*, to the upper angle of the incision.

Fig. 20.

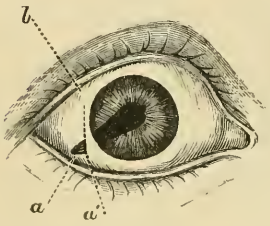

Or again the prolapse (Fig. 21, *a*), may be divided into two portions at *b*. The lower portion is to be drawn in the direction of *c*, to the lower angle of the incision, and snipped off. The upper portion is then to be drawn in the direction of *d*, and also divided. There is, however, this disadvantage in this mode of operating that, if there is much hæmorrhage, the upper portion of iris is somewhat hidden, or it may slip back into the anterior chamber, and have to be searched for.

Fig. 21.

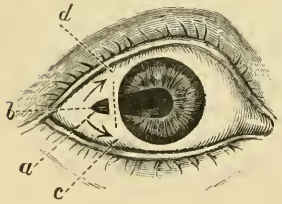

But either method, if well accomplished, will yield an excellent artificial pupil. The iris will be torn away quite up to its ciliary attachment, and the pupil will consequently reach quite up to the periphery (Fig. 22).

Fig. 22.

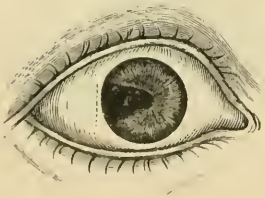

If there is any hæmorrhage into the anterior chamber, the blood should be permitted to escape before coagulation. A small curette is to be inserted between the lips of the wound, slight pressure being at

the same time made upon the eyeball with the fixing forceps, so as to facilitate the escape of the blood. But if the latter does not escape readily, it should not be forced out but be permitted to remain, as it will soon be absorbed, especially if a compress bandage is applied.

I have described the mode of performing iridectomy in the outward direction, as this is the easiest, and it may therefore be wise for a perfectly unskilled operator to make it at first in this direction, until he has gained a certain degree of practice and dexterity, and then to pass over to the upward or inward incision. The operation in either of the latter directions is certainly more difficult than the temporal, on account of the prominence of the nose or upper edge of the orbit, and the consequent necessity of employing a knife bent at a more or less acute angle, which an unskilled operator may find somewhat difficult to keep quite flat.

The size of the iridectomy and the direction in which it is to be made, should vary with the purpose for which the operation is performed. Thus, if it be done solely for the purpose of arresting inflammation, or of diminishing intra-ocular tension, it should, if possible, always be made directly upwards, for then the upper lid will cover the greater portion of the artificial pupil, and thus not only hide the slight deformity, but also cut off much of the irregularly refracted light. In these cases, more especially in glaucoma, the incision should be made somewhat in the sclerotic, so that the iris may be removed quite up to the ciliary insertion, and should be of a sufficient size to permit of the excision of about one-fifth of the iris. We find that if both these requirements are not fulfilled, the beneficial effect of the iridectomy in checking the inflammation and the increase in the tension is either greatly diminished, or not permanent.

But when iridectomy is performed simply for the purpose of making an artificial pupil through which to admit the light, as in opacity of the cornea, lamellar cataract, etc., it should be made of a much smaller size, and, if possible, inwards, as the visual line cuts the cornea slightly towards the inner side of the centre. But with regard to the position, we must be guided by the condition of the cornea, endeavouring to make the artificial pupil opposite to that portion of the cornea which is most transparent, and most true in its curvature. The incision should in these cases be slightly in the cornea, so that a narrow belt of iris may be left standing, and the irregular refraction produced by the periphery of the cornea and of the lens, and consequent confusion of sight, be diminished. For the same reason the iridectomy should not be large, otherwise its base will expose a considerable portion of the edge of the lens. Hence the incision should be made with a narrow iridectomy knife, or even with a broad needle. If a very small incision is made, the iris may be drawn out with a blunt silver or platinum iris

hook, instead of the forceps, just as in the operation of iridodesis. This mode of operating is also indicated in those cases in which there are extensive adhesions between the edge of the pupil and the anterior capsule. In such cases the incision should, if possible, be made at a spot corresponding to a point at which the edge of the pupil is unadherent, so that the hook may seize this portion of the iris. If the whole edge of the pupil is adherent, and the iris is thin and rotten, it is often impossible to obtain a good sized pupil, for the iris breaks down, and tears between the forceps, and only small portions can be removed piece-meal. Or again, the adhesions of the pupil to the capsule may be so firm, that they resist the traction of the forceps, and this portion of the iris remains standing. In fact we have performed the operation, which Desmarres has recommended in such cases, and has termed iridorhexis. A portion of the iris is excised, leaving the adherent pupillary edge standing.

(2.) IRIDODESIS.

This valuable and ingenious operation was devised by Mr. Critchett,* and is very useful in all cases in which we desire to obtain an artificial pupil for optical purposes only, as, for instance, in cases of opacity or conicity of the cornea, or of lamellar cataract, etc.

The operation is to be performed in the following manner:—The patient having been placed under the influence of chloroform, and the eyelids kept apart with the stop speculum, the operator fixes the eyeball with a pair of forceps, and makes an incision with a broad needle in the sclero-corneal junction, slightly encroaching upon the cornea. If the incision is made inwards (which is the best direction) and the nose is prominent, Mr. Critchett employs a broad needle bent at an angle on the flat. With regard to the size of the incision, it is of importance to remember that whilst, on the one hand, it should be sufficiently large to admit of the easy introduction of the hook or forceps, it must not, on the other, be too wide, otherwise the strangulated portion of the iris, with the ligature, may be drawn into the anterior chamber when the aqueous humour re-accumulates. The incision having been completed, and the broad needle removed, a small loop of very fine black silk is to be placed directly over the wound. A blunt platinum or silver hook (bent at the requisite angle) is then to be introduced through the loop into the anterior chamber to the proximate edge of the pupil, which is to be caught up by it, and then the portion of iris thus secured is to be carefully and gently drawn forth into the loop. If it is desired to stretch the opposite portion of the iris, so as to bring it opposite an opacity

* "R. L. O. H. Rep.," i, 220.

in the cornea or lens, and thus to displace the pupil considerably to the side of the incision, the operator must be extremely careful that, whilst drawing forth the iris, he does not cause a separation of the opposite border from its ciliary attachment (coredialysis), which may be easily done if the iris be put too much upon the stretch, or drawn forth somewhat roughly. As soon as a sufficient portion of iris lies within the loop, an assistant, with a pair of broad cilia forceps in each hand, seizes the two free ends of the loop and ties this tightly, so as to include the prolapsed iris firmly within it. In tightening the ligature, he should not draw the ends of the loop away from the eye, but should follow the curvature of the sclerotic. The ends of the ligature are then to be cut off, the one being left somewhat longer than the other, in order that it may be readily seized with the forceps, if the loop should show a tendency to be drawn into the anterior chamber. The little strangulated portion of iris quickly shrinks, and the loop may be removed on the second or third day. But, instead of the hook, the canula forceps may be employed, the iris being seized by them, about midway between the edge of the pupil and its ciliary attachment. The hook is, however, to be preferred.

I have above described the operation which is to be performed when the artificial pupil is to extend to the periphery. But if we desire simply to displace and enlarge the original pupil from its central position towards one side, preserving at the same time the constrictor pupillæ intact, the peripheral portion of the iris must be seized with the canula forceps, and drawn forth through the loop until the pupil occupies the desired position, when the ligature is to be tightened.

It may occasionally occur that, although the sight is considerably improved by the iridodesis, the patient greatly feels the want of more light, and a stronger illumination of the retinal image. In such cases Mr. Critchett has succeeded admirably, by making a second iridodesis in the same eye, in such a manner as to enlarge the pupil and alter its shape, giving it a somewhat crescentic form, with the two corners of the crescent cut off.

The operation of iridodesis is, as a rule, quite free from danger, and productive of but very little irritation. In very rare instances it may, however, give rise to iritis, or even suppurative irido-cyclitis. Such cases have been recorded by Alfred Graefe,* Steffan,† etc., but although I have a large experience of the operation, both in the hands of others and in my own, I have never met with a single case in which it caused inflammatory complications. In order to avoid the risk of irritation, and also to simplify the operation, Wecker has suggested that the prolapse of the iris, instead of being tied, should be allowed to heal in

* "A. f. O.," ix, 3, 199. † Ibid., x, 1, 122.

the wound. He makes the incision rather further in the sclerotic, so as to obtain a long track; he then seizes the iris with a very fine pair of iridectomy forceps, and draws it out into the incision. To maintain it in this position, and to accelerate the healing of the wound, a firm compress bandage is applied. The prolapse becomes firmly adherent in the track of the wound, and the little protruding portion soon drops off.

(3.) ARTIFICIAL PUPIL MADE BY INCISION OF THE IRIS.

We sometimes find after a perforating wound or ulcer of the cornea, or the common flap operation for cataract with extensive prolapse, that the iris presents a plane surface tightly stretched from the cicatrix to the periphery of the cornea, and that there is no trace of a pupil. If the lens is absent, a very fair artificial pupil may often be obtained in these cases by simply splitting the fibres of the iris across with a broad needle. The edges of the incision will generally retract, and a very good sized pupil be left; if this is not the case a Tyrrel's hook may be passed through the corneal incision, and one edge of the incised portion of iris be caught, drawn forth, and excised.

(4.) CORELYSIS.

The detachment of adhesions between the edge of the pupil and the anterior capsule of the lens by operative interference, was first extensively practised by Mr. Streatfeild,* and subsequently also by Weber.† The patient having been chloroformed, and the lids fixed with the stop speculum, an incision is to be made in the cornea with a broad needle, of sufficient size readily to admit the spatula hook into the anterior chamber. Prior to the operation, a strong solution of atropine should be applied to the eye, so that any unadherent portions of the pupil may become dilated. The exact position and size of the different posterior synechiæ should then be carefully ascertained with the oblique illumination, for upon their position and number must depend the situation of the incision, and with regard to the latter it should be remembered that no adhesion, directly behind the incision through which the spatula hook has to be introduced, can be torn through. It is best, therefore, to make the incision at a point situated sideways to the principal adhesions; thus if there are two adhesions opposite to each other, the incisions should be made between them so that by a simple half

* "R. L. O. H. Rep.," i, 6, and ii, 309.
† "A. f. O.," vii, 1, and viii, 1, p. 354.

rotation of the spatula each may be easily torn through. If there are several adhesions and one broad unattached portion of the pupil, the incision should be made opposite the latter. Mr. Streatfeild recommends that the broad needle should be rapidly withdrawn from the anterior chamber, so as to allow as little of the aqueous humour to escape as possible. Whereas Weber prefers to withdraw the instrument very slowly so as to permit the gradual escape of the aqueous humour, in order that the crystalline lens may come in contact with the cornea and thus be steadied; the spatula will glide over the former, and there is less chance of injuring the capsule.

The incision having been finished, a small spatula hook (Fig. 23) is introduced into the anterior chamber, and, with a somewhat lateral "wriggling" movement, the instrument is passed slightly beneath the iris, at a point free of adhesions, and is then passed behind the nearest adhesion, and drawn gently and slowly towards the operator so that it breaks down the band before it, care being taken to keep it quite parallel to the iris lest the capsule of the lens should be injured. The adhesion may yield at once before the pressure of the spatula, but if it resists it may be caught in the hook and thus torn through.

Fig. 23.

(5.) IRIDODIALYSIS.

If nearly the whole cornea is opaque, and there is only a narrow transparent rim left, it may be advisable to adopt this mode of forming an artificial pupil, for if the incision is made, as in iridectomy, in the sclero-corneal junction, it is sometimes followed by some opacity of the cornea close to the incision, and this would prove very disadvantageous where the rim of clear cornea is but very narrow. An incision is made in the cornea with a broad needle, at a sufficient distance from the point where the iris is to be removed from its ciliary attachment, for the forceps or hook to be easily managed. A fine pair of iridectomy (or canula) forceps are passed into the anterior chamber, a fold of iris seized, gently torn from its insertion, and a portion drawn forth through the incision and snipped off. In this way a fair sized, marginal pupil can be made opposite the transparent edge of the cornea. Even if the vicinity of the incision should become a little clouded, this will be at the same distance from the new pupil.

I must now briefly enumerate the different diseases in which an iridectomy is indicated. These may be divided into two groups, viz.:— those affections in which the operation is performed for the purpose of diminishing inflammatory symptoms and an increase in the eye-tension, and those in which the object is simply to make an artificial pupil.

In the first group it is indicated—1. In ulcers of the cornea which threaten extensive perforation, or cases of suppurative corneitis. The iridectomy diminishes the intra-ocular tension, and thus affords a favourable opportunity for the process of reparation, and also improves the nutrition of the parts. 2. If the cornea, after perforation, shows a tendency to become prominent and staphylomatous at this point, and more especially if there is any increase in the intra-ocular tension. 3. In obstinate fistula of the cornea, and in prolapse of the iris. 4. In recurrent or chronic iritis and irido-choroiditis, particularly if the communication between the anterior and posterior chambers is interrupted by circular synechia. Also in cases in which a foreign body has become lodged in the iris, or a tumour or cyst exist in the latter. 5. In traumatic cataract, accompanied by much swelling of the lens substance, great irritation of the eye, and augmented tension. Also in various operations for cataract, the object being partly to prevent bruising of the iris during the extraction of the lens, and partly to diminish the tendency to subsequent inflammatory complications. 6. In the extensive group of glaucomatous diseases, in which there is increase of the intra-ocular tension, leading finally to excavation of the optic nerve and blindness. The importance of an early operation in such cases cannot be over-estimated.

In the *second class* of cases in which the object of the iridectomy is simply to afford an artificial pupil, it is indicated in the following affections:—1. In opacities of the cornea, also in conical cornea. In the latter case the object of the operation is, however, strictly speaking, twofold, viz.: to diminish the intra-ocular tension, and also to make a pupil opposite a portion of the cornea whose curvature is but slightly, if at all, altered. 2. In occlusion of the pupil after iritis. 3. In lamellar cataract, and in dislocations of the lens.

9.—CHANGES IN THE FORM AND CONTENTS OF THE ANTERIOR CHAMBER.

The size of the anterior chamber may undergo considerable alteration. Thus, if the intra-ocular tension be much augmented, or the iris is bulged forward by a collection of fluid, or by exudation-masses between the posterior surface of the iris and the capsule of the lens, the anterior chamber may be extremely shallow, the iris being perhaps almost in contact with the posterior surface of the cornea. Whereas, when the anterior portion of the eyeball is distended and enlarged (hydrophthalmos), or when the crystalline lens is absent or displaced, the anterior chamber increases in depth. The size of the latter also varies according to the age, and the state of refraction. It diminishes with

advancing years, and is deeper in myopic and more shallow in hypermetropic persons.

Effusions of lymph and pus may take place into the anterior chamber and sink down to the bottom in the form of hypopyon, which may attain a considerable size, and even fill the whole of the anterior chamber. The lymph or pus may be effused either from the cornea, the iris, or the ciliary body, as has been described at length in the articles upon the diseases of these parts.

Blood may also be effused into the anterior chamber, this condition being termed "hypæmia." The hæmorrhage may be either spontaneous or traumatic in its origin. In the latter case, it may be due to a wound of the cornea, iris, ciliary body, etc., or it may be produced by a simple blow or fall upon the eye (as from a cricket or racket ball, a "cat," or a blow from the fist), without any rupture of the external coats of the eye. The anterior chamber is filled with blood, and when this has become partially absorbed we find perhaps that the lens has been dislocated, and that there is also hæmorrhage into the vitreous humour. Spontaneous hypæmia is of rare occurrence. It has been known to occur periodically during the time of menstruation, perhaps vicariously, or after the catamenia had ceased. Cases have been recorded in which the patient could voluntarily produce an effusion of blood into the anterior chamber by stooping or rapidly shaking his head.* The best treatment is the application of a firm compress bandage to the eye, for this accelerates the absorption of the blood more than any other remedy. If there is much irritability of the eye or any iritis, atropine drops should be frequently applied.

Foreign bodies, such as portions of metal, gun cap, splinters of glass, eyelashes, etc., may penetrate the cornea and become lodged in the anterior chamber, lying either free in it, or being perhaps partly adherent to the cornea or the iris, and partly situated in the anterior chamber. Their presence in the latter frequently sets up severe iritis or iridochoroiditis. But in other cases, after the immediate effects of the injury have passed away, the foreign body may remain for many years innocuous in the anterior chamber, without either provoking any serious injury to the affected eye or symptoms of sympathetic disease in the other. Thus Sämisch† records a case in which a fragment of stone remained twelve years in the anterior chamber without exciting any serious injury. The foreign body had originally become lodged in the lens, the latter became absorbed, and then the fragment of stone fell into the anterior chamber, remaining attached to the secondary cataract by a fine filament. As it had set up some irritation a fortnight before

* For cases of this kind, vide "A. f. O.," vii, 1, 65; Wallter, "System der Chirurgie," 1848; also Mooren, op. cit.

† "Klin. Monatsblätter," III, 46.

the patient consulted Sämisch, the latter extracted it successfully by a large linear incision in the cornea combined with an iridectomy. Wecker* extracted with success a fragment of stone which had remained fourteen years in the anterior chamber, without causing any irritation.

In removing these foreign bodies from the anterior chamber, care must be taken that the incision in the cornea is of a sufficient size, and so situated, that the foreign body can be easily reached; a large iridectomy should then be made, and the foreign body seized with the iridectomy forceps or an iris hook, and extracted. If the foreign body (*e.g.*, a splinter of steel) is partly in the cornea and partly in the anterior chamber, the blade of the iridectomy knife or of the broad needle should be passed behind it, so as to steady it and push it forward through the cornea, where its anterior extremity should be seized with a pair of forceps and extracted.

Cysticerci are sometimes met with in the anterior chamber, and about twenty cases of this kind have been recorded by different authors. The diagnosis is not difficult, for the little animal is noticed in the form of a small transparent vesicle, generally lying upon the surface of the iris. The vesicle shows at times very decided movements, more especially when the pupil is stimulated to active contraction by the action of strong light, the head and neck of the animal being perhaps stretched out and moved about. The cysticercus may either lie free in the anterior chamber, or be partly adherent to the iris or cornea. The following case of Mr. Pridgin Teale's† illustrates admirably the symptoms presented by the presence of a cysticercus and the mode of treatment to be adopted:—"Mary Isabel Bateman, æt. 10, living at Anerley, was brought to me on June 2nd, in consequence of tenderness of the right eye. On examining the eye there was seen (vide Fig. 24) on the surface of the lower part of the iris an opaque body, constricted in the middle, and rather longer than an hemp seed, which was evidently causing some distress to the eye. The conjunctiva was slightly injected, the cornea was bright, but dotted on its posterior surface with minute spots, as in corneo-iritis; the iris was active, except at the situations of the white body, near which it was adherent to the capsule of the lens. Tension normal. Reading No. 16 Jäger." The mother stated that for two or three years the eye had been occasionally inflamed. Six weeks ago she first noticed a speck on the iris, about

Fig. 24.

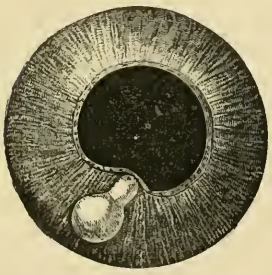

* "Klin. Monatsbl.," 1867, 36.

† "R. L. O. H. Rep.," V, 320.

the size of a pin's head, which became doubled in size at the end of five weeks. The child had always been delicate, and had long suffered from thread-worms, but never from tape-worm. On June 9th Mr. Teale made an incision at the margin of the cornea with a cataract knife and withdrew the piece of iris on which the animal was fixed, and cut it off without destroying the cysticercus. When removed from the eye the slow movements of the body and changes of shape were easily detected. On examination with the microscope, the head and neck, surmounted by the circle of hooklets and four suckers, were seen to project from the side of the body (vide Fig. 25).

Fig. 25.

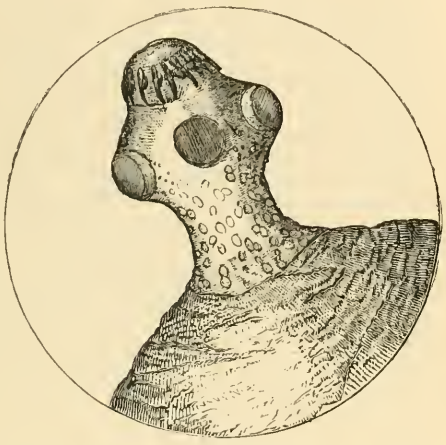

The removal of the cysticercus was soon followed by the disappearance of all symptoms of inflammation and irritability of the eye, and four months afterwards the patient was able to read Jäger No. 1.

10.—IRIDO-CHOROIDITIS.

I have already pointed out, when speaking of iritis, that on account of the close relationship between the iris, ciliary body, and the choroid (which in truth form one continuous tissue, the uveal tract), any inflammation commencing in the iris is very prone to extend to the ciliary body and choroid, or *vice versâ*. The most frequent cause of such an extension of the inflammation of the iris to the choroid is to be sought in the presence of considerable posterior synechiæ, or still more in complete exclusion of the pupil.* In such cases, the recurrence of the inflammation, and its extension to the ciliary body and choroid are partly due to the constant irritation and teasing kept up by the adhesions at the

* I must remind the reader that by this term "exclusion of the pupil" is meant, that the adhesion between the edge of the pupil and the capsule of the lens extends completely round the circumference of the pupil, and thus shuts off the communication between the anterior and posterior chamber. The area of the pupil may, in such a case, be perfectly clear and unoccupied by lymph. If this is not the case, but it is filled with a deposit or plug of lymph, it is termed "occlusion" of the pupil, and this involves also exclusion.

edge of the pupil, preventing the normal dilatations and contractions of the pupil, which take place in accordance with any alteration in the degree of illumination, the movements of the eye, and the changes in the accommodation. But they are still more caused by the interruption in the communication between the anterior and posterior chamber (in cases of exclusion of the pupil), which prevents that regulation and just balance of the intra-ocular tension in front and behind the iris, which always exists in the healthy eye. Thus, if there is any increase in the vitreous humour, the anterior chamber becomes narrower, and contains less aqueous humour; if, on the other hand, the quantity of the aqueous humour is increased, the iris is somewhat cupped backwards, and the fluid in the posterior chamber diminished in quantity. In this way, changes in the amount of the fluids in different parts of the eye are prevented from exercising any deleterious influence, if their augmentation does not exceed a certain degree. For on account of the regulation between the anterior and posterior chamber no harm accrues. But it is quite different when this communication is stopped, and the iris forms, so to say, a firm barrier between the anterior and posterior chamber. If there is any increase of tension in the posterior portion of the eye, it cannot be relieved at the expense of fluid in the anterior chamber, consequently a stasis occurs in the circulation of the inner tunics of the eyeball, soon followed by inflammatory complications of a serious nature.

In practice we can distinguish two principal forms of irido-choroiditis, presenting certain characteristic differences, which it is of consequence to observe, not only with regard to the prognosis, but also with regard to the line of operative treatment which is required in each.

In the *first* form the disease commences with iritis, and if the pupil is not kept widely dilated with atropine, posterior synechiæ soon form and rapidly lead to exclusion of the pupil from circular synechia. The pupil may remain clear excepting just at its edge, where it shows a well marked border of pigmented exudation. Gradually we notice that small knob-like bulgings show themselves in the iris, which may remain chiefly confined to one portion, or extend more or less to the whole of it, so that the iris is bulged forward into numerous prominences, like sails before the wind. This bulging is not due to any firm exudation on the posterior surface of the iris, but to a serous effusion behind it; and the partial bulging is due to the fact that some portions of the iris resist the pressure of the fluid more than others. The appearance presented by such cases is very peculiar and characteristic.

On account of the firm adhesion of the whole circumference of the pupil to the capsule, the iris cannot at this point yield to the pressure

of the fluid behind it, but bulges out between the pupil and its ciliary adhesion into more or less numerous, knob-like protuberances, which are sometimes so considerable in size, as to come in contact here and there with the posterior surface of the cornea. The bulge slopes gradually down towards the circumference of the cornea, but passes steeply down to the pupil, which lies in a crater-like depression.

The iris is generally very much discoloured, and of a grey ash-like, or greenish tint. On closer examination, more especially with the oblique illumination, it will be seen that its fibrillæ are somewhat opened up and stretched apart, and that it is traversed by a few dilated tortuous veins.

The tension of the eye is generally at first normal, but may then become considerably increased, finally however it diminishes more and more as the eye becomes atrophied. If the pupil is clear, the sight may at the outset be good, but when the bulging of the iris occurs, it rapidly deteriorates. If the refractive media and the pupil are sufficiently clear to permit of an ophthalmoscopic examination, the vitreous humour is often seen to be diffusely clouded, with delicate, floating, or fixed opacities suspended in it, proving that the disease is no longer confined to the iris, but has extended to the ciliary body and choroid. If an iridectomy is made in such a case, we notice that when the knife is withdrawn, some aqueous humour escapes from the anterior chamber; but that the latter is not emptied completely, in consequence of the intraocular pressure not being able to affect the anterior chamber on account of the exclusion of the pupil. A sufficiently large piece of iris can generally be seized with the forceps and excised, a copious stream of watery yellow fluid simultaneously escaping from behind it. The iris now at once recedes to its normal plane, even although, as Von Graefe points out, the bulging part itself has not been excised, but only a neighbouring portion of iris. The artificial pupil thus obtained, may be almost entirely clear, excepting just at the edge of the pupil; or, as frequently occurs, a more or less considerable portion of the uvea is found to be left behind in it; the uvea having been separated from the iris proper by the fluid, and become attached to the capsule of the lens.

The *second* form of irido-choroiditis presents very different appearances. The iris instead of being arched forward in little knob-like projections, is perfectly straight and even on its surface, although it is pressed forward towards the cornea, producing great shallowness of the anterior chamber, but the pupil is not drawn back. There is complete exclusion of the pupil, and its area is generally occupied by a more or less dense false membrane, or by a thick plug of lymph. The tissue of the iris looks stretched, its fibrillæ are indistinct, its surface discoloured, and of a dirty reddish tint, which is partly due to the cloudiness of the aqueous humour, but chiefly to the numerous large

tortuous blood-vessels which traverse its surface; there being a considerable stasis in the venous circulation and mechanical hyperæmia, on account of the inflammatory affection of the ciliary body and choroid. The pressing forward of the iris is not due to a collection of fluid behind it, but to the pushing forward of the lens (with whose capsule the iris is intimately connected by means of extensive, thick masses of exudation), which yields to the intra-ocular pressure. The false membrane behind the iris is generally very considerable, consisting of a thick, organized, felt-like mass of exudation, which adheres closely to the capsule of the lens, and perhaps fills up a great portion of the posterior chamber. The intra-capsular cells generally proliferate, and become clouded, but the lens itself often remains transparent.

In these cases, the simple iridectomy is of no avail, for even if we can remove a portion of the iris (which is often very difficult), the opening thus made is again rapidly closed by exudation, for the operation excites a fresh attack of inflammation, and finally such eyes will undergo gradual destruction from atrophy, if they are not operated upon in the manner described below.

I must state that the distinctive characters of these two forms of irido-choroiditis are not always so strongly marked, for we often meet with mixed forms; or, again, the second may supervene upon the first, forming, so to say, a more advanced and hopeless stage.

It has been stated above, that irido-choroiditis may ensue upon an inflammation which primarily affected the iris and then extended to the ciliary body and choroid; or that it may begin in the latter and only subsequently attack the iris. It is sometimes difficult, at a late stage of the disease, to ascertain with anything like certainty, which course the disease had originally pursued. The following facts will, however, afford us some guidance. When the disease originated in the iris, we find that there were well marked symptoms of recurrent inflammation, and that the structure of the iris is considerably changed, being much discoloured, thinned and atrophied. The lens also becomes less frequently opaque, and only at a much later period. The dimness of sight is also less considerable, and depends at first chiefly upon the deposit of lymph in the pupil, and only subsequently upon the cloudiness of the lens or vitreous humour. Whereas, if the inflammation commenced in the choroid, the train of symptoms is different. There are marked symptoms of choroiditis, with opacity of the vitreous humour, followed very generally by detachment of the retina from a serous or hæmorrhagic effusion. The tension of the eyeball diminishes. Then an opacity of the lens supervenes, very frequently commencing at its posterior pole, and gradually extending thence to the whole lens substance. At a later stage, the lens undergoes further degenerative changes, becoming chalky, and transformed into a "cataracta accreta."

The iris may either remain unaffected until a late period in the disease, and not until some time after the formation of cataract, or it may become inflamed at an earlier stage; but the iritis is generally insidious, and not accompanied by any marked inflammatory symptoms. The pupil becomes adherent, lymph is effused in its area and on the posterior surface of the iris, which may become bulged forward by fluid, or pressed forward by dense masses of exudation. One very important guide by which to distinguish between this form of irido-choroiditis and that commencing with an inflammation in the iris, is the degree of sight and the state of the field of vision. The perception of light will be far less in the former case, and there will be a marked contraction or absence of that part of the field (the upper) which corresponds to the detached portion of the retina. Thus, if the light from a lamp is distinguished when it is held in the lower half of the field, but becomes unapparent when it is removed into the upper half, it indicates a detachment of the lower portion of the retina.

The sight is generally very much impaired in cases of irido-choroiditis, so that the patient can only perhaps distinguish large letters, count fingers, or has only simple perception of light. In irido-choroiditis uncomplicated by detachment of the retina, or glaucomatous or atrophic changes in the retina and optic nerve, the quantitative field of vision should be good.

The *prognosis* is, of course, very variable, according to the stage and form of the disease. If a case of irido-choroiditis (uncomplicated with extensive lesions of the choroid, detachment of the retina, or opacity of the lens) be seen at the outset, whilst the changes in the iris are still but slight, the area of the pupil clear, or only occupied by a film of exudation, and there are no masses of exudation membranes behind the iris, the prognosis may be favourable if the sight be still tolerably good, and the field of vision normal.

The first form of irido-choroiditis, in which the iris is bulged forward by fluid, affords a much better prognosis than the second. The most hopeless of all, are of course the cases of irido-choroiditis with detachment of the retina. In such a case, or if there is no perception of light left, no operation should be attempted excepting for the sake of relieving pain, or diminishing the risk of sympathetic ophthalmia. A certain degree of atrophy of the eye (if it be not too far advanced, and the perception of light and field of vision are good) does not contra-indicate an operation, for we find that the iridectomy often arrests the atrophy, and that the eye regains its plumpness, and a normal degree of tension.

The most frequent *cause* of irido-choroiditis is the presence of posterior synechiæ, above all, the circular form. The presence of adhesions between the edge of the pupil and the capsule of the lens lead to frequent recurrences of the iritis, more lymph is effused, more synechiæ formed,

until finally the pupil is excluded, and then, if this has not already occurred, future inflammations are sure to extend from the iris to the ciliary body and the choroid. The best safeguard against a recurrence of the iritis and the supervention of irido-choroiditis, is to cure a case of iritis without the formation of any posterior synechiæ. Of course such eyes do not enjoy a perfect immunity from a recurrence of iritis if a sufficient exciting cause should arise, but they are far less prone to it than if adhesions have remained behind. Irido-choroiditis may also be caused by injuries and wounds of the eye, by the lodgement of foreign bodies (more especially splinters of metal, gun caps, or glass) within the eye, and by operations, particularly those for cataract. It may likewise arise in consequence of an injury to the other eye, thus constituting "sympathetic ophthalmia."

If the adhesions between the iris and capsule of the lens are not considerable, and are thin and "tongued," it may be possible to tear them through by the prolonged use of a strong solution of atropine, or to separate them by operative interference (corelysis). But if they are firm and broad, and especially if they extend all round the edge of the pupil, and thus cut off the communication between the anterior and posterior chamber, we must have recourse to iridectomy, for no other means will suffice to guard the eye against the dangers of irido-choroiditis, or to stay the progress of this disease if it is already present.

In the early stage, when the adhesions are not very extensive and firm, and the tissue of the iris has not yet undergone atrophic changes, it is generally not difficult to obtain a tolerably good artificial pupil, by means of an iridectomy. Frequently, however, a small rim of iris, at the edge of the pupil, is so firmly attached to the capsule as not to yield to the traction of the forceps, but is left standing. This does not invalidate the result, if a tolerable sized piece of iris is removed, and a clear artificial pupil and a free communication between the two chambers are established. If the pupil is only adherent at certain points, it will be best to employ a fine blunt hook, instead of the iris forceps, for catching up the iris. The hook is to be passed carefully along to the edge of the pupil (the portion where there are no synechiæ), gently turned over the margin, and the iris then drawn out and snipped off. In this way we may often succeed in excising a considerable segment of the iris, whereas from the rottenness of its structure and the firmness of the adhesions, it would probably have resisted the grasp of the forceps, and only small shreds have been removed. Care must be taken never to employ too much force in the removal of the iris, otherwise a dialysis may be easily produced at the opposite circumference of the iris.

We generally find that after the operation, the inflammatory symptoms quickly subside, that the sight improves, and that the recur-

rence of inflammation is arrested. In some cases, however, this is not the case. Exposure to cold, bright light, continued use of the eyes, easily reproduce an inflammation. If these recurrences are frequent and obstinate, much benefit is often derived from a second iridectomy, made in an opposite direction, so that the two halves of the iris are completely cut off from each other. This operation has been practised with much success by Graefe and Critchett (independently of each other), and I have often found much benefit from its performance in cases of obstinate recurrent iritis. The line of the double iridectomy may be either horizontal or vertical. The advantage of the latter is, that a more or less considerable portion of the upper part of the artificial pupil is covered by the upper lid, which diminishes the circles of diffusion upon the retina.

In that form of irido-choroiditis in which the iris is bulged forward by knob-like protuberances, and the edge of the pupil is tied down tightly by a firm circular synechia, it is generally not difficult to grasp and remove a considerable piece of iris, and thus to form a good sized artificial pupil.

On account of the great shallowness of the anterior chamber and the proximity of the bulging iris to the posterior portion of the cornea, it is often very difficult to avoid cutting the iris with the common iridectomy knife. It is better, therefore, to make the incision with Von Graefe's long, narrow cataract knife, for with it we can skirt the edge of the chamber and gain a large incision without any fear of injuring the iris.

We unfortunately not unfrequently find that although the iridectomy is large, the sight is but little if at all improved, for the artificial pupil is occupied by a thick uveal membrane detached by the fluid from the iris. It is of practical importance to remember the probability of this occurrence on forming our prognosis as to the effect of the operation; hence we should never definitively promise the patient great improvement of sight after the first operation, but prepare him for the probable necessity of a second. The uveal pigment is so intimately connected with the capsule of the lens, that it is generally unwise to attempt to scrape a portion of it off, as rupture of the capsule and traumatic cataract might ensue. If we therefore find that so considerable a portion of the artificial pupil (the natural one being also blocked up by lymph) is occupied by the uvea as greatly to impair the sight, it will be best, at a later period, to make another iridectomy in a different direction, in the hope that at this point there may be less deposit upon the capsule. By this means, or even by a third iridectomy, we may succeed in finally giving the patient a good clear pupil and a considerable degree of sight. A most interesting and instructive example of this kind occurred amongst the patients at Moorfields, where Mr. Bowman repeated the operation; performing

iridectomy twice upon the right eye and three times upon the left. The result was most successful. On the patient's admission his sight was as follows:—Right eye, letters of 20 (Jäger) with difficulty, counts fingers within 18 inches. Left eye—counts fingers with uncertainty within 3 feet. Seven weeks afterwards, on his discharge from the hospital, he could read No. 2 with the right eye and No. 12 with the left.*

Even although the first iridectomy may not materially improve the sight, we find that it generally exerts a beneficial influence upon the tissue of the iris and the general condition of the eye. The iris gradually gains a more normal colour and appearance. Von Graefe was the first to call attention to the fact that a certain degree of atrophy of the eye, consequent upon irido-choroiditis, may be arrested by the performance of iridectomy, and the eye regain its normal tension. This fact has since been widely acknowledged by all surgeons who have much experience on this subject. Of course the atrophy must not have advanced too far, otherwise its arrest will be impossible, the same being the case if detachment of the retina has occurred. The benefit derived from iridectomy (perhaps repeated several times) in these cases, is that the stasis and congestion in the choroidal vessels is relieved, which not only causes an improvement in the choroidal circulation, but also in the nutrition of the vitreous humour.

If we cannot succeed in finding a portion of capsule sufficiently clear of uveal pigment to allow of much improvement of sight, or if the lens is opaque, it will be best to remove the latter.

Whilst we may afford considerable improvement in the above class of cases from repeated iridectomies, in the second kind of irido-choroiditis this is by no means the rule. Although in the former case the first artificial pupil often becomes narrowed or even closed, yet the texture of the iris improves; at a second operation we mostly succeed in gaining a larger pupil, and at a subsequent one, a tolerably good result as to the sight. But when thick felt-like masses of exudation exist between the iris and capsule, we fail to remove a considerable portion of the rotten iris, and this attempt, moreover, sets up renewed inflammation, increased proliferation of the exudation masses, and we thus, instead of improving the condition, hasten the atrophy of the eye. It will therefore be necessary, in order to benefit such cases, to remove not only the iris but the dense masses behind it; but they are generally so firmly adherent to the capsule that we are almost sure to rupture the latter in our endeavour to remove them. A traumatic cataract is formed, and this complicates matters still more. But Von Graefe had an opportunity of seeing that these false membranes could be removed with compara-

* I have reported this case at length in the "Royal London Ophth. Hosp. Reports," vol. iii.

tive facility and success when the lens was absent.* This led him to remove the lens, in the following manner, prior to attempting the withdrawal of the iris and exudation masses. A large linear incision is to be made in the sclero-corneal junction downwards with Graefe's long, narrow cataract knife, avoiding, if possible, to wound the iris; but if the latter is greatly bulged forwards the knife should be passed boldly through it, and this generally lacerates the capsule sufficiently freely to permit the ready exit of the lens. If this is not the case or the iris has been left untouched by the knife, a pair of straight forceps or a hook should be introduced, and as much of the iris and false membrane should be removed or torn away as will allow the lens to escape. A compress should be applied after the operation, and should be worn for two or three weeks if there has been much bleeding into the anterior chamber. Sometimes the condition of the eye sensibly improves after the removal of the lens, the iris assumes a better colour, the anterior chamber becomes larger, the perception of light may even improve a little. A month or six weeks after the extraction, Von Graefe recommends the iridectomy to be made. The incision should be large, and a sharp pointed hook should be passed perpendicularly through the false membranes and a hole torn in them; if a moderate clear black pupil results, and the vitreous humour protrudes through it into the anterior chamber, the dilaceration may be considered sufficient. If this is not the case, a blunt hook or straight forceps should be introduced, and the opening enlarged, the same being necessary if a secondary cataract appears in the newly-made pupil. These pupils do not generally close again, and it is surprising that the eye mostly bears these operations with remarkable quietude. Indeed, eyes affected with chronic irido-choroiditis but seldom undergo suppuration after operations. By means of the above operation we are not unfrequently enabled to restore a useful degree of sight to eyes otherwise hopelessly blind, the patient being perhaps able to guide himself, to distinguish large letters, etc.

The following mode of operating, as practised by Mr. Bowman, may also be adopted with advantage. An incision is made with an iridectomy knife in the upper part of the sclero-corneal junction, and the knife is carried on far into the anterior chamber, until its point reaches the opposite side of the iris just below the lower edge of the pupil; into this part of the iris a transverse cut is to be made with the point of the knife. The blades of a pair of scissors are then introduced through the incision in the cornea, the one blade being passed in front, the other behind the iris, and a cut is made straight through the iris down to the transverse incision below the pupil, a similar cut being then made on the opposite side, so as to include between the two a large

* "Graefe's Arch.," vi, 2, 97; vide also the author's abstract of this paper in the "Royal Lond. Ophth. Reports," vol. iii, p. 224.

lozenge-shaped piece of iris together with the whole pupillary edge, which is then to be seized with a pair of forceps and drawn out through the incision. The capsule may then, if necessary, be widely lacerated, and the lens matter be removed by Critchett's cataract-spoon. A considerable portion of the capsule is, however, generally torn away together with the iris. We may finally again introduce the scissors and divide the lower segment of the iris, so as completely to separate the two lateral halves.

11.—SYMPATHETIC OPHTHALMIA.

The name of sympathetic ophthalmia was first applied by Mackenzie to those cases in which an injury of the one eye was followed by a peculiar inflammation in the other, which generally ensues within a short time of the accident, and proves extremely dangerous and intractable. That such a sympathy exists between the two eyes had, however, been previously pointed out by Himly and Beer.

The character of sympathetic inflammation is so extremely dangerous and insidious, that if it has once been lit up, we are but seldom able to stay its progress before great, and often irreparable, mischief, has been done. In the great majority of cases the disease shows itself in the form of a very malignant irido-cyclitis, accompanied by great degeneration of the iris, total exclusion of the pupil, and the formation of dense masses of exudation between the posterior surface of the iris and the capsule of the lens. This is the "sympathetic ophthalmia" *par excellence*, but it occasionally appears in a more tractable and benign form, assuming the character of serous iritis. Von Graefe has, moreover, observed a third and still more rare affection, viz., sympathetic choroido-retinitis.

It is of practical importance to distinguish the condition of sympathetic irritation, which sometimes ensues upon an injury or inflammation of the one eye, from sympathetic ophthalmia. In the former case, the patient finds that any inflammatory exacerbation of the injured eye is accompanied by more or less irritability of the other. He is unable to employ the latter in reading or fine work, without its soon becoming tired and strained, owing to an impairment of the power of accommodation. The range of accommodation is generally also markedly diminished, the near point being removed further from the eye. Every accommodative effort causes the eye to flush up and become irritable, a bright rosy zone appears around the cornea, and photophobia and lachrymation soon supervene, together with more or less ciliary neuralgia. These symptoms generally subside, more especially at the

commencement, as soon as the work is laid aside, but quickly re-appear on its being resumed, or when the eye is exposed to cold, bright light, etc. The injured eye, moreover, often also becomes painful and irritable when the other is used for reading or sewing. Donders describes a form of severe sympathetic irritation under the name of "sympathetic neurosis." It is particularly distinguished by the intensity of the photophobia and lachrymation, these symptoms being often so severe as to cause a violent spasm of the lids, and directly any attempt is made to open the eye a stream of scalding tears pours over the cheek. There is, however, no impairment of sight, although from its great irritability the eye is quite unfit for use. Donders considers that this neurosis never passes over into sympathetic ophthalmia, and yields in a very rapid and marked manner to the removal of the injured eye. Whether or not cases of sympathetic irritation are to be regarded in the light of a premonitory stage of sympathetic ophthalmia, or whether they are to be looked upon as completely differing from it in character, and as never liable to pass over into it, is at present, I think, an open question. Whilst on the one hand, it must be admitted that we occasionally meet with instances in which a state of great irritability has existed for a long time without setting up sympathetic ophthalmia, yet on the other, it must also be conceded, that the attack of inflammation is often shown to have been clearly preceded by symptoms of irritation. Although this question is one of much interest and importance in the study of the true nature of sympathetic inflammation, it is fortunately of but little consequence in the treatment. For I think there can be no doubt that the proper mode of dealing with a case in which marked and persistent symptoms of sympathetic irritability appear, is the immediate removal of the injured eye, more especially if its sight is lost or very much impaired. Indeed, it would be incurring unnecessary risk to neglect doing so, on the supposition that the state of irritation would never pass over into that of inflammation.

Sympathetic irido-cyclitis is characterised by all the symptoms of a severe intra-ocular inflammation. The eyelids are somewhat red and swollen, and there is more or less photophobia, lachrymation, and ciliary neuralgia. Sometimes, however, there is not the slightest pain, so that even in children we hear no complaint, and this invests the disease with a peculiarly dangerous character, as it is very apt to be long unnoticed by the parents. The ciliary region is generally sensitive to the touch, and often acutely so. Soon there appear some peri-corneal vascularity and chemosis, the iris becomes discoloured, and of a yellowish-red tint, the aqueous humour is clouded, and the anterior chamber perhaps diminished in depth. There is a rapid effusion of lymph at the edge of the pupil, soon leading to its complete exclusion; indeed the action of atropine exerts but little influence upon the pupil. But the exudation

is not confined to the pupillary edge, but extends to the posterior surface of the iris and the ciliary processes. The iris becomes firmly glued down to the capsule of the lens, and as the disease advances, these exudations assume a very dense, firm, and organized character. Lymph is also effused upon the surface and into the stroma of the iris, often to such an extent that the latter appears soaked in it. The pupil is either covered by a film of exudation, or may be completely occluded by a dense yellow nodule. On account of the inflammatory swelling of the ciliary body, this region is very sensitive to the touch, and the circulation of the iris is greatly impeded, and the venous efflux obstructed; hence we soon notice the appearance of large tortuous veins upon the iris. Its structure soon becomes degenerated and changed into a firm, tense, fibrillar tissue, which cannot be caught up in a fold by the iridectomy forceps, but is so friable and rotten that it tears and breaks down under their grasp. Hence if an iridectomy is attempted, we shall only succeed in tearing away a small portion of the iris, and probably set up fresh inflammation, which will lead to a rapid increase in the density and extent of the exudation-masses. If the pupil and refracting media are sufficiently clear to permit of the use of the ophthalmoscope, we may notice opacities in the vitreous humour, and inflammatory changes in the choroid and retina. Or there may be dense masses of exudation in the anterior portion of the vitreous humour, giving rise to a peculiar yellow lustrous reflex. At a later stage of the disease, when the morbid products have become more consolidated, the periphery of the iris is often drawn back, which is due to a direct retraction caused by the adhesion of its posterior surface to the ciliary processes (Graefe*). Whereas, on account of the increase in the exudation behind the iris, the latter, and with it the lens, is moved forward. So that the more central portion of the iris and the pupil are approached nearer the cornea and the anterior chamber narrowed, whilst the periphery of the iris may be drawn back towards the ciliary body. In other cases fluid is effused behind the iris, and the latter becomes bulged out into little protuberances. The attack is often so insidious and painless, that the patient pays but little heed to the first stage of the inflammation, thinking perhaps that he has only caught a slight "cold" in the eye; and it is not till the sight becomes materially affected that he is frightened and seeks medical aid. In children especially (from their taking but little heed of the impairment of sight and from the absence of pain), the disease is sometimes allowed to proceed very far indeed before much attention is paid to it by the parents. But although the spontaneous pain is often absent, we find that the region of the ciliary body is generally very sensitive to the touch, and sometimes, as has been pointed out by Bowman and Von

* "A. f. O.," xii, 2, 151.

Graefe, at a spot corresponding symmetrically to the point at which the other eye has been injured, or where it still remains tender to the touch.

The tension of the eye varies considerably; at first it is generally more or less increased, but then it gradually diminishes until the eye becomes quite soft, being still, however, liable to considerable fluctuations in consistence. It is, moreover, a fact of great practical importance, that if such eyes are left alone, and the acme of the inflammatory process is allowed to subside, and the eye to become quiet, that gradually and slowly its condition often begins to improve. The tension becomes better, and gradually augments until it may even reach the normal standard; the tissue of the iris improves greatly in appearance, loses its dirty yellow hue, and assumes a fresher and more normal tint.

In the sympathetic serous iritis we find that the symptoms are very different, and closely resemble those of serous iritis, or serous irido-cyclitis. Together with a certain degree of ciliary injection, we notice that the iris is somewhat discoloured, the pupil perhaps dilated, the aqueous humour faintly clouded, and the posterior surface of the cornea dotted by innumerable, small, punctiform opacities, which are perhaps arranged in the form of a pyramid, having its base downwards. The depth of the anterior chamber may be increased. If the inflammation has extended to the ciliary body, this is sensitive to the touch, and the vitreous humour is also clouded. The intra-ocular tension is often augmented. This form is much less common, and much less dangerous than sympathetic irido-cyclitis.

Von Graefe* describes another and very rare form of sympathetic ophthalmia, under the name of "*sympathetic choroido-retinitis*," and narrates two cases, illustrative of the symptoms presented by it. In one of these, the patient had a dislocated chalky lens lying in the anterior chamber of the left eye, which was perfectly blind, and somewhat atrophied. The lens was removed with facility by Von Graefe, but the operation was accompanied by a considerable loss of fluid, yellow vitreous humour. The eye remained irritable, red, and very sensitive to the touch for several weeks, and there were, moreover, symptoms of plastic cyclitis. Six weeks after the operation, when these symptoms had somewhat subsided, but the sensibility to the touch still remained, the sight of the right eye, which had hitherto been perfectly good, began suddenly to be impaired, but this was unaccompanied by any pain. The acuity of vision had already on the second day after the attack sunk to one-fifth, and there was considerable torpor of the retina, with indistinctness of eccentric vision on the whole of the temporal half of the visual field. With the ophthalmo-

* "Archiv. f. O.," xii, 2, 171.

scope, the retinal veins were seen to be very tortuous and dilated, more especially on the inner side. The retina also showed a delicate and diffuse cloudiness, which not only veiled the choroidal ring of the optic nerve, but extended to certain portions of the retina, especially along the course of some of the larger retinal vessels. Slight symptoms of iritis soon supervened, and very delicate punctiform opacities were observed on the membrane of Descemet. The power of accommodation was almost completely paralysed. These symptoms gradually subsided, and the sight became finally quite restored. Whether this favourable result was chiefly due to the remedial measures employed (local depletion, bichloride of mercury, and afterwards iodide of potassium), or to the extinction of the sensibility of the left eye to the touch was uncertain. Von Graefe himself lays the greater stress upon the last fact. The morbid appearances of the retina disappeared less rapidly than the functional disturbances, and then there were noticed patches of choroiditis.

Causes of sympathetic ophthalmia.—1. Amongst the most frequent causes are injuries to the eye, such as punctured and incised wounds, more especially in the region of the ciliary body. If such wounds are extensive, the lens has generally escaped, accompanied perhaps by considerable loss of vitreous and extensive intra-ocular hæmorrhage. Small incised wounds of the ciliary region, or situated partly in the latter and partly in the cornea, are not necessarily of so dangerous a character, more especially if they have only penetrated the coats of the eye without injury of the lens or vitreous humour. In such cases, no time should be lost in bringing the lips of the little wound together with a suture. Union by the first intention will take place, and many an eye will thus be saved, which might otherwise have not only been itself lost from choroiditis, but might have also proved a source of danger to the other eye. In wounds which implicate the cornea alone, there is generally not much danger of sympathetic ophthalmia, although, if they are accompanied by a considerable prolapse of the iris, and this is situated near the periphery, it may, by dragging upon and irritating the ciliary processes, set up sympathetic ophthalmia. But when there has been a penetrating wound of the cornea (such as may be produced by a pair of scissors), and the iris and lens have been also injured, there is always some risk. The disease, may, moreover, be likewise produced by severe contusions of the eye.

2. Foreign bodies lodged within the eye, are a most frequent cause. Amongst these we must especially enumerate portions of gun cap or of metal, and splinters of glass or stone. They prove a source of constant irritation to the eye, more especially if they are considerable in size, and differ in their chemical constituents from the structures in which they are embedded. Inflammation of the iris and choroid

supervene, and the eye may become gradually atrophied, shrinking down to a small shrivelled stump. But even then, all danger to the other eye, if this has hitherto escaped, is by no means passed, for such stumps are a source of constant risk, as long as they remain *painful to the touch*, and show signs of irritability. Years may elapse after the injury, and the patient have long since forgotten his surgeon's admonition as to the danger to the other eye, when suddenly the latter becomes sympathetically inflamed, and in spite of all our efforts, perhaps destroyed. Mr. Lawson, in his valuable work on "Injuries of the Eye,"* narrates two very interesting and important cases of this kind, cases which should indelibly imprint themselves upon our memory, in order that we may know how to decide on an emergency, as to the advisability of the immediate removal of an eye having a foreign body lodged within it, and which it is impossible to extract. One of the patients was injured in the left eye, by the explosion of a gun cap, in 1857. The accident was followed by inflammation and suppuration of the injured eye, which shrivelled up to a small stump, with the foreign body probably still lodged within it. But the stump was quiescent, and gave no trouble. The sight of the right eye remained perfect up to February, 1865 (seven years after the injury), when it became dim, but the patient experienced no pain in it. The stump had, however, become painful and inflamed some time previously.

Repeated attacks of inflammation occurred in the right eye between this time and September of the same year, when he first applied to Mr. Lawson, who then found it affected with marked sympathetic ophthalmia, and the sight so much impaired, that he could not count fingers. The stump of the left eye was inflamed, red, and irritable, and was at once excised, and within it, near the cicatrix in the front, was found the percussion cap. The right eye improved decidedly after the operation.

The second patient was under Mr. Couper. His right eye was lost by injury from a gun-cap, in 1850. *Fourteen years after the injury* (1864) the injured eye became again painful and inflamed, and now the left was affected with sympathetic ophthalmia. He applied six months later at the Royal London Ophthalmic Hospital, and Mr. Couper found that the sympathetic inflammation had proceeded so far that the patient could scarcely distinguish a hand with the left eye. The right was at once excised, and a small chip of gun-cap was found embedded in lymph, and lying on the ciliary processes; the retina was detached.

3. Sympathetic ophthalmia may also be caused by internal inflammations of the eye, more especially if they are accompanied by hæmorrhagic effusions, either considerable in quantity, or of frequent

* P. 321—323.

recurrence, together with rapid fluctuations in the intra-ocular tension. Also if a bony deposit in the choroid has occurred, and the eye remains irritable to the touch. Indeed the continuance of sensibility in the region of the ciliary body in cases of irido-choroiditis, or in eyes which have undergone atrophy after internal inflammation, is one of the most dangerous symptoms, as such eyes are extremely prone to set up sympathetic ophthalmia.

Mooren* mentions a very interesting case in which the sympathetic ophthalmia was apparently produced by the contusion of the optic nerve in dividing it with the scissors in excision of the eye.

Some observers are inclined to push the causation of sympathetic ophthalmia much further than I have done; but I believe that I have above enumerated most, if not all, the causes which have been sufficiently authenticated, as giving rise to sympathetic disease. It must be granted, however, that when one eye is utterly lost (*e.g.*, from absolute glaucoma, from intra-ocular hæmorrhage, or from irido-choroiditis after unsuccessful operations for cataract, etc.), and remains painful and irritable, that the removal of this eye affords a much better prognosis for any operation (for instance, for cataract) upon the other, than if it be allowed to remain and prove a constant source of irritation.

It was formerly generally supposed that sympathetic ophthalmia was propagated from the injured eye to its fellow through the optic nerves, by way of the optic commissure. But this view has been long abandoned as untenable, for cases of sympathetic ophthalmia have occurred in eyes in which the optic nerves were not only completely atrophied, but had even undergone extensive chalky degeneration. It is now generally held that the sympathy is propagated by the ciliary nerves, and this view certainly receives the strongest support from many clinical facts. Thus we not unfrequently meet with cases, as has been especially pointed out by Bowman and Von Graefe, in which the starting point of the sympathetic irritation or inflammation in the second eye occurs at a spot of the ciliary region which corresponds symmetrically to that at which the injured eye was hurt, or at which the ciliary region still retains its sensibility to the touch. Moreover, as Von Graefe strongly insists, the danger of the sympathetic ophthalmia should never be considered as passed, as long as the ciliary region of the injured eye, or its stump, remains sensitive to the touch, more especially if it is accompanied by diminished tension, for it is then a symptom of plastic cyclitis.

Again, when suppuration of the eyeball occurs, and the ciliary nerves are destroyed by it, there is no tendency to sympathetic ophthalmia. It is a well known fact that the latter is never set up by eyes lost from

* "Ophthalmiatrische Beobachtungen," p. 160.

general suppuration (panophthalmitis), as, for instance, after operations.

The *prognosis* of sympathetic ophthalmia is most unfavourable, if the disease has once fairly broken out. In the stage of sympathetic irritation the removal of the injured eye arrests the progress; but it is quite different if the inflammation has already set in, more especially if it assumes the character of plastic irido-cyclitis. For then, even the immediate enucleation of the other eye generally fails to have any, or any but a temporary beneficial effect. For a few days or weeks the inflammation appears to be diminished, but then it breaks out again with all its former severity. The serous sympathetic iritis, being more benign in character and more amenable to treatment, affords a more favourable prognosis.

Sympathetic ophthalmia is more prone to attack youthful individuals, than middle-aged or elderly persons. Its course also appears to be more rapid in the young. It generally occurs within a few weeks of the injury, but a long period, even many years, may elapse before it is excited, as for instance, in the cases above cited from Mr. Lawson's work.

Treatment.—With regard to the general treatment of sympathetic ophthalmia, I must strongly insist upon the necessity of complete rest of the eye for a prolonged period, and this is to be continued for some length of time after the eye appears to have recovered from the inflammatory attack. Otherwise, there is the greatest danger of a recurrence, which may prove most dangerous and intractable. Whilst the eye remains irritable, the patient should be confined to a darkened room, and if he has to go into the open air, the eye should either be protected by a bandage, by a pair of dark blue eye-protectors, or the wire goggles. In order to allay the irritability of the eye, poppy or belladonna fomentations may be applied, as also a solution of atropine (varying from ij to iv grains to the ounce of water), which should be dropped into the eye several times a day. At the very outset of the disease we should endeavour to gain, if possible, a wide dilatation of the pupil, and hence apply it more frequently and in a strong solution; but as has already been stated above, the pupil is generally very imperfectly acted upon by atropine, and at a later stage, the adhesions to the capsule are so firm and extensive as completely to resist its action.

The diet should be nutritious and generous, more especially if the patient is feeble and ill-nourished. Tonics, more particularly quinine and preparations of steel, should also be administered.

We have now to consider, in the first place, whether we are enabled by any operative interference to prevent the occurrence of sympathetic ophthalmia; and, secondly, whether we can arrest its progress when it has once broken out.

With regard to the first point, I may state that, as far as I am

aware, no instance has been recorded in which sympathetic ophthalmia ever attacked an eye after the injured eye had been removed, if at the time the other was still quite unaffected. This being so, there cannot be the slightest doubt as to the imperative advisability of the immediate removal of an eye which has been so greatly injured as to have quite lost its sight, or at all events to leave no hope of any restoration of a useful degree of vision. This is still more the case, if the injury has been of a kind which is prone to be followed by sympathetic ophthalmia. For we have no guarantee that we shall have time to check the sympathetic inflammation, if it has once broken out, even by a speedy removal of the injured eye. For although symptoms of sympathetic irritation not unfrequently usher in the inflammation, and the latter may be prevented by the excision of the injured eye at this premonitory stage, yet this is not always the case. The inflammation may occur without any premonitory symptoms, and advance so rapidly that in the course of a few days the integrity of the eye may be greatly and perhaps permanently impaired. Thus, a case is narrated by Maats, in which within four days (and without any premonitory symptoms) an eye became so affected by sympathetic irido-cyclitis, that there was nearly a complete posterior synechia, and the sight had sunk to $\frac{3}{200}$. In spite of the immediate removal of the injured eye, and of every endeavour to improve the condition of the other by iridectomy, and subsequently by a second iridectomy, with removal of the lens, the eye became atrophied, and only retained perception of light. Such a case should warn us of the danger of procrastination in excision of the blind injured eye, in the hope that there will always be time enough for this when symptoms of sympathetic irritation manifest themselves or during the earliest stage of sympathetic inflammation. For the former may never occur, and the latter may be so rapid in its development and course, that great and irremediable mischief may be done before we can enucleate the other eye. Moreover, there is another point which weighs heavily in the scale amongst persons whose livelihood depends upon their work, and that is the long time which is lost by them during the treatment of the injured eye. For it may remain painful and irritable for many months, and thus render the patient quite unfit to use the sound eye. It may be laid down as a fundamental rule, that as long as the injured eye remains painful to the touch it is always a source of danger, and may at any moment set up sympathetic ophthalmia. It should consequently be removed if its sight is lost, or greatly and irremediably impaired, this being particularly indicated if a foreign body remains within the eye. For thus only can we insure the patient against the dangers of sympathetic inflammation. The question as to whether the injured eye should be removed if it still retains some degree of vision is of course much more difficult and embarrassing. In deciding upon this point, we

must be chiefly guided by the nature and extent of the injury. Thus, if it is a small incised wound of the cornea or sclerotic, and the iris, lens, and vitreous humour have escaped any severe injury, we may by careful and judicious treatment avoid the danger of sympathetic inflammation, and ultimately, perhaps, restore excellent vision. But if the wound is very extensive, and implicates the ciliary region and sclerotic, if the lens has been lost or is injured, a considerable amount of vitreous has escaped, or intra-ocular hæmorrhage has occurred, and if, consequently, the injuries are so great that but very little, if any sight can possibly be saved, it is much better to remove the eye at once, even although some degree of vision may still exist. Still more imperative is such a course, if these extensive injuries are due to a foreign body which has become lodged in the eye and cannot be removed by operation, for although rare instances occur in which foreign bodies remain encapsuled and quiescent within the eye, such cases, form, unfortunately, the great exception. I would especially urge the necessity for the operation if the patient resides at a distance from medical aid, so that a careful watch cannot be kept over the eye, and the first symptoms of sympathetic irritation or inflammation be at once detected. The question in all such cases is, whether it is not better to sustain a small loss than to run the risk of a very great danger. I, however, fully feel and admit the heavy responsibility which rests upon the surgeon who shall advise the removal of an eye which still possesses some sight, and when, as yet, no symptoms of sympathetic disease have appeared. We can in such cases only carefully and conscientiously weigh the different bearings of the case, and place them clearly and forcibly before the patient and his friends, and leave the decision in their hands. I have entered somewhat at length upon this part of the subject, because I feel it to be of great importance to all medical men, and one upon which they should hold strong and decided views. For we never know at what moment we may not be called upon to decide a question of this kind, and what reproaches we may not have to make ourselves if by our procrastination and indecision the second eye is lost from sympathetic ophthalmia.

We must now pass on to the consideration of the question, as to whether we have any power of checking the progress of sympathetic inflammation if it has once broken out. If the sight of the injured eye is lost, it should be *at once* removed, for even although this proceeding may not always stop the progress of the sympathetic disease, but only perhaps arrest it for a time, it will probably at least exert a favourable influence upon its course, from the removal of the primary source of irritation. But it will be different if some degree of sight still lingers in the injured eye, more especially if the sympathetic inflammation has already produced extensive injury, for then it must be borne in mind that in some similar cases the injured eye eventually proved of the most use to the

patient, he having more sight in it than in the other. It appears certain, from the experience of all authorities upon the subject of sympathetic ophthalmia (amongst whom I would especially enumerate Mackenzie, Bowman, Critchett, Graefe, Lawson, Donders, Pagenstecher) that any operative interference upon the second eye during the progress of the sympathetic inflammation is not only not beneficial, but even does positive harm, in increasing the inflammatory proliferation of the exudation masses behind the iris, and thus hastening instead of arresting the progress of the disease. Von Graefe, however, mentions a case in which the performance of an early iridectomy exerted a beneficial influence upon the course of the inflammation. He employed his narrow cataract knife, and made the incision very peripheral (just, in fact, as for the operation for cataract), and thus succeeded in seizing and excising a portion of iris. He, however, strongly advises that the iridectomy should be made as early as possible, as soon, in fact, as the ominous character of the disease manifests itself. But, when the disease has become fully established, the pupil and posterior surface of the iris being tied down to the capsule of the lens by firm masses of exudation, and the tissue of the iris shows symptoms of disorganization, no operation should be performed. It is then far wiser to wait until the active inflammatory symptoms have subsided. Von Graefe thinks that we should wait until the tenderness of the ciliary region has diminished, the development of the large venous trunks in the disorganized iris become arrested or retrograded, the exudations in the pupil have changed their yellow colour for a more bluish-grey tint, the intra-ocular tension (which is generally distinctly diminished) shows no fluctuations, and, finally, until at least three or four months have elapsed since the outbreak of the disease. In opposition to this, it might be urged that if the disease is thus allowed to run its course unchecked, the eye might become so atrophied, and its functions so much impaired as to be beyond all hope of improvement. But, in such malignant cases, any operative interference only accelerates this result, and then, again, these are, according to Von Graefe, quite exceptional cases, for generally the atrophy of the eyeball becomes arrested at a certain point, not reaching perhaps a high degree, and the quantitative perception of light remains good. Under such circumstances, much advantage is gained by waiting as long as possible with the operation, because, as he states, "the vascularisation and irritability of the exudation-masses diminish when the acme of the disease is passed, and besides, the extensive operative interferences which will have to be undertaken will be borne much better; whilst at an earlier period hæmorrhagic effusions from the delicate and newly developed vessels, and the proliferation of the neoplastic formations again destroy the result of the operation. Moreover, the whole tendency of the diffusion of the traumatic irritation upon

the choroidal tract diminishes with the prolonged existence of the disease; and not unfrequently the tension of the eyeball becomes increased."*

The operation which should be performed in such a case is the removal of the lens, together with an extensive iridectomy and a dilaceration of the masses of exudation. This may be performed according to Von Graefe's method, described at page 193, or in that practised by Bowman.

The mode of performing the operation of excision of the eyeball is described in the chapter on "Diseases of the Orbit."

I have already stated that the sympathetic irritation is evidently propagated by the ciliary nerves, and this fact has led Von Graefe to suggest the division of these nerves at the point where the ciliary region of the injured eye remains sensitive to the touch. Dr. Meyer,† of Paris, has performed this operation with marked success in several cases of sympathetic neurosis. After having raised and incised the conjunctival and subconjunctival tissue over the painful portion of the ciliary region, just as in the operation for strabismus, he introduces a squint hook underneath the tendon of the nearest rectus muscle, so that the eye may be well steadied. He then obliquely punctures the sclerotic at the painful point of the ciliary region with Von Graefe's narrow cataract knife, in such a manner that the wound lies parallel to the edge of the cornea. The vitreous humour is at once exposed by the incision. The hook being carefully removed the conjunctival wound is to be closed by a suture, the sclerotic incision healing in the course of a few days.

* "A. f. O.," xii, 2, 165.

† "Annales d'Oculistique," Sept., 1867, p. 120.

Chapter IV.

DISEASES OF THE CILIARY BODY AND SCLEROTIC.

INFLAMMATION OF THE CILIARY BODY (CYCLITIS), ETC.

The congestion and hyperæmia of the ciliary body which are met with in cases of iritis accompanied by extensive posterior synechiæ, soon give rise to cyclitis, the inflammation but too frequently extending to the choroid. Again, the reverse may obtain, the inflammation may commence in the choroid, and extend thence to the ciliary body, and perhaps to the iris. But idiopathic cyclitis may also be met with, more especially after injuries to the ciliary region, such as contusions, incised or punctured wounds, or the lodgement in it of a foreign body. The presence of cyclitis is in such cases recognised by the appearance of very marked subconjunctival injection, acute, often indeed intense pain, on pressure of the ciliary region, great ciliary neuralgia, and the appearance of hypopyon. We may distinguish two principal forms of cyclitis, the *serous* and the *purulent*.

Serous cyclitis often supervenes in the course of serous iritis, more especially if the latter is severe in character, and has been negligently or injudiciously treated with astringent or caustic collyria. The coexistence of serous cyclitis must be suspected, if together with the symptoms of serous iritis, there is marked pain upon pressure of the ciliary region. This tenderness is very frequently situated at the upper or inner portion of the ciliary region. Also, if the tension of the eyeball is increased, accompanied by dilatation of the pupil and shallowness of the anterior chamber; and if the vitreous becomes diffusely clouded, having also large fixed or floating opacities suspended in it. The veins of the iris are likewise often dilated and tortuous. There is at the same time marked and rapid deterioration of the sight, which is in part dependant upon the opacity of the vitreous humour, and in part upon the increase of the eye tension, which causes compression of the retina. The accommodation and field of vision are also more or less impaired. The supervention of cyclitis in cases of serous iritis is always to be

regarded with apprehension, and the state of the sight, of the field of vision, and of the tension of the eye, should be watched with great anxiety, for if the symptoms do not yield to the usual remedies, but rather increase in severity, no time should be lost in performing iridectomy. Still graver is the danger in *purulent cyclitis*, which is characterised by the following symptoms:—There is very marked subconjunctival injection, together with great ciliary neuralgia, photophobia, and lachrymation. The colour of the iris is somewhat changed, and if there is considerable iritis it may be greatly altered. The veins of the iris are dilated. This, indeed, is a very pathognomonic symptom of cyclitis, and it is due to the following cause:—On account of the inflammatory changes in the ciliary body the venous efflux from the iris is more or less impeded, and the blood does not readily flow off from the veinlets of the iris, which, therefore, become dilated and engorged. The region of the ciliary body is very tender to the touch, sometimes the pain thus produced is so exquisitely acute that the patient shrinks back with apprehension. Pus makes its appearance in the anterior chamber, and sinks down to the bottom in the form of a more or less extensive hypopyon. It should be remembered that an hypopyon may be due to a purulent exudation from the ciliary body; for at the rim of the anterior chamber the ciliary body is only separated from the latter by the delicate division of the membrane of Descemet, through which pus may easily exude into the anterior chamber, and then become precipitated in the form of hypopyon. If we can, therefore, exclude the origin of the latter from the cornea and iris, we may be certain, even apart from other symptoms, that it is due to cyclitis. The edge of the pupil is often adherent, its area blocked up with a dense plug of lymph, and a purulent exudation is but too frequently poured out behind the iris, and also perhaps into the vitreous humour.

Purulent cyclitis is very apt to occur after injuries to the ciliary body, operations for cataract, and as sympathetic ophthalmia, indeed it is, as we have seen, the form under which the latter most frequently makes its appearance.

At the commencement, the constant application of hot poppy fomentations frequently afford very marked relief to the severe ciliary neuralgia, and sensitiveness of the ciliary region. If this is not the case, and if there is great hyperæmia and congestion of the subconjunctival vessels, as also of those of the iris, leeches should be applied, and when they have drawn very freely, a strong solution of atropine should be employed, in order to produce dilatation of the pupil as soon as possible. If there is much nocturnal pain, or the patient is restless, a subcutaneous injection of morphia is indicated. When a considerable exudation of lymph occurs into the anterior chamber, or into the vitreous humour, salivation should be induced as rapidly as possible by the inunction of

the mercurial ointment. It must be confessed, however, that we are often quite unable to stay the progress of the disease, and prevent the loss of the eye from suppurative irido-cyclitis, terminating in atrophy of the globe.

An extensive iridectomy, if performed at an early stage of the disease, often exerts a very beneficial influence upon the course of the latter. At a later period it is but too frequently followed by a recurrence of severe inflammation, with a fresh exudation of pus, which completely blocks up the artificial pupil.

Injuries implicating the ciliary region are not only dangerous on account of the inflammatory complications to which they may give rise in the injured eye, but also on account of the risk of sympathetic ophthalmia, which they are very prone to excite. Simple incised wounds of the sclerotic at or near the edge of the cornea, if they are not extensive in size, and have not penetrated too deeply, and thus caused severe injury to the ciliary body, lens, etc., will often rapidly unite, on the insertion of a fine suture. Such wounds may be produced by fragments of glass or steel, or by a clean cut from a small sharp instrument. In the former case, a careful examination should always be made as to the presence of the foreign body, which may either have fallen out after having wounded the sclerotic, have entered the eyeball, or be lying in the lips of the wound, whence it may be readily extracted. A bead of vitreous is seen protruding between the lips of the little wound, and this constant oozing greatly diminishes the intra-ocular tension, the eye being generally extremely soft. But whilst the tension in the vitreous humour is much diminished, that in the anterior chamber may be augmented, the iris being cupped backwards, and the depth of the anterior chamber much increased, and being occupied by yellowish serum. This causes a peculiar and markedly greenish discoloration of the iris, more especially if the latter is normally of a blue or bluish-grey tint. In such cases, by far the best treatment consists in bringing the lips of the little scleral wound together with a fine suture. This is best and most safely done by attaching a curved needle to each end of a very fine silk thread, and passing one needle through the one edge of the wound from *within outwards*, and the other needle through the opposite edge also from within outwards. In this way we shall avoid all danger of injuring the ciliary body or lens from a sudden jerk of the point of the needle deeply into the eye. The suture generally produces little or no irritation, and may be left for eight or ten days, until the wound is firmly united. As soon as the oozing of the vitreous is arrested the intra-ocular tension increases, and in the course of a day or two it generally reaches the normal standard. If the depth of the anterior chamber is much increased by the accumulation of serum, an iridectomy should

be made to re-establish the communication between the anterior and posterior chambers.

A description of the *tumours* met with in the ciliary region will be found in the article upon "Tumours of the Choroid."

DISEASES OF THE SCLEROTIC.

1.—EPISCLERITIS.

Though not a dangerous affection, episcleritis often proves extremely troublesome on account of the protracted and obstinate course which it runs, and also on account of the tendency to frequent recurrence which it often manifests. It is distinguished by the appearance of a small dusky-red, or reddish-yellow elevation on the sclerotic, in close proximity to the insertion of one of the recti muscles, and at a short distance from the edge of the cornea. It occurs most frequently at the temporal portion of the sclerotic, near the insertion of the external rectus muscle. The appearance of the little nodule is generally preceded and accompanied by more or less conjunctival and subconjunctival redness, more especially of that segment of the eyeball upon which the elevation is situated, to which, indeed, the vascularity is often confined. The subconjunctival tissue is at this point markedly thickened and swollen, and of a peculiar rusty, dark, purplish hue, its blood-vessels (as well, perhaps, as those of the conjunctiva) being here somewhat dilated, tortuous, and of a dusky tint. Frequently the conjunctiva is hardly at all affected, the vascularity and swelling being confined to the subconjunctival tissue and the superficial layers of the sclerotic. There is sometimes considerable photophobia, lachrymation, and a certain degree of ciliary neuralgia, but in many cases these symptoms are almost entirely absent, and the patient experiences only slight discomfort, or a feeling of dull, heavy pain in and around the eye. The affected point of the sclerotic may also be more or less sensitive to the touch. At the outset, the affection might be mistaken for phlyctenular or pustular ophthalmia, but the little nodule soon increases in size, and assumes a dusky, reddish-brown appearance, having a broad base, and showing no tendency to ulcerate or suppurate. Gradually it becomes more pale, diminishes in size, and slowly disappears, after it has existed perhaps for many months. Or it may recur again and again, either at the same spot, or at some other point of the eyeball, so that the disease may travel round the cornea from point to point.

The disease is not only very protracted and obstinate in its course, but also very little influenced either by general or local treatment. It

occurs most frequently in females of an adult age, and does not appear to be due to any appreciable cause, except that it is perhaps more often met with in persons of a rheumatic tendency than in others. The cornea sometimes becomes implicated, more especially the part nearest the elevation, the superficial portions of the cornea becoming cloudy, and this opacity assuming somewhat the appearance of a partial arcus senilis. If there is much ciliary irritation and pain, atropine drops should be employed, and warm poppy fomentations be applied to the eye. The insufflation of calomel or the use of the red-precipitate ointment have proved of little benefit in my hands; indeed, I think them contra-indicated if there is any ciliary irritation, still more so is this the case with caustic collyria. I have, however, in some cases found marked and striking benefit from the use of a collyrium of chloride of zinc. I employ at first a very weak solution (gr. $\frac{1}{2}$ to $\overline{3}$j of water), and if this is well borne and does not augment the redness or produce much irritation, I increase the strength to gr. i—ii to $\overline{3}$j. The patient should be placed upon a generous diet, and tonics should be freely administered.

2.—ANTERIOR SCLEROTIC STAPHYLOMA.

Staphylomatous bulging of the sclerotic may be chiefly or entirely confined to one part of the anterior portion of the sclerotic, or it may involve, more or less, the whole of the eyeball.

The partial anterior staphyloma is generally situated near the ciliary region, or further back near the equator of the eye. It may occur at any point from the edge of the cornea to the equatorial region of the eyeball, and frequently shows itself between the insertion of two of the recti muscles, as there is less resistance offered at such a point to the protrusion of the sclerotic.

In the great majority of cases staphyloma of the sclerotic is due to irido-choroiditis, accompanied by an increase in the intra-ocular tension, which leads to distension and bulging of the sclerotic at one or more points, the resistance of the sclerotic having moreover been perhaps also weakened by an inflammatory thinning of its structure. The prominence of the inflammatory symptoms varies very greatly according to the rapidity and acuteness with which the staphyloma is formed. If the course of the disease is very acute, we find that there are marked symptoms of irido-choroiditis. There is conjunctival and subconjunctival injection, accompanied perhaps by a certain degree of chemosis, more especially over and around that part of the sclerotic which is beginning to bulge. The ciliary neuralgia is often very severe, and the ciliary region acutely sensitive to the touch. The edge of the cornea

may be somewhat opaque, the aqueous humour hazy, the iris discoloured and inflamed, and its pupillary edge tied down by exudations of lymph.

If the pupil is sufficiently clear to admit of an ophthalmoscopic examination, the vitreous humour is often found diffusely clouded, with large, dark shreds floating about in it. The tension of the eye is generally considerably increased, and the sight and field of vision greatly impaired. The increase in the eye-tension is not, however, absolutely necessary to the production of a staphyloma. For on account of an inflammatory thinning of a certain portion of the sclerotic, the latter may not be sufficiently firm and strong at this point to resist the presence of even a normal degree of intra-ocular tension, and consequently yields before it. In such a case there would of course be no augmentation of the eye-tension, no hardness of the globe. Such cases are, however, rare in comparison to the others, in which the increase of the tension is the chief cause of the protrusion. Besides the severe pain, the patient often complains of bright flashes of light (photopsies). Soon there is noticed at one point of the sclerotic a slight prominence or bulging, the outline of which may be circumscribed and clearly defined, or be irregular and pass gradually and insensibly over into the healthy sclerotic. As the bulge increases, the sclerotic becomes more and more thinned (partly perhaps from inflammation and partly from distension) and discoloured, assuming at this point a dusky, dirty, bluish-grey hue, which is due to the shining through of the choroid. Thus the staphyloma may attain a considerable size even in the course of a few weeks. Together with the increase in the size of the staphyloma, the proximate portion of the ciliary region and even of the cornea may become involved in it, and be considerably changed in curvature, the corresponding plane of the iris and the zonula of Zinn being stretched, and the attachment of the lens consequently relaxed and loosened.

As a rule, however, the progress of the staphyloma is very slow and gradual. After a more or less acute and severe inflammation of the iris and choroid has existed for some length of time, and its progress has been perhaps apparently arrested, it is noticed that the curvature of one portion of the sclerotic is somewhat altered and more prominent, and its surface traversed by dark, dilated vessels. Gradually and slowly the protrusion increases, the sclerotic becomes more thinned, and exchanges its bright lustrous white colour for a dusky bluish tint. Sometimes the staphylomatous bulging is traversed by tendinous glistening trabeculæ, forming a kind of framework, through the interstices of which the darker portions bulge out, giving to the whole a faint likeness to a mulberry. The staphyloma may now remain stationary for a time, and the inflammatory symptoms disappear. Then an inflammatory exacerbation supervenes, the eye becomes painful, irritable, flushed, and an increase in the size of the staphyloma is

noticed. But these symptoms again disappear, and the progress of the disease is temporarily arrested. Such exacerbations may be of frequent occurrence, and lead, finally, to a considerable and very prominent staphyloma. Sometimes the staphylomatous bulgings are not chiefly confined to one portion of the sclerotic, but occupy the whole of the ciliary region around the cornea, and then the disease is termed "annular staphyloma."

The distension and bulging is not limited to the sclerotic, but extends to the choroid, which is generally adherent to the former, and consequently stretched and bulged with it, undergoing in time perhaps almost complete atrophy. The retina may either be adherent to the choroid, and therefore also stretched and altered in structure, or it may be separated from it at this point, and pass straight across the base of the staphylomatous bulge, the cavity of the latter being occupied by a serous fluid. The vitreous humour is also more or less clouded and fluid. Sometimes it is however quite transparent, and we can then distinctly see (if the other refractive media are clear) the details of the fundus, and perhaps detect a deep excavation of the optic nerve. Generally, however, we are unable to see the fundus on account of exudations in the pupil, or the opacity of the lens and vitreous humour.

In complete sclerotic staphyloma the anterior portion of the sclerotic and the cornea are greatly altered in curvature, being either distended into a conical, or sub-ovoid shape. The iris and zonula of Zinn are also much distended. The plane of the iris is greatly increased in size and discoloured, being of a dirty slate tint, which is partly owing to inflammatory changes, and partly to the stretching and atrophy of its fibrillæ. It is, moreover, often tremulous on account of the partial or complete dislocation of the lens, or on account of the latter being separated from its posterior surface by a considerable amount of fluid. From the distension and stretching of the zonula of Zinn, the attachments of the lens are relaxed and weakened, and the latter may be partially or completely dislocated into the vitreous humour. The depth and size of the anterior chamber are often greatly increased. Indeed the whole eye is much enlarged, and on this account as well as the protrusion of the eye from the orbit, this condition is often termed "buphthalmos." The sclerotic is traversed by dilated tortuous vessels, and is of a dusky, dark-blue tint, which is either diffuse and uniform in character, or chiefly confined to certain points, giving to the whole a dark, patchy appearance. The pupil is often occupied by lymph, the capsule of the lens opaque, and covered by masses of exudation, the lens itself being also frequently cataractous. If the staphyloma has formed after an extensive perforation of the cornea, there will be no anterior chamber, the iris and capsule of the lens are intimately connected with and adherent to the corneal cicatrix, the lens

is cataractous, perhaps shrivelled and chalky, or altogether absent, having escaped through the corneal perforation.

Both the partial and complete staphyloma may after a time become arrested, the inflammatory exacerbations become less and less frequent, and finally cease. In other cases, severe suppurative irido-choroiditis supervenes, and gradually leads to atrophy of the eye. Or again, the bulging portion in a partial staphyloma may give way, either spontaneously or in consequence of a blow upon the eye, or a sudden and severe strain or exertion. A great portion of the contents of the eyeball escapes, this being often accompanied by profuse intra-ocular hæmorrhage; severe inflammation supervenes, and the globe shrinks and atrophies.

With regard to the treatment, I need only say that at the very outset of the disease, when the symptoms are only those of irido-choroiditis the usual remedies—atropine, leeches, paracentesis, etc.—should be employed, but when the tension of the eye is markedly increased, and if the sclerotic shows at one point a tendency to bulge, these remedies no longer suffice, and a large iridectomy should be made at once. If this should not check the inflammation and the bulging of the sclerotic, repeated paracentesis may be tried, or a second iridectomy may be made opposite to the first, so as to divide the iris into two separate halves. But if the staphyloma is considerable and has existed for some time, the iridectomy no longer suffices to cause it to shrink, and we may then have to abscise it. This should be done with a cataract knife, as in the case of staphyloma of the cornea (page 136). After the operation a firm compress bandage is to be applied. In cases of partial staphyloma, more especially if the base is small, I should prefer Borelli's operation (page 140) to abscission. In those cases in which the sight is greatly and hopelessly lost, and the eye is a source of constant irritation and discomfort, abscission by Critchett's method should be performed. But if the disease reaches far back, or involves the whole eyeball, it will be much wiser to excise the eye, for by abscising the anterior part, a portion of the diseased structures will be left behind, and the stump be prone to inflammatory complications, and thus prevent perhaps the possibility of wearing an artificial eye with comfort, and even endanger the safety of the other eye.

3.—WOUNDS AND INJURIES OF THE SCLEROTIC.

Incised wounds of the sclerotic chiefly prove dangerous in so far that if they are extensive, a considerable portion of the contents of the eyeball escapes, which is perhaps followed by profuse intra-ocular hæmorrhage, suppurative choroiditis, and finally atrophy of the eyeball.

Or again, if the wound is smaller, its cicatrization may, by involving a portion of the retina, lead to a detachment of the latter, which, though limited at first, may gradually extend and threaten the safety of the eye. Again, the instrument producing the injury may wound the lens and cause traumatic cataract, accompanied perhaps by severe inflammatory complications leading to the destruction of the sight. Still greater is the danger if the point of the instrument is broken off and lodged in the interior of the eye, the same being the case if foreign bodies have perforated the sclerotic and entered the globe. If the wound is situated at the anterior portion of the sclerotic near the cornea, the iris generally protrudes, and the lens may be dislocated under the conjunctiva; this is especially the case after severe blows from blunt instruments, producing a rupture of the sclerotic. Indeed, ruptures of the sclerotic are generally far more dangerous than incised wounds, on account of the great force of the blow which was necessary to cause the sclerotic to give way. If the incised wound is not considerable in size, its edges should be carefully brought together by a fine suture or two. Any portion of protruding iris or vitreous humour being abscised, cold compresses should then be applied to allay the inflammatory reaction. In small punctured wounds a little bead of vitreous may protrude through the little aperture, and if the application of a firm compress does not accelerate union, the object may be obtained by lightly touching the wound with a crayon of nitrate of silver and potash every second or third day. When the wound is very extensive and a large portion of the contents of the globe has escaped, and there is no hope of restoring any sight, it is better to excise the eyeball at once, more especially if it is to the patient a matter of great moment (as amongst the poorer classes) to be cured as soon as possible, and to be free from further inflammatory attacks.

A portion of the sclerotic may slough after injuries from burns, hot metal, etc. The injured part becomes covered with a whitish grey eschar, which is thrown off together with portions of the sclerotic, until the vitreous humour becomes visible. The injury may be accompanied by inflammation of the cornea and iris, and opacity of the lens.

Chapter V.

DISEASES OF THE CRYSTALLINE LENS.

1.—CATARACT.

By the general term "cataract" is understood an opacity situated in the crystalline lens: to such only should it be applied. When the opacity is in the capsule, it is termed "capsular cataract;" whereas, when both the capsule and lens are involved, it is designated "capsulo-lenticular cataract." The "spurious cataract" of old authors, which was the name given to deposits of lymph in the pupil, should be altogether abolished.

It must be frankly admitted that the etiology of cataract is still shrouded in much obscurity and doubt. It appears most probable that the principal causes of the loss of transparency of the lens are to be sought in an impairment of its nutrition, and in inflammatory changes within the lens itself. The defect in the nutrition may be due to certain alterations in the condition of the blood, to senile involution, or to inflammatory lesions of the neighbouring tunics (*e.g.*, irido-choroiditis, sclerotico-choroiditis posterior, retinitis pigmentosa, etc.). Cataract is not unfrequently met with in those conditions of the blood in which its watery constituents are very deficient, so that it assumes great density (as, for instance, in diabetes). This gives rise to an exosmosis of the watery constituents of the lens, a loss of transparency in its fibres, and a deposit of calcareous and other salts. In diabetes, the cataract does not generally appear until a late stage of the disease, when the patient is greatly emaciated and enfeebled, and his health much broken. I have, however, met with some cases in which the opacity of the lens appeared whilst the general health was still good. The diabetic cataract is generally met with about or before middle age, and does not present any peculiar or characteristic symptoms. It generally affects both eyes, and is mostly of a softish consistence, and rapid in its formation. In elderly persons, however, it will be more firm, and contain a more or less large hard nucleus. The perception of light, and the condition of the field of vision should always be very carefully

examined in such cases, as affections of the retina and optic nerve not unfrequently occur in the course of diabetes, and may, therefore, co-exist with the cataract, and thus render the prognosis of the operation unfavourable. Another fact which should be remembered in operating for diabetic cataract is, that the iris is often very susceptible of irritation, so that iritis is exceptionally easily to set up. The amblyopia which is sometimes met with in persons affected with diabetes may, however, be simply due to paralysis of the accommodation.

The presence of secale cornutum in the system may produce cataract. Thus, Dr. Ignaz Meyer* has shown that the consumption of bread containing ergot of rye may give rise to it. The ergotism has lasted in some of these cases for two or three months, the principal symptom being the fits. The development of the cataract was very slow, and always occurred in both eyes. The mode in which the ergotism gives rise to cataract is still very uncertain, but it is probably due to some impairment of the nutrition of the lens. Wecker thinks that this mal-nutrition may, perhaps, be owing to a diminution in the blood supply to the anterior portion of the uveal tract, on account of the prolonged spasmodic contraction of the ciliary muscle.

Cataract is, as a rule, a disease of old age, and the loss of transparency of the lens is probably chiefly due to its deficient nutrition, dependent upon an inefficient blood supply, and consequent diminution of the watery constituents of the crystalline. We must not, however, mistake for this condition, the small punctated opacities which are due to senile fatty degeneration of the fibrillæ of the lens, and which sometimes appear in old persons in the form of a fringe of small, yellowish, grey dots, situated quite at the periphery of the lens, where they may remain stationary for a very long period.

Inflammations of the inner tunics of the eye, more especially of the iris, choroid, and vitreous humour, may give rise to cataract, not only by an impairment of the nutrition of the lens, but also by the inflammatory changes implicating the intra-capsular cells, and even the lens itself. Again, the cataract may be due to the presence of extensive deposits of lymph upon the capsule, which prevent the osmotic interchange of material between the lens and aqueous humour. If these exudations cover the greater portion of the anterior capsule, the opacity of the lens generally soon becomes complete, whereas, if the exudation is confined to the area of the pupil, the cataract is often only partial. In the former case, the watery constituents of the lens soon become absorbed, the lens becomes diminished in size and shrivelled up, and may in time become almost entirely absorbed, there being only an opaque, white, chalky disc left behind.

Cataract is very frequently due to some injury to the lens, but this

* "A. f. O.," viii, 2, 120.

form will be considered more at length under the head of "traumatic cataract."

Considerable difficulty is experienced in attempting to classify the principal forms of cataract in such a manner that their distinctive features shall be easily recognised and remembered. Not only are the minor varieties numerous, but some of them do not present any marked characteristics, so that their description often proves somewhat confusing and unintelligible to the novice.

I think it most practical to divide lenticular cataracts into two principal classes:—1. The cortical, or soft cataract; 2. The nuclear, or hard cataract. The former is the most frequent kind of congenital cataract, and is met with in various forms up to the age of 30 or 35, and is chiefly characterised by the fact, that although the whole lens may be involved in the process, there is no hard nucleus. The nuclear cataract occurs generally after the age of 35 or 40, and is distinguished by the presence of a more or less large, yellow, hard nucleus. I am well aware that so general a division is open to the objection that exceptional cases are not unfrequently met with, so that all varieties cannot be embraced within it. Yet in a practical point of view I believe it to be the best, as it enables us to lay down broad rules as to the modes of operation to be selected. For instance, the cortical cataract may be operated upon by division with the needle, by suction, or by linear extraction; whereas the nuclear cataract, on account of the presence of a hard nucleus, demands extraction either through a corneal or scleral flap, or by the assistance of some form of traction instrument.

But there is one form of soft cataract which requires a special description, as, on account of its peculiar structure, it may often be best treated by an operation which does not interfere with the lens itself. I mean the lamellar or zonular cataract. Cataracts produced by injuries to the lens, and opacities in the capsule, will be considered under the heads of "Traumatic Cataract," and "Capsular Cataract."

Formerly, much attention was paid to the symptoms which distinguished cataract from glaucoma and amaurosis. But since the discovery of the ophthalmoscope, these diseases could not be mistaken for cataract, except through the grossest ignorance or carelessness.

A fully formed, mature cataract may be at once recognised even with the naked eye. The pupil is no longer dark and clear, but is occupied by a whitish opalescent body, which lies close behind it. It is different, however, when the affection is incipient and but slightly advanced, more especially when the opacity commences at the edge of the lens, for it may then be easily overlooked except the eye is carefully examined with the ophthalmoscope and the oblique illumination. If elderly persons complain somewhat of dimness of sight, the condition

of the lens should always be examined, even although they may apparently be only suffering from presbyopia, and are able to read the smallest print with suitable convex glasses ; for amongst the aged cataract is most common, and often commences at the very edge of the lens in the form of small spicular opacities, which might easily escape detection. Wherever incipient cataract is suspected, the pupil should be dilated by a weak solution of atropine, and the lens examined with the ophthalmoscope and the oblique illumination. If there is any objection to dilating the pupil, a very fair view may, however, be obtained even of the margin of the lens, by directing the patient to turn his eye to one side, and then looking very slantingly behind the iris.

Care must, however, be taken not to mistake the physiological changes which occur in the lens in old age for commencing cataract. These changes consist in a thickening and consolidation of the lens substance, especially of the nucleus, which assumes a yellow tint. If this physiological cloudiness is very marked, it might easily be mistaken for incipient cataract. The chief distinctive features are, that in the former case the sight is perfect (any existing presbyopia being corrected by suitable glasses), the opacity remains absolutely or almost entirely stationary for a very long period, and the cloudiness is not observable with the ophthalmoscope, although perhaps very evident with the oblique illumination.

The *catoptric test*, which was formerly much employed in the diagnosis of cataract, has fallen into complete disuse since the discovery of the ophthalmoscope, and the introduction of the oblique illumination. The catoptrical examination depended upon the three images which may be observed in a healthy eye when a lighted taper is moved before it. Two of these images are erect, the third is inverted. The first is an erect image of the candle, and is produced by reflection from the surface of the cornea; the second is also erect, and is produced by reflection from the anterior surface of the lens; the third is inverted, and is due to reflection from the concave posterior surface of the lens. The first two images move in the same direction as the candle, the third in the opposite direction. If the lens becomes opaque, of course the image from the posterior surface is lost, and that from the anterior surface also soon becomes indistinct.

With the oblique illumination, opacities in the lens will appear of a light grey, or whitish colour. The slighter forms are best seen by only a moderate amount of light.

In employing the ophthalmoscope for the diagnosis of cataract, the mirror alone is to be used (without any lens in front). To gain a larger image, a convex lens may be placed behind the mirror. The illumination is to be weak. Incipient cortical cataract, composed of centripetal stripes, will appear in the form of well-defined dark streaks upon a red

back ground. Punctiform opacities also appear as dark spots, but are often not so observable as with the oblique illumination.

I will now briefly describe the characteristic appearances presented by the different forms of cataract.

I. *Lamellar or zonular cataract* (*Schichtstaar*) is generally congenital or developed in early infancy. Arlt originally called attention to the fact that it often occurs in children who have suffered from convulsions, but the connexion between the two has not yet received a satisfactory explanation; for it is difficult to understand why only certain perinuclear layers of the lens fibres should be affected by the mal-nutrition or succussion consequent upon the violent muscular efforts during the convulsions.

As lamellar cataract does not materially impair the sight, it often escapes detection until much later in life. Its appearance is very characteristic, and its diagnosis easy. On dilating the pupil with atropine, we observe an opacity of the lens measuring from two to three and a half lines in diameter. It is quite uniform from the periphery to the centre, and is sharply defined against the transparent margin of the lens. The cataract consists, in short, of a layer of opaque lens substance lying between the nucleus and a transparent portion of the cortical substance. Hence it has been designated "Schichtstaar," or lamellar cataract. The nucleus of the lens is transparent, which is proved by the uniform character of the opacity, which is not more dense in the centre than at the periphery, and by the relatively fair sight which such patients enjoy even when the pupil is not dilated. Moreover, with the ophthalmoscope, a reddish-brown reflex shines through the central portion of the lens.

With the oblique illumination, the opacity appears of a uniform light grey colour, sharply defined, and surrounded by a more or less broad margin of transparent cortical substance. It will now also be seen that there is a clear portion of cortical substance between the opacity and the anterior capsule. In the centre of the opacity may often be remarked one or more small white spots. With the ophthalmoscope, the opacity has the appearance of a well defined dark disc, the centre of which affords a reddish-brown reflex. If the margin of the cortical substance be clear, the details of the fundus will be visible through it. If there are opacities in it, they will appear as fine dark stripes or specks upon a red background. Some of the varieties of lamellar cataract are very pretty. For instance, I have seen cases in which little stripes ran from the opacity into the cortex, their extremities being studded with small, pearl-like opacities. Lamellar cataract is either stationary or very slowly progressive. It is, therefore, of consequence, before deciding upon an operation, to determine whether the cataract be progressive or not. In deciding this, we must be chiefly guided by the condition of the marginal cortical substance. If the latter is per-

fectly clear and transparent, the cataract is stationary; if it is diffusely clouded, or presents punctiform or striped opacities, it is progressive. Von Graefe thinks that its progress is most rapid when the stripes are broad, and the interjacent lenticular substance is somewhat opaque and studded with coarse specks. If the opacities consist only of very fine dots, or a few delicate narrow stripes, the progress is very slow.

According to Von Graefe, lamellar cataract may also be formed later in life in dislocated lenses, and after iritis.

Vision may be relatively good if the opacity is not dense; for instance large print may be read. But the sight is always improved by dilatation of the pupil with atropine, for this permits the rays from the object to pass through the clear marginal portion of the lens. I have seen cases in which the difference in the sight, before and after dilatation of the pupil, has been most marked; so that persons who, prior to it, could with difficulty decipher large letters, were afterwards able to read the smallest print. The accompanying diagrams (Figs. 26 and 27) will explain this. Fig. 26 (*a*) the undilated pupil occupied by

Fig. 26.

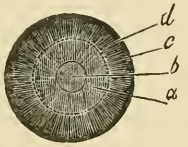

Fig. 27.

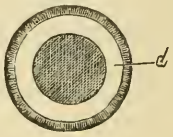

the opacity (*b*), which extends beneath the iris as far as the dotted line (*c*), where the transparent margin (*d*) commences. As the latter is completely covered by the iris, the rays can only pass through the central opaque portion; hence the indistinctness of sight. But on dilatation of the pupil (Fig. 27) the transparent margin (*d*) is exposed, and the rays can now pass through it to the retina. The solution of atropine to be used for dilating the pupil should be extremely weak (gr. j. to eight or twelve ounces of water), so that we may obtain complete dilatation of the pupil without any paralysis of the accommodation. If this point is not attended to, we may easily be misled by the fact of the patient's complaining that after the dilatation the sight is dim and misty, which may be due simply to the fact that the accommodation is paralysed by the atropine, which was too strong.

Persons suffering from lamellar cataract are often supposed to be short-sighted, as they hold small objects (a book, for instance) very close to the eye, in order to gain larger retinal images. In time, however, this constant accommodation for very near objects may really give rise to myopia of even a considerable degree.

In practice, it is important to remember two facts with regard to

lamellar cataract—1. That the opacity is surrounded by a more or less clear margin of cortical substance, which, if it be sufficiently wide and transparent, may admit of excellent sight when the pupil is dilated. 2. That the greater portion of the lens is transparent and in a normal condition, and will, therefore, swell up far more than a cataractous lens, after laceration of the capsule and the admission of the aqueous humour, as, for instance, in a needle operation.

II. *Cortical Cataract.*—The opacity generally commences at the margin. Small, greyish-white stripes are observed running towards the centre of the lens. At the very commencement, the interjacent lens substance is either perfectly transparent, or but sparsely studded with little opaque dots. Soon, however, the cloudiness becomes more general and diffuse, until the whole lens is involved. Sometimes the stripes may be observed both on the anterior and posterior cortical substance, the lens between them being transparent. The difference in their position may be easily recognised with the oblique illumination. The anterior stripes are close behind the pupil, whereas the others are far back in the eye, and appear concave, the concavity being turned towards the observer.

On examining an incipient cortical cataract with the ophthalmoscope, we notice dark, well-defined stripes intersecting the red background, and radiating from the margin of the lens to the centre. Between them, at the very edge of the lens, there is often a fringe of short, stunted stripes. Punctiform opacities, which with the oblique illumination appeared of a grey colour, now look like little dark dots strewn about on and between the stripes.

In rare instances the opacity, instead of being striped, consists of innumerable little dots with clear portions of lens substance between them. With the naked eye it looks like a diffuse uniform opacity.

The following symptoms are characteristic of a fully formed, mature cortical cataract:—The opacity is of a grey or bluish-white colour, which increases somewhat in density towards the centre. On account of this white tint, the movements of the pupil appear peculiarly marked and distinct. If the volume of the lens be increased through the imbibition of fluid, the iris may be slightly arched forward, and the pupil somewhat dilated and sluggish. The stripes are broad, white, and often very opalescent, like mother of pearl. There is no admixture of yellow in the colour of the opacity, which proves at once that the nucleus is not hard. With the oblique illumination, we notice that the outer layers of the cortical substance, although opaque, are somewhat translucent, so that we can see through them into the deeper layers. This is of importance with regard to the consistence, for in the very soft or the fluid cataract the dense white opacity reaches quite up to the capsule, and is not at all diaphanous.

Von Graefe* calls attention to a peculiar form which is sometimes met with in early infancy. Its diagnosis is of special importance, as it is very frequently complicated with lesions of the deeper structures of the eyeball. It commences as a milky-white cloud in the outer portions of the cortical substance, and soon reaches quite up to the capsule. The opacity is either completely homogeneous, or studded with small white dots which extend close up to the capsule. The lens, which is at first somewhat increased in volume, soon diminishes again in size on account of the absorption of its fluid constituents. In cases, therefore, in which the volume of the lens is much diminished, and considerable opacities are lodged in the central portions of the anterior capsule, the degree of sight and the state of the field of vision should always be carefully tested prior to an operation, in order that the existence of any deep-seated lesion may be detected.

The progress of cortical cataract is generally rapid, more especially in children, in whom it may become mature in the course of a few weeks or months. In adults it may increase but slowly, particularly if the stripes are narrow and few in number. Broad stripes and large flocculent opacities indicate a rapid progress. This form is not unfrequently confined to one eye. As cataract is not of very common occurrence even before the age of fifty, we should always ascertain whether it may not have been produced by some special cause, such as injury to the lens or internal inflammation of the eye. If both eyes are affected, the urine should be tested for the presence of sugar, as diabetes is a not unfrequent cause of cataract.

Cortical cataract is always soft. In children it may be almost fluid. Although its consistence increases with advancing years, it is generally up to the age of thirty or thirty-five free from a hardish nucleus, and sufficiently pulpy to be readily removed by linear extraction.

When a mature cortical cataract has existed for some time, it may undergo certain retrogressive changes. Its fluid and fatty constituents may become absorbed, and the cortical substance become more dry and consolidated. As absorption proceeds, the cataract shrivels up, the anterior capsule becomes wrinkled and recedes from the pupil, so that a more or less deep posterior chamber is formed.

The capsule sometimes looks like a little wrinkled bag, containing small white chalky chips of lens. In very young subjects the greater portion of the lens may become absorbed, so that finally there is nothing left but a small white shrivelled disc, of a hard chalky consistence. This is the chalky or "siliculose" cataract of old writers. Although this form may occur simply as the result of the absorption of the softer constituents of an ordinary cataract, it is still more frequently met with in deep-seated inflammatory lesions of the eyeball, as, for instance, in

* "A. f. O.," i, 2.

the latter stages of irido-choroiditis. But the fluid constituents, instead of becoming absorbed, may increase, the structure of the lens breaking down, so that the cataract may become extremely soft or even fluid, which is especially the case in children. In adults, more particularly after the age of thirty, the harder nucleus sets a limit to the process of softening, which can then only affect the cortex and not the whole lens. Now, if in such cases the cortical substance becomes fluid, the hard yellow nucleus will sink down in it, and thus the so-called "Morgagnian" cataract will be produced.

The chief characteristics of fluid cataract are, that the opacity is of a milky-white or dirty grey colour, that it is homogeneous, and that it reaches quite up to the anterior capsule, on the inner side of which are often observed small white dots. There are no opalescent stripes, and the anterior layers of the cortex are not translucent.

III. *The Nuclear or Hard Senile Cataract.*—It has been already stated that after the age of from thirty to thirty-five the lens undergoes certain physiological changes. The nuclear portion becomes firmer and more consolidated, and assumes a yellow tint. This condition may exist for many years without any marked increase, without deterioration of sight, or without any opacity being observable with the ophthalmoscope; but the division between the physiological and pathological consolidation and cloudiness is only one of degree. When these senile changes increase to such an extent that the sight is perceptibly impaired, and when the opacity of the lens is progressive and becomes marked even by transmitted light, I think that we must then no longer consider it as a physiological condition, but as commencing nuclear cataract. In the latter case the nucleus presents a marked yellow or yellowish-brown tinge, and is easily distinguishable from the cortical substance, which may remain clear, except perhaps in the immediate vicinity of the nucleus. With the oblique illumination the cataract will appear as a round yellow opacity, situated some distance behind the pupil. The anterior layers of the cortical substance are translucent and transparent, so that we can see through them into the centre of the lens, and the pupil throws a deep shadow upon the surface of the opacity. The nuclear cataract may be very dark, even black in colour, which is due to the imbibition of hæmatine. The "black cataract" may easily be overlooked if the eye is not examined with the ophthalmoscope or the oblique illumination.

Pure nuclear cataract is but rarely met with. In the great majority of cases of senile cataract the cortex is also affected, so that we have in truth a mixed form—viz., a hard yellow nucleus with a more or less firm cortical substance. I think it well, however, to retain the name of "nuclear" cataract for the senile form, as indicating the presence of a hardish nucleus.

Senile cataract generally commences at the periphery of the lens in the form of small centripetal stripes, between which we may often notice smaller and shorter spikes, situated at the very margin of the lens. The stripes may run along the anterior or posterior surface of the lens, the interjacent substance being clear. The opacity gradually becomes more general, and involves more and more the centre of the lens; the intervals between the stripes becoming clouded and perhaps studded with small opaque dots or patches. As the cataract progresses, the distinction between the nucleus and the cortex becomes more marked, the former showing a distinct yellow tint.

Sometimes the stripes commence in the posterior cortex, extending from the margin to the posterior pole of the lens, where they coalesce, the opacity thus assuming a stellate appearance. The intervals between the stripes may remain transparent for some time, as also the nuclear portion of the lens, so that we can see quite to the back of the latter. The view of the background of the eye is of course obscured in the centre by the confluence of the stripes, but if the segments between them are clear, we may yet at the periphery distinguish the details of the fundus; such forms are often extremely slow in their progress. When opacities commence at the posterior pole of the lens, either in the form of centripetal stripes or of circumscribed spots or patches, the general condition of the eye should be carefully examined, as this form of cataract (posterior polar cataract) not unfrequently shows itself in the latter stages of sclerotico-choroiditis posterior, retinitis pigmentosa, detachment of the retina, and other deep-seated lesions. The co-existence of any such complication would, of course, materially affect our prognosis of the result of an operation.

We occasionally meet with incipient cataracts in which there is a marked difference between the amount of the opacity, according to whether the oblique illumination or the ophthalmoscope be used for examination. On account of the great opalescence of the stripes, it is very apparent to the naked eye and with the oblique illumination; yet, on testing the vision, we find it surprisingly good, and with the ophthalmoscope we can, with a little management, clearly distinguish the details of the fundus. I have noticed this peculiarity several times in myopic patients; the progress has generally been very slow.

In the majority of cases, one of the first symptoms noticed by a person affected with incipient cataract is, that distant objects appear somewhat indistinct and hazy, or as if surrounded by a halo. After a time, near objects also become indistinct, and in reading, the print has to be approximated closer to the eye or observed through a strong convex lens, in order that a larger retinal image may be gained. If the opacity is chiefly or entirely confined to the centre of the lens, the margin being clear, the patient will see best when his back is turned to

the light, or when he shades the eye with his hand, so that the pupil becomes somewhat enlarged. Dilatation of the pupil by a very weak solution of atropine will have the same effect. If the cloudiness be confined to the margin of the lens, the reverse will obtain; the sight will be best when the pupil is small.

Sometimes, persons suffering from incipient senile cataract complain that they are getting myopic, requiring the aid of a concave glass in order to distinguish distant objects. The reason of this fact is somewhat doubtful, and can only be explained upon the supposition that there is some increase in the volume of the lens which gives it a higher refractive power.

It was formerly thought that senile cataract almost always commenced at the centre of the lens, and extended thence towards the margin. This opinion led to great mistakes, and caused incipient cataract to be often entirely overlooked.

On examining a mature senile cataract with the oblique illumination, we at once notice the presence of a yellow nucleus. Its size may be estimated from the extent of the yellow reflex, its hardness from the depth of the colour. The darker the yellow tint, the harder and more compact will the nucleus be. The cortical substance is of a grey or bluish-white colour, traversed by numerous centripetal opalescent stripes, and studded perhaps with small white dots or patches.

The rate of progress of senile cataract is very difficult to determine with accuracy. It is far more rapid in the cortex than in the nucleus. Sometimes, years may elapse before it arrives at maturity. It may remain at an incipient stage for a very long time without apparently making any progress, and then suddenly advance very rapidly, arriving at maturity within a few months or even weeks. We must, therefore, always be upon our guard against giving a decided opinion as to when any given case of incipient cataract will be fully formed and fit for operation. Patients are sure to ask this question, and we may fall into great mistakes by giving a decided answer. This can only be predicted with anything like certainty, when the progress of the case has been constantly watched. As a general rule, I may state that if the cortical substance presents broad, white, opalescent stripes and large flakes or spots, the progress is more rapid than if the stripes or spots are small and narrow, and the intermediate lens-substance clear.

Senile cataract occurs most frequently after the age of 50 or 55, and sooner or later generally affects both eyes.

When a mature senile cataract has existed for some length of time, it may also undergo some retrogressive changes; but these are far less than in the cortical cataract, for they only affect the cortical substance and not the nucleus, which becomes harder and firmer. The fluid constituents may be partially absorbed, and some of the elements may

undergo a fatty or chalky degeneration, so that the cataract diminishes in thickness and becomes flatter, but is very coherent. The molecules are aggregated together into small masses, which become adherent to the inner surface of the capsule, or are often collected at the margin of the lens. They may prove in so far dangerous, that they are very apt to remain behind in the capsule when the cataract is extracted, and give rise to secondary cataract. In very rare instances, a great portion of the cataract may be absorbed and the sight of the patient materially improved. In the majority of cases, the yellow nucleus may still be seen shining through the cortical substance, but now, however, no longer in the centre, but sunk down to the bottom of the capsule (Morgagnian cataract). If the cortical substance is grey, very opaque, and pretty uniformly studded with fine dots or patches, it may be considered as soft, not, however, pulpy or diffluent, but friable, so that small coherent portions are apt to remain behind, and adhere to the pupil or the corneal section after the chief portion of the cataract is removed.

2.—TRAUMATIC CATARACT.

When the capsule is perforated or torn by a sharp instrument, the aqueous humour is admitted to the lens substance, which may become rapidly opaque. If the perforation is extremely small and superficial, such as might be produced by a very fine needle, the danger may be but slight. The lips of the wound in the capsule may unite, and no permanent, or only a very limited, opacity may remain; but if the wound is larger, much aqueous humour is admitted, the lens will swell up very rapidly, and will press upon the iris and ciliary body. The iris is often considerably lacerated, or protrudes through the corneal wound, and this greatly increases the irritation and danger of severe inflammation. Flakes of softened lens matter, or broken portions of lens, fall into the anterior chamber, and, coming in contact with the anterior surface of the iris, produce great irritation; or portions of lens matter may exude through or become entangled in the wound. The inflammation, which may involve the iris, ciliary body, and choroid, may assume either a purulent or a serous character. In the latter case, there may be more or less increase in the intra-ocular tension, with the attendant train of glaucomatous symptoms. In children the danger of secondary inflammation is less than in adults, as the lens is softer, the iris less impatient of pressure, and absorption more rapid; in fact, the lens may be almost entirely absorbed, so that finally there only remains a small, hard, white disc. The lens becomes more rapidly opaque in the young than in elderly persons. I have occasionally met with cases in youthful individuals in which, a few days after the injury to the lens, the latter had become almost completely cataractous. The swelling of the lens

is often very considerable, so that its volume is much increased; the iris is consequently pushed forward and the anterior chamber diminished in size. This pressure of the swollen lens upon the iris and ciliary body produces great irritation, and may give rise to severe irido-cyclitis. The danger is very great when a foreign body—*e.g.*, a piece of gun cap or a chip of steel—is lodged in the lens, or, having passed through it, is fixed in the deeper tissues of the eye, as it is frequently followed by a most destructive inflammation. After any injury to the lens, the history of the accident should be inquired into, and if it was caused by a chip of steel, a shot, etc., the condition of the eye must be carefully examined, in order that we may, if possible, ascertain whether the foreign body be still in the eye, and whereabouts it is situated. After an injury to the lens, the condition of the eye must be anxiously watched. The tension of the eyeball, the state of the sight and of the field of vision must be frequently examined, so that the earliest symptoms of any glaucomatous complication may be detected, and, if possible, cut short. The danger of sympathetic ophthalmia must also be kept in mind. A traumatic cataract may also be produced through a simple contusion of the eye without any laceration or rupture of the external coats of the eye. Thus a blow upon the eye or over the head from the fist, or some blunt body (a piece of wood, whip, etc.) may give rise to traumatic cataract. Special attention to this fact was called by Mr. Lawson some years ago, who recorded several instances of the kind.* In such cases, however, the capsule is generally ruptured, in most instances, as was pointed out by Von Graefe,† at the periphery of the lens, just where the thick anterior passes into the thin posterior capsule. Sometimes, however, no tear in the capsule can be detected.

3.—CAPSULAR CATARACT.

Capsular cataract presents a white, chalky appearance, and is situated in the area of the pupil. Strictly speaking, this term is inaccurate, for the capsule itself appears never to become opaque, for although it may become wrinkled and changed in thickness, it retains its transparency. According to Heinrich Müller,‡ these opacities are not owing to any changes in the structure of the capsule itself, but are situated at its inner side, and are due to the deposition of new layers of a substance which is often much akin in its nature to that of the capsule, but in other cases is of a fibrous character. Schweigger§ insists strongly

* Vide "R. L. O. H. Rep.," iv, 179; also Mr. Lawson's book, "On Injuries of the Eye," p. 130.

† "Kl. Monatsbl.," 1864, 19. A translation of this Lecture upon Traumatic Cataract will be found in the "Ophth. Review," ii, 137.

‡ "Archiv. f. Ophthal.," iii, 1, 56.

§ Ibid., viii, 1, 227.

upon the fact that capsular cataract only occurs as a complication of a previous cataractous opacity of the lens. Thus, when the fluid constituents become absorbed in a retrograding cataract, the harder portions may become adherent to the inner portion of the capsule, and thus produce an opacity of the latter. The intra-capsular cells are either not at all, or but slightly involved in an uncomplicated cataract; but if it is complicated with irido-choroiditis, great proliferation of these cells takes place, and they have a considerable share in the formation of the capsular cataract. The capsule, although transparent, is often somewhat wrinkled. As capsular cataract occurs most frequently in the later stages of irido-choroiditis, the history of the case and the general condition of the eye must be carefully examined before any operation is undertaken.

Anterior central capsular cataract may be congenital, but is more frequently formed in early childhood in consequence of a perforating ulcer of the cornea. It occurs in this way: if an ulcer, which is situated at or near the centre of the cornea, perforates the latter, the aqueous humour escapes, the iris and lens fall forward, and come in contact with the cornea. Plastic lymph is effused into the ulcer, and a little nodule of this is deposited upon the centre of the capsule. As the pupil contracts on the escape of the aqueous humour, only the central portion of the capsule remains uncovered by the iris, and this is, therefore, the place where the cataract is formed. As the nutrition of the lens is impaired near the deposit of lymph, the superficial layers of cortical substance in its vicinity become somewhat opaque. The ulcer of the cornea heals, the iris and lens recede to their former position, but the opacity on the anterior capsule remains. If the cornea subsequently becomes transparent, the origin of the capsular cataract may remain unsuspected. When this central capsular cataract is very prominent, and elevated above the surface of the capsule, it has been termed "*pyramidal cataract;*" but even in such cases, Müller has found that it is covered by transparent capsule. Mr. Hutchinson* does not consider that the form of cataract is generally produced by a perforation of the cornea when it is observed to occur after purulent ophthalmia. He believes rather that "the mere proximity of the inflammatory action on the surface of the conjunctiva and cornea suffices to disturb the nutrition of the lens-capsule, and to produce deposits."

I will now pass on to the different operations suitable to various forms of cataract, commencing with the flap extraction; but before so doing, I must touch upon certain important preliminary considerations.

It is generally deemed important that a cataract, especially the

* Vide Mr. Hutchinson's paper, "On Pyramidal Cataracts, with speculations as to their Cause."—R. L. O. H. Rep., vi, 136.

senile form, should be mature before it is submitted to an operation. In mature cataract the opacity involves the whole lens, and the iris throws little or no shadow upon it. The sight is so much impaired that the patient is unable to distinguish the largest print, or to count fingers. If the cataract is immature, it will not come out *en masse*, but the transparent portions of lens substance are stripped off, and remain adherent to the capsule or the edge of the pupil. They swell up very considerably, and may produce great inflammation or a dense secondary cataract. These observations do not of course apply to zonular cataract, which may never become mature. The question now arises, what should be done if the cataract remains immature for a long time, yet is so advanced as greatly to impair vision? Can we hasten its progress? Undoubtedly, but we run some risk in so doing—a risk which should not, I think, be incurred except under peculiar circumstances. If, for instance, a person who is entirely dependent upon his sight for his means of subsistence is affected with double cataract, whose progress is extremely slow, and which, though very immature, is sufficiently dense to prevent his following his customary occupation, it may be advisable to hasten the progress of the cataract. This is to be done by gently pricking the lens with a fine needle, so as to slightly divide the capsule and the lens substance, and admit a little aqueous humour. This may be repeated several times, care being taken not to divide the lens too freely at one sitting, lest a severe iritis or irido-choroiditis be set up. The pupil is to be kept widely dilated with atropine, and the state of the eye narrowly watched, for fear of any severe inflammatory symptoms ensuing. It is safer still, as was recommended by Von Graefe, to make preliminary iridectomy, so as to afford more room for the swelling up of the lens; moreover, the existence of an iridectomy would prove of advantage when the final operation of removal of the lens is performed. But not many patients will submit to such repeated operations. This proceeding is, however, accompanied by the disadvantage that it necessitates two operations, with an interval of some weeks between them. This often proves of much inconvenience and anxiety to patients who come from a distance, or to those who are of a very timid and nervous character. Since the introduction of Von Graefe's new operation, I must confess that I have paid less heed to the necessity of waiting with the operation until the cataract is quite mature, for I have obtained excellent results where this has not been the case; indeed, I have removed with perfect success cases of lamellar cataract in persons above the age of 25. As a rule, I should, however, *prefer* to operate on a cataract which is quite mature, as it affords a better chance of complete removal. Again, instead of hastening the progress of the cataract, the lens may be removed in its capsule, which obviates the danger of unripe portions being left behind. This operation, which

has been strongly advocated by Pagenstecher and Wecker, I shall have occasion to speak of again. Whilst, on the one hand, it is dangerous to operate too early, it may also be wrong to wait too long after the cataract is fully formed. In children especially, we should operate early, for otherwise the sight and the sensibility of the retina may permanently suffer, and oscillation of the eyeball (nystagmus) may also be produced. Later in life, a mature cataract may exist for very many years without the sensibility of the retina being affected by this passive exclusion from the act of vision. But in children it is different; in them the passive suppression of the retinal image produced by the cataract, appears to exert a similar influence upon the sensibility of the retina, as the active suppression which occurs in cases of squint, and which often rapidly leads to great amblyopia. Again, we have seen that when a mature cataract has existed for some time, it may undergo certain retrogressive changes, its fluid constituents may become absorbed, fatty or calcareous masses may be collected at its margin or adhere to the capsule, and remain behind when the lens is removed, giving rise to inflammatory complications and secondary cataract. It is wiser, therefore, to operate before such secondary changes have set in.

Should we operate upon the one eye if the other is quite free from cataract? I think it is advisable, where the operation is almost certain of succeeding, as, for instance, in the discission or linear extraction of cataract of young individuals. The operated eye, although differing greatly in its state of refraction from the other, will still assist somewhat in the act of vision. The visual field will be extended, and the fear of amblyopia will be removed, as the eye may be separately practised with suitable convex glasses. Moreover, the personal appearance will be improved.

Should both eyes be operated upon at the same time in cases of double cataract? It is doubtless safer to operate only on one eye at a time. Unsuspected peculiarities in the constitution or the temperament may show themselves in the course of the treatment, a prior knowledge of which may prove of great value in the treatment of the other eye, and lead us, perhaps, to select a different mode of operation. On the other hand, it has been urged that it is very rare to see a bad result (*e.g.*, suppuration of the cornea) in both eyes, if they have been operated upon at one sitting. In this point we must be much guided by personal circumstances. It may be very inconvenient for the patient to have the operations divided, and the treatment thus extended over a long period; or, if he be in a weak and nervous condition, it may be unwise to submit him to the anxiety of two operations. If one cataract is mature and the other only partially formed, but yet sufficiently opaque to prevent the patient from following his customary employment, it may be necessary to operate upon the former, so as to enable him speedily to resume his

avocations whilst the other is advancing to maturity. If no such necessity exists, we generally wait till both cataracts are mature.

It is of little consequence at what time of the year extraction is performed. Formerly it was thought advisable to operate chiefly in the spring and early summer, but we now operate all the year round, except during intensely hot or very cold weather, for extremes of temperature are not favourable for the progress of the case. If the weather is hot and oppressive, the patients become very restless, irritable, and exhausted. The time of day is also of little or no moment, although I myself prefer the morning, for we can then judge by the evening whether or not any primary inflammatory reaction is likely to set in, and if so, we can without loss of time endeavour to check it.

Before an operation is decided upon, the general health must be examined, and if this be at all impaired we must endeavour to improve it as much as possible prior to operating. It is of the greatest advantage for the result of the operation to have the patient in perfect health. The chief fear is, that in a weak and decrepid person the vitality of the cornea may be so low that its healing power is greatly impaired, or that it may even slough after the operation. A symptom of some importance, as being indicative of this low vitality, is the loss of elasticity of the skin, so that if we pinch up a fold of skin on the back of the hand it does not fall back at once, but remains wrinkled. Severe cough or chronic bronchitis contra-indicate flap extraction. If double cataract occurs in youth or early middle age (before the age of 45), and if its formation is rapid, we must examine whether the patient is suffering from diabetes, for this is a not unfrequent cause of cataract. The lens becomes affected chiefly in the later stages of the disease, when the health is much broken. The cataract is generally softish, and its formation rapid. In old persons a more or less large and hard nucleus will be present, but diabetic cataract does not show any special characteristics. If diabetes is found to exist, especial care must be taken to examine the sight and the field of vision, as affections of the retina and optic nerve not unfrequently occur in the course of the disease, and may therefore co-exist with the cataract and render the prognosis of the result of an operation unfavourable.

The general condition of the eye should always be carefully examined before an operation for cataract is determined upon. The tension of the eyeball, the degree of sight, and the state of the field of vision must be ascertained, so that the presence of any deep-seated lesion may not escape detection. Otherwise we might fall into the reprehensible and unjustifiable error of operating upon an amaurotic eye.

Should the patient be suffering from epiphora, dependent upon some affection of the lachrymal apparatus, or from inflammation of the eyelids or the conjunctiva, this should, if possible, be cured prior to the opera-

tion, as any such complication not only enhances the difficulties of the after-treatment, but may even endanger the result of the operation.

The method to be pursued in examining the perception of light and the condition of the field of vision, in a person affected with mature cataract, has been already explained in the Introduction (p. 8). Such a person should be able to distinguish a low burning lamp at a distance of 10 or 14 feet, if his perception of light is good, and there is no lesion of the deeper tunics of the eye. If there is any marked deterioration of the perception of light, or of the field of vision, the history of the case must be carefully inquired into, in order that we may detect the presence of any complication. If the upper or lower half of the field is lost, we must suspect detachment of the retina; if the lateral halves are wanting, an affection of the optic nerves. Cerebral amaurosis generally causes a concentric contraction of the field, or the latter may commence at the temporal side. In glaucoma the contraction of the field begins almost invariably at the nasal side. If such a contraction of the field exists, the tension of the eyeball must be ascertained, and the other symptoms of glaucoma searched for. If glaucoma attacks an eye affected with mature senile cataract, the glaucoma must first be cured by an iridectomy, and then subsequently, at the interval of several months, the cataract should be removed. But this must not be done until all symptoms of irritation and increased tension have subsided, and the improvement in the nutrition and circulation of the eye has been firmly re-established. (*Vide* the article on "Glaucoma").

The pupil should be dilated by atropine before the operation. In a very presbyopic eye, with an exceedingly shallow anterior chamber, there is always some danger, even to an expert operator, of wounding the iris either before the counter-puncture is made, or whilst the flap is being formed. Wide dilatation of the pupil is the best safeguard against such a danger, for the iris will be removed out of the way of the puncture, the counter-puncture, and the line of incision. When the aqueous humour flows off, the pupil again contracts somewhat; but this will not be of much consequence, as the section should by this time be nearly completed. The degree and rapidity with which the pupil dilates under the influence of atropine also affords us a hint as to the probability of iritis. Von Graefe has called attention to the fact that if the iris is easily and quickly affected by atropine, there is less tendency to subsequent iritis than if its action is tardy and imperfect.

The patient should be operated upon in the recumbent position, being placed either on a couch or in his bed. In the Hospital I prefer operating in the ward, as there is considerable risk of the dressing being disturbed in the removal of the patient from the operating theatre. The light should, if possible, come from the side, for this dazzles the patient less, and causes much less reflection upon the cornea

than when it comes from the foot of the bed or from a skylight. The latter, indeed, is the worst light of all for eye operations, more especially those of a very delicate nature.

The position which the operator is to assume with regard to the patient will depend upon which eye is to be operated on, and upon the fact whether the surgeon is ambidexter or not. Some think it a *sine quâ non* that an oculist should be able to use both hands equally well; but this is not the case. By changing his position, he may always operate with the right hand upon either eye, either by the upper or lower section. Yet I strongly advise every surgeon to practise operating with the left hand, for he will constantly find it a great advantage to be able to use it well. For instance, in performing iridectomy it is very desirable that he should be able to grasp the iris with the forceps held in the left hand, and snip it off with the scissors in the right, or *vice versâ*. Still, if he finds after much practice on the dead subject, that he cannot operate for extraction nearly so well with the left hand as with the right, he should not endanger the result of the operation by using the left hand. If the left eye is to be operated on (either by the upper or lower section), the surgeon, if he is not ambidexter, is to seat himself on the couch in front of the patient, and on his left side. If he operates with his left hand, he will stand behind the patient. The latter position is also to be assumed when the right eye is to be operated on.

4.—FLAP EXTRACTION.

The section may be made either upwards or downwards, as the advantages are pretty evenly balanced. The downward section is, however, the easier of the two. There is often, moreover, an uncontrollable tendency for the eye to roll upwards beneath the lid, which materially enhances the difficulties of the operation, and may greatly embarrass the operator, especially during the laceration of the capsule and the exit of the lens. The chief advantages of each mode of operating may be briefly stated to be as follows:—In favour of the upper section, it may be urged that the broad smooth surface of the inside of the upper lid will lie in contact with the section and support it, and thus facilitate the union; whereas the edge of the lower lid may rub against the lips of the incision, or even get between them, set up considerable irritation, and prevent the union by first intention. Again, if in the upper section the wound does not unite by first intention, either from the occurrence of prolapse of the iris, or suppuration of the edge of incision, the cicatrix thus produced will be hidden by the upper lid. But to this it may be objected, that if the prolapse has produced much distortion of the pupil, the latter may be so much covered by the upper lid as greatly to impair the vision; so that it will be necessary to make

an artificial pupil in another direction. The advantages offered by the lower section are, that it is more easy of performance; as are also the division of the capsule, the exit of the cataract, and the removal of the remains of cortical substance. The cornea is, moreover, less liable to be bruised, and should suppuration of the cornea occur, it is more likely to limit itself than in the upper section. Bearing these points in mind, I should advise the beginner at first to perform the lower section, until he has acquired sufficient dexterity and experience in operating to give each method a fair trial.

The instruments required for flap extraction are—1. An extraction knife. 2. A pair of forceps for fixing the eyeball. 3. A pricker or Graefe's cystotome, for dividing the capsule. 4. A curette, which, for convenience sake, is fixed to the other end of the pricker. 5. A blunt-pointed secondary knife. 6. A blunt-pointed pair of scissors.

Various forms of extraction knives are recommended by different operators. I myself prefer Sichel's knife (fig. 28). It is rather long

Fig. 28.

and narrow, and increases regularly, but not too abruptly, from point to heel, so that the flap is formed by simply pushing the blade on through the anterior chamber until the section is completed. Its wedge shape fills up the gap, and prevents the premature escape of the aqueous humour. The handle is to be lightly held between the thumb, fore, and middle finger, the thumb being slightly bent outwards at the joint. The elbow must be kept close to the side and the wrist steady, so that all movements are made from the fingers and hand.

I will now proceed to a description of the operation, and I shall throughout suppose that the right eye is to be operated upon by the upper section.

I shall enter somewhat at length into the description of the mode of operating, the accidents which may occur, and the principles which should guide us in the after treatment, because most of these questions are of importance in every mode of operating for the extraction of cataract; hence it is absolutely necessary that the surgeon should be acquainted with them, even although he may entirely abandon the common flap extraction for Von Graefe's new operation.

The operator should stand or sit behind the patient, who is to be placed in the recumbent position. If he is about to operate without fixation, he will hold the upper eyelid with the forefinger of his left hand, drawing it upwards and away from the eye. The tip of the second finger is to be placed gently against the sclerotic on the nasal side of

the cornea, so as to prevent the eye from rolling too far inwards. An assistant is to draw the lower eyelid down without everting it. Many of our best operators do not employ fixation, and generally make admirable sections; but yet cases will occur in which even the most skilled operator does not make the counter-puncture just at the desired point. The chief difficulty in operating without fixation is, that the eye may roll swiftly inwards directly the puncture is made, or even before, so that the cornea becomes almost hidden in the inner canthus, and the knife has to traverse the anterior chamber and to make the counter-puncture without the operator being able to see its course. This will prove extremely embarrassing to the beginner, and may even unnerve him for the remainder of the operation. I should, therefore, strongly recommend him to fix the eyeball, as this greatly facilitates the first part of the operation, and as there is not the slightest objection to his doing so. It has been objected that the fixation often produces pain and much irritation, but this will hardly occur, if it be gently and carefully done. Moreover, so sensitive an eye would prove most difficult to operate upon without fixation. Afterwards, when the operator has gained more confidence and dexterity, he may do without it, if he chooses. Various instruments have been devised for this purpose, but the common eye forceps are the best. Their use in this operation has long been advocated by Von Graefe, and more lately by Mr. France. As soon as the counter-puncture is made, they are to be removed, for the eye is then completely under our control. The operator should rather fix the eye himself than entrust this to an assistant, for it is impossible that their hands can work together with such unanimity as if both hands are guided by the same volition. If fixation be employed, an assistant must hold the lids. If the right eye is to be operated on, he should stand on the left side of the patient, and place the tips of the fore and second finger of his right hand upon the edge of the upper lid (without touching the lashes), and draw it gently upwards and a little inwards, away from the eyeball. If the lids are at all moist, a piece of linen may be folded around the fingers, so as to prevent their slipping. The lower lid is to be held with the forefinger of his left hand. But if the assistant is not dexterous and trustworthy, and the surgeon cannot operate well without fixation, the spring speculum may be employed to keep the lids apart, but I am rather afraid of it, as it is apt to irritate the eye, and to press upon the eyeball.

The operation is divided into three periods—1st. The formation of the flap; 2nd. The laceration of the capsule; 3rd. The removal of the lens.

First Period.—Let us again assume that the right eye is to be operated upon by the upper section, and that the operator will fix the eye. Holding the forceps in his left hand, he seizes a fold of conjunc-

tival and subconjunctival tissue near the lower edge of the cornea (as in Fig. 29, after France), or, as I prefer it, rather more to the nasal side, and draws the eyeball gently down, so as to bring the cornea well into view. Then, holding the knife lightly in his right hand, and steadying the latter by placing his ring or little finger against the temple, he enters the point at the outer side of the cornea about a quarter of a line from its edge, and just at its transverse diameter, and then carries the blade steadily and rather slowly across the anterior chamber to the point of counter-puncture, keeping it quite parallel to the iris. Special care must be taken not to rotate it or to press upon its edge, but rather to press upon the back of the blade, as if, in fact, he were wishing to cut with this. If this be done, the blade will be pushed steadily on and fill up the gap, thus preventing the premature escape of the aqueous humour. I find this pressing upon the back of the blade one of the most difficult things for the young operator to acquire. The eye of the operator is not to be kept fixed upon the point of the knife, but upon the point where he wishes to make the counter-puncture, for this will insure the knife being brought out at the desired spot, which should lie slightly in the upper half of the cornea, about a quarter of a line from its edge. As soon as the counter-puncture is made, the forceps are to be removed and the handle of the knife turned back towards the temple, the blade being pushed steadily on until the section is all but finished. When only a small bridge of cornea remains undivided, the section is to be slowly completed by turning the edge of the knife a little forwards, and, instead of carrying it straight on, drawing it back from heel to point until the section is finished. Von Graefe insists especially upon the advantage of doing this, for as the narrowest part of the blade thus issues last from the incision, the flap will be less elevated than by the broad part; moreover, the altered position and direction of the knife cause a relaxation in the tension of the muscles of the eye, and thus diminish straining. When the incision is completed, the upper lid is to be gently and carefully dropped, so that it may not catch in between the lips of the wound and evert the flap. The patient having been calmed by a few words of encouragement, we pass on to the

Fig. 29.

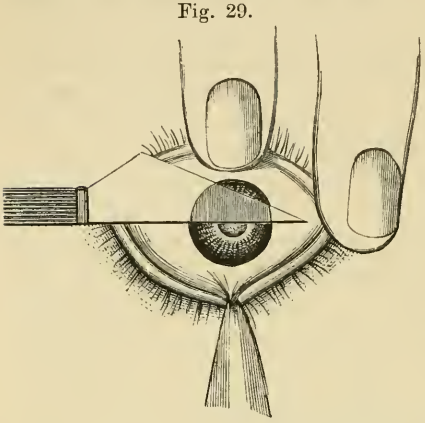

Second Period, the Opening of the Capsule.—This may be done either

with the pricker (Fig. 30, which represents this instrument, together with the curette, which is placed at the other end of the handle), or with Graefe's cystotome. The patient is directed to look well down to his feet, and the upper lid being slightly lifted, the pricker is introduced

Fig. 30.

Fig. 31.

with its blunt angle downwards. When arrived at the inner side of the pupil, it is slightly rotated, so as to turn its point against the capsule, which is to be divided across as far as the outer edge of the pupil by one or more incisions. The point is then turned downwards, and the instrument carefully removed, so as not to entangle it in the iris or cornea. For flap extraction I prefer Graefe's cystotome (Fig. 31—beside it is an enlarged view), as it makes a freer opening, and as we need not change its horizontal position in lacerating the capsule, whereas the handle of the pricker requires to be a little elevated, which causes more or less gaping of the section. Care must be taken not to press the point of the pricker or cystotome against the lens in dividing the capsule, otherwise we may cause a displacement of the lens into the vitreous humour.

Third Period—Removal of the Lens.—The patient being again directed to look downwards, the point of the forefinger, or the end of the curette, is to be placed against the lower lid, and a gentle, but steady, pressure made upon the globe. The point of the other forefinger may be placed on the upper portion of the eyeball, so as to regulate and alternate the pressure to a nicety. The pressure on the lower lid should be at first backward, in order that the upper edge of the lens may be tilted slightly forward against the upper portion of the pupil, which gradually dilates and permits the presentation of the lens. The pressure is then directed a little more upwards and backwards, so that the lens advances through the pupil into the anterior chamber, and makes its exit through the incision. If it halts a little in its course through the section, it may be extracted with the curette. The pressure throughout should be steady, but very gentle, in order that the lens may not be violently jerked out, which is generally accompanied by

rupture of the hyaloid membrane and an escape of vitreous humour. When the lens has been removed, we should examine its outline to see whether this is perfect, or whether it is irregular or notched, as the latter shows at once that portions of the cortical substance have remained behind. If the cataract is not quite mature, fragments of cortex are apt to remain in the capsule, or are stripped off during the passage of the lens through the pupil or the corneal incision, to either of which they may cling. These portions should, if possible, be removed, as they are very apt to set up iritis or to give rise to secondary cataract. The lids are, therefore, to be closed and lightly rubbed in a circular direction, so that any little flakes remaining behind the iris may be brought into the area of the pupil, whence they are to be gently removed with the curette, as also any portions adhering to the lips of the wound. The vision of the patient may also be tested by trying if he can count fingers, and if it is not as good as might be expected, we may examine again as to whether remnants of lens substance still linger behind.

We must now briefly consider what course is to be pursued if any untoward circumstances arise during the different steps of the operation.

Under the following circumstances, it is advisable to withdraw the knife at once, and to postpone the operation until the wound is united :— 1. If the puncture is too near the edge of the cornea, or in the sclerotic. 2. If it is too far in the cornea, so that the flap would be too small. 3. If the aqueous humour spirts out when the point of the knife has only just entered the anterior chamber, for the iris will then fall forward upon the knife, which would become entangled in it, so that it would be impossible to finish the section without lacerating the iris considerably. 4. If the point of the knife is so blunt that it will not readily make the counter-puncture.

Should the aqueous humour escape directly the counter-puncture has been made, the section may yet be finished without wounding the iris, by placing the point of the fore or middle finger of the other hand, upon the edge of the blade, and pushing the iris off from it as the section is being slowly completed. If, however, it is impossible to avoid wounding the iris, it is better to cut boldly through it, as this is far less apt to excite iritis than if the knife becomes entangled in it. If the counter-puncture is too close to the sclerotic, the knife must be slightly drawn back, and another counter-puncture made, or the size of the section be diminished by turning the edge of the blade slightly forwards in finishing the flap. This should also be done when the counter-puncture is too low. If it be too high, the flap will be too small, and this may be remedied (1) by making another counter-puncture a little lower down, (2) by turning the edge of the blade back in cutting

ont, or (3) by enlarging the section downwards with a secondary knife or a pair of blunt-pointed scissors. The last proceeding is to be preferred if the counter-puncture is much too high. If we purpose doing this, the section is to be continued until only a little bridge of cornea is left standing (Fig. 32, *a*). The knife is then to be withdrawn, and the section enlarged by dividing the cornea to the required extent at the counter-puncture with the probe-pointed secondary knife (Fig. 33), or with a pair of blunt-

Fig. 32.

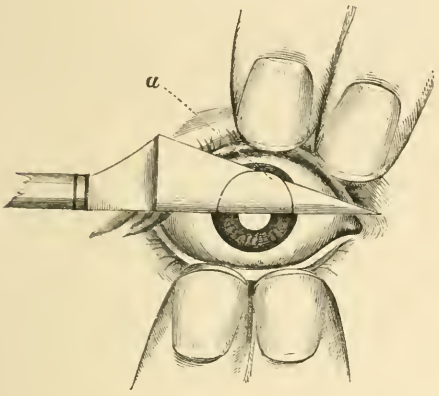

Fig. 33.

pointed scissors. The advantage of leaving the little bridge standing is, that it will keep the cornea tense, and prevent its yielding before the knife or scissors. The bridge is then to be divided, or before so doing the capsule may be opened. The size of the flap should always be noted before the section is completed, so that we may enlarge it in the above manner if necessary. If the section is too small to permit the ready exit of the lens, there is much danger of rupture of the hyaloid membrane and escape of vitreous humour, and of bruising of the iris and cornea. It is also advisable to leave the bridge standing if the patient is very unruly, and strains greatly as we are making the section. A few moments' rest will generally suffice to restore his quietude, and then the bridge may be divided.

If the lens does not, at the third period, readily present itself in the pupil, we must on no account attempt to force this by pressing strongly on the eye; but we must lacerate the capsule again, and more freely than before. If the capsule be so tough as not to be readily torn with the cystotome, it sometimes comes away with the lens, or it may be divided with the point of the knife, or be afterwards removed with a hook or a pair of iris forceps.

If a little vitreous humour escapes with the lens, it is but of slight consequence. The protruding portion is to be snipped off, and a firm compress applied. But it is very different if it escapes before the lens,

for then it will push the latter aside, so that it may even fall to the bottom of the vitreous humour. If this accident should occur, a hook or scoop should be passed behind the lens, and the latter gently "fished out." It should be extracted at all hazards, for if it remains behind it is but too likely to set up a most destructive and painful panophthalmitis.

After the exit of the lens, the corneal flap sometimes becomes wrinkled and collapsed, so that it falls away from the line of incision. This wrinkling is due either to decrease of the intra-ocular tension, or to a diminution in the elasticity of the cornea. Von Graefe lays great stress upon the importance of this symptom, considering it unfavourable if the collapse be at all considerable, for he has found that suppuration of the cornea often occurs in such cases. If we therefore find, in a case of double cataract which is to be operated on at one sitting, that the cornea of the first eye becomes much wrinkled after extraction, it would be wise to submit the other eye to a different mode of operation. In such cases, also, great care must be taken that the flap is not turned back when the upper lid is let down. If the iris protrudes between the lips of the wound after removal of the lens, or if the pupil is distorted, the lids should be closed and lightly rubbed in a circular direction, so as to replace the iris, and restore the regularity of the pupil. If the prolapse still persists, it may be gently replaced with the curette. But if all our efforts prove unavailing, it is by far the best course to draw it out a little further and snip it off. The iridectomy will not be of the slightest disadvantage, more especially in the upper section; in fact, it may prove of positive advantage, not only in favouring the cure, but also in exposing remnants of lens substance which may be situated behind the iris, and have, perhaps, caused the prolapse; whereas the occurrence of prolapse after extraction is one of the chief dangers and annoyances of this operation. The protruding portion of iris sets up considerable irritation, and prevents, perhaps, the union of the section, the aqueous humour flowing off through the fistulous opening; and this constant irritation may set up iritis or irido-cyclitis. Even if the iris unites with the section, a broad unsightly cicatrix will be left, the pupil being, perhaps, greatly distorted or almost obliterated. To prevent all these untoward complications, I strongly advise the removal of a portion of the iris if the prolapse cannot be easily returned, or if the iris has been much contused by the exit of the lens, or by our endeavours to restore the prolapsed portion.

Hæmorrhage into the vitreous humour is a disastrous occurrence. It may take place either at the time of the operation, or some hours afterwards. The patient complains of a sudden sharp pain, a gush of vitreous takes place, followed by blood, and the eye is lost. In such cases there generally exists a diseased condition of the choroidal and retinal vessels, detachment of the retina, etc.

The *after treatment* of flap extraction is a subject of great importance, as much may be done by timely care and attention. As it is of consequence to detect and combat any unfavourable symptoms at the earliest stage, the surgeon should visit the patient very frequently during the first few days after the operation, and, if possible, himself change the dressings, so that he may watch the condition of the lids, the quantity and character of the discharge, etc. As the after-treatment of the different operations for cataract involves the same principles, I shall lay down certain broad general rules of treatment, which will, however, require modification according to the exigencies of particular cases. At one time the antiphlogistic treatment was in great repute. Local and general depletion were had recourse to, and perhaps repeated several times, upon the slightest appearance of pain or inflammatory symptoms. But now this mode of treatment has justly fallen into disuse. Our primary object is to obtain adhesion of the corneal flap by the first intention, and this will take place far more readily in a strong healthy person, than in one who is weak and decrepid; nearly one-half of the cornea has been divided, and for a time the other half has to carry on the nutrition of the whole, and to assist in the process of union. It must also be remembered that this operation is generally performed in persons above the age of 50 or 55, and even indeed in the very aged, whose vital powers will not bear depression. The general health and the reparative power of the system must therefore be sustained. The better and stronger the patient's constitution is, the more favourable may be the prognosis of the result of the operation. Even the florid, turgid, apoplectic-looking individual warrants a better prognosis than the very aged decrepid person, whose general health is poor and feeble, whose cheeks are pale and shrunken, whose arteries are rigid and skin unelastic. Von Graefe also considers the prognosis less favourable if the eyeball is deep-set and sunken, and the diameter of the cornea short, for in such cases flaccidity and wrinkling of the corneal flap, and suppuration of the cornea, are of not unfrequent occurrence on account of its feeble nutrition.

The after treatment must be varied according to the general health, constitution, and habits of the patient. The diet should, from the commencement, be light, nutritious, and easily digestible. Meat may be allowed once daily; it should, however, be finely minced, so that there is no need for mastication, which would disturb the quietude of the eye. Good beef tea or mutton broth may be given occasionally during the day, but slops are, as a rule, to be avoided. But whilst we endeavour to sustain the patient's strength, we must not fall into the opposite error of over-feeding him. In a very plethoric and full-blooded individual, especially if marked inflammatory and febrile symptoms manifest themselves, a strictly antiphlogistic regimen must be observed. With regard

to stimulants and beer, we must be entirely guided by the patient's constitution and habits. It is very unwise to cut off all stimulants from an individual who has always, and perhaps largely, indulged in their use; we should allow him a moderate amount of his customary beverage, watching the while its effect, and diminishing or increasing the quantity as the case may demand. In feeble, decrepid persons stimulants and malt liquor, together with a good nutritious diet, often prove of great service; quinine and ammonia being also given.

It is well to administer a gentle purgative the day before the operation, so that the bowels may not require to be opened for a day or two after the latter. A mild dose of castor-oil should then be given, in order to prevent any straining; and this may be repeated if necessary.

When the operation has been concluded, the patient is to be placed in bed in a darkened room. At night his hands should be tied to the side of the bed, to prevent his touching his eyes during sleep. The lids of both eyes may be fastened with a strip or two of sticking plaister, although this is apt to irritate from its shrinking and hardening. I myself prefer a light bandage, especially Liebreich's, which is the most convenient for this purpose. If this is found to be too hot, I employ a very thin gauze bandage. A piece of soft linen is to be applied over the eyelid to soak up any discharge, and prevent its clogging and hardening the charpie, a little pad of which is to be next applied, the whole being kept in place by the bandage. But if we desire to exert more pressure upon the eye, we must employ Von Graefe's compress bandage, the application of which, however, demands far more care and practice.

So much care and attention is required in the application of these bandages, and in the regulation of the amount of pressure, that we are but seldom able to entrust this to a nurse. If we cannot change the compress ourselves, or leave this duty to a practised and trustworthy assistant, it is far better to abstain altogether from its use. It should be changed night and morning, and, if the eye feels uncomfortable, even more frequently. The quantity and character of the discharge upon the linen and charpie should be examined, as it affords a clue to the condition of the eye. The edges of the lids should be softly sponged with lukewarm water, so as to remove any hardened discharge from the eyelashes, which may also be smeared with a little cold cream or simple cerate. This will prevent their sticking together, and thus interfering with the ready escape of tears or discharge. Great care must, however, be taken not to rub or press upon the upper eyelid, otherwise the coaptation of the flap may be disturbed and union prevented. Much comfort and relief is afforded by the sponging and cleansing of the eyelids, and the change of the compress. The

eye should not, however, be opened or examined unless we specially desire to ascertain its condition. Union of the flap generally takes place within the first forty-eight hours, or even sooner. Then it is advisable to apply a drop of atropine once or twice daily to the inside of the lower lid, without widely opening the eye. This soothes the eye and dilates the pupil, so that there is less chance of a secondary cataract, as the torn edges of the capsule have no point to adhere against, and will therefore retract and shrivel up. Moreover, should iritis occur, it will be of great advantage to have the pupil already widely dilated. It is an interesting fact that if atropine was applied before the operation, its effect upon the pupil partially returns when the section is united, and the aqueous humour re-accumulated. Should the atropine cause any irritation, a solution of belladonna should be substituted. A few hours after the operation, the patient generally experiences a slight sensation of pressure and smarting in the eye, which lasts for a few minutes, but re-appears at intervals of an hour or two. It is due to an accumulation of tears and aqueous humour. If the pain increases towards night and becomes continuous, and the eye is hot, and the patient restless and uncomfortable, morphia should be administered either internally or endermically. I generally employ the subcutaneous injection, varying in strength from $\frac{1}{6}$th to $\frac{1}{4}$th of a grain. It may be repeated if necessary. If the eye is very hot and painful, much relief is often experienced from cold-water compresses. But their use requires much care and discretion, for if they are applied for too long a time, they may depress the circulation of the part too much, and thus increase the danger of suppuration of the cornea. I have also sometimes found great relief from the application of two or three leeches to the temple, especially in plethoric individuals. I must, however, state that Von Graefe, after having for many years employed leeches, has now entirely abandoned their use during the first three days after the operation. He thinks that they prove injurious, insomuch as they produce in the first instance an increased congestion of the infiltrated structures, and thus favour suppuration of the edges of the wound.* In such cases he much prefers, if the patient be plethoric and robust, a small venesection of from four to eight ounces; also if there is much pain accompanied by considerable lachrymation and swelling of the lids during the first thirty-six hours after the operation, for during this period suppurative inflammation generally commences. But it is not to be employed if suppuration has already set in.

If the case goes on well, without the appearance of any unfavourable symptoms, such as severe pain in and around the eye, swelling of the lids, muco-purulent discharge, or copious lachrymation, the eye should

* Graefe's Clinical Lecture, "Kl. Monatsbl.," 1863, translated in "Ophthalmic Review," No. 3.

not be opened during the first five or six days. Nothing is so bad as being too curious as to the result, and opening the eye too early to assure ourselves that everything is going on well, for this may easily set up iritis. It is very different if unfavourable symptoms arise, for then it is best to open the lids and carefully examine the condition of the eye, so that we may know what is really the matter, and what treatment should be adopted. The upper lid should be gently lifted, and the state of the cornea and iris examined. This is best done by the light of a candle, which should be shaded by the hand of the nurse or assistant until the moment that the surgeon is ready to examine the eye. In this way, the latter is exposed only for a few seconds to the light, and the glare and intensity of the illumination is far less than if daylight is admitted into the room.

But the case may not run so favourable a course. The thinly cicatrised wound may yield, and a portion of the iris protrude through it. This frequently happens a few days after the operation. The patient experiences a feeling of grit or sand in the eye, as if a foreign body were lodged under the eyelid. The lids become swollen, the eye painful, and there is a copious, clear, watery discharge, which, after a time, assumes more of a muco-purulent character. These symptoms may arise suddenly, perhaps, after a fit of coughing or sneezing, which has caused the section to yield. If the prolapse is large, and causes a wide gaping of the wound, the pain and irritation are often very great. The eye should be opened and the real condition ascertained. If protrusion of the iris has occurred, the lids must be gently closed again, and a firm compress applied, which will not only favour the consolidation of the wound by the formation of a layer of lymph over the prolapse, but will prevent its increasing in size, and by the continuance of gentle pressure will even cause it to shrink. Afterwards, when the wound is quite consolidated, and a firm layer of exudation covers the prolapse, the latter may be pricked with a fine needle, as has been recommended by Mr. Bowman, so as to let the aqueous humour, which is distending it, flow off. The prolapse then shrinks and dwindles down. This pricking may be repeated several times. If the prolapse is large and widely distends the section, it may be necessary to remove it, either with scissors or with the extraction knife, a compress being afterwards applied. Some surgeons touch the prolapse with a stick of nitrate of silver, but this often produces great irritation. The prolapse may have so drawn up the pupil that it is quite covered by the upper lid, or even involved in the section, which will afterwards necessitate the formation of an artificial pupil, and this will often also cause the prolapse to shrink. Prolapse of the iris, occurring after extraction, is not only a source of long-continued trouble to the patient, but may even prove very dangerous, by setting up protracted inflammatory

complications—*e. g.*, irido-choroiditis—which may eventually destroy the eye.

But still more dangerous is the occurrence of suppuration of the cornea, which is to be chiefly feared during the first two days. It may be diffuse or circumscribed. The former, according to Von Graefe, occurs generally in from twelve to twenty-four hours after the operation, the latter in from sixteen to thirty-six hours. The lids become swollen and red, the eye painful, and there is a more or less copious muco-purulent discharge. On opening the eye, we may find a considerable degree of chemosis surrounding the cornea. If the suppuration is partial, the edges of the wound will show a yellow purulent infiltration, which extends deeply into the substance of the cornea, the whole of the flap perhaps also becoming opaque. The remainder of the cornea, however, retains its transparency sufficiently to permit our seeing the iris at this point. But if the suppuration is diffuse, the infiltration is not confined to the line of incision, but extends round the cornea, the whole expanse of which assumes an opaque yellow tinge. We must consider diffuse suppuration as hopeless, for the inflammation generally extends to the iris and ciliary body, and in the worst cases general inflammation of the eye (panophthalmitis) ensues. If this occurs, the inflammatory symptoms become greatly intensified, the pain is often excruciating, the lids greatly swollen, the discharge thick, purulent, and profuse. We can then only endeavour to alleviate the sufferings of the patient by the application of warm sedative poultices or fomentations, for all hopes of saving the eye are gone. But the partial suppuration of the cornea must also be regarded with great anxiety, for it may not only pass over into the diffuse form, but it may give rise to suppurative iritis or iridocyclitis, which may end in atrophy of the globe. It has been long a keenly-debated question whether the suppuration commences in the iris and passes thence to the cornea, or whether it originates in the latter, and extends secondarily to the iris and ciliary body. Von Graefe maintains the latter view. According to him, the iritis which occurs at this early stage is propagated or secondary, whereas that which comes on at a later period is primary or simple iritis. In partial suppuration of the cornea we must endeavour if possible to prevent its extension, and this can only be done by supporting the patient by nutritious diet, bark and ammonia, and stimulants, and by the application of a pressure bandage. No other local remedies will prove of any avail. Von Graefe first pointed out the advantage of the pressure bandage in such cases, and I have myself frequently seen it, in his practice, of the greatest benefit in limiting the suppuration of the cornea, and can therefore strongly recommend it. In very feeble decrepid individuals it may be alternated with warm camomile or poppy fomentations, which should be applied for an hour

at intervals of two to three hours. I know that many surgeons will view the application of a pressure bandage to an eye affected with suppuration of the cornea with astonishment and incredulity; it is, however, certain that it often proves very beneficial, and tends more than any other remedy to diminish the swelling of the lids and the discharge, and to limit the suppuration of the cornea. So much care and nicety are required in applying the pressure bandage, that the surgeon should always do this himself, unless he has an exceptionally trustworthy and dexterous nurse. Von Graefe has also called attention to the very important fact, that in very old and feeble individuals suppuration of the cornea may occur without their having experienced the slightest pain or uneasiness in the eye. The surgeon, perhaps, congratulates himself upon the apparently excellent progress of the case, and then, on opening the eye, finds the cornea suppurated.

The primary or simple iritis which may occur after the extraction does not generally come on before the fourth or fifth day after the operation. It may be due to the bruising or contusion of the iris by the instruments, or by the passage of the lens through the pupil, or it may be set up by the irritation produced by portions of lens substance which have remained behind. The patient experiences pain in and around the eye; the lids become swollen, and there is more or less photophobia and lachrymation. On opening the eye, we may find a considerable amount of chemosis surrounding the cornea, which is clear, but the aqueous humour is somewhat clouded, the iris discoloured, and the pupil contracted. If the patient is sufficiently strong, much benefit is derived from the application of leeches to the temples. A strong solution of atropine (four grains to the ounce of water) should be frequently applied, so that the pupil may be widely dilated. Belladonna ointment should be rubbed over the forehead three or four times daily.

If, after flap extraction, the case has throughout progressed favourably, the patient may be permitted to leave his bed for an hour or two at the end of the fifth or sixth day. He should, however, wear a light bandage, and the room be somewhat darkened, but it should at the same time be kept cool and well ventilated. If the remaining in bed proves very irksome, which is apt to be the case in country people accustomed to an active life, it may be well to permit the patient to get up even on the third or fourth day. But then he must be very carefully watched. In a hospital in which there are no special eye wards, the bed should have dark blue curtains round its head, so as to afford a protection against cold and draught, and the bright light of the ward. In such a case I think it also very advisable to keep the patient in bed some days longer than would be necessary in a private room or a special ward. At the end of the first week, the bandage may generally be exchanged for a shade,

and the patient be gradually accustomed to the light. Should, however, any inflammatory symptoms appear, such as photophobia, lachrymation, swelling of the lids, etc., the bandage should be re-applied, and increased care be taken of the eye. If the weather is favourable, the patient may go out into the air at the end of a fortnight. This often proves of great benefit, especially if there is any conjunctivitis, which is apt to become chronic if the confinement to the house has been long. In such a case a weak astringent collyrium should be prescribed.

I have already mentioned that in certain cases of immature senile cataract, in which the progress is extremely slow, and the opacity so advanced or situated (*e.g.*, at the posterior pole of the lens) as to impair vision considerably, it may be advisable to hasten the progress of the cataract by pricking the capsule and admitting the aqueous humour to the lens substance. Great care must, however, be taken not to divide the capsule too freely, as this may cause considerable swelling of the lens substance and give rise to severe iritis or iridocyclitis. It is much better to make only a small opening in the capsule, and to repeat the operation, if necessary, several times, more especially if a considerable portion of the lens is still transparent. If severe inflammation supervenes, and if it does not yield rapidly to antiphlogistics, it is advisable, more especially if the tension of the eye is increased, to remove the lens at once, either by the flap extraction or Von Graefe's operation; in the former case it would be well to make at the same time a large iridectomy.

Von Graefe* has recommended that a downward iridectomy should precede the laceration of the capsule. About five or six weeks afterwards he makes a superficial crucial incision in the capsule with a fine needle (the pupil having been previously widely dilated by atropine). The vertical incision should extend to within about half a line of the edge of the dilated pupil, whereas the horizontal one is to be shorter, corresponding only to the transverse diameter of the normal pupil. The needle must not penetrate deeply into the lens substance, otherwise the lens may be displaced. The pupil is to be kept widely dilated by atropine, in order to afford plenty of room for the swelling of the lens, and prevent its pressing upon the iris and ciliary body. Generally, but very slight irritation follows the laceration of the capsule, and flap extraction may be performed from about six to twelve days afterwards, when the cataract will readily escape. For reasons already stated, I prefer making the iridectomy upwards.

I have before stated that the chief dangers to be feared after flap extraction are suppuration of the cornea, prolapse of the iris, and iritis.

* "Archiv. f. Ophthalmologie," x, 2, 202; vide also a paper upon this subject by Dr. Mannhardt in the "Sitzungsbericht der Ophthalmologischen Gesellschaft," 1864.

The principal causes which may produce the latter are—1. Bruising of the iris by the instruments and by the passage of the cataract through the pupil, more especially if the latter is small and somewhat rigid, so that it dilates with difficulty. 2. The contusion and irritation which the iris may suffer in the attempts to replace a prolapse. 3. The irritation set up by portions of lens matter remaining behind the iris or adhering to the pupil, which is especially apt to occur if the pupil is small and rigid, and the cataract immature, or if it possesses a small nucleus, with a considerable portion of softish cortical substance. Now, in accordance with the fact that the segment of the iris corresponding to the corneal section is the portion most exposed to these different influences, we find that it almost always forms the starting-point of the inflammation (iritis). In order to diminish these dangers it has been proposed to remove this portion of the iris prior to the extraction of the cataract—to perform, in fact, a preliminary iridectomy. Von Graefe originally pointed out that such a proceeding might be advantageous in some cases, and Dr. Mooren has more lately submitted this plan to an extensive trial, with marked success. There can be no doubt that it renders flap extraction a much more safe operation; for as a segment of the iris corresponding to the apex of the flap is removed, there is far less danger of wounding the iris with the instruments or of its being contused by the passage of the lens, for the wide artificial pupil permits the ready exit of the cataract, so that there is also much less fear of portions of cortical substance remaining behind. Even if the latter should occur, there is more room for these fragments to swell up, and they will therefore exert a far less deleterious influence upon the iris and ciliary body. The danger of prolapse of the iris is also diminished, and it can only occur at the angles of the incision. According to Von Graefe, a preliminary iridectomy does not, however, guard against either diffuse or partial suppuration of the cornea, but he thinks that it certainly exerts a favourable influence upon the course of the latter, and on the secondary iritis, as it diminishes their intensity. The iridectomy should be made upwards, as it will then be covered by the upper lid; the subsequent flap operation is of course to be made in the same direction. Mooren makes it about a fortnight before the extraction, but it is better to permit a longer period (from four to six weeks) to elapse between the performance of the two operations, so that all irritation may have subsided, and the edges of the artificial pupil have become cicatrised.

Let us now consider in what cases it may be advisable to perform this modified flap extraction. Mooren recommends it in all cases where the patient is very old and decrepid, where the pupil does not dilate quickly and fully under atropine, where the nucleus of the cataract is small and surrounded by hardish, coherent cortical substance, portions

of which may easily be rubbed off during the exit of the lens, remain behind, and give rise to severe iritis, or even irido-choroiditis. Again, in diabetic cataract there is not only the fear of suppuration of the cornea if the patient is very feeble, but there is, moreover, a special tendency to iritis, as the iris is extremely impatient of contusion and irritation. But then we must also remember the danger of submitting such a patient, who is perhaps already in a very weak state of health, to the anxiety and shock of two different operations. In fact, we find that even persons in good health are frequently most unwilling to undergo two operations. To avoid this inconvenience, the iridectomy may be combined with the operation of extraction, as has been advised by Professor Jacobson, who has introduced the following modification of the ordinary flap extraction. The patient having been placed fully under the influence of chloroform, the downward section is made, the puncture and counter-puncture lying half a line below the horizontal meridian of the cornea, and not in the substance of the latter, but in the sclero-corneal junction, as he thinks that union is more readily effected here than in the cornea itself. After the lens has been removed in the usual manner, the corresponding segment of the iris is to be excised, for by this proceeding the risk of iritis, prolapse of the iris, and suppuration of the cornea is diminished. Professor Jacobson states, in his treatise upon this operation, published in 1863, that he had up to that time operated upon 100 cases by this method, and had only lost two eyes. It is to be regretted, however, that he has not furnished more ample details of the 100 cases, more especially as to their progress and the amount of vision restored, etc., so that a more accurate opinion could have been formed of the real success of his operations. My chief objections to this modification are, the direction of the iridectomy, and that the iris is to be excised after the removal of the lens. The downward iridectomy is not only unsightly, but it causes considerable dazzling and confusion of vision on account of the circles of diffusion on the retina, more especially when cataract glasses are used, and this proves of great inconvenience to the patient, particularly in walking, crossing a street, etc. The excision of the iris after the removal of the lens is not only difficult, but even attended by some risk of losing vitreous humour in attempting to seize and draw out the iris, more especially if the eye has to be fixed with a pair of forceps. Moreover, there is no reason why, if the iridectomy is to be made at all, it should not be done before the extraction of the lens, which is much easier and attended by far less risk.

I have mentioned that Professor Jacobson places the patient thoroughly under the influence of chloroform. Most operators (amongst whom I must include myself) have hitherto been afraid of giving chloroform in flap extraction, on account of the danger of vomiting or

retching during or after the operation. The wound is so large (embracing nearly half the cornea) that a fit of vomiting or severe retching may cause a great loss of vitreous humour, and may even force out the retina and choroid. Professor Jacobson states, however, that there is no danger of vomiting if the patient be thoroughly narcotised, and Mr. Windsor, of Manchester, has lately published* a series of twenty cases of flap extraction successfully performed under chloroform. He says:—"The result has been, I think, sufficiently satisfactory; in no case did the chloroform appear to have any injurious influence. Seventeen operations were unattended by any accident; in three a little vitreous was lost. Vomiting occurred within a few hours in four cases, but appeared to have no pernicious effect." If choroform is given in eye operations, the patient should be placed thoroughly under its influence; otherwise it is better to abstain altogether from its use. These operations, more especially those upon the iris and for cataract, are of so delicate a nature, that a sudden start of the patient's head, or a fit of vomiting or retching, may not only endanger the result of the operation, but even the safety of the eye. When the patient is so deeply narcotized, the sudden inhalation of a strong dose of chloroform may prove very dangerous; and it is therefore of great importance to know exactly what percentage of chloroform the patient is breathing. For this reason I greatly prefer Clover's apparatus for administering chloroform. It is not only the safest method, but by no other have I uniformly seen such perfect tranquillity and unconsciousness produced, without there being any cause for fear. There is little or no struggling or straining; the patient breathes calmly and quietly; and when he is thoroughly under its influence the most difficult and delicate ophthalmic operations may be performed without fear or risk. In order that there may be no vomiting or retching, strict orders should be given that the patient does not take any food or drink for three or four hours prior to the operation.

5.—REMOVAL OF THE LENS IN ITS CAPSULE.

This operation has been especially recommended for the following cases:—1. Capsular cataract. 2. Cataract complicated with choroiditis, or irido-choroiditis; for in such cases the eye is extremely irritable, and if portions of lens matter are left behind they are apt to set up very destructive inflammation; moreover, the connexion between the posterior capsule and the hyaloid is apt to be loosened. 3. Retrogressive cataract, in which the lens is somewhat shrivelled. If some of its constituents have undergone fatty or chalky degeneration, considerable portions of lens matter are liable to adhere to the capsule and

* "Ophthalmic Review," vol. ii, 365.

remain behind when the cataract is removed, setting up more or less severe inflammation and giving rise to dense secondary cataract. 4. Immature cataract, in which there is also danger of lens substance remaining behind.

This operation was originally practised by Richter and Beer, but fell into disuse until it was lately re-introduced by Sperino, Pagenstecher, and Wecker. Pagenstecher performs it in the following manner:—The patient having been placed thoroughly under chloroform, he makes a flap incision (generally downwards) lying throughout its whole extent in the sclerotic, and not in the cornea; at the apex of the flap he leaves a small bridge of conjunctiva standing. He next makes a large iridectomy downwards and outwards, and then divides the conjunctival bridge with a pair of blunt-pointed scissors. If any posterior synechiæ exist, he divides them with a fine silver hook passed between the edge of the pupil and anterior capsule; then, by slight pressure upon the eye, he endeavours to remove the lens in its capsule; but if the hyaloid membrane should be ruptured, and vitreous escape, he passes in a small scoop behind the lower edge of the lens and to its posterior surface, and thus removes it with the capsule. Up to the year 1864 he had operated in this way upon fifty-four cases of cataract of various kinds with marked success. Only two eyes were lost through suppuration, and in a third case there was some iritis dependent upon previous opacity of the vitreous, but the result of this operation was fairly good, the patient being able to read No. 16 with convex 3. In not one of the remaining fifty-one cases was there the slightest iritis. In some of these cases the lens was extracted without the aid of the scoop, and without loss of vitreous, the same occurring sometimes even when the scoop was employed; in others more or less vitreous was lost.

Wecker operates in a very similar manner, except that he does not make his incision so much in the sclerotic as Pagenstecher, and does not leave a conjunctival bridge. A portion of iris having been excised, he passes a curette behind the lens and draws it out in its capsule. When the lens has reached the incision, an assistant, grasping its edge with a Daviel's curette, extracts it. His results have also been very favourable, and he has often succeeded in extracting the lens without any loss of vitreous. The latter accident is almost sure to occur if chloroform is not given, or if the patient is not thoroughly under its influence. When a mature senile cataract has existed for many years, it often adheres somewhat closely to the capsule, and the relations of the latter with the suspensory ligament are, moreover, generally somewhat relaxed, so that the lens can be unusually easily removed in its capsule. This fact has been especially pointed out by Mr. Bowman, who has succeeded in several cases in extracting the lens in its capsule

by Graefe's operation. If, on attempting this, it is, however, found that the lens does not come readily, it is much better to divide the capsule freely, than to force the exit of the lens in the capsule at the expense of a great loss of vitreous, and perhaps the dislocation of the lens into the vitreous humour.

6.—LINEAR EXTRACTION.

Before I describe this mode of operating, let us glance for a moment at its history.* In 1811, Gibson introduced it as supplementary to the needle operation, in those cases of soft cataract in which the lens (after having been divided) was not absorbed with the desired rapidity or success. He also employed it in capsular and membranaceous cataract. His mode of operating consisted in removing the lens through a small corneal section, which was about three lines in extent, and was situated about one line from the sclerotic. In 1814, Travers, after dividing the capsule, displaced the lens into the anterior chamber, and then removed it through a small corneal section. He, however, subsequently gave up this method, and, making a quarter section of the cornea, divided the capsule with the point of the knife, and, if the lens was sufficiently soft, he let it escape through the section, but if it was too firm for this, he introduced a curette into the anterior chamber, and by its aid removed the lens piecemeal. Both the operations of Gibson and Travers fell into disuse, until about 1851, when Bowman and Graefe, quite independently of each other, re-introduced linear extraction. Von Graefe, having worked out the subject extensively and with great care, states in his first essay upon it† that the linear extraction is especially indicated in the cortical cataract of youthful individuals, and also in those cases in which there is so much swelling up of the lens substance (either in consequence of a needle operation, or of some injury to the lens) as to threaten the safety of the eye. But he thinks it unsuitable if the lens retains its normal consistence, and still more so, if there is a hardish nucleus. As a general rule, linear extraction is, therefore, indicated in cases of cortical cataract, occurring between the age of ten and thirty, or even thirty-five. It is also often employed with advantage as supplementary to the needle operation. Linear extraction is to be performed in the following manner. The pupil having been previously well dilated with atropine, and the patient placed under the influence of chloroform, the eyelids are to be kept apart by Weiss's spring speculum, and the eye steadied with a pair of

* For an interesting historical sketch of this operation, I must refer the reader to Von Graefe's paper on "Modified Linear Extraction," "Arch. f. Ophthalm.," xi, 3.

† "Arch. f. Ophthalm.," i, 2.

forceps. An incision is then to be made in the cornea, at its temporal side, and about one line from the sclerotic, with a broad straight iridectomy knife. The incision should be about from two to two and a half lines in extent. The capsule is then to be divided with the cystotome, and the lens removed. In order to facilitate the exit of the cataract, the convexity of the curette is to be placed against the edge of the cornea, which causes the section to gape; a slight counter-pressure, being at the same time exerted by the forefinger of the left hand, which is to be lightly placed against the inner side of the eyeball. By alternately pressing with the curette and the finger, the soft lens substance will readily exude through the incision. If portions of cortical substance remain behind the iris, the lids are to be closed, and the globe lightly rubbed in a circular direction to bring these flakes into the pupil or anterior chamber, whence they may be readily removed. Or Mr. Bowman's suction-syringe may be employed for this purpose. Should the iris protrude through the incision, it must be gently replaced, but if it has been much bruised by the exit of the lens or the movements of the curette, it will be wiser to excise a portion of it. A light compress bandage is to be applied after the operation, and the pupil should be kept well dilated with atropine.

Von Graefe found that, although occasionally a cataract possessing a firm nucleus may be removed through a linear incision without danger, yet that, as a rule, this operation is inapplicable when the nucleus is hard, for the iris must then be more or less bruised by the passage of the lens through the narrow section. The scoop may also have to be introduced into the anterior chamber behind the lens, so as to facilitate its removal, and this, of course, adds to the contusion of the iris. Great irritation of the latter is likewise often produced by portions of hardish lens substance remaining behind the iris or in the pupil. Now, as the segment of the iris which corresponds to the incision is the most exposed to bruising, and interferes the most with the ready use of the scoop, we find that this is almost always the starting point of any subsequent iritis. In those cases in which there was a somewhat firm nucleus, Von Graefe was therefore led to modify the linear extraction, and to excise a portion of iris prior to the laceration of the capsule, and then to remove the lens with a broad flat scoop.* The stages of this operation were as follows:—1. The incision was made at the edge of the cornea (temporal side), and embraced about a quarter of its circumference. 2. A portion of iris was removed, the size of which did not, however, quite equal the extent of the incision. 3. The capsule was freely divided quite up to the margin of the lens. 4. A scoop was then introduced at the free edge of the lens and gently inserted between the posterior cortical substance and the nucleus, and the cataract

* "Archiv. f. Ophthalm.," v, 1.

lifted into the anterior chamber and extracted. The scoop which he employed for this purpose was shallower, broader, and sharper at the extremity than Daviel's curette. Thus originated the modified linear or scoop extraction—an operation which afterwards assumed so important a position in ophthalmic surgery. By this modification, Von Graefe greatly extended the applicability of the linear extraction, for he was now able to remove through a linear incision cataracts whose cortex was of a pulpy consistence, and the nucleus moderately large and hard, a form of cataract which would otherwise have necessitated the flap extraction. I would here remark that to Von Graefe belongs the credit of having first suggested, in some cases, the combination of an iridectomy with flap extraction, and also of having introduced the modified linear or scoop extraction. The principle of the latter operation is essentially his, whatever changes may be made in the shape of the scoop, and it is worthy of remark that the latest operations assimilate it more to that originally used by him. Mr. Critchett has already pointed out these facts in his admirable paper upon scoop extraction,* in which he says :—"Thus there suddenly appeared three new methods of operating for cataract, bearing the name of their several champions—the method of Mooren, Jacobson, and that of Schuft (Waldau) ; but justice compels me to state that these gentlemen lighted their tapers at the torch of their great master Professor Von Graefe. Each of these methods had been previously suggested and practised by him, but only in exceptional cases, instead of as a general rule."

Waldau shortly afterwards contrived a different form of scoop, of varying size, which was deeper, broader, and flatter at the bottom than Von Graefe's. Its edges were, moreover, high and thin, so as to bite into the lens, the anterior lip being the highest, and thus facilitating the removal of the cataract by pressing after it. By its aid he proposed to remove even the hard senile cataract. It was soon found, however, that this form of scoop was too large and cumbersome, and its edges too high and sharp, and that it was therefore difficult to introduce it readily behind the lens, more especially in hard senile cataract, in which it may very easily cause displacement of the lens or rupture of the hyaloid membrane. Mr. Bowman and Mr. Critchett have since devised some forms of scoop which are far better and in all cases preferable to Waldau's. The scoop operation, as performed at Moorfields, has proved remarkably successful in the hands of some of our English ophthalmic surgeons, more especially in those of Messrs. Bowman and Critchett, who have worked out the subject most thoroughly, and have done the most to bring this operation to perfection. As my description of it must be necessarily brief, I would refer the reader to their admirable

* "Royal London Ophthalmic Hospital Reports," iv, 4, 319.

articles upon this subject in the "Royal London Ophthalmic Hospital Reports," vol. iv., p. 4.

7.—SCOOP EXTRACTION.

Prior to the operation, the pupil should be widely dilated with atropine, and the cataract examined by the oblique illumination, so that the size and hardness of the nucleus and the consistence of the cortical substance may be ascertained. For the size of the incision should be apportioned to that of the nucleus, and to the extent and consistence of the cortical substance. Nothing is more likely to mar the success of the operation than if the incision is too small, for then the iris and the lips of the section must be more or less bruised during the exit of the lens, considerable portions of the latter are sure to be stripped off, and, if they cannot be entirely removed, may set up subsequent inflammation. If the nucleus is small and the cortex softish, the incision should embrace about a quarter of the circumference of the cornea; but if the nucleus is large and hard—as, for instance, in the senile amber cataract —and the cortex firm, the size of the incision must be increased, and should extend to about one-third of the cornea. The section must also be large, if the cataract is over-ripe, and if little fatty or chippy fragments have collected on the surface or at the margin of the lens; for these are very apt to be stripped off and left behind if the exit of the lens is rendered difficult and forced from the section being too small.

The patient should be placed thoroughly under the influence of chloroform, so that he may be quite tranquil and passive, for any sudden start may endanger the safety of the eye, more especially during the period of the introduction of the scoop. It is, moreover, important that the different steps of the operation should be performed, if possible, without any interruption by the recovery of the patient from the effects of the chloroform; for if this happens after the excision of the iris, and there is any considerable bleeding into the anterior chamber, it may be impossible to remove the blood before it has become coagulated, owing to the time lost in again getting the patient thoroughly narcotised, and this will considerably enhance the difficulties of the other steps of the operation. The operation of scoop extraction is divided into four periods. 1. *The incision.* 2. *The iridectomy.* 3. *The laceration of the capsule.* 4. *The removal of the cataract by the scoop.*

The incision is to be made in the upward direction with a broad, lance-shaped knife in the sclero-corneal junction, and should be about from four to four and a half lines in extent. A corresponding portion of the iris is to be removed. The capsule is then to be freely lacerated with the pricker. The latter is to be passed into the anterior chamber as far as the opposite edge of the pupil, and even a little beneath the

margin of the latter, especially if there be slight adhesions of the edge of the pupil to the capsule, which will thus be torn through. The point being then turned towards the lens, the pricker is to be drawn gently along on each side and in the centre, so that the capsule may be freely lacerated quite up to the margin of the lens corresponding to the incision. But the instrument must be used very lightly and delicately, otherwise the lens may be dislocated, especially if the cataract is hard. The next and most difficult step of the operation is the removal of the lens by the scoop. Waldau's is too large and cumbersome, and either Mr. Critchett's or Mr. Bowman's form of scoop should be used. The former, Fig. 34, is so constructed as to glide readily behind the posterior surface of the cataract. It is thin, flat, and concave, so as to adapt itself accurately to the posterior convex surface of the lens. At the end there is a small receding edge, which assists in fixing and holding the cataract, and thus facilitates its removal. Mr. Bowman thinks, however, that this wedge-like end occupies too much space behind the nucleus. He, therefore, prefers another form (Fig. 35), the end of which is not recurved, but looks from it at a very obtuse angle, and the extreme edge is very thin. The sides, except towards the end, have no edge above the general level. In those cases in which there is no soft matter to permit room for the insertion of the scoop between the lens and capsule, he uses a different shape (Fig. 36). This instrument is

Fig. 34. Fig. 35. Fig. 36.

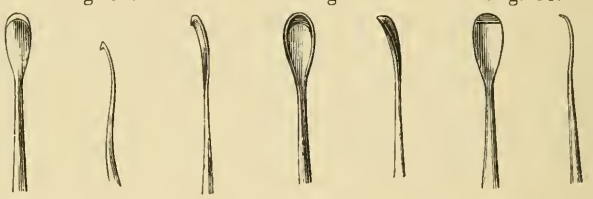

nearly flat from side to side, and but slightly concave from end to end. The end has a very thin, though not sharp, edge only slightly incurved, and the concave surface at the end is roughened by transverse lines. For those forms of cataract in which, together with a large firm nucleus, there is a sufficient layer of soft cortical substance to permit the easy passage of the scoop, I generally use Mr. Critchett's instrument. When this is not the case, I prefer Mr. Bowman's second form (Fig. 36).

Great dexterity, delicacy, and care are required in the use of the scoop, which is to be lightly held between the forefinger and thumb. The eye having been fixed with the forceps, the scoop is to be introduced into the section, being turned directly towards the back of the eye, so that its anterior lip may glide past the free margin of the lens

exposed by the iridectomy. It is of great consequence to remember that the scoop is to be at first directed backwards, for if it be passed forwards and downwards before its anterior lip has skirted the edge of the lens, the nucleus will be pushed before it, and even perhaps displaced behind the lower portion of the iris, the hyaloid membrane will in all probability be ruptured, and a considerable portion of the vitreous humour escape even before the body of the lens has been extracted. When the edge of the scoop has passed the margin of the lens, it is to be turned quite flat, and slowly and gently insinuated into the posterior cortical substance between the capsule and the nucleus until its further end has passed the margin of the latter. This forward movement must be very delicately performed by a slightly undulating or "wriggling" motion; for if the scoop is roughly pushed on it may carry the lens before it, and thus displace it, or the hyaloid membrane may be ruptured and the vitreous humour escape. When the lens is well grasped by the scoop, it should be slowly removed, care being taken that its anterior surface is not pressed too much forward; otherwise it will bruise the iris and cornea, a not unfrequent cause of subsequent iritis and circumscribed corneitis. If small portions of cortex have been stripped off during the passage of the lens into the anterior chamber, and lie in the latter, a slight backward movement of the scoop may be made before the cataract is removed through the incision, as this will gather up such fragments and draw them readily after the main portion; or they may be afterwards removed with a smaller scoop, slight pressure being at the same time made upon the globe opposite the incision. If the detached fragments are considerable, and cling to the edge of the pupil, or remain behind the iris, the speculum should be removed and the eyelids rubbed in a circular direction, so as to bring them into the anterior chamber, whence they may be readily extracted by the curette. This is much to be preferred to the frequent introduction of the scoop. The suction syringe may also be employed for the removal of small soft fragments. Any little portions of lens matter that may cling to the lips of the incision are to be removed with the curette, as they interfere with the union of the section, and are apt to give rise to suppurative infiltration of the edge of the incision. Should a little of the vitreous humour exude through the section with the last portion of lens, it must be snipped off and a compress applied. If the vitreous escapes directly after the division of the capsule, the scoop must be passed well behind the cataract so as to extract it, if possible, *en masse*. If the loss of vitreous does not occur until the body of the lens has been extracted, any fragments of lens that remain behind should be removed. If they can be easily reached, the curette should be employed; otherwise it is better gently to rub the lids and bring them into the anterior chamber, whence they may be

readily extracted. More or less vitreous will, of course, be lost, but this is better than leaving considerable fragments behind, as they swell up and give rise to great irritation and inflammation of the iris or ciliary body.

The after treatment is far more simple than that of flap extraction, and it is very similar to that which I shall describe in Von Graefe's operation.

8.—VON GRAEFE'S MODIFIED LINEAR EXTRACTION.

Von Graefe* has lately devised an important modification of the linear extraction, which combines the advantages of the flap and scoop extraction. For whilst the section involves but a small portion of the cornea, it yet, on account of its shape and mode of formation, gapes sufficiently to permit the ready exit of even a hard senile cataract without the aid of a traction instrument. The operation is divided into four periods :—1. *The incision;* 2. *The iridectomy;* 3. *The laceration of the capsule;* 4. *The removal of the lens.* The operation is to be performed in the following manner :—

1. *The Incision.*—The patient having been placed under the influence of chloroform, the eyelids are to be kept apart with the stop speculum, and the eye fixed with a pair of forceps. For this operation I greatly prefer Mr. Noyes's (New York) speculum, the rack and screw of which are on the nasal side, so that the temporal portion of the eye is left quite free for the manipulation of the knife in forming the section. Another great advantage is that it does not press upon the eyeball, but lifts the lids away from it. The speculum may be obtained of Messrs. Krohne and Co., Whitechapel. The point of a long narrow knife (Fig. 37), with its cutting edge turned upwards, is to be entered

Fig. 37.

Fig. 38.

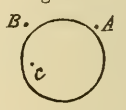

in the sclerotic (at the point *A*, Fig. 38) near the upper and outer portion of the cornea, about one-third of a line from its edge, so that it may enter quite at the periphery of the anterior chamber. The point of the knife should be at first directed downwards and inwards towards *c*, so as to enlarge the inner incision, and then, when the blade has advanced about three and a half lines into the anterior chamber, the handle is to be depressed and the point carried along to *B*, where the

* Vide A. f. O., xi, 3, xii, 1, xiii, 1 and 2, xiv, 1.

counter-puncture is to be made. Great care must be taken that the counter-puncture does not fall too far in the sclerotic, which might easily occur if the presentation of the point of the knife is not carefully watched, or the blade is passed too far downwards and inwards, before it is turned upwards to make the counter-puncture. Such an accident will give rise to a wide gaping wound, and, in all probability, to great loss of vitreous, even perhaps before the iris has been excised, and certainly during the pressure which has to be made upon the globe to facilitate the exit of the lens.

As soon as the counter-puncture has been made, the edge of the blade is to be turned steeply forwards, and the knife pushed straight on until its length is nearly exhausted, when the section is to be finished by drawing it backwards from heel to point. If a little bridge should remain, it is to be divided by a slight sawing movement of the knife, which will then lie under the conjunctiva, which is next to be divided in such a manner as to leave a conjunctival flap of about one line to a line and a half in height. In order that it may not exceed this extent, the edge of the blade must be turned horizontally forwards, or even downwards. If the cataract is hard and firm, it may be advisable to use a somewhat broader knife, and to make the points of puncture and counter-puncture one-third of a line lower.

By this incision the track of the wound lies almost perpendicular to the surface of the cornea, and is steeper (less sloping) than that made by the lance-shaped knife. Thus the exit of the lens is greatly facilitated, for its equator passes far more readily into the track of the wound, and the cortical substance exudes also more easily. There is, however, the disadvantage that on account of the steepness of the section the suspensory ligament loses its support, and hence there is a greater tendency to loss of vitreous than if the incision is made with the lance-shaped knife.

In senile cataract with a large, firm nucleus, care must always be taken that the incision is sufficiently large to permit of the ready exit of the lens without there being the necessity to use much pressure upon the eye, or to pass in a scoop to remove it. In such cases I always make the puncture and counter-puncture somewhat lower down and nearer the horizontal diameter of the cornea, which is, I think, to be preferred to a more peripheral position of the section. The incision lies throughout slightly in the sclerotic (just at the sclero-corneal junction), for I believe that union takes place much more rapidly here than when the section lies in the cornea. Moreover, the section is sufficiently large to admit of the easy exit of the cataract, a very gentle pressure with a curette upon the lower portion of the cornea sufficing to "coax" it out. Mr. Critchett, on the other hand, prefers to make the section throughout in the cornea quite close to its edge, as he thinks that there

is thus less chance of loss of vitreous and of prolapse of the iris. He also only removes a very small portion of the iris.

2. *The Iridectomy.*—If the section does not come well into view, an assistant is to draw the eye down with a pair of forceps, and the little conjunctival flap is to be turned back over the cornea with a pair of very small iris forceps. The prolapsed portion of the iris will thus be laid bare, and the iris should be drawn forth a little more and be excised to the required extent quite up to its ciliary insertion. The size of the iridectomy must vary according to the size and hardness of the nucleus, and also according to the position of the upper lid. If the nucleus is large and hard I think it wiser to remove a considerable portion of the iris, even perhaps nearly corresponding to the whole length of the incision. This will permit of the ready exit of the large, hard cataract, without much, or any, bruising of the iris. Moreover, if the upper eyelid hangs down sufficiently to cover the upper third of the cornea no unsightliness or inconvenience will be produced by so large an iridectomy. It will be different, if the aperture between the eyelids is wide, so that the whole of the cornea is exposed, for then the very extensive artificial pupil may give rise to a considerable feeling of glare, and also diminish the acuity of the vision by irregular refraction at its periphery, which gives rise to considerable circles of diffusion. But whatever the extent of the iridectomy, we should always be very careful to remove the iris quite close to its insertion, so that no little portions remain behind in the section, for these may retard the union of the wound, be productive of much irritation, and give rise to prolapse, which may subsequently prove very troublesome, or even dangerous to the eye.

3. *Laceration of the Capsule.*—The capsule is to be freely divided with the pricker by two successive lacerations. The one is to commence at the lower edge of the pupil, or even a little beneath it, and extend upwards along its inner side, the other along its outer side. Both incisions should reach quite up to the periphery of the lens exposed by the iridectomy. If there are slight adhesions between the iris and the pupil, these may be readily divided by passing the instrument slightly beneath the edge of the pupil. The capsule should also be gently lacerated at its periphery, corresponding to the line of incision. Throughout, the edge of the instrument should be turned in a somewhat slanting direction, and not be pressed firmly backwards, indeed it should be used with great delicacy and lightness, otherwise displacement of the lens into the vitreous humour may easily occur.

4. *Removal of the Lens.*—During the earlier period of performing his new operation, Von Graefe was in the habit of assisting the progress of the lens by pressing upon the upper portion of the sclerotic with a broad curette, and aiding this by a counter-pressure with the forceps

below the cornea. When the edge of the lens had once presented itself in the section, its delivery was still more assisted by gliding the curette in a lateral direction along the sclerotic to the angles of the incision ("Schlitten-manœuvre" of Von Graefe). It was found, however, that the removal of the lens was often difficult without exerting a dangerous degree of pressure and that occasionally it was necessary, in order to extract the lens, to pass in a scoop, or a peculiarly shaped hook, devised by Von Graefe.

Lately he has substituted for this manœuvre the use of a vulcanite curette, which aids the removal of the lens by being pressed against the lower portion of the cornea. It is to be used in the following manner: —The eye is to be fixed with the forceps, which are to be placed not directly below the cornea, as they would then interfere somewhat with the manipulation of the curette, but slightly to the inner or outer side. The curette is then to be placed upon the lower edge of the cornea, and pressed slightly backwards and upwards, so as to cause the upper edge of the lens to present itself in the section; the pressure is then to be made directly backwards, in order that the lens may be rotated round its transverse axis, and tilted well forward into the incision. When this has occurred, its exit is gently aided by pushing the curette slowly upwards over the surface of the cornea, so that it follows step by step the delivery of the lens. If it is found that portions of the lower cortical substance are stripped off, and are inclined to lag behind, the curette should be drawn a little back again, and the fragments of cortex pushed along after the body of the lens, and in this way the whole cataract may generally be removed. If small portions of lens matter remain behind, they should be coaxed out by again passing the curette over the cornea, and pushing on the fragments in front of the instrument. The object of making the curette of vulcanite instead of silver is that it is more resilient, and the degree of pressure can therefore be regulated with the greatest nicety, and its touch is moreover more agreeable to the cornea. The vulcanite, has, however, the disadvantage of being very brittle, so that it breaks very readily. For this reason I have lately preferred Weiss's tortoise-shell curette, which offers all the advantages of the vulcanite, without its brittleness.

The loss of vitreous humour has diminished very considerably since Von Graefe substituted the latter mode of removing the lens (by pressing from below) for the "Schlitten-manœuvre," indeed in the last 230 operations he has only lost vitreous humour in nine cases, which gives less than 4 per cent. In three of these the vitreous humour was, moreover, fluid. If this occurs, the vitreous may escape directly the section is finished, and even before it is attempted to excise a portion of iris. In such a case it is best to excise a portion of iris, if this can be done without a very great loss of vitreous, and then to remove the lens in

its capsule by passing Critchett's scoop behind it into the vitreous humour, and lifting it out. A considerable quantity of vitreous will of course escape, but subsequent inflammation is likely to be far less severe if the entire lens is removed in its capsule, than if more or less considerable fragments of lens substance and capsule remain behind.

Several of the best operators still differ in opinion as to the advantage of making the section in the sclerotic or in the cornea, whilst Graefe prefers the former, Critchett and Arlt are in favour of the latter proceeding. I think that the exact line and size of the incision should vary with the size and hardness of the nucleus and with the size of the cornea. If the nucleus is large and firm, and the diameter of the cornea small, the section should be made slightly more in the sclerotic, the puncture and counter-puncture being also somewhat lower, for thus we shall gain a larger section, and the delivery of the lens will be easy and free from all squeezing and bruising of the parts. If the section is made in the cornea, and more especially if a portion of cornea is left standing at the top, the exit of the lens is often difficult and laboured, and accompanied by a good deal of bruising of the parts and stripping off of the surface matter of the lens, which, if it remains behind, may set up very considerable irritation. Moreover, the upper edge of the lens may be caught behind the portion of the cornea which has been left standing, and be firmly wedged in between it, or the lens may even be displaced upwards behind the sclerotic. This is the more apt to occur if the first pressure which is made with the curette upon the lower portion of the cornea is not made backwards and upwards, but only upwards, for then the lens will be pushed directly upwards, and may become lodged behind the upper portion of the cornea. The object of the backward pressure upon the lower portion of the lens is to tilt its upper edge into the section, for when it has once gained this position the escape of the lens is easy enough, providing the section be of a sufficient size. My own experience, I must admit, is greatly in favour of the sclerotic section lying in the sclero-corneal junction or very slightly beyond it. Where a considerable section is required, I prefer to obtain this rather by making the puncture and counter-puncture lower, than by making the section more in the sclerotic, for in the latter case there is always a greater risk of loss of vitreous.

The after treatment of this operation is generally extremely simple. Liebreich's bandage should be applied directly after the operation, and if any severe pain should arise in the course of the day, cold water dressing (frequently changed) should be applied, care being taken that it is not persisted in too long. If the pain does not yield to this treatment, a leech or two should be applied to the temple. On the second day atropine drops should be prescribed. The patient may generally leave his bed on the second or third day, but this will depend upon individual

circumstances, and upon the fact as to whether he can have proper supervision. With some patients it is advisable to permit their leaving the bed even the day after the operation, but it is always wiser to err on the side of safety. The general rules laid down for the after treatment of flap-extraction also apply to Von Graefe's operation.

The success of this operation has been so great, that most ophthalmologists, amongst whom I may mention Mr. Bowman, have entirely abandoned the scoop extraction, and even to a great extent the flap operation. My own experience of it is also extremely favourable, and I prefer it greatly to every other mode of extraction.

Dr. Taylor, of Nottingham, has operated by a method somewhat similar to that of Von Graefe (but quite independently of him) since the summer of 1865, indeed both appear to have begun about the same time. In No. 9 of the *Ophthalmic Review* (April, 1866), Dr. Taylor says:—"I have also, in certain cases where the results of sclero-choroiditis posterior, extensive atheroma of the vessels, staphyloma, or other disease of the eyeball, render it unsafe to reduce tension so suddenly or completely as is done by the ordinary flap operation, endeavoured to obviate the dangers of escape of vitreous, hæmorrhage, and subsequent suppuration of the eyeball by a modification of Schuft's operation—premising an iridectomy as above, and making the incision with a small ground down cataract-knife, entered in the cornea and sclerotic junction, and emerging at a counter-puncture, so as to incise a little more than the upper third of the cornea, the opening being well back, and larger than the large one sometimes required in Schuft's operation. The eye may be safely fixed throughout the operation. The flap cannot be turned down; and yet, if the posterior lip of the wound be gently pressed back, the lens may be coaxed out without passing any instrument into the eye."

I will now briefly mention the principal arguments which may be advanced in favour of or against the different operations for senile cataract. In doing this I shall confine myself to the flap extraction, the scoop operation, and Von Graefe's new modified linear extraction.

There cannot be any doubt that the common flap extraction is the most perfect operation of all, when it turns out perfectly successful. It is nearly free from pain; it does not in the least interfere with the appearance of the eye; the pupil remains central and moveable; the sight is perfect, and is not at all deteriorated and confused by circles of diffusion upon the retina, which are always more or less present when an iridectomy has been performed. It must, however, be confessed that these great advantages are often more than counterbalanced by the considerable dangers which beset the operation. On account of the great size of the flap, there is much risk of the vitality of the cornea becoming impaired, and of its undergoing partial or even diffuse sup-

puration, which may be accompanied by suppurative iritis or irido-choroiditis. Again, prolapse of the iris is a not unfrequent complication, proving a source not only of great annoyance and irritation, but even of danger to the eye. The after-treatment also demands much care and attention—more, indeed, than can generally be bestowed in an Hospital, especially in a General one, with no special nurses or ophthalmic wards. Now, in the scoop extraction, these two principal dangers—suppuration of the cornea and prolapse of the iris—are nearly completely eliminated. On account of the position and shape of the incision, suppuration of the cornea, even of limited extent, is rare, and a prolapse of the iris can only be slight, and is confined to the angles of the section. Moreover, chloroform may be administered without any fear. But it must be admitted that iritis, chronic and insidious irido-choroiditis, inflammation of the intra-capsular cells, and secondary cataract, are more common than in flap extraction. Von Graefe's operation, however, offers all the advantages of the scoop extraction, viz., the administration of chloroform, the linear shape of the incision, involving but a small portion of the cornea and the iridectomy, and yet one more most important one, the power of removing the lens without any traction instrument. It is in my opinion to be preferred, as a rule, to any other mode of extraction, more especially in Hospital practice, as the patient requires far less watching and attendance, and the after treatment is extremely simple. The confinement to the bed and house is also much shorter than in flap extraction. I think it is especially indicated in very feeble, decrepid, nervous, and unmanageable patients, or those suffering from severe cough, or bronchitis; also if the pupil is adherent, or small and rigid, so that it dilates but imperfectly under the influence of atropine, or if the cataract is complicated with some choroidal or retinal lesion. It is also the safest operation for diabetic cataract, for in the flap extraction (even with a preliminary iridectomy), there is always some risk of suppuration of the cornea in these patients, as they are generally in a very feeble state of health. As the iris is exceptionally impatient of irritation and bruising in cases of diabetes, it may be advisable, in order to secure the greatest immunity from this danger, to make a double iridectomy, viz., upwards and downwards, so as to get a broad vertical pupil, the two opposite portions of the iris being thus completely cut off from each other. I am sometimes asked by medical practitioners and students which operation I consider the easiest and safest for an inexperienced operator. I think that, all things considered, the downward flap operation is the easiest, for when the section has been successfully completed, the chief danger and difficulty are past; whereas in the modified linear extraction the iridectomy is superadded. I should, therefore, recommend that when the surgeon has operated several times by the lower flap extrac-

tion, and has acquired some experience and dexterity, he should pass on to the upper flap extraction, and Von Graefe's operation. The only two points in the latter which demand practice, care, and dexterity, are the incision and the removal of the lens. If the section is too small, the delivery of the lens will be difficult and forced, and will necessitate enlargement of the incision, considerable pressure upon the eyeball, or the introduction of some form of traction instrument. If, on the other hand, it is too large and lies too far in the sclerotic, there is imminent risk of losing much vitreous humour, perhaps even before the removal of the lens is attempted. Considerable nicety and care are also required in coaxing out the lens by pressing upon the cornea with the curette, for if this is roughly and clumsily done the hyaloid may be ruptured, the vitreous escape, and the lens will probably be pushed somewhat aside, and a scoop will have to be employed for its removal.

9.—RECLINATION OR COUCHING.

I only mention this operation to state that, in my opinion, it should be completely abandoned. Although it may appear to be temporarily successful, it has been found that ultimately about 50 per cent. of the eyes have been lost from chronic irido-choroiditis, etc. It is performed in the following manner:—The pupil having been widely dilated by atropine, a curved couching needle, with its convex surface turned upwards, is passed through the sclerotic at the temporal side, a little distance from the cornea, and somewhat below its horizontal diameter. When the needle has penetrated the sclerotic, it is to be turned so as to bring its convex surface parallel to the iris, behind which it is to be carried to the edge of the pupil, and then passed diagonally across to the opposite side of the anterior chamber. When its point has arrived near the inner and upper edge of the pupil, the handle of the instrument is to be lightly tilted upwards between the fingers, and the lens slowly depressed by the concave surface of the needle into the lower and outer portion of the vitreous humour. It should be kept by the needle in this position for a few moments, in order to prevent its reascending. The needle is then to be slightly rotated, in order to disentangle its point, and drawn back to the point of entrance. The operator should wait for a few moments to see if the lens rises up again, in which case the depression is to be repeated.

10.—DIVISION OR SOLUTION OF CATARACT.

This operation is more especially indicated in the cortical cataract of children and of young persons up to the age of twenty, or even twenty-five; also in those forms of lamellar cataract in which the

opacity is too extensive to allow of much benefit being derived from an artificial pupil. After the age of thirty-five or forty, the lens is generally too hard to undergo anything but very slow absorption, even after frequent repetitions of the operation; the iris is also more impatient of irritation and pressure, so that the danger of setting up iritis is much increased; and there are other operations which are much to be preferred for cataracts occurring at this time of life. In infants and young children an operation for cataract should not be unnecessarily postponed, as the presence of the cataract is very apt in infancy to give rise to nystagmus, and to that form of amblyopia which is dependent upon non-use of the eyes, and which is similar in character to that so often met with in strabismus.

The object of the operation of division is to lacerate the anterior capsule with a fine needle, so as slightly to break up the surface of the lens and to permit the aqueous humour to come into contact with the lens substance, which, imbibing the fluid, softens, and becomes gradually absorbed. The time required for the absorption varies with the age of the patient and the consistence of the cataract. In infants and young children the lens is often absorbed in from six to ten weeks, and one operation may suffice for this purpose. But in adults it may have to be repeated several times, and in them great care should be taken not to divide the capsule and the lens too freely at one sitting, for this will cause great swelling of the lens substance, or the exit of considerable flakes into the anterior chamber, and either of these causes may set up severe iritis or irido-cyclitis. The same caution is necessary in cases of lamellar cataract, because in these, a large portion of the lens is transparent and of normal consistence, and will therefore imbibe much aqueous humour and swell up very considerably.

Prior to the operation the pupil should be widely dilated with atropine. The patient, more especially if a child, should be placed under the influence of chloroform. Infants should be firmly rolled in a blanket or sheet so that their movements may be controlled. The eyelids are to be kept apart with the spring speculum, and the eye fixed with a pair of forceps. A very fine needle is then to be passed somewhat obliquely through the outer and lower quadrant of the cornea, at a point lying well within the dilated pupil, so that the iris may not be touched by the stem of the needle during the breaking up of the lens. The track of the corneal wound must not be too slanting, otherwise its channel will be too long, and the tissue of the cornea will be stretched and bruised during the working of the needle, and this may produce an opacity of the cornea; nor must it be too straight, otherwise the aqueous humour might easily escape. The size and number of the incisions in the capsule must vary with the amount of effect that we desire. If the latter is to be but very slight, a single

small horizontal or vertical tear may suffice, or a crucial incision of limited extent may be made. But if we desire a more considerable effect, more especially in the cortical cataract of children, the incisions must be more extensive, or the superficial portion of the lens is to be gently broken up or comminuted by a series of short superficial incisions, which converge towards the centre of the cataract. In infants and young children the needle may be far more freely used than in adults, or in cases of lamellar or partial cataract. In such, it is always safer to repeat the operation, even several times, than to do too much at one sitting. It may be repeated at intervals of three or four weeks, if it is found that the absorption has become arrested or progresses but very slowly; but all irritability and redness of the eye should have disappeared before the needle is again introduced. If the opening in the capsule is too large, or the cataract broken up too freely, the lens will imbibe much aqueous humour, and, swelling up very considerably, will press upon the iris and ciliary body, and may thus set up severe iritis or irido-cyclitis; or if the incisions in the capsule are too extensive, fragments of lens substance may fall into the anterior chamber, and there set up great irritation.

The needle used for this operation should be very small; its cutting, spear-shaped point should only extend to about $\frac{1}{15}$th or $\frac{1}{20}$th of an inch from the end, and the stem should be cylindrical, so that the aqueous humour may be retained throughout the operation. I always use Bowman's fine stop needle (Fig. 39), which fulfils all these indications.

Fig. 39.

The after-treatment is generally very simple. The pupil should be kept widely dilated with atropine, so that the iris cannot be pressed upon by the swollen lens or any flakes that may have fallen into the anterior chamber. A bandage should be worn for the first twenty-four hours, and the patient should be kept in a somewhat darkened room for the first day or two, especially if there is much reaction. Generally, however, this is but slight, the eye only looking flushed, and watering somewhat on exposure to bright light. My friend, Mr. Lawson, has even successfully operated by this method upon some cases of monocular cortical cataract in adults (between the ages of twenty and thirty), and treated them throughout as out-patients. These were, however, exceptional cases, in which it was absolutely necessary that the patients should follow their employment. In order to expedite the cure, which is often of consequence in patients from the country, it is a very good plan, after the lens matter has become softened by the admission of the aqueous, to remove the whole cataract by a broad linear incision. In children this may generally be done within a week after the division, and thus the sight may be restored in a few days, whereas,

otherwise, many weeks or even months would have elapsed before the cataract would have been entirely absorbed. The same proceeding may be employed in cases of partial cataract, the transparent portion of the lens being made opaque, and softened by the introduction of the needle. This mode of operation has been very successfully practised and much advocated by Mr. Bowman, who also often advantageously employs the suction syringe for the removal of the softened lens after it has been previously broken up by the needle.

If symptoms of irritation and inflammation should set in after the operation of division, and they do not readily yield to antiphlogistics, but increase in severity, and more especially if the tension of the eyeball is augmented, the cataract should be at once removed through a good-sized linear incision, made near the periphery of the cornea with an iridectomy knife. This is also to be done if the capsule has been too freely divided, and the nucleus or considerable portions of lens substance have fallen into the anterior chamber, and are setting up much irritation. If the lens is so firm that it cannot all be readily removed through the linear section, it will be wiser to combine an iridectomy with it, than to endeavour to remove the portions of lens by repeated introductions of the curette into the anterior chamber. An iridectomy is also indicated if the increase of tension has existed for some little time, and if the perception of light and the extent of the field of vision are markedly deteriorated.

Two special forms of inflammation may follow the operation, and endanger the safety of the eye. In the one, the inflammation is chiefly plastic or purulent in character. The iritis or irido-cyclitis is accompanied by plastic exudations behind the iris, and into the vitreous humour, leading eventually in all probability to chronic irido-choroiditis and atrophy of the globe. In the other form, the inflammation is of a serous nature, giving rise to an increased secretion of the vitreous humour, and an augmentation of the intra-ocular pressure—in a word, to a glaucomatous condition of the eyeball, which may cause irretrievable destruction of the sight if timely relief be not afforded.

As these inflammatory complications are most apt to occur in adults above the age of fifteen or twenty, more especially if the cataract is only partial or of a lamellar nature, Von Graefe advises that in such cases, or if any posterior synechiæ exist, an upward iridectomy should be made a few weeks before the operation of division. By so doing, plenty of room will be afforded for the swelling up of the lens, and if fragments have fallen into the anterior chamber, they will produce far less irritation.

11.—OPERATIONS FOR LAMELLAR OR ZONULAR CATARACT.

When describing the nature of lamellar cataract, I mentioned that in those cases in which a sufficiently broad margin of transparent lens substance exists, great improvement of vision may often be attained by dilating the pupil by atropine. A glance at the accompanying figures will explain this. In Fig. 40, *a* represents the undilated pupil occupied by the opacity *b*, which extends beneath the iris as far as the dotted line *c*, where the transparent margin *d* commences. As the

Fig. 40.

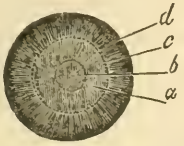

Fig. 41.

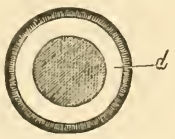

latter is completely covered by the iris, the rays of light can only pass through the central opaque portion; hence the indistinctness of vision. But when the pupil is dilated (Fig. 41) the transparent margin of the lens *d* is uncovered, and the rays can now pass through it to the retina. This fact is of great practical importance, for it furnishes us with a very valuable indication as to the treatment of such cases of lamellar cataract, for we may often succeed in restoring excellent vision by simply making an artificial pupil without operating upon the lens itself. Such a proceeding possesses very marked advantages over any operation for the removal of the lens; for the patient retains the power of accommodation, and is freed from the necessity of wearing cataract glasses, which are not only inconvenient, but also unsightly, more especially in youthful individuals. The artificial pupil may be made either by means of an iridectomy or an iridodesis. The former operation has the disadvantage that the base of the artificial pupil (Fig. 42) is opposite the periphery of the lens *d*, and may therefore give rise to a certain indistinctness of vision, on account of the rays being irregularly refracted by the edge of the cornea and lens, circles of diffusion on the retina being thus produced. In order to diminish this defect, the iridectomy should be but small. In most cases I think Mr. Critchett's operation of iridodesis is to be preferred. A considerable portion of iris should be drawn out, in order that the entire pupil may be drawn near the margin of the cornea, for the iris will thus cover a large extent of the opaque portion of the lens. There will thus result a pupil like that in Fig. 43, having its apex,

Fig. 42.

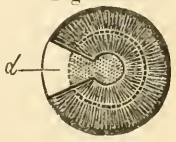

Fig. 43.

and not its base, opposite the clear portion of the lens. Mr. Critchett has also in some cases obtained great improvement of sight by making a second iridodesis close to the other, thus gaining a somewhat broader pupil, and admitting more light.

If the transparent margin in lamellar cataract is not sufficiently broad or clear to admit of much improvement of vision by an artificial pupil, the lens itself must be operated upon either by division with or without iridectomy, or by Von Graefe's operation.

In persons under 25, I think it best slightly to divide the lens with a needle, and to repeat this several times, and then, when the whole lens has become opaque and softened, to remove it through a large linear incision, or with the suction curette. It is never wise to operate upon both eyes at the same time, for in some cases eyes affected with lamellar cataract are extremely irritable, and considerable irido-choroiditis, with or without sloughing of the cornea, may supervene and destroy the eye. If this has occurred in the one eye, we should be greatly upon our guard in operating upon the second at a subsequent period, or devise some other mode of operating. In persons above the age of 25, I have succeeded very well in removing the lens by Von Graefe's operation.

12.—OPERATIONS FOR TRAUMATIC CATARACT.

If the wound in the lens is of but slight extent, and the patient young, the cataract may be left to absorption if no symptoms of inflammation set in. The pupil should be kept widely dilated with atropine, and the condition of the eye carefully watched. If inflammatory symptoms supervene, it may be necessary to remove the lens by linear extraction, more especially if it swells up considerably, or large portions have fallen into the anterior chamber and are setting up irritation. This operation should also be at once performed if the wound in the lens has been considerable, so that the latter, imbibing much aqueous humour, becomes rapidly swollen and presses upon the iris and ciliary body. The simple linear extraction will generally suffice if the lens is so softened that it will readily escape through the incision. But if the nucleus or the greater portion of the lens is still firm, it may be more advisable to make a large iridectomy, in order to afford more room for the swelling of the lens, and then to leave the latter to undergo absorption, which will now be attended by far less risk. In those cases in which great swelling of the lens is accompanied by severe inflammation, it will be best to make a large iridectomy, and remove the cataract either with or without the aid of the scoop. If there is much soft matter, this may be removed with the suction syringe, although I am rather afraid of its use in such cases, especially if there

is any iritis or irido-choroiditis, as it may easily produce hyperæmia *ex vacuo* of the inner tunics of the eyeball. If a foreign body—*e.g.*, a chip of steel, glass, or gun-cap—is lodged in the lens, it is wiser to endeavour to remove it, together with the lens. This should be done by introducing a scoop well behind the foreign body and lifting it out; for if we permit the lens to undergo absorption, the foreign body will at last become disengaged and fall down into the anterior or posterior chamber, and probably set up severe and even perhaps destructive inflammation. The situation of a bit of metal in the lens may often be recognised by the aid of the oblique illumination, when we may observe a little brown spot in the lens, or a little dark line showing the track of the foreign body.

If the foreign body has passed through the lens and is lodged in the vitreous humour, retina, or choroid, great attention must be paid to the condition of the eye, as severe and destructive inflammation is but too likely to ensue. The degree of sight, the state of the field of vision, and the tension of the eyeball, should be especially watched. If in such a case the lens swells up very considerably, it may be wise to perform linear or scoop extraction combined with a large iridectomy, in the hope that the absence of the lens may diminish the inflammation, although it must be remembered that the chief exciting cause—the foreign body—still remains behind, and may at any time, even after the lapse of years, again set up inflammation. In all such cases of injury, the condition of the other eye must also be anxiously watched. At the earliest symptoms of sympathetic inflammation, or even of well-marked and recurrent sympathetic irritation, the wounded eye should be at once removed, for only thus can we ensure the safety of the other. If the injury is so severe that the sight is greatly, and probably permanently, impaired, the immediate removal of the eye may be indicated, even although the other eye does not sympathise. This is especially the case amongst the labouring classes, who cannot be under our immediate supervision, or cannot afford the time to undergo a lengthened course of treatment without the hopes of regaining any useful degree of vision. The same course may be advisable amongst the higher classes, if from circumstances—such as officers being ordered abroad, necessity for a long voyage, etc.—they cannot be under constant supervision, so that the earliest symptoms of sympathetic inflammation may be detected.

13.—REMOVAL OF SOFT CATARACT BY A SUCTION INSTRUMENT.

In the extraction of soft cataract through a simple linear incision, some difficulty is occasionally experienced in removing the firmer portions without exerting a certain amount of pressure upon the globe,

or introducing the curette into the anterior chamber. This difficulty has led Mr. Pridgin Teale* to the ingenious employment of a suction curette for the more easy and complete extraction of soft cataract.

His instrument consists of three parts—a curette, a handle, and a suction-tube.

Fig. 44.

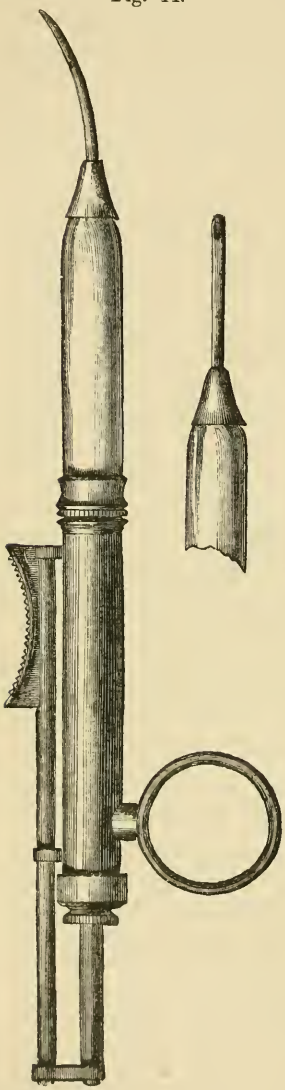

After Lawson.

"The *curette* is the size of the ordinary curette, but differs from it in being roofed in to within one line of its extremity, thus forming a tube *flattened* on its upper surface, and terminating, as it were, in a small cup. The curette is screwed into the 'handle.'

"The *handle* receives the curette, and is hollow for a short distance, thus being a continuation of the tube of the curette. Passing out at right angles from this portion of the handle is a further continuation of the tube, to which the 'suction-tube' can be fixed.

"The *suction-tube* is a piece of india-rubber tubing, ten or twelve inches long, having an ivory or metal mouth-piece at one end, and fitting on to the projecting part of the handle by the other."

Mr. Teale describes his mode of using it thus:—"The anterior capsule of the lens having been freely torn asunder by two needles, a small opening was made in the cornea by the broad needle, through which the suction curette was introduced. Holding the open end of the curette in the area of the pupil, and slightly depressing it towards the posterior capsule, I withdrew, by suction, the soft matter, the pupil becoming perfectly clear in a few seconds."

Mr. Bowman has devised an excellent suction syringe (Fig. 44), the use of which is, I think, more easy, and can be regulated with more nicety than the curette.† The operator having made an incision in the cornea with the broad needle, and freely divided the lens, can introduce the nozzle of

* "R. L. O. H. Rep.," iv, 2, 197.

† Both Mr. Teale's and Mr. Bowman's instruments are made by Messrs. Weiss.

the instrument (which is to be held in the right hand) in the corneal aperture, and gently "suck out" the soft lens substance.

Although it appears that the idea of employing suction for the removal of cataract dates back as far as the fourth century, and that it has since been advocated by several authors, more especially in later years, by Blanchet and Langier, it never attained a recognised position until it was introduced by Mr. Teale. This operation has now met with much and deserved favour, more especially at the Royal London Ophthalmic Hospital, Moorfields, where it has been employed with marked success. It is especially indicated in soft cortical cataract, which may generally be very readily and completely removed by the suction instrument. If the cataract be somewhat more firm in consistence, it will be well to break it up with the needle a few days previously. I have also used it with much advantage in removing portions of soft cortical substance which have remained behind in the pupil in the operations for senile cataract, either in the common flap or Von Graefe's operation, for such portions may often be more readily and thoroughly removed in this way than by rubbing the eyeball or the re-introduction of the scoop. Some care and delicacy are, however, required in the use of this instrument, for, if too great a suction power is employed, hyperæmia (*ex vacuo*) of the iris and the deeper tunics of the eyeball may easily be produced.

14.—SPERINO'S TREATMENT OF CATARACT BY PARACENTESIS.*

This mode of treatment is chiefly based upon the theory that the impairment of vision in cataract is partly dependent upon a temporary disturbance in the intra-ocular circulation, especially an occasional state of congestion of the choroid, and partly upon the opacity of the lens. Dr. Sperino holds that the opaque lens fibres may regain their transparency as long as their intimate structure is not disorganised, which always follows, more or less rapidly, upon the opacity, but less so in old than in young persons. Now, as the operation of tapping the anterior chamber relieves the intra-ocular circulation, it often produces a marked and immediate improvement in the sight, and in some cases often-repeated tappings have at last effected a complete cure. In others their effect has been but moderate, or even negative. The operation consists in making a small puncture with a broad needle at the edge of the cornea or slightly in the sclerotic; a blunt probe is then inserted between the lips of the wound, and the aqueous humour slowly evacuated. The evacuations by the same opening may be made

* Vide a most interesting work by Dr. Sperino, entitled "Etudes Cliniques sur l'Evacuation repétée de l'Humeur aqueuse dans les Maladies de l'Œil," Turin, 1862. Also a review of this work in the "Ophthalmic Review," vii, p. 294.

repeatedly during a single sitting, followed by an interval of several days, or singly at an interval of a day or two. The operations in cataract were repeated a great number of times. In one case 167 tappings were made, and finally linear extraction was performed. I am not aware that this treatment has been adopted by any other surgeon on a sufficiently large scale to warrant any exact conclusion as to its efficacy. It would be, I think, very difficult to find patients who would submit to such a very protracted course of treatment and such numerous operations.

15.—OPERATIONS FOR CAPSULAR AND SECONDARY CATARACT.

I have already stated that capsular cataract often occurs in retrogressive lenticular cataract, and that in such cases it may be advisable to remove the lens in its capsule. If, in an operation for senile cataract, the capsule is found so tough and thickened that it resists the pricker, it should be torn across with a sharp hook, and then, after the extraction of the lens, the capsule should be removed by the hook or a pair of forceps. In such cases the connexion between the posterior capsule and the hyaloid is not unfrequently loosened, and the lens may often be readily extracted in its capsule by the hook. Some operators, in making the section, divide the tough capsule across with the point of the knife.

Secondary cataracts vary much in thickness and opacity. They may be produced by portions of lens substance remaining behind and becoming entangled in the capsule, by the deposition of lymph upon the latter, or by the proliferation of the intra-capsular cells.

Again, if the more fluid constituents of a cataract become absorbed and the cortical substance undergoes chalky or fatty degeneration, the lens gradually dwindles down, and assumes the appearance of a flattened, shrivelled disc.

Mr. Bowman* has also called special attention to another form of secondary cataract, in which the capsule, though quite transparent, is crumpled or wrinkled, and thus produces much confusion of vision by irregularly refracting the rays of light. This condition of the capsule may easily escape detection, even although the eye be examined with the oblique illumination, and is not perhaps noticed until the ophthalmoscope is employed, when the observer finds that he cannot obtain a clear and distinct view of the optic disc, but that it looks somewhat distorted. On then getting the capsule itself into focus, the wrinkles may be readily observed.

No operation for secondary cataract should be performed until the eye has quite recovered from the cataract operation and is entirely free

* "R. L. O. H. Rep.," iv.

from all irritation. Generally three to four months should be allowed to elapse between the two operations. Nor should it be done if the area of the pupil is not of a good size. If it has become contracted, or is partially occupied by lymph, or if there are extensive posterior synechiæ, a preliminary iridectomy should be made, and then, when the eye has become quiescent, the operation upon the capsule may be performed.

Formerly, the favourite mode of operating was by the removal of the obstructing membrane. But this is falling more and more into disuse, as it often proves a very dangerous operation and is far less safe than opening up the membrane by the needle, which is attended by much less risk of setting up inflammation. Moreover, it is a well-established fact that a small clear aperture in the opaque membrane will afford most excellent sight.

For the needle operation chloroform is hardly necessary, unless the patient proves very unmanageable. The eyelids should be kept apart with the stop speculum, and the eye may be steadied with the forceps. Bowman's fine stop needle should then be passed through the cornea at a short distance from the margin, and the operator should endeavour to tear a hole in the centre of the opaque membrane. The portion which is thinnest, least opaque, and consists chiefly of wrinkled capsule, should be selected for this purpose. It is to be torn across in different directions, the point of the needle comminuting the membrane, without, however, being allowed to go deeply into the vitreous humour. If the operator finds, after one or two ineffectual attempts to transfix it and tear it through, that the false membrane yields before the needle and eludes it, or if it is too tough and firm to be torn through, he should at once have recourse to a second needle. This is to be passed into the anterior chamber from an opposite point of the cornea. Transfixing and steadying the false membrane with the needle held in his left hand, the operator employs the other needle to tear the membrane and open it up. Or the points of the needles may be made to cross each other, and then, after being revolved a few times round each other, be separated, which will cause the membrane to be torn across. Great care must be taken to use the needles with extreme delicacy, and not to drag roughly upon the adhesions between the capsule and the iris, otherwise severe inflammation may be set up. If any portion of the iris should have been considerably dragged upon during the use of the needles, it may be advisable to excise this segment, in order to allay any tendency to inflammatory reaction. This ingenious double-needle operation was first devised by Mr. Bowman,* and has proved a most valuable addition to Ophthalmic Surgery.

Should the false membrane be found but slightly adherent to the

* "Med. Chir. Trans.," 1853, p. 315.

iris, so that it floats almost freely in the pupil, the adhesions may be torn through by the needle, and the whole membrane extracted by the canula or small iris forceps through a linear incision. If the adhesions are found to be so firm that a good deal of force would have to be employed to break them down or to divide them, this should on no account be attempted; but the free portion should be caught by a sharp hook, gently drawn through the linear incision, and snipped off, which will leave a good-sized opening in the capsule.

Fig. 45.

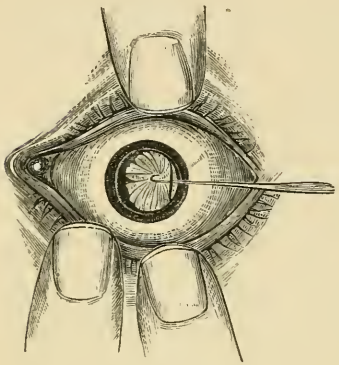

After Stellwag.

In cases of chalky or siliculose cataract, in which the capsule looks like a little wrinkled bag containing small chalky chips of lens, it may be possible to remove the whole capsule with a sharp hook through a good-sized linear incision, as in Fig. 45. But it is often a very dangerous operation, setting up perhaps severe irido-choroiditis, which may even lead to atrophy of the eyeball.

After an operation for secondary cataract, atropine should be applied, the patient be kept in a somewhat darkened room for a few days, and carefully watched, in order that the first symptoms of inflammatory reaction, accompanied, perhaps, by increased intra-ocular tension, may be detected. Within from twelve to twenty-four hours of the operation the patient may experience a good deal of pain in and around the eye, and down the corresponding side of the nose (ciliary neuralgia); there is perhaps some subconjunctival injection and lachrymation, and the sight appears somewhat cloudy. On trying the tension of the eyeball it is found increased, and the iris pushed forward (sometimes partially), so that the anterior chamber is narrowed. If the intra-ocular tension is considerably increased (T 2), and this persists for twelve hours from the commencement, Mr. Bowman* strongly advises that the bulging part of the iris should be punctured with a broad needle, thus establishing a communication between the anterior and posterior chambers, which will generally diminish the intra-ocular pressure and cut short the inflammation.

Dr. Agnew,† of New York, has devised the following operation. He passes a stop needle through the centre of the membrane, thus fixing both the eye and the latter; he then makes a linear incision on the temporal side of the cornea, through which he passes a small sharp-pointed

* R. L. O. H. Rep., iv., 366.

† "Kl. Monatsb.," 1865, p. 389.

hook, the point of which is passed into the same opening in the membrane as the needle. He now tears the membrane, and by a rotatory movement of the hook rolls it up round the latter, and then either draws it out altogether, or, if this cannot be done, he tears it widely open.

16.—DISLOCATION OF THE LENS (ECTOPIA LENTIS).

The dislocation of the lens may either be partial or complete. In the latter case it may be displaced into the vitreous or aqueous humours, or beneath the conjunctiva.

Partial Dislocation.—In the slightest degree of partial displacement the lens is simply turned somewhat upon its axis, one portion of its periphery being tilted obliquely forwards against the iris, the other backwards and away from the latter. Or again, the dislocation may be eccentric, the lens being somewhat shifted towards a certain direction, so that its centre no longer corresponds to the optic axis, but lies more or less considerably to one side of it; the periphery of the lens may even lie across the normal pupil. This form of displacement generally occurs in a downward direction; but it may also take place upwards and inwards, or upwards and outwards. Such partial displacement of the lens may be occasioned by various causes, amongst others by anterior synechia, for if in such a case an adhesion exists between the iris and the capsule of the lens, the latter is drawn forwards with the iris at this point, and therefore somewhat displaced or tilted. It may also occur, as Stellwag has pointed out, in cases of anterior scleral staphyloma.

On examining an eye affected with partial displacement of the lens, we find that when it is moved rapidly about in different directions, the iris is slightly tremulous at the point where it has lost the support of the lens, where the latter has receded from it. Moreover, it is here also somewhat cupped or curved back, being on the other hand pushed forward and prominent at the point where the edge of the lens is tilted forward against it. In the former situation the anterior chamber will consequently be slightly deepened, in the latter narrowed. If the pupil is widely dilated with atropine, we can easily recognise the altered position of the lens by the aid of the oblique illumination, or still better, by the direct examination with the ophthalmoscope. With the latter, the free edge of the lens will be noticed as a sharply defined, dark, curved line, traversing the red fundus, and forming the outline of a transparent or opaque lenticular disc. If the displacement is so great that a considerable portion of the background of the eye can be examined through that part of the pupil in which the lens is absent, a distinct erect image of the details of the fundus will be obtained. In

the reverse image the prismatic action of the edge of the lens can be easily observed, for then the double image of the fundus will appear, and the two images cannot be simultaneously distinctly seen, for whilst the one is clearly defined, the other will appear hazy, and in order to render the latter distinct, either the position of the observer's eye or of the ocular lens must be changed. Such a partial displacement of the lens will also have a peculiar effect upon the patient's sight, for he will generally be affected with monocular diplopia, or polyopia, which is due to the difference in the refraction of the two portions of the pupil, and to the prismatic action of the peripheral portion of lens which lies across it. The state of refraction will also differ in the two portions of the pupil, for in that in which the lens is absent a very considerable degree of hypermetropia will exist. Von Graefe* mentions a case of displacement of the lens, in which, when the patient was endeavouring to distinguish a small object, the eye deviated in a certain direction, in order that the rays might impinge upon the central portion of the lens. If the pupil is small, the patient may observe the edge of the displaced lens entopically, or the same phenomenon may be produced with a dilated pupil, if he looks through a minute aperture in a card or a stenopaic apparatus.

If the dislocation of the lens is due to an accident, etc., *e.g.*, a severe blow upon the eye, the sight is often greatly impaired directly afterwards by hæmorrhage into the aqueous and vitreous humours. As the blood becomes absorbed the sight may gradually improve, if there is no other deep-seated lesion.

17.—COMPLETE DISLOCATION OF THE LENS

Into the Vitreous Humour.—The iris will be observed to be markedly tremulous when the eye is moved in different directions, and the anterior chamber will be somewhat deepened. If the catoptric test be employed, it will be found that the lenticular reflections are wanting. On examining the eye with the oblique illumination, the absence of the reflection from the anterior capsule will also be noticed, and the position of the displaced lens will in most cases be easily recognised, more especially if the pupil is dilated, as a portion of the lens generally occupies some part of the pupil, or floats across it when the eye is moved. If the lens is opaque, the sight will of course be temporarily lost when the lens lies across the pupil. The position of the lens will vary with that of the head. If the latter is held erect, it will sink down into the vitreous humour; if the head is bent forward, the lens will fall against the pupil, or may even pass through it into the anterior chamber. With

* "A. f. O.," i, 2, 291.

the ophthalmoscope, the situation of the lens in the vitreous humour can be very easily ascertained, for it will appear in the form of a darkish lenticular body, generally lying in the lower portion of the vitreous humour. The latter is of course more or less fluid, generally entirely so. In spontaneous luxations, the lens is frequently opaque, and in such cases the sight will be greatly improved. Even if it is transparent at the time of the displacement, it generally becomes opaque in the course of a few months. In such cases the cataract may assume the lamellar form, only some layers around the nucleus becoming clouded. But a dislocated lens may retain its transparency for very many years, if its capsule is uninjured. Mooren has seen a case in which the lens remained clear for 36 years.* When the lens has sunk into the vitreous humour out of the area of the pupil, the eye will be extremely hypermetropic, in fact, in a similar condition to one operated on for cataract.

Dislocation of the Lens into the Anterior Chamber.—Although this condition may occur in a transparent lens, it is more frequent when the latter is chalky, and perhaps diminished in size. The displacement is moreover generally spontaneous and gradual, and not due to an accident. There can be no difficulty in recognising the affection, for in the anterior chamber will be observed a lenticular disc, either transparent and diaphonous, or white and opaque.

If the lens is in its capsule, a sharply defined yellow border will be noticed, encircling the disc (Graefe). The lens may be either entirely in the anterior chamber, or a part may lie in and behind the pupil. The latter condition is especially dangerous, as the presence of the lens in the pupil is apt to set up irritation and inflammation of the iris, from maintaining a constant "teazing" and contusion of the edges of the pupil. In some cases, the lens does not retain its position in the anterior chamber, but falls back again into the vitreous humour, and it may thus frequently alternate in its position, being sometimes found in the anterior chamber, at others in the vitreous. Its presence in the anterior chamber will cause a considerable deepening of the latter, and a cupping back of the iris. Adhesions are sometimes formed between the capsule and the cornea; the latter may ulcerate and the lens escape through the perforation (Graefe).†

Severe inflammatory symptoms may also supervene, implicating the cornea, iris, and the deeper structures of the eyeball, and accompanied perhaps by an increase in the intra-ocular tension. There is often also very severe periodic ciliary neuralgia. But the inflammation may even extend sympathetically to the other eye. On the other hand, the lens may remain for a very long period in the anterior chamber without producing any irritation or pain.

* Mooren, 257.

† "A. f. O.," i, 1, 343.

Dislocation of the Lens under the Conjunctiva.—This is always due to an accident, generally to a heavy blow from some blunt substance, hitting the eye below, and knocking it forcibly against the roof or upper edge of the orbit, hence the most frequent seat of this displacement is upwards and inwards, or upwards and outwards. The rupture in the choroid generally occurs quite anteriorly, between or in front of the insertion of the recti muscles. This form of dislocation is most frequently met with in persons after the age of thirty or forty, when the sclerotic has lost its elasticity. It is characterised by the following appearances:—Beneath the conjunctiva is noticed a small, well marked, prominent tumour, which may even cause a little circumscribed prominence in the lid. The colour of the tumour varies, it may be dark from the presence of effused blood in and beneath the conjunctiva, or of a portion of prolapsed iris, or the conjunctiva may be transparent, and only slightly injected, and then the greyish-white lens can be easily recognised. But in some cases only a part of the lens has escaped beneath the conjunctiva, the rest remaining within the eye. Whilst the sclerotic has been ruptured, the conjunctiva on account of its laxity and elasticity has generally yielded before the lens, and has not given way or been torn, but covers the displaced lens. The pupil is mostly irregular and drawn up, and there is a more or less considerable prolapse of the iris. If the capsule has been ruptured, and the lens escaped from it, the remains of the torn shreds of capsule will be seen with the ophthalmoscope, just as after an operation for cataract.

Dislocation of the lens may be spontaneous, and is then generally due to a gradual relaxation or elongation of the suspensory ligament, or its partial rupture. In such cases the lens is often opaque, and the vitreous humour perhaps fluid. Moreover, in such a condition a very slight shock to the eye, which has perhaps been unnoticed by the patient, will produce dislocation of the lens. The affection may also be congenital, and even hereditary, occurring in several members of the same family. Thus, Mr. Dixon* mentions a case in which a partial displacement of the lens existed in a mother and three sons. Mr. Bowman narrates a case in which a patient suffering from dislocation of the lens had two uncles affected with the same disease. If the affection is congenital, it is generally accompanied by more or less amblyopia, and perhaps nystagmus, and such eyes are as a rule also very myopic. In such cases the dislocation mostly exists in both eyes. But the most frequent cause is an injury to the eye from blows or falls upon this organ, which cause a rupture of the suspensory ligament, and a more or less complete dislocation of the lens. Mr.

* "Roy. Lond. Ophthal. Hosp. Reports," i, 55.

Bowman* has called attention to the fact, that glaucomatous symptoms occasionally arise in cases of dislocation of the lens. This appears to be due to the pressure of the lens upon the iris, thus dragging upon its ciliary attachment, which sets up irritation, and a hypersecretion of the fluids within the eye.

The treatment of dislocation of the lens must vary according to the exigencies of the case. Where it is but slight, the sight may not be materially affected, and no operative interference may be indicated. If, however, the displacement is so considerable, that the free edge of the lens lies in the pupil, and thus gives rise to great impairment of the sight, and very annoying diplopia, an endeavour should be made to remedy this defect. The best mode of treatment is that originally adopted by Wecker,† viz., an iridodesis made in the opposite direction to that in which the lens is displaced, so that the artificial pupil will be brought opposite that portion of the eye in which the lens is deficient, and the iris will be drawn over the displaced lens, and cover the latter to a more or less considerable extent. The patient will then be in the condition of a person whose lens has been extracted, and he will be able to see well both at a distance and near at hand through suitable convex glasses. Iridodesis is in such cases for obvious reasons to be preferred to an iridectomy. If the lens is completely dislocated into the vitreous humour, and is setting up no disturbance, it is wiser not to interfere. But if inflammatory complications arise, or the sight is much impaired by the lens floating about across the pupil when the eye is moved, it will be best to remove it. An iridectomy should be made opposite the point towards which the lens is displaced, and the latter is then to be removed by Critchett's scoop. The operation is, however, often very dangerous, for a considerable amount of fluid vitreous will be lost, and severe irido-choroiditis with subsequent atrophy of the globe may supervene.

When the lens is luxated into the anterior chamber, we must endeavour to obtain its re-position into the vitreous humour, by making the patient assume the horizontal posture, and applying a compress bandage. If it falls back into the vitreous humour, its maintenance in this situation may be assisted by an iridodesis, or temporarily by the application of the solution of Calabar bean. If the presence of the lens in the anterior chamber sets up inflammatory reaction, or impairs the sight, it should be extracted with the scoop, and it will be better to combine an iridectomy with this operation. The incision should be made in the lower part of the cornea with Graefe's cataract knife. To prevent the escape of the lens into the vitreous humour, Wecker advises that it should be transfixed with a needle, and kept in

* "Roy. Lond. Ophth. Hosp. Reports," v, 1.

† Vide Wecker, 2nd edition, p. 477.

its position in the anterior chamber, until the scoop can be introduced beneath it. If the lens simply disturbs the sight without setting up any inflammation, we may endeavour to gain its absorption by the operation of division, care being taken not to lacerate the capsule too freely, but rather to repeat the operation several times.

In the subconjunctival dislocation, an incision should be made, and the lens removed; and the prolapsed portion excised, so that the wound may be quite smooth. If a tolerably firm union of the lips of the wound has already taken place, it will suffice to apply a compress bandage; but if the rupture in the sclerotic is gaping, it will be better to unite its edges with one or two fine sutures, in the same manner as has been advised for incised wounds in this region.

Chapter VI.

THE USE OF THE OPHTHALMOSCOPE.

It was formerly supposed that the black appearance of the pupil is due to the fact that all the light which enters the eye is absorbed by the choroid, and consequently that none is reflected towards the observer. This, however, is not the case, for a considerable portion is diffusely reflected, and may be caught up by the observer's eye if this is placed in the direction of the emerging rays. In such a case, the pupil no longer appears black, but is luminous, having a bright red glow. Cumming, in 1846, pointed out that all normal eyes are luminous, more especially if the pupil is dilated; but that it is necessary, in order to obtain this luminosity, that the eye of the observer should be placed parallel to the incident rays, that is, as nearly as possible in the direct line between the source of light and the eye observed. But in the ordinary mode of examination this is next to impossible, as the observer's head must be placed between the light and the patient's eye, and will therefore cut off the rays passing to the latter. Moreover, even if some of the reflected rays could be caught up, they would only afford the appearance of a bright red glow, or, at the best, but a very confused and indistinct image of the fundus, owing to the insufficiency of the illumination and to the direction of the emerging rays. For, in consequence of the optical condition of the eye, the incident rays, if the eye is accommodated for the object, are so reflected that they emerge again in exactly the same direction as they entered, and would therefore be brought to a focus at the point whence they originally emanated, that is at the source of light. The object and its retinal image are, in fact, in the position of conjugate foci. The pupil of the patient's eye will therefore appear black if it is accommodated for the pupil of the observer, as the latter will then only see the reflection of his own pupil.

A glance at Fig. 46 will readily explain this. If F is the object, and *c* its image formed upon the retina, rays reflected from *c* will be brought to a focus at F, so that whichever of these two points is the radiant-point, the other will be the focal point. Now, if we place our

eye at F, the luminous rays emanating from our pupil (which is black) will be insufficient to illumine the fundus of the patient, and hence his pupil will also appear black.

Fig. 46.

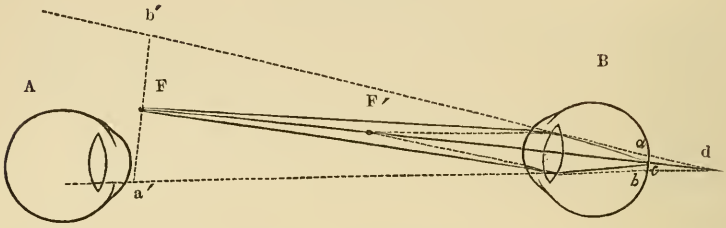

But, in certain conditions of the eye, a considerable amount of reflection may be obtained, as, for instance, in the eyes of albinos, and in cases in which the retina is bulged forwards by morbid products. It is a well known fact that the pupil of the albino is markedly luminous. This is not caused, as is often supposed, by a greater reflection of the rays which enter the pupil, on account of the deficiency of the pigment in the choroid, but is due to the great amount of light which passes through the iris and sclerotic. The truth of this statement was proved by Donders, who placed before an albinotic eye a small screen, having a circular aperture for the pupil, but covering the iris and sclerotic in such a manner that no light could pass through them. It was then found that the pupil lost its luminosity, and at once acquired the usual darkness of other eyes.

Again, if the position of the retina is altered, it being bulged forward by a tumour behind it (amaurotic cat's eye) or by fluid, more light will be reflected, and the fundus will appear luminous. Moreover, on account of the more anterior position of the retina, the emerging rays will be divergent, and hence easily brought to a focus upon the retina of the observer.

Brücke, in 1844–47, made a series of interesting experiments with regard to the luminosity of the eye, and showed that if the eye under examination is neither accommodated for the light nor for the pupil of the observer, but for some other nearer point, a portion of the light reflected from its background may be caught up by the observer, and the pupil will then appear red and luminous. This is shown in the preceding figure (Fig. 46). If F is a luminous point for which the eye under observation (B) is accommodated, the rays emanating from F will be brought to a focus upon the retina at *c*, at which point a clear and distinct image of F will be formed. This being so, the rays reflected from *c* will unite at F, for F and *c* are conjugate foci. If the eye of the observer (A) be placed beside F, it will receive no luminous

rays from B, and will hence see the pupil of the latter black. Now, if whilst the eye, B, remains accommodated for the luminous point, F, the latter is brought nearer to the eye, to F′, the rays emanating from it will no longer be brought to a focus on the retina at *c*, but behind it, at *d*, and a circle of diffusion, *a b*, will be formed upon the retina. As the eye is accommodated for the distance, F, the rays emanating from the points of the circle of diffusion, *a*, *b*, will be brought to a focus at a′ b′, and there form an enlarged and inverted image of *a b*. Hence the eye of the observer, placed at A, will receive a portion of this reflected light, and therefore the pupil of B will appear more or less luminous.

We shall see, hereafter, that Helmholtz turned this experience of Brücke's to a practical use, and constructed his simplest ophthalmoscope upon this principle. Before entering upon this, I must state that Helmholtz, in 1851, devised an apparatus by which the observer was enabled to place his eye in the direct line of the emerging rays, and thus gain a view of the fundus. The accompanying figure and description of this instrument are from Mr. Carter's admirable translation of Zander's work on the ophthalmoscope—a work I cannot too warmly recommend to all who wish to gain a thorough knowledge of the theory of the ophthalmoscope, its use in practice, and the different morbid changes of the fundus which may be recognised with it. The student will also derive great benefit from the perusal of Mr. Hulke's and Mr. Wilson's excellent works on the ophthalmoscope, which, though shorter and less exhaustive, yet contain a great amount of information, conveyed in a very clear and concise manner.

"Under certain conditions, however, we may see the fundus of the human eye shine with a reddish lustre. Such conditions are shown in Fig. 47, where *F* is a luminous point, and *S* a polished plate of glass, which reflects the light *a b* falling upon it, into the observed eye *B*, in a direction as if it came from a point *F′* lying as far behind the plate *S* as the actual point *F* lies before it. Disregarding the loss of light caused by irregular reflection and other circumstances, the rays *a d* and *b c*, reflected from *S* enter the observed eye, and become united at *e*. The emerging rays in their exit from *B* must take precisely the same course as in their entrance; they proceed, therefore, in the converging cone *c b a d* to the plate of glass, by which they are partly reflected back to *F*, while the remainder proceed in an unaltered direction forwards, to unite in a focus at *F′* and then again to become divergent. If now the eye of the observer be placed so as to intercept them before their union, as at *A′* it receives from *e* convergent rays that, made more convergent by its own refraction, are united before they reach its retina, upon which, after crossing, they form only the dispersion circle *α′ β′*. The eye of *A′* would certainly, therefore, receive

no image, but only the sensation of light—it would see the eye B illuminated, and the same would happen if it were so placed as to intercept the diverging rays behind the point F'.

Fig. 47.

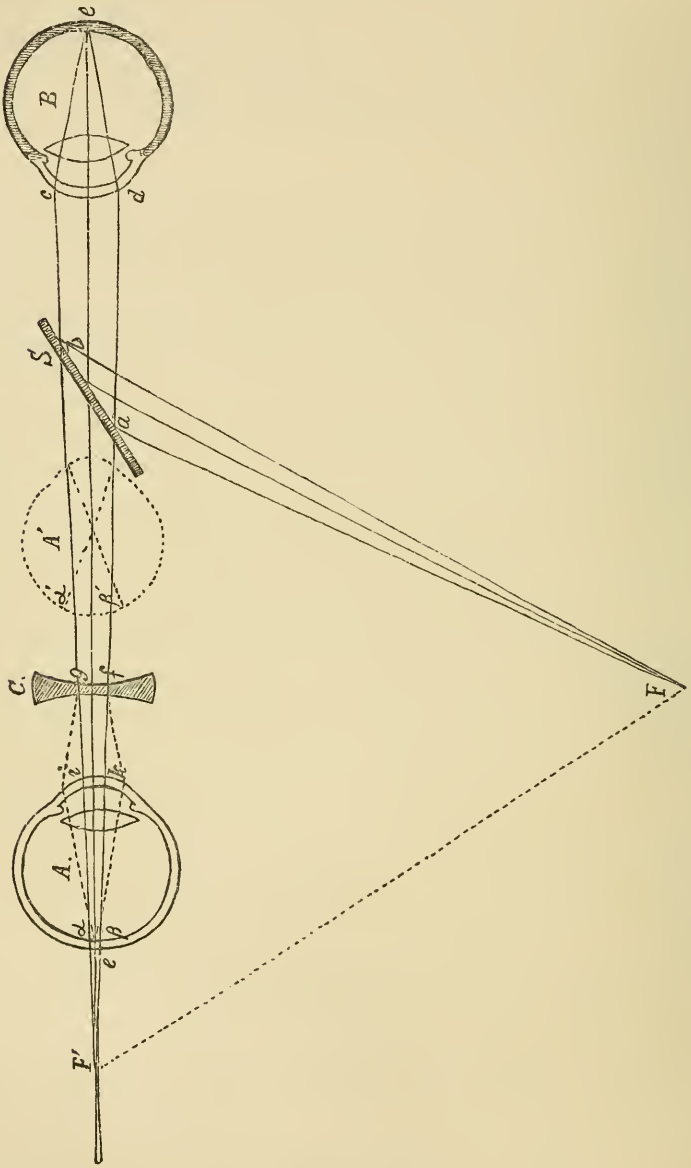

After Zander.

"After this principle was announced by Von Erlach, Professor H. Helmholtz, then of Königsberg, and since of Heidelberg, was the first to discover the reason why the retina was not distinctly seen, and to find the means of rendering it visible. The problem was threefold: the observed eye must be sufficiently illuminated; the eye of the observer must be placed in the direction of the emerging rays, and these must themselves be changed from their convergence, and rendered divergent or parallel. The solution of the main difficulty was obtained when, in a darkened chamber, the light of a lamp was allowed to fall on a well polished plate of glass in such a manner that the rays reflected therefrom entered the eye to be observed. The observer placed himself on the other side of the glass plate, and made the convergent rays divergent by a concavelens. Thus in Fig. 47 we place the concave glass c before the eye of the observer *A*, and convert the convergent pencil *b g f a*, coming through *S*, into the divergent pencil *g i k f*, so that the eye *A* may form upon its retina *e'* a clear image of the point *e*.

"The combination of such an illuminating apparatus with suitable lenses forms an instrument by which it is possible clearly to see and examine the details of the background of the eye of another person. To this instrument Helmholtz gave the name of Eye-mirror, or Ophthalmoscope."

In order to obtain a better illumination Helmholtz afterwards employed three plates of glass instead of a single slip. A still greater advance was made when Helmholtz utilized Brücke's experiment above referred to, and employed a strong convex lens, held before the patient's eye, to converge the rays reflected from a large circle of diffusion formed upon the retina. In this way an enlarged and inverted image of the fundus was formed between the lens and the observer. This constitutes the "examination of the actual inverted image."

Helmholtz placed the flame of a candle before the eye under observation, and a screen behind the flame, so that the observer's eye could be brought close to the source of light, and thus catch the rays after they had been united by the convex lens, and formed an image of the fundus. This point of union lies at the focal distance of the lens. This mode of examination was, however, troublesome and inconvenient, and hence Ruete had recourse to a concave mirror having a central aperture for the observer's eye, and he thus still more increased the illuminating power. Since then different forms of mirror have completely superseded the plates of polished glass.

The following description and illustration from Zander clearly explain the action of the concave mirror in the inverted examination, *i.e.*, the use of a convex lens placed a short distance from the eye under observation, so as to converge the rays emanating from the circle of

diffusion formed upon its retina. The patient is to accommodate for an infinite distance, so that the rays issue parallel from this eye.

"*Examination of the actual Inverted Image.*—In Fig. 48 F is again the flame, *S* the mirror, *L* the convex lens, and *B* the eye observed. The rays *a e b f*, proceeding convergent from the mirror and rendered more convergent by their passage through the lens, strike the cornea of *B* in *c* and *d*. Rendered still more convergent by the dioptric apparatus of *B*, they intersect at some point in front of the retina, for example at *o*, and form on the retina the dispersion circle *α β*. On account of the passive state of accommodation of the eye, the rays proceeding from it will follow courses parallel to the lines of direction *α x* and *β x*, and after their refraction by the lens *L* will unite to form at *α′ β′* an actual inverted image of *α β*."* In this mode of examination it will be observed that the aerial image of the fundus is situated between the observer and the convex lens, and that it is inverted and enlarged. If we desire to increase the size of the image, a somewhat weaker object lens ($3\frac{1}{2}$ to 4″ focus) should be employed, for as this renders the rays less converging the image will be proportionately enlarged, but will at the same time lie somewhat further from the eye; this is, however, accompanied by the disadvantage that the field of vision is much diminished in size. Hence the best plan is to use first a lens of 2 or $2\frac{1}{4}$ inches focus, so as to gain a view of the whole fundus, and then to change this for a weaker lens if we desire to examine any special part of the back ground with particular care and minuteness. The size of the image may also be considerably magnified by placing a convex lens of 8 or

Fig. 48.

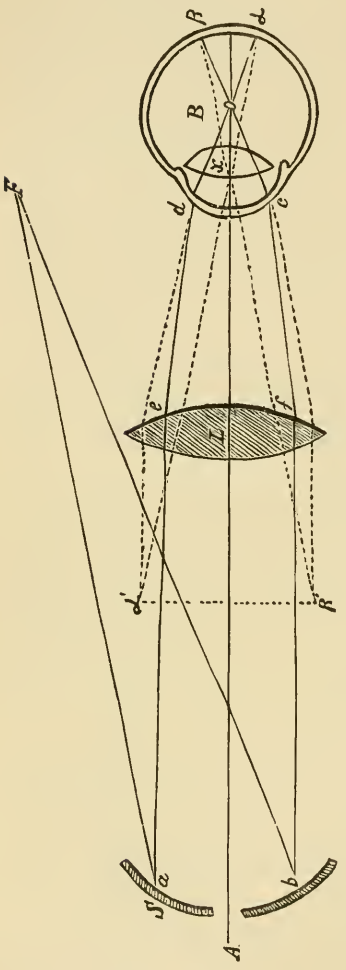

* Carter's Translation of Zander, p. 20.

10 inches focus in the little clip behind the mirror. In this case the observer must, however, approach somewhat closer to the patient.

"*In the examination of the virtual erect image* the mirror alone is used, without the aid of an object lens, the observer approaching very closely to the patient's eye. He will thus obtain an erect, geometrical image of the fundus, the image being apparently situated behind the patient's eye, as in Fig. 49.* *E* is the examined eye, and *E'* the position of the examiner's eye; *r r* are divergent rays from *F*, a flame incident on the concave speculum *A B*, which reflects them convergingly as *r' r'* to *E*, about two inches distant, upon the fundus of which they form the circle of dispersion *d d*. The rays reflected from any point *a b* within the circle, after leaving *E*, assume a direction parallel to the prolongations of the lines *a c b c* (which pass through *c* the optical centre of *E*) and reach the observer's eye at *E'*, on the retina of which they form an inverted image of *a b*, which is mentally projected as the *enlarged, erect*, geometrical image α β." It will be explained hereafter that it is generally necessary to make use of an ocular lens behind the mirror, in order to gain a clear and distinct image of

Fig. 49.

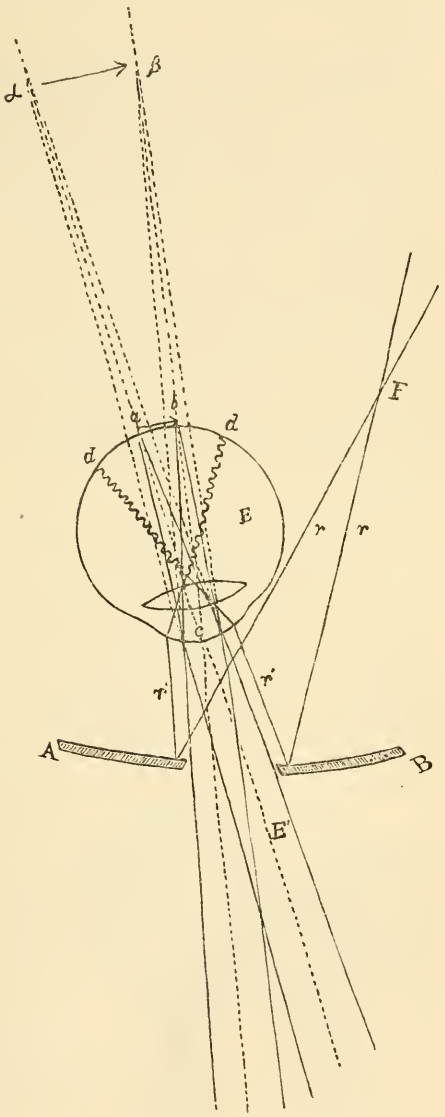

* This figure and its explanation are from Mr. Hulke's able work on the Ophthalmoscope.

the fundus. The nature and strength of this lens depend upon the state of refraction of the eye of the observer and that of the patient's.

I must now pass on to a brief description of the different forms of ophthalmoscope which are in most frequent use. For a full and accurate description of the various kinds of ophthalmoscope which have been invented, I must refer the reader to Mr. Carter's translation of Zander.

Ophthalmoscopes may be divided into four different classes.

1. The portable or hand ophthalmoscopes. Of these I shall notice those of Liebreich, Coccius, and Zehender.

2. The fixed or stand ophthalmoscopes, such as Liebreich's and its excellent modification by Smith and Beck.

3. The binocular ophthalmoscopes of Giraud-Teulon, and of Laurence and Heisch.

4. *The aut-ophthalmoscope.*

All ophthalmoscopes may also be divided into two principal classes, the *homo-centric* and the *hetero-centric.* In the *homo-centric* the mirror is concave, and its focus, calculated from its surface, is fixed and definite ; whereas in the *hetero-centric* the mirror is plane or convex, and the focus is negative, situated behind the mirror, and can be altered according to the strength of the bi-convex lens which is fixed beside the mirror.

1.—THE PORTABLE OR HAND OPHTHALMOSCOPES.

(1.) The Ophthalmoscope of Liebreich.

As has been already mentioned above, Ruete was the first to employ a concave perforated mirror (which was, however, fixed) as a substitute for the slips of glass of Helmholtz, and this principle has formed the base for the numerous modifications at present in use. Of all the different forms of concave mirror I think Liebreich's (Fig. 50) the most handy and useful. It consists of a concave metal mirror, about $1\frac{1}{4}$ inch in diameter, and of 8 inches focal length. Its centre is perforated by a small aperture, about 1 line in diameter, the edges of which are exceedingly thin. The bronze back of the speculum around this opening is bevelled off towards the edge, so that the latter may be as thin as possible, in order that the peripheral rays of the cone of light

Fig. 50.

which passes through the aperture, may not be intercepted and cut off by a thick broad edge, which would give the opening the character of a short canal. Behind the speculum, which is fixed upon a short handle, is a small clip for holding a convex or concave lens.

(2.) The Ophthalmoscope of Coccius.

This instrument consists of a plane mirror combined with a lateral bi-convex collecting lens. Its chief advantages over the concave mirror are:—that the observer's eye is placed within the cone of reflected light, instead of being behind it; that the focal distance of the mirror can be altered according as the lens at the side is approximated or placed further from the speculum, or as the power of the lens is changed; the light can be more concentrated upon one point of the retina; and the corneal reflex is far less. These advantages over the concave mirror are especially marked in the examination in the direct image. With the concave mirror, only a cone of light corresponding in size to that of the pupil is admitted into the eye, and as the size of this cone diminishes with the approximation of the mirror, it follows that in the direct examination the illumination of the fundus is but slight. Moreover, on account of the very close proximity in which the mirror has to be brought to the patient's eye, much of the light from the lamp is often intercepted, whereas this is obviated by the collecting lens in Coccius' instrument. The latter is, therefore, to be much preferred to the concave mirror for the direct method of examination. For the indirect method the advantages are less marked, but even for this I prefer it, for reasons which I shall mention hereafter.

Coccius' ophthalmoscope (Fig. 51), as made at present, consists of a plane metal mirror, having a small central aperture. Behind the mirror is a hinged clip to hold a convex or concave lens. A lateral bi-convex lens of 5 inches focal length is held in a large clip mounted on a jointed bracket, which is so connected with the neck of the handle that it permits of the lens being moved to either side of the mirror.

Fig. 51.

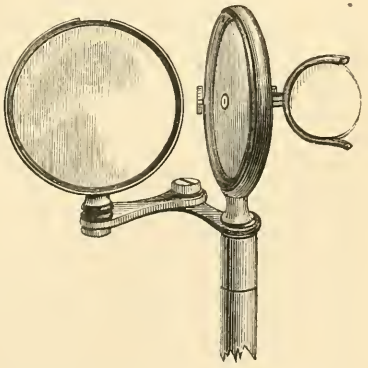

The original form of Coccius' ophthalmoscope differed from that which I have described above, and which is at present in general use, both in being square in shape, and in being made of glass instead of metal. The square mirror was

inconvenient, and could not be steadied so well against the orbit as the circular. But the great disadvantage of the glass mirror was (as Helmholtz pointed out) that the aperture could not be bevelled down to so fine an edge as the metal one, in consequence of which more or less of a canal existed, which intercepted many of the peripheral rays, and produced considerable diffraction.

The mode of using Coccius' ophthalmoscope is as follows :—The collecting lens is to be turned towards the flame, which should be somewhat more than twice the distance of the focal length of the lens from the observer. The mirror is then to be set somewhat slanting to the lens and the eye of the patient. If the mirror is properly adjusted for the lens and the flame, we shall obtain, if we throw the image of the flame upon the palm of our hand or the cheek of the patient, a bright circle of light, with a small dark central spot, which corresponds to the opening in the speculum. The dark spot is then to be thrown into the pupil of the eye under examination, the surgeon placing the mirror close to his own eye, and looking through the aperture into the patient's eye, which should afford a bright luminous reflex. For the indirect mode of examination a bi-convex lens of from 2 to 3 inches focus is to be held before the eye under observation. I, moreover, also use a convex lens of 8 or 10 inches focus behind the mirror, in order still more to magnify the image. If the direct examination is employed, a concave lens will generally be required behind the speculum. At first this instrument may be somewhat more difficult to use than the concave mirror, on account of our having to regulate the position of the collecting lens with respect to the flame and the mirror; but a little practise and perseverance will very soon overcome this difficulty.

(3.) The Ophthalmoscope of Zehender.

This consists in the combination of a slightly convex mirror with a bi-convex collecting lens. The illumination of the retinal image is thus greatly increased, for the whole of the cone of light reflected from the mirror can be collected into a narrower section, and can be thrown into the eye without the peripheral rays being intercepted by the edge of the pupil; more light can also be diffused over the fundus, and it can be more strongly concentrated upon one point.

This ophthalmoscope is, in fact, a modification of that of Coccius, and it very closely resembles the present form. Indeed, at the first glance, they may be readily mistaken for each other. On closer observation it will be, however, noticed, that Zehender's mirror is convex, whereas that of Coccius is quite plane. Moreover, on looking into Zehender's, we get a smaller image of our face than is the case with that of Coccius. It is certainly the best ophthalmoscope for the direct

examination, but I prefer Coccius' for the indirect mode of observation. Indeed, the latter answers so well for both purposes, that for the general surgeon it will amply suffice.

2.—THE FIXED OPHTHALMOSCOPE OF LIEBREICH.

This instrument is constructed upon the principle of the concave mirror as it is employed in the indirect mode of examination, and is so arranged that the whole apparatus (mirror and object lens) is fixed to a table, thus allowing the surgeon free use of his hands, and when it is properly adjusted, enabling even an unskilled observer to see the details of the fundus.

The instrument consists of two tubes, moving one over the other. That nearest to the surgeon has a small oblong portion cut out of its side, in order to admit the light to the concave mirror, which is attached to its extremity. Behind the speculum there is a small clip for an ocular lens. The other tube carries, at its free end, a bi-convex object lens of from 2 to $2\frac{1}{2}$ inches focus, which is to be placed about $2\frac{1}{2}$ inches from the patient's eye. The two tubes are moveable, one upon the other, by a rack and pinion, so that the mirror and the object lens may be adjusted to any required distance. The whole apparatus is supported on an upright stem, and may be fixed by a clamp to the corner of a table. This stem is also supplied with a moveable rest to receive the patient's chin, and thus to steady his head, which purpose is also assisted by a small arc, supported by a rod adjusted to the upper end of the stem, the arc receiving the patient's forehead. Two small black shades are adjusted to the tubes, so as to cut off the light of the lamp from the eyes of the patient and the observer. The lamp is to be placed a few inches from the instrument, and nearly opposite to the opening in the tube containing the mirror, so that its rays may fall direct upon the latter. The patient is to be seated at the other end of the apparatus, having the eye under examination on a level with the object lens, and about $2\frac{1}{2}$ inches from it. Before illuminating his eye, it will be best to throw the light upon the palm of our hand, upon which it should form a bright circle of light having a small central dark spot; if this is obtained, the instrument is properly adjusted, and the light should be thrown into the patient's pupil, which should be widely dilated by atropine. If the reflection is not round, but jagged or faint, there is some fault in the adjustment of the lamp, mirror, or object lens, which must be corrected before the examination is commenced. If the reflections of the lamp on the retina confuse the image, the object lens should be slightly turned, so as to separate the two reflections and remove them from the centre of the field of view.

This instrument is especially useful for demonstration to a class, or for the purpose of drawing the appearances of the fundus, as it leaves both hands of the surgeon at liberty. For common examination it is too tedious and inconvenient, as we are completely dependent upon the patient, for the slightest movement of his eye will throw the object out of view, whereas with the hand ophthalmoscope we are chiefly dependent upon our own dexterity.

A very excellent modification of Liebreich's instrument has been made by Messrs. Smith and Beck, as suggested by Mr. Kilburn. It is more easily adjustable, and its position with regard to the patient and observer can be more readily changed. Instead of being screwed on to the edge of the table, this instrument is fixed upon a small board supplied with rollers, which enables its position to be changed with great facility, and quite independently of the patient. Moreover, the standard carries a paraffin lamp, so that the position of the ophthalmoscope towards the light always remains the same, even although the former may be moved nearer to or further from the patient. This arrangement saves a great deal of time and trouble, and obviates the constant change of position between the lamp and the ophthalmoscope, necessitated by any movement of the latter. The rest which supports the patient's chin instead of being attached to the instrument is independent of it, and is supported on a separate standard. This permits the position of the instrument to be changed without affecting that of the patient.

3.—BINOCULAR OPHTHALMOSCOPES, Etc.

We are indebted for this valuable and ingenious instrument to Dr. Giraud-Teulon, who was the first to solve the difficult problem how it was possible to gain a binocular view of the details of the fundus, and thus give a stereoscopic effect to the image.

The annexed diagram (Fig. 52) will explain its mode of action. Let O be the eye of the patient, L the object lens, and *m n* the concave mirror, having a central aperture. Behind the mirror are two rhombs (R R) of crown glass, ground so as to afford a double refraction at an angle of 45°. These rhombs are in contact at the edge *o*, thus equally dividing the aperture of the mirror. The effect of this arrangement is that each pencil of rays diverging from the actual image (*a*) of the background of the eye after falling upon the mirror, is divided into two—a right and left half—and is then reflected by the opposite sides of the rhombs in such a manner that it will emerge parallel to its original direction, and give rise to two inverted images *d* and *g*. The one (*d*) belonging to the right eye, the other (*g*) to the left. In order to cause these two images to become united, two decentrated lenses are

adjusted behind the rhombs. The two images d and g are consequently united at a', and the observer thus gains one stereoscopic view of the details of the fundus.

The disadvantage of this ophthalmoscope, as originally constructed, was that as the rhombs were adjusted for a certain fixed distance, it only suited persons whose eyes were a corresponding width apart from each other; for if they were either nearer or further apart than the ocular openings, the surgeon either found that one eye was altogether excluded from participation in the visual act, or that he saw double. This difficulty has now been removed, by a division of one of the rhombs into two parts, the outer of which is moveable, and thus allows of the instrument being adapted to all eyes.

Fig. 52.

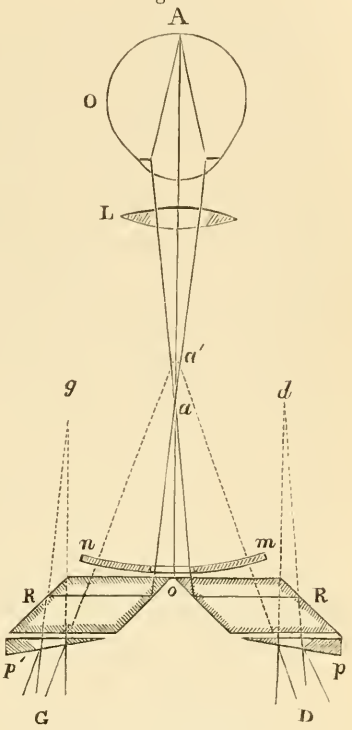

After Giraud-Teulon.

The mode of using this instrument differs somewhat from that of the ordinary monocular ophthalmoscope. Before attempting to use it, the observer should accurately adjust it for his eyes, so that when he is looking with both eyes at an object he receives a single, clearly defined image. The readiest mode of adjusting the instrument is to pull out to its furthest extent the screw at the end, which governs the position of the moveable half of the prism, and then to look through the ocular openings at the flame of a lamp placed at a distance of from 12 to 18 inches. If the observer only sees one image of the flame, he must alternately close each eye and notice whether the image remains apparent on the closure of either eye; if so, the instrument is properly adjusted. But if the image disappears when the one eye is shut, it shows at once that the observer was only looking through one ocular opening, and that the position of the rhomb must be changed. If two images are seen, the screw must be gently pushed in (or out, as the case may be) until they are brought closer and closer together, and are at last fused into one clear and well defined image, which must remain apparent on the closure of either eye. The lamp is then to be placed directly behind the patient, so that its rays may pass over his head to

the observer, who is seated straight before him. Before the examination is commenced, the surgeon should again convince himself of the proper adjustment of the instrument, by throwing the light into the pupil and noticing whether or not he sees one image of it, and whether this remains apparent when either eye is closed. At first, it is better to dilate the pupil with atropine, as this greatly facilitates the examination, for even to an accomplished ophthalmoscopist the binocular ophthalmoscope will prove somewhat strange at the commencement, and will require to be used a few times before he becomes thoroughly familiar with it. In the more recent form of Giraud-Teulon's instrument, the mirror admits of a lateral movement, so that the lamp may be placed at the side of the patient. I, however, much prefer the illumination from above; still this is not always convenient, and therefore it is necessary that the mirror should have a lateral movement, more especially for the direct examination, which it renders more easy.

A very excellent form of binocular ophthalmoscope has been invented by Messrs. Laurence and Heisch. It consists of a set of prisms arranged so as to divide the rays into two. The two central prisms are fixed, but the two lateral ones are moveable in such a manner that they not only allow of a lateral movement, but their inclination can also be changed, so that the angle of divergence of the rays from the median line can be altered as may be necessary. On account of this arrangement the decentred lenses of Giraud-Teulon are unnecessary, and instead of these, convex spherical lenses may be employed, and the image be thus considerably enlarged.

"The instrument* consists of a horizontal metallic plate 1½ centimetre wide and 10 centimetres long, with a central perforation. Behind this plate the central prisms are fixed, and the lateral ones slide in moveable settings, furnished with an index and graduated scale, by which their distance apart can be read off at a glance. Their inclination is regulated by a screw that acts upon both of them at once. The mirror turns upon a pin on the upper part of the plate, and the instrument is completed by a moveable wooden handle. The metallic portions are constructed of aluminium bronze, and the total weight is thus reduced to 2 ounces and 50 grains. The case, as fitted up by Messrs. Murray and Heath, contains also an object lens, and two pairs of oculars, and is made of a shape and size convenient for the pocket."

This ophthalmoscope possesses certainly several advantages over that of Giraud-Teulon. In the first place it is much lighter, which is very convenient if numerous cases have to be examined, for then a heavy instrument proves irksome and fatiguing. Again, on account of the alteration which can be made in the inclination of the prisms, the strain upon the internal recti muscles, in maintaining a forced convergence in

* Vide Carter's Translation of Zander, p. 61.

order to unite the double images, is done away with. But this instrument is rather more apt to get out of order than that of Giraud-Teulon, if it be carelessly handled, as is apt to be the case in a class, where it is used by many different persons.

The great advantage of the binocular ophthalmoscope consists in its affording us a stereoscopic view of the details of the fundus, so that they are brought into relief. We are thus enabled to judge of the real thickness of the retina, and can readily determine whether this is abnormally increased or diminished. The slightest degrees of detachment of the retina are also easily recognised. The optic disc shows itself in its reality, and we can detect at a glance whether its surface is level, arched forward, or excavated. Whereas, with the monocular ophthalmoscope, slight changes in the level of the disc are often very difficult to determine with certainty, even by an accomplished ophthalmoscopist. Again, we can ascertain with facility the exact position of extravasations of blood, exudations of lymph, or collections of pigment, and whether they are situated in the retina or the choroid, or perhaps in both these tissues. These points in the differential diagnosis are often of much importance in framing the prognosis.

Various forms of *aut-ophthalmoscopes*, by which the surgeon could examine his own eye, have been devised, the first who succeeded in constructing such an instrument being Coccius, since then Heymann, Giraud-Teulon, and Zehender have invented different kinds of aut-ophthalmoscopes. The best and simplest of these is, I think, Giraud-Teulon's. Its action is explained by the accompanying diagram (Fig. 53), copied from Giraud-Teulon's article in the French translation of Mackenzie. The instrument consists of two plane mirrors, *m m'* inclined to one another, at an angle of 90°, and placed in front of the observer. A concave mirror (*c c'*) is held obliquely before the left eye (*g*), so that the rays from a flame (F) are reflected on to *m*, and thence on to *m'*, which will reflect them into the right eye (*d*). A double convex lens *l* is placed between *d* and *m'*, by which an inverted aerial image of A is formed, which is situated in reality at *a'* between the two mirrors, but which will appear

Fig. 53.

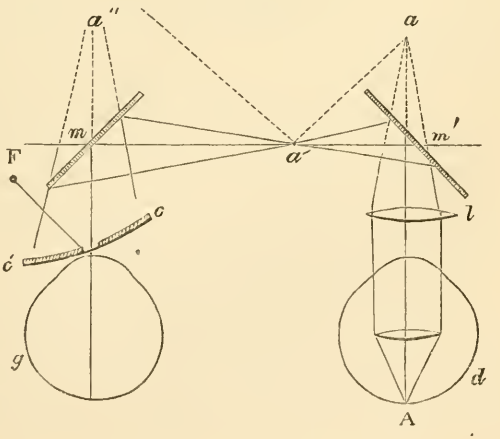

to g to be situated beyond the mirror m at a''. In fact the rays emanating from d, instead of passing straight on, are bent twice at a right angle, and brought back to g, without having undergone any change in their relative positions.

4.—THE EXAMINATION WITH THE OPHTHALMOSCOPE.

In the selection of a portable monocular ophthalmoscope, our choice for the examination of the inverted image lies, I think, between the instruments of Coccius and Liebreich. The latter, on account of its being somewhat easier to use, is the one most generally employed. But as certain difficulties in the use of the ophthalmoscope have always to be overcome by beginners, I think it just as well that they should commence at once with the best instrument, even although the difficulty of the examination be hereby somewhat enhanced. I have for many years used Coccius' instrument for the inverted image, in preference to any other, as it possesses certain decided advantages over the concave mirror. Thus, on account of the lateral collecting lens, we can alter the focal length of the mirror and the intensity of the illumination to any desired extent, and we can also more fully concentrate the pencil of light upon any given portion of the fundus which we wish to submit to special examination. The corneal reflex is also much less, and this is of great importance if the pupil is very small, as is frequently the case in elderly people, in whom, with the concave mirror, we can often obtain, on account of the great corneal reflex, but a very imperfect view of the fundus without artificial dilatation of the pupil.

Coccius' ophthalmoscope is also decidedly better than Liebreich's for the examination of the erect image, although it is for this purpose somewhat inferior to Zehender's. But to persons who desire to have only *one* ophthalmoscope, which shall serve them for all purposes, I should recommend that of Coccius as fulfilling this desideratum better than any other.

For conducting an ophthalmoscopic examination, a darkened room and a bright, steady-burning lamp are essentially necessary. In arranging a room for this purpose in a public institution, care must be taken that a bright stream of daylight does not enter directly in front of the patient, as this produces great reflection, weakens the illumination of the fundus, and renders the examination far more difficult, and needlessly trying to the eyes of the surgeon.

The best gas-lamp for ophthalmoscopic purposes is that employed at Moorfields, which has an Argand porcelain burner, perforated by a number of small apertures, and closed underneath by a very fine wire gauze, so as to regulate the draught, and thus steady the flame. The burner should not be too small, but should give a full round flame, as

this affords a much better illumination than if the flame is long and thin. It is attached to a bracket, which admits of a universal movement in all directions. In the consulting room a standard upright burner, connected with a gas pipe by means of an elastic tube, will be, however, perhaps more convenient. Or a good, bright-burning, moderator lamp may be employed. The lamp or burner is to be covered only by a chimney, and not a globe. In order to decrease the intensity of the light, and thus to diminish the contraction of the pupil, a blue chimney may be employed, or what is still better, a blue object lens, as suggested by Mr. Carter, which is made by cementing a plane, light blue glass (A tint) between two plano-convex lenses of the required power.

It is best for the beginner to have the pupil widely dilated by atropine, as this greatly facilitates the examination. But when he has acquired some dexterity in the use of the ophthalmoscope, he must learn to examine with an undilated pupil, for the use of atropine proves very inconvenient to the patients. It should, therefore, only be employed exceptionally, and when it is essentially necessary, as for instance when the pupil is very small, and the periphery of the fundus has to be examined for a suspected slight detachment of the retina, or morbid changes in the outlying portions of the choroid and retina. The examination in the region of the yellow spot is also very difficult, on account of the great reflection of the light, and the great contraction of the pupil when this part of the eye is illuminated. If atropine is used, only a very weak solution should be employed, otherwise the dilatation of the pupil will not only last some time, but there will also be much inconvenience from the paralysis of the accommodation, which will, perhaps, prevent the patient from using his eyes for reading and writing for several days. For the purpose of simply dilating the pupil for ophthalmoscoping, a drop of a solution of 1 grain of atropine to 10 or 12 ounces of water will suffice to produce the requisite degree of dilatation in about an hour, and it will continue from 12 to 30 hours. The atropinized gelatine discs will be found very convenient, as the patient can himself place one in the eye, before his visit to the surgeon.

5.—THE EXAMINATION OF THE ACTUAL INVERTED IMAGE.

The patient is to be seated on a chair, and the lamp should be placed beside, and somewhat behind him, at the side corresponding to the eye which is to be examined. The surgeon then seats himself directly opposite to the patient, and, holding the mirror in his right hand, places it close before his eye, so that its upper edge rests against the superior margin of the orbit. Then turning the mirror slightly

towards the lamp, he throws the reflection of the flame into the eye, the pupil of which will be brightly illuminated. This movement of the mirror must be very slight, and simply made by rotating the handle a very little between the fingers, otherwise the reflection will be thrown considerably above or to the side of the patient's head. The beginner always finds some difficulty in acquiring these slight movements of the mirror, as also the power of moving his own head in different directions, and yet keeping the eye constantly well illuminated. When the fundus is thoroughly lighted up, the rim of the bi-convex object lens is to be taken lightly between the forefinger and thumb of the left hand, and held about two inches from the eye under examination. The ring finger is to be placed against the upper edge of the orbit, in order to steady the hand, and this leaves the little finger free for lifting the upper lid if necessary. The object lens should be held at such a distance from the eye that its focal length coincides with the pupil. A 2-inch lens should, therefore, be held a little less than two inches from the cornea, and a 3-inch lens a little less than three inches. At first, some difficulty is always experienced in keeping the eye illuminated during the adjustment of the object lens, as the observer's attention is apt to be entirely directed to it, and he forgets all about the illumination. Indeed one of the chief difficulties that the beginner has to overcome, is that of learning to work both hands readily together.

When the fundus is well illuminated, we should first endeavour to gain a view of the optic disc, and the patient should therefore be directed to look at the ear of the observer which is on the opposite side to the eye under examination, so that the optic axis of the latter may be turned somewhat inwards. Thus if the right eye is to be examined, the patient should look towards the surgeon's right ear, and *vice versâ*. For as the entrance of the optic nerve is not situated in the optic axis (centre of the retina), but towards its nasal side, it is necessary that the patient should look inwards, in order that the disc may be brought directly opposite to the observer's eye. To gain this position, the patient may also be directed to look at the uplifted little finger of the hand holding the ophthalmoscope. In this case its handle may be held horizontally, and the left hand used for holding the mirror when the left eye is under examination. It is still more convenient to have a screen or board, divided into differently-numbered compartments, placed at some distance behind the surgeon. The patient is then directed to look at a certain figure upon the board, according to the part of the fundus which we desire to examine. The object should always be placed at some distance, in order that the patient's accommodation may be relaxed to the utmost. The entrance of the optic nerve is readily recognised by its presenting a whitish reflex, instead of the red glare reflected from the fundus. As soon as this white reflex is obtained, the object

lens should be adjusted, and we shall then have no difficulty in finding the optic nerve entrance, which appears in the form of a circular pinkish-white disc, on whose expanse are noticed numerous blood-vessels, which diverge from it to be distributed to different portions of the retina. If the disc is not in view, it may also be easily found by tracing some of the retinal vessels up to the point towards which they converge—*i. e.*, the optic nerve entrance. The disc having been found, the observer should very carefully study its colour, the appearance of its surface and margin, and the course of the blood-vessels upon it, in order that these different points may be well impressed upon his memory. In the next place, passing from the disc, the different portions of the fundus should be successively examined, and the appearance and mode of distribution of the retinal vessels, and the difference between them and those of the choroid be carefully studied. The beginner should always examine at first a considerable number of healthy eyes; to study very attentively the physiological appearances of the fundus, and the various peculiarities which may occur within normal limits. And then, when he has become thoroughly conversant with these diversities, he should pass on to the examination of the pathological conditions. The examination of the rabbit's eye, also affords excellent practice, and in the Albino rabbit the distribution of the choroidal and retinal vessels can be most beautifully seen. As the opportunity of examining a considerable number of human eyes is not always to be had, the following instrument, made by Nachet of Paris, will be found extremely useful for practising ophthalmoscopy, and for studying many of the morbid appearances of the fundus. It consists of an artificial eye, or dummy, made of brass, and fitted in front with a lens in the situation of the cornea. This lens is covered with a black metal cap, having a central aperture corresponding to the pupil. There are two of these caps, the one having a very small central opening corresponding to the normal size of the pupil; the other a large aperture, like a widely dilated pupil. By changing the lens, we may convert the eye into a hypermetropic, myopic, or astigmatic one. The posterior half of the eye opens, so as to admit of the insertion of a papier maché cup or disc, coloured to represent the appearance of a healthy fundus, or of some pathological condition, as for instance, retinitis pigmentosa, excavation of the optic nerve, posterior staphyloma, etc. In the box containing the instrument, there is a series of these coloured discs, illustrating many of the morbid ophthalmoscopic appearances of the fundus. The eye is fixed upon a standard for placing it upon a table.

I have already mentioned, that if we desire to increase the size of the image in the indirect mode of examination, we must employ a weaker object lens, *e.g.*, of 3 or 4 inches focus, which must be held

somewhat further from the eye. In order to magnify the image still more, Coccius* has devised a compound object lens which consists of two convex lenses (one of which has a focal length of 2, the other of $2\frac{1}{4}$ inches), inserted in the extremities of a brass tube, composed of two portions, each of which is $2\frac{1}{4}$ inches in length, and made to slide, one within the other. The effect of this is, that parallel rays reflected from an emmetropic eye will be united within the tube into an actual inverted image, the rays from which will then pass through the second lens, which will afford a magnified virtual image of the actual image within the tube. The disadvantages of this compound object lens are, that it is expensive, and very cumbersome, proving very fatiguing, if many patients have to be examined in succession. I find, moreover, that we may gain almost as great an enlargement, by using an ordinary object lens of four inches focus, and a convex lens of eight inches focus behind the mirror.

6.—THE EXAMINATION OF THE VIRTUAL ERECT IMAGE.

It has already been stated, that in this mode of examination the observer must go very close to the patient's eye. The lamp must therefore be placed on the side corresponding to the eye under examination, and the surgeon will find it most convenient to examine with his right eye the corresponding eye of the patient, and *vice versâ*. For the examination of the erect image the ophthalmoscope of Coccius or Zehender will be found preferable to that of Liebreich. Not only is the illumination better, and the corneal reflex considerably less, but it is also easier, on account of the lateral collecting lens, to maintain a good illumination of the eye, and to keep the optic axis of the observer's eye in a line corresponding to that of the patient, which is often difficult, if the mirror has to be considerably turned in order to catch the rays from the lamp. If the surgeon is not much accustomed to this mode of examination, and the pupil is small, the latter should be dilated with atropine, for this will increase the size of the field of vision, and facilitate the lighting up of the fundus. If the observer and the patient are both emmetropic, and their accommodation is suspended (*i.e.*, if they are accommodated for their far point, in this case for parallel rays) the surgeon will receive a clearly defined and distinct image of the details of the fundus. The beginner, however, generally finds considerable difficulty in completely relaxing his accommodation, more especially as his close approximation to the patient leads him involuntarily to accommodate for a point considerably nearer than his far point, *i.e.*, he is accommodated for more or less divergent

* Mr. R. Carter has given an excellent description of this apparatus and its mode of action in the "Lancet," March 18, 1865.

rays. This will render the image indistinct, and necessitate the use of a concave ocular lens, in order to give the requisite degree of divergence to the parallel rays emanating from the patient's eye. In certain conditions of the refraction either of the patient's or surgeon's eye, a concave ocular lens is absolutely necessary to render the image of the fundus distinct. Thus, if the patient's eye is emmetropic, but that of the surgeon myopic, the rays from the former will be parallel, and be consequently brought to a focus in front of his retina, and a concave lens will be required to give them the necessary degree of divergence. The strength of this lens should be such as to neutralize his myopia for distance. A still stronger concave lens will be required, if the eyes of the surgeon and patient are both myopic, for then the rays will impinge in a convergent direction upon the surgeon's eye. But if the surgeon is myopic, and the patient hypermetropic, the former may be able to see the fundus distinctly without the aid of a concave lens for the following reason:—the focus of the dioptric system of the eye under examination, will in this case lie behind the retina, and the eye will therefore be adjusted for more or less convergent rays. The emerging rays will consequently be divergent, and will be readily united upon the observer's retina, if his myopia is not too considerable in degree. The same would occur if the surgeon were hypermetropic or emmetropic, but then he would have to use his power of accommodation, in order to bring the divergent rays to a focus upon his retina. If on the other hand the observer is hypermetropic, he may also be able to examine a myopic or emmetropic eye (if the myopia is not too great) without the aid of a concave lens, for he will be able to unite convergent rays upon his retina, and also parallel rays by an effort of the accommodation. The cases containing the portable ophthalmoscopes are supplied with a series of concave ocular lenses, varying in focal length from 4 to 10 or 12 inches, and fitting into the clip behind the mirror. The surgeon should select the strength of the lens according to the state of the refraction of his own and the patient's eye.

The chief advantage of the erect image is, that we obtain a much larger image, so that the minute details of the fundus can be studied with much greater accuracy. This mode of examination is therefore of much importance in solving any doubts which may exist with the reverse image, as to the exact nature or situation of any morbid appearances. But the field of vision is more limited, and the examination somewhat more difficult. Moreover, it is not always convenient or agreeable to examine all patients in such close proximity. The latter may be one reason why this mode of examination is far too much neglected in England in favour of the inverted image. As a rule, it is best to obtain a general view of the appearances of the fundus in the

inverted image, and then, if we desire to examine any particular point with greater minuteness and accuracy, to have recourse to the direct method.

7.—THE OPHTHALMOSCOPIC APPEARANCES OF HEALTHY EYES (Plate I, Figs. 1, 2).

Before commencing any ophthalmoscopic examination of the fundus, the condition of the cornea, iris, pupil, and crystalline lens should be examined by the oblique illumination. This having been done, the same structures should be viewed by transmitted light, *i.e.*, the surgeon should examine the eye by the direct method (without the interposition of a convex lens between the mirror and the patient's eye), but the mirror should be held at some distance (14 or 18 inches) from the eye under examination. In this way no opacity of the refracting media can escape detection, which is not unfrequently the case if these modes of examination are neglected, and the fundus only examined with the inverted image. We can also in this way readily ascertain the state of refraction of the eye.

The examination of the refracting media in a healthy condition, of course affords a negative result. Sometimes small flakes of mucus may be noticed on the cornea, giving it a somewhat irregular appearance. They disappear on closure of the lids.

It has been already stated (p. 218) that certain physiological changes occur in the lens in advancing age, and we must be upon our guard not to mistake these for commencing cataract. The lens substance becomes thickened and consolidated, and the nucleus assumes a yellowish tint, which is especially apparent by reflected light. Indeed this opacity is sometimes so considerable, that it may be mistaken for a tolerably advanced cataract, but on examining the lens by transmitted light (with the mirror only) it will be found perfectly transparent, and the details of the fundus quite distinct.

On the other hand, the healthy appearances presented by the fundus oculi deserve and demand the closest and most attentive study, in order that the many diversities which they may present may not be mistaken for morbid phenomena. It is only by an intimate knowledge of the many physiological peculiarities which may exist in a perfectly normal eye, that we can avoid committing grave errors in diagnosis. Beginners are but too apt to hurry over the examination of healthy eyes with a careless, "Oh, there is nothing the matter; the fundus is quite healthy," craving only after the most marked pathological changes, such as large posterior staphylomata, very deep excavations of the optic nerve, and huge patches of atrophied choroid; and completely overlooking the minuter shades of difference between a healthy and morbid

condition of the fundus, a knowledge of which proves of the greatest importance in practice.

On looking at No. 1 of the ophthalmoscope plates, the reader will be at once struck by the marked difference in the appearances presented by Figs. 1 and 2, and yet both illustrate a perfectly healthy fundus.

In Fig. 1 (which is taken from a person with black hair and a dark brown iris) the optic nerve entrance appears circular, and of a yellowish white tint. The blood-vessels emerge somewhat to the left of the centre of the disc, which is here of a deeper white. The paler vessels are the retinal arteries, the darker ones the veins. They pass over the disc to the retina, where they course and divide in different directions, chiefly upwards, downwards, and towards the left. At some little distance to the right of, and slightly below the disc, is noticed a large dark red spot, with a small white dot in the centre. This is the macula lutea, or yellow spot, with its foramen centrale. It will be observed that the vessels course round the yellow spot, leaving it free. The fine grey film in the region of the disc and the yellow spot is due to the reflex yielded by the retina; it is only observable in dark eyes, and is consequently altogether absent in Fig. 2. The fundus of the eye is of a rich dark red tint, and only the retinal vessels are apparent, those of the choroid being hidden by the density of the pigment in the epithelial layer and stroma of the choroid.

In Fig. 2 (taken from the eye of a person with very light hair and a blue iris) the appearances are quite different. The disc is of a more rosy tint, the retinal vessels, although very distinct, are less markedly so than on the darker background of Fig. 1. The region of the yellow spot is of a bright red colour, and the foramen centrale appears in the form of a little light circle. But the greatest difference is noticed in the pale, brilliantly red colour of the fundus, and the distinctness with which the finest branches of the choroidal vessels can be traced. The ciliary arteries enter in the region of the yellow spot, and running towards the periphery ramify in various directions, and partly pass over directly into the larger branches of the vasa vorticosa, situated at the equator of the eye.

The red colour of the background of the eye, as seen with the ophthalmoscope, is due to the reflection of the light from the blood-vessels of the retina and choroid, more especially the latter. As the retina is very translucent, but little light is reflected by it, and the sclerotic can only be seen through the choroid, and will therefore be the more apparent the less pigment there is in the latter. The appearance presented by the fundus will, therefore, vary greatly according to the degree of pigmentation of the choroid. If its epithelial layer and stroma are darkly pigmented, the vessels of the choroid may be com-

pletely hidden, even at the periphery of the fundus. But if the epithelial layer contains but little pigment, and the stroma is, on the other hand, richly pigmented, the choroidal vessels will appear like bright red bands or ribbons, divided by dark islets or intervals, the so-called intravascular spaces. These vessels are chiefly situated in the stroma of the choroid, for they are less covered by the pigment than those of the venæ vorticosæ, which lie deeper (nearer the sclerotic), or the smaller vessels (Schweigger). The intravascular spaces are of a longitudinal shape near the equator of the eye, and more oval or circular in the vicinity of the disc. If the stroma is light, and the epithelium but moderately pigmented, the epithelial cells may be well seen with a considerable magnifying power, as has been shown by Liebreich, and may be recognised as small circumscribed dots uniformly studded over the fundus, giving it a markedly granular appearance. In eyes in which the pigmentation of the choroid is but very slight, the choroidal vessels may be most beautifully traced to their smallest divisions, as also the large stems of the venæ vorticosæ as they perforate the sclerotic. The red colour of the background is also influenced by age and the illumination. It is of a brighter tint in young persons than in older individuals. If the illumination is strong, the brightness will be uniform, if it is weaker, it will decrease from the disc towards the periphery of the fundus.

The retina is extremely translucent, and reflects but little light. On this account it is not visible in light eyes, but becomes so when the fundus is dark, appearing like a thin grey film or halo over the background. In very dark eyes, such as those of negroes, the retina is very distinctly apparent, showing a grey striated appearance, especially in the vicinity of the disc. The striæ are not, Schweigger thinks, due to the nerve fibres, but to the peculiar arrangement of the connective tissue.

8.—THE OPTIC DISC.

The normal disc is subject to numerous and sometimes marked differences in shape, colour, and size. An exact knowledge of all the peculiarities which come within the normal and physiological standard is absolutely necessary to prevent the surgeon from falling into errors in diagnosis, and mistaking some perfectly physiological appearances as being of pathological import.

The entrance of the optic nerve is generally round, but not perfectly circular; it is often oval, having the long diameter vertical. This oval appearance is particularly striking in cases of astigmatism. The disc is generally of a transparent, greyish-pink tint, with a slight admixture of blue. This tint varies in appearance with the pigmentation of the choroid; thus in dark eyes the disc appears white and glistening,

whereas in very light eyes it assumes a more rosy hue. The admixture of the colour of the optic nerve entrance is made up from three sources; the white is due to the reflection from the connective tissue of the lamina cribrosa, the red to the blood in the capillaries on its expanse, and the bluish-grey to the nerve tubules lying in the meshes of the cribriform tissue. The outline of the disc appears sharply defined, but on closer observation we notice that it may be divided into an internal grey ring, the real boundary of the nerve; outside this, is the white line of the sclerotic ring, which varies somewhat in size, being broadest and most apparent at the outer side of the disc. External to the scleral zone, is the dark grey line of the opening in the choroid. This choroidal ring is somewhat irregular in shape and colour, being most marked at the outer side, at which there is often a well defined deposit of pigment molecules, assuming the appearance of a broad black crescent, which is frequently mistaken by beginners for some pathological change.

The retinal vessels generally emerge from the central portion of the disc, or somewhat to the inner side of it. If the division of the central artery takes place after its passage through the lamina cribrosa, the division of the main trunk into the different branches can be distinctly observed. Whereas, if the division occurs before the passage of the trunk through the lamina cribrosa, the main branches pierce the disc in an isolated manner, so that their point of division from the trunk cannot be distinguished. The number, mode of division, and course of the retinal vessels vary very considerably, being constant only in this, that the principal branches run upwards and downwards. As a rule, no main branch runs inwards, but only a considerable number of smaller vessels; whereas towards the outer side only a few very small, short twigs are sent. The most frequent arrangement is that an artery and two veins pass upwards, and the same downwards; but sometimes there are two arteries and two veins. The arteries may be readily distinguished from the veins by being lighter in colour, smaller, and straighter in their course. Moreover, along the centre of the vessel is noticed a bright streak, so that the artery appears to have a double outline, this bright stripe being due to the reflection of light from the cylindrical wall of the vessel. The retinal veins are of a darker tint, larger, and more undulating than the arteries. On account of the greater tenuity of the walls of the veins, and of the blood-tension being less in them than in the arteries, they are somewhat flattened and not cylindrical in form. Hence the reflection of light is very slight, and the central bright streak hardly observable. The blood supply of the most anterior part of the optic nerve is maintained not only by the small twigs given off to it from the central vessels of the retina, but also by a series of branchlets emanating from a vascular circle, which is situated close to the edge of the optic nerve, and which is formed by three or four of

the short posterior ciliary arteries.* Leber, moreover, has found that numerous arteries and some veins also pass directly from the choroid to the optic nerve, anastomosing there with the network of vessels which surrounds the nerve fibres.

On closely regarding the surface of the disc, we notice that its colour varies at different points, and that it presents, moreover, towards the outer side, a somewhat mottled greyish-white appearance. This grey stippling is produced by the nerve tubules seen in section, and the white dots or lines between them are due to the trabeculæ of the sieve-like lamina cribrosa. At the point of exit of the retinal vessels the white appearance is very marked, and often presents a little pit or hollow. Whilst the outer portion of the disc presents a mottled greyish-white appearance, the inner half assumes a much redder tint. The reason of this is easily explained. As a greater number of the optic nerve fibres, after the entrance of the optic nerve into the eye, bend over to the inner side, the transparency of this portion of the nerve is much diminished by this close super-imposition of the fibres, and hence the details of the lamina cribrosa are hidden. Whereas, on the outer half the latter are still very evident, as the layer of nerve fibres is here much less considerable and more arched upwards and downwards, and the white reflection consequently much more marked. Inattention to these facts may lead the observer into considerable errors of diagnosis. He may consider the normal redness of the inner half of the disc as pathological, and assume the presence of hyperæmia, or even inflammation of this part of the nerve; or he may mistake the white appearance of the outer half for commencing atrophy.

We must now notice two peculiarities of the optic disc which are often met with in perfectly healthy eyes, viz., 1, spontaneous or easily producible pulsation of the retinal veins; 2, physiological excavation of the optic nerve.

The venous pulsation is characterised by an alternating increase and diminution in the calibre of the vein. The emptying of the vein commences at the centre of the optic disc, and extends to the periphery; the re-filling, on the other hand, begins at the periphery and extends towards the centre. The venous pulsation is generally only visible in the expanse of the disc, but in very rare cases it may even extend beyond its margin. It exists probably in all eyes, but does not generally appear spontaneously. The pulsation may, however, be made apparent, or rendered more marked and distinct, by slight pressure with the finger upon the eyeball, and we may thus alternately produce a complete emptying and re-filling of the vein. On a sudden relaxation of pressure which has been continued for a little time, the veins

* Vide Jäger, "Einstellung des dioptrischen Apparates," p. 55; also Leber, "A. f. O.," xi, 1, 5.

become rapidly over-filled and swollen, this dilatation lasts for about a minute, and then they resume their normal calibre. The respiration also somewhat affects the retinal circulation; thus, an increase in the size of the vein may be noticed during strong expiration, whereas a deep inspiration causes it to diminish. The vein and artery are in an opposite state of fulness, the arterial systole being synchronous with the venous diastole.

Whilst spontaneous pulsation of the retinal veins is a perfectly physiological phenomenon, this is not the case with the arterial pulsation, for this only exists when the intra-ocular tension is abnormally increased. It is, therefore, a symptom of great importance in the diagnosis of a glaucomatous condition of the eyeball. The presence of venous pulsation was supposed to indicate a fluctuation in the intra-ocular pressure, but according to Memorsky* this is not so. He considers it to be a visible expression of the action of the forces which regulate the blood-pressure within the eye.

The *physiological* excavation may be known by its being limited to the central portion of the disc, it is, moreover, generally very small and shallow, and may continue throughout life without undergoing any change. Sometimes the excavation is well marked and easily recognisable, the central portion of the disc presenting a peculiar white, glistening appearance, of varying size and form. This central, glistening spot may be oval, circular, or longitudinal, and its size is generally very inconsiderable in comparison with that of the disc; it is surrounded by a reddish zone, which may be almost of the same colour as the background of the eye. The width of this zone varies with the extent of the excavation; if the latter is small, the zone will be very considerable, but if it is large, the zone will be narrow, and limited to the periphery of the disc. The edges of the cup are generally slightly sloping, and never abrupt or steep, so that the excavation passes over gradually into the darker zone without there being any sharply-defined margin. But if the excavation is conical or funnel-shaped the edges are more abrupt, and the margin more defined. On tracing the retinal vessels from the periphery towards the centre of the disc, we notice that they undergo peculiar changes when they arrive at the margin of the excavation, for instead of passing straight on, they describe a more or less acute curve as they dip down into it. This curve may be very slight and gradual if the cup is shallow, but if it is deep and extensive the curve may be abrupt and give rise to a displacement of the vessels at its edge. In the expanse of the excavation, the vessels generally assume a slightly darker shade, but they sometimes appear of a lighter and more rosy tint, and seem to be enveloped by a delicate veil. The excavation is frequently not in the centre of the disc, but nearer its outer side. A

* "A. f. O.," xi, 2, 107.

very peculiar appearance is produced if a glaucomatous excavation occurs in a nerve having a physiological cup, for then the two conditions may for a time exist side by side; the physiological excavation is, however, subsequently merged in the deeper glaucomatous cup.

9.—THE OPHTHALMOSCOPIC EXAMINATION OF DISEASED EYES.

The Refracting Media.

Before commencing any ophthalmoscopic examination of the fundus, the refracting media should always be examined by the oblique illumination and by transmitted light (vide p. 304). By making this a constant rule the beginner will avoid falling into many an error in diagnosis which might otherwise occur, such as mistaking opacities of the cornea, the capsule, or the lens for some deeper-seated lesion. In making an examination of the lens or the vitreous humour the pupil should be widely dilated, although an expert observer will often be able, even with an undilated pupil, to detect opacities which are situated at the margin of the lens, or the periphery of the vitreous humour, by making the patient look very far in the opposite direction, which will enable the surgeon to look quite behind the iris. The colour of opacities in the refracting media will vary according to the amount of illumination, and the fact whether they are examined by reflected or transmitted light. In the former case, they will appear in their true colours, the fundus being in the shade, so that they will look like grey or whitish opacities situated upon a dark background. It is different, however, when the fundus is lighted up with the ophthalmoscope, for then the opacities will appear like dark specks, of varying size and form, upon a bright red background, for their surfaces can reflect but little light, and they are thus seen in shadow. On this account very small opacities are best seen by a weak illumination, for in consequence of their very slight reflection, they become invisible if the illumination is too bright. It is of much importance to be able rightly to estimate the depth at which any opacity in the refracting media is situated. There cannot be the slightest difficulty about this when the opacity is in the cornea, the capsule, or the anterior portion of the lens, for with the oblique illumination we shall be able to ascertain the position of the opacity in relation to the pupil. Indeed, for opacities in the anterior half of the eyeball the oblique illumination is of most service, but for those in the posterior half the ophthalmoscope should be used. But it is best to avail ourselves of both modes of examination. When the opacity is situated in the vitreous humour, it is more difficult to ascertain its exact depth. The two following methods of examination will,

however, enable us to decide this :—If, for instance, the observer (in the direct image) looks in such a direction that his optic line passes through the turning point of the patient's eye, it will be found that this point and the corneal reflection of the mirror will alone remain stationary when the eye is moved in different directions. Any opacity which is situated in front of this point will move in the same direction as the cornea, whereas any opacity situated behind the turning point will move in a direction opposite to that of the cornea. The further the opacity is from the turning point of the eye, the greater will its excursion be. Now the turning point corresponds as nearly as possible to the posterior pole of the crystalline lens. If there should consequently be an opacity situated at this spot (posterior polar cataract), it will remain stationary during the various movements of the eye. If the opacity is situated in front of the posterior pole it will move in the same direction as the cornea, if the latter moves upwards the opacity will do the same; the reverse will occur if the opacity is situated behind the turning point, for then it will move downwards as the cornea moves up, and *vice versâ*.

It is more difficult to determine the exact position of the object when it lies very close to the retina. This is best done by the surgeon making a slight movement with the object lens (in the examination with the reverse image), his own and the patient's eye being at the same time kept stationary. The nearer that the object is to the observer, the more marked will be its movement in the same direction as the lens. To illustrate this Liebreich* cites the following example :—If we suppose that a filiform opacity were to extend from the posterior pole of the lens to the centre of the retina, it would appear like a point when seen from in front. If we were then to move the convex lens from right to left, the anterior extremity of the opacity would pass to the corresponding side, in front of its posterior extremity, so that the opacity would no longer appear like a point, but a line. The depth of opacities in the vitreous is, however, best determined by the aid of the binocular ophthalmoscope.

Opacities of the cornea are best seen with the oblique illumination, and appear like small grey or white spots, and their situation and extent can thus be ascertained with the greatest nicety. This method of examination will also be found useful in the detection and removal of foreign bodies from the cornea. In the direct mode of examination with the ophthalmoscope, small opacities or facets in the cornea lend a peculiar mottled or marbled appearance to the fundus, as if little dark spots or streaks were studded over its red expanse. We may thus also readily detect changes in the curvature of the cornea, and diagnose the

* French Translation of Mackenzie's "Treatise on the Diseases of the Eye," p. 31.

earliest stage of conical cornea, for the conical portion yields a bright reflection, like a transparent bead or drop of water, with its base half in shadow, the situation of the latter varying with the movements of the mirror.

The appearances presented by different forms of cataract, etc., both by reflected and transmitted light, have already been described at length in the chapter upon the diseases of the lens.

Chapter VII.

DISEASES OF THE VITREOUS HUMOUR.

1.—INFLAMMATION OF THE VITREOUS HUMOUR.—HYALITIS.

It was formerly supposed that the vitreous humour was incapable of undergoing inflammation, on account of the absence of nerves and blood-vessels in its structure. Thanks, however, to the researches of Virchow and Weber, it has been proved beyond doubt that the vitreous humour can become inflamed. Although these inflammatory changes generally either accompany or supervene upon inflammation of the deeper tunics of the eyeball, viz., the retina and choroid, yet idiopathic hyalitis may occur, and it may be quite impossible to trace any participation of the other tunics of the eye.

These inflammatory changes consist chiefly in a proliferation or hyperplasia of the cells of the vitreous humour, which become opaque and granular, and undergo, perhaps, fatty degeneration. Sometimes, there is a considerable development of connective tissue elements, or there may be a great tendency to suppuration, and large quantities of pus cells be formed.

The progress of hyalitis is best studied by watching what changes occur when a foreign body (*e.g.*, a piece of gun cap, steel, etc., or a displaced lens) is lodged in the vitreous humour. If the refracting media are sufficiently clear to permit of an ophthalmoscopic examination, we find that soon after the accident, the vitreous humour in the vicinity of the foreign body loses its transparency, and becomes somewhat hazy, which is due to the proliferation of the vitreous cells, and an increase of their nuclei and molecular contents. The foreign body appears to be enveloped in a thin mist or cloud of a bluish-grey tint, which assumes a more dense and firm appearance if much connective tissue is developed, and a creamy yellow colour if suppuration sets in. The track of the foreign body is often visible in the form of a thin whitish-grey opacity, like a thread, running towards it. We sometimes find that these inflammatory changes in the vitreous humour, consequent upon the lodgement of a foreign body within it, are idiopathic, no trace of inflam-

mation of the other structures of the eye being visible, either externally or with the ophthalmoscope. Generally, however, this is not the case, for symptoms of irido-cyclitis or choroiditis soon supervene, and the eye is but too frequently lost through suppuration.

The simple (non-suppurative) form of hyalitis may be either acute or chronic, and the opacity of the vitreous be either diffuse or circumscribed. On ophthalmoscopic examination, we may find the whole vitreous humour diffusely clouded, which renders the details of the fundus either completely invisible, or very indistinct, so that they appear to be covered by a thin grey film or veil. In this diffuse opacity may be noticed dark, thread-like films, of varying size and shape, which may be either fixed, or float about when the eye is quickly moved. Neoplastic formations of connective tissue are often met with at the anterior portion of the vitreous humour, close to the posterior pole of the lens. They give rise to a more or less extensive opacity, which is sometimes termed posterior polar cataract. But connective tissue is also formed in other portions of the vitreous humour, often in very considerable quantities, giving rise to membranous and filamentous opacities, which, traversing the vitreous in different directions, may perhaps even divide it into fibrillar compartments. The true cellular gelatinous substance of the vitreous humour disappears in proportion to the development of the connective tissue, and generally becomes fluid (synchysis). In such cases the retina is often found to be extensively detached, and the vitreous humour shrivelled up to a very small space; and chiefly consisting of connective tissue, of an almost tendinous structure, interspersed with loculi containing cells which have undergone various changes, and not unfrequently pigment molecules.

Although simple hyalitis sometimes occurs idiopathically, yet generally it is dependent upon an inflammation of the retina, choroid, or ciliary body.

Still more so is this the case in the suppurative form of hyalitis, which is but seldom idiopathic, being mostly associated with purulent irido-cyclitis or irido-choroiditis, which supervenes perhaps upon operations for cataract, injuries, etc. As the cornea is but too frequently opaque, or the pupil blocked up with lymph, it is often impossible to trace the course of the disease with the ophthalmoscope. If we are, however, able to do so, we sometimes find that the anterior portion of the vitreous humour, close to the lens, yields a yellow, creamy reflex, which may be very well seen with the oblique illumination. It is called posterior hypopyon, and is due to pus in the anterior portion of the vitreous, which may have made its way from the ciliary body or anterior segment of choroid, having burst through the retina. In such a case, the other portions of the vitreous may be found comparatively, or even completely healthy. In other instances, the suppura-

tion occurs at the posterior or lateral portions of the vitreous, to which it may remain chiefly confined, but it may also become general, and involve the whole of the vitreous humour. Ophthalmitis generally ensues, and the globe gradually becomes atrophied with or without previous perforation of the cornea or sclerotic.

The prognosis of inflammation of the vitreous humour will depend chiefly upon the cause, and the extent to which the deeper tissues of the eye are implicated. I must therefore refer the reader for a consideration of these points, as well as the question of treatment, to the diseases of the choroid and retina. With regard to the treatment, I may, however, state that in the acute cases of diffuse hyalitis, much benefit is often experienced from salivation, and the periodic application of the artificial leech to the temple.

2.—OPACITIES OF THE VITREOUS HUMOUR.

The presence of opacities in the vitreous humour is easily detected with the ophthalmoscope in the direct mode of examination. The patient should be ordered to move his eye quickly and repeatedly in various directions, and then to hold it still. These movements will cause the opacities to be shaken up, and they will float about in the field of vision, and we shall thus be enabled to judge of their size and density, and to distinguish between the fixed and moveable ones. When the eye is held still, the latter soon sink again to the lower portion of the vitreous. The excursions which these opacities make are often very considerable, and allow us to estimate approximately the degree of fluidity of the vitreous. The binocular ophthalmoscope is particularly useful in the examination of vitreous opacities, and in determining the different depths at which they are situated.

We have seen that in simple hyalitis the opacity of the vitreous assumes a diffuse grey appearance, shrouding the whole fundus in a fine veil, the sight being at the same time greatly affected. Sometimes the opacity is chiefly confined to one portion, perhaps the central, in which case the yellow spot and the retina in its vicinity will appear hazy, whilst the details at the periphery of the fundus can be clearly seen. This partial, uniform opacity may shift somewhat when the eye is moved. A peculiarly dangerous form of diffuse opacity of the vitreous is that which occurs suddenly, and after clearing somewhat, recurs perhaps several times, for it is but too often followed by detachment of the retina. We must not, however, confound with this, the temporary cloudiness of the vitreous which occurs in glaucoma, and which is due to a serous hypersecretion, evidently dependent upon irritation of the ciliary nerves.

Together with a more or less diffuse opacity, we often meet with various circular, membranous, or filiform opacities, which are due to the remains of blood effusions, or alterations in the cells of the vitreous humour, which may have undergone fatty, purulent, or pigmentary changes; or connective tissue elements may have been formed. These opacities assume very various shapes and forms. At first, perhaps, the patient only notices a dark speck before his eyes, which he cannot wipe away; then thin, flaky membranes may appear, which float about and assume different forms and positions with every movement of the eye. Between these opacities, the field of vision may either appear clear or be more or less diffusely clouded. The nearer the opacities are to the retina the more will they throw a shadow upon it. If they are some distance from it, they may not throw individual shadows, but only give rise to a general dimness of vision. The patients, as Von Graefe has pointed out, often throw their eyes periodically upwards in reading, etc., in order to cause the opacities to move and shift their position, so that the field of vision may be momentarily cleared, which of course enables them to see more distinctly. This periodic upward movement of the eye is accompanied by an elevation of the upper lid, and gives a peculiar and characteristic appearance to the patient.

With the ophthalmoscope, we can readily distinguish these opacities as dark, fixed, or floating bodies, assuming various shapes, like dark spots, threads, or reticulated fibrillæ; sometimes, however, they are so delicately fine that we cannot individualize them, and the whole fundus only appears to be hazy and veiled.

The disease in which opacities of the vitreous are by far most frequently met with is sclerotico-choroiditis posterior. The posterior portion of the vitreous frequently becomes fluid, and the opacities may be seen floating very freely about in it. Sometimes, however, the synchysis extends to the greater portion or even the whole of the vitreous humour.

Extravasation of blood into the vitreous humour is a very frequent cause of these opacities. The hæmorrhage is generally due to a rupture of some of the vessels of the choroid, more especially at its anterior portion, where it is most vascular, and at which situation the retina is thinnest, and therefore most readily gives way; whereas, when the effusion takes place in the posterior portion of the choroid, it is more prone to cause detachment of the retina than to perforate the latter and make its way into the vitreous. This is due to the fact that the connection between the choroid and retina is at this point very lax, and the retina thicker than in the region of the ora serrata. Hence a more or less considerable detachment of the retina is generally produced at the posterior portion of the fundus, before perforation takes place. When the blood has become absorbed, and the vitreous is again transparent,

we can always discover changes in the choroid, such as ecchymoses, etc., showing whence the hæmorrhage has proceeded, and we are also sometimes able to detect a cicatrix in the retina, where the latter has been ruptured by the extravasation of blood. Schweigger* has pointed out that hæmorrhage into the vitreous humour occurs far more frequently from the choroidal vessels than from those of the retina, for the latter are not only smaller in size, but, on account of the peculiar arrangement of the connective tissue fibrillæ (Stützfasern) of the retina, and the resistance offered by the membrana limitans interna, hæmorrhage from the retina extends generally towards the choroid, and not into the vitreous.

We are generally able, with the ophthalmoscope, easily to distinguish extravasations of blood into the vitreous, as they yield a peculiar bright red reflex. But if the hæmorrhage is very extensive and diffuse, it may not be possible to light up the eye at all, the fundus looking quite dark, and not affording the least reflex. The sight is generally very greatly and very suddenly impaired, the patient having the sensation as if there was a dense red mist or veil before his eye. When the blood is beginning to be absorbed, fixed and floating opacities of a filiform, reticulated, or membranous character make their appearance, and become rolled up into dark fantastically-shaped masses when the eye is moved. Sometimes when the absorption has gone on for some time, and the vitreous has regained much of its transparency, a fresh extravasation takes place, and this may recur several times. Although the patient may regain a considerable amount of sight during these intervals, the recurrence of hæmorrhage is always to be regarded with great anxiety, as it but too frequently leads to detachment of the retina, glaucomatous complications, or atrophy of the eyeball.

When the hæmorrhage has been at all considerable, permanent opacities are generally left behind, and may produce great impairment of vision, and even detachment of the retina by traction. H. Müller† was the first to show that the latter is a not unfrequent consequence of opacities in the vitreous.

Extravasations of blood into the vitreous humour are very often of traumatic origin, being produced, for instance, by severe blows upon the eye, causing a rupture of the blood-vessels of the choroid or retina. They may, however, arise independently of this, if there is much congestion of the internal tunics of the eyeball, or if the coats of the vessels are diseased.

In the treatment of opacities of the vitreous humour, we must be especially guided by the cause, and whether they are due to, and a part symptom of, inflammatory affections of the deeper tunics of the eye-

* "Archiv. für Ophthalmologie," vi, 2, 259.

† Ibid., iv, 1, 372.

ball, or, perhaps, to intra-ocular hæmorrhages caused by rupture of some of the choroidal vessels. In the former case, our attention must be chiefly directed to the treatment of the primary disease. The absorption of the vitreous opacities may, however, be greatly aided by preventing all congestion of the choroidal or retinal vessels by the application of the artificial leech. I have often gained great benefit from its use, as it facilitates and hastens the absorption, and relieves the intra-ocular blood-vessels. If the patient is weak and anæmic, I generally prefer dry cupping at the temple, making use only of the glass cylinder of the Heurteloup. This may be repeated once or twice a week, according to circumstances. But if the patient is strong and plethoric, I invariably take away blood by means of the artificial leech, one cylinder full being the usual quantity. In those cases in which the affection of the vitreous is dependent upon derangement of the functions of the uterus or liver, the general health must be strictly attended to. Much benefit is experienced from the use of saline mineral waters, as the Pulna, Kissingen, Kreuznach, etc., and the tendency to congestion and hyperæmia of the vessels of the eye should be relieved by hot pediluvia or hip-baths. The absorption of blood into the vitreous may also be hastened by the application of a firm compress bandage. In cases of dense membranous opacities of the vitreous which had resisted all efforts of absorption, Von Graefe has derived much benefit from tearing them through with a fine needle.* This produces not only an improvement in the sight, but renders the opacities more amenable to treatment, and prevents their exercising any deleterious influence upon the retina by traction.

It is of much practical importance to distinguish between the pathological opacities of the vitreous humour and the subjective physiological muscæ volitantes (*Myodesopia*) which are met with in perfectly healthy eyes. These assume the most various shapes and appearances. Sometimes they look like small transparent discs or circles, which may be isolated or arranged in groups; or they may resemble strings of bright beads, or filamentous bands, which float about in all directions through the field of vision. They are generally due to minute beaded filaments or groups of granules in the vitreous humour, and are quite physiological, occurring more or less in all eyes. They are so minute that they are perfectly invisible with the ophthalmoscope, and this instrument is therefore of the greatest use in enabling us to distinguish between the physiological and pathological *muscæ volitantes*, for directly it reveals to us the presence of opacities in the vitreous, however slight they may be, we must regard them as pathological products. I must, however, mention in passing, that certain changes in the choroid and

* "A. f. O.," ix, 2, 101.

retina may give rise to fixed dark spots in the visual field (so-called "scotomata"). No careful observer could, however, confound these with the opacities in question.

Muscæ become very evident when the person regards some light and highly illuminated object, as, for instance, the bright clear sky, a very white wall, or the brightly illuminated field of the microscope, whereas, in a subdued light the floating bodies may be hardly, if at all observable. They are also increased by fatigue of the eye from overwork, or when the retina is very sensitive and irritable; the same often occurs if there is any derangement of the nervous system or of the digestive organs. The situation of the muscæ may be approximately ascertained, as was shown by Listing, by making the patient look through one of the minute apertures of the stenopaic apparatus, or a pin-hole in a card. Now, if the card is moved in a certain direction (*e.g.*, upwards), and the objects also move upwards, they are situated behind the pupil, whereas, if they move in the opposite direction, they lie in front of the pupil. The greater the degree of movement, the further does the object lie from the pupil.* The position of the objects can be estimated with still greater accuracy by Donders's mode of examination *à double vue*. He employs a diaphragm pierced by two small apertures, situated about one line from each other, so that two shadows are thrown upon the retina, and cover one another by nearly one half.† We must distinguish the muscæ which have their seat in the vitreous humour from the appearances produced by eyelashes, mucolachrymal drops on the conjunctiva and cornea, and the radii and spots situated in the lens. For full information upon this interesting subject of Entoptics, I would refer the reader to Dr. Jago's admirable and exhaustive treatise.‡

Short-sighted persons are especially troubled by muscæ, for even the physiological motes are rendered peculiarly marked and distinct by the size of the circles of diffusion upon the retina. In consequence of this, they often prove a source of the greatest anxiety and trouble to the patient. Already, perhaps, in constant dread that his myopia should rapidly increase, and lead eventually to great impairment of vision, or even total blindness, the appearance of these muscæ often frightens him greatly, and causes him to yield undivided attention to his eye sight, and to watch every symptom with anxiety. This is more particularly the case with those persons who are dependent upon their sight for their livelihood, or are naturally of a nervous and anxious temperament. Even although we may earnestly and repeatedly assure them that these

* Helmholtz Physiologische Optik., 150.

† Donders's "Anomalies of Accommodation and Refraction," 201.

‡ "Entoptics, with its use in Physiology and Medicine," by James Jago, M.D 1864 (Churchill).

physiological motes are not of the slightest importance, and are a source of no danger, we but too frequently fail to alleviate their mental distress. They seek advice from others who, in their opinion, are more competent, and willing to understand the nature of their complaint. Amongst such patients the charlatan finds his most fervid and profitable followers. I have met with several most distressing cases in which advertising quacks have greatly frightened patients who complained of these motes, assuring them that they depended upon some secret disorder, and if not speedily and properly treated, that they would lead to amaurosis, of which, indeed, they were the sure precursory symptoms. Such patients must be cheered up, and prevented as much as possible from thinking of their ailments. Their general health must be strengthened, and any irregularities of the circulation or digestive organs removed. Much benefit is often also produced by the use of dark blue or neutral tint eye-protectors, as they diminish the intensity of the light, and thus render the muscæ less visible.

It has been already mentioned, in speaking of the opacities in the vitreous humour, that the latter may lose its normal gelatinous consistence, and become partially or wholly fluid. This condition, which is termed *synchysis*, cannot be diagnosed with certainty if there are no floating opacities. An erroneous opinion sometimes prevails, that the eye is always soft in all cases of fluid vitreous. But this is not the case, for the tension of the eyeball varies according to the amount of the vitreous humour, and not according to the nature of its consistence. Thus in glaucoma, the tension of the eyeball may be very greatly increased, owing to the hyper-secretion of the vitreous humour, which may be perfectly fluid. Again, diminution of the intra-ocular tension only proves that the contents of the vitreous are diminished in quantity, although it must be allowed that in such cases the vitreous is often fluid. Tremulousness of the iris is also an uncertain symptom. It can exist only when the iris has lost its natural support from the crystalline lens, either through absence of the latter, or through its having become displaced. Together with fluidity of the vitreous, the diameter of the eyeball may have become increased, and the position of the lens with regard to the iris somewhat altered, and, therefore, on account of this loss of support, the iris may be tremulous. But the most reliable symptom is the presence of floating opacities. In staphylomatous enlargements of the eyeball, the vitreous is always found more or less fluid. The same occurs if a foreign body or a displaced lens has become lodged in the vitreous. Moreover, when vitreous humour is lost, as for instance during an operation for cataract, or owing to a wound of the eye, this loss is always made up by fluid. It is of importance to be aware, if possible, of the consistence of the vitreous humour before undertaking an operation for cataract, in order that we

may take every precaution to limit as much as possible the loss of vitreous which must inevitably occur.

A most beautiful and striking appearance is presented by the presence of crystals of cholesterine in the vitreous. As this condition generally, if not indeed always, occurs in a fluid state of the vitreous, it has been termed sparkling synchysis (synchysis étincelant). The exact mode of origin of these crystals is not at present known, but it seems that they often occur after hæmorrhage into the vitreous, and are therefore very probably deposited from the blood; or they may be due to fatty changes in the vitreous humour. The appearance presented by cholesterine in the vitreous is most characteristic and striking, if the ophthalmoscope is used. On every movement of the eye a shower of bright, sparkling crystals is seen floating through the field of vision, which gradually sink down to its lower part when the eye is again held still. Sometimes the crystals float about in an otherwise clear vitreous, or they may be intermixed with darker filamentous opacities, to which they may even adhere, fringing them with a sparkling lustrous border. They have also been met with in the retina, and even between the retina and choroid. When they are situated at the anterior portion of the vitreous, close behind the lens, they may be noticed even with the oblique illumination. Von Graefe mentions a case in which they gradually disappeared.

3.—FOREIGN BODIES, ETC., IN THE VITREOUS HUMOUR.

If a foreign body becomes lodged in the vitreous humour, it but too frequently excites the most severe and destructive inflammation of the tissues through which it has passed, or with which it lies in contact. Thus if it has entered through the cornea, this and the iris often become violently inflamed; the lens, through which the foreign body has also passed, becomes cataractous and swells up, thus tending to increase still more the severity of the inflammation. If the injury has been severe and the foreign body lies in the vitreous humour close to the retina, it often excites inflammation, perhaps of a suppurative character, in this and the choroid, which leads perhaps to atrophy of the globe. If the media remain sufficiently clear to permit of an ophthalmoscopic examination of the fundus, we generally find that for the first few days the foreign body may be seen of its natural colour, mostly sunk down in the vitreous humour. Then, the latter becomes somewhat clouded in the vicinity of the foreign body, surrounding it with a thin, greyish-blue halo, which, as the plastic nature of the exudation increases, assumes a denser and more opaque yellowish-white appearance, hiding the foreign body from view. It has in fact become encysted. At the same time

the vitreous humour is often more or less diffusely clouded, and dark, filamentous opacities float about in it. When it regains sufficient transparency to permit of an ophthalmoscopic examination of the fundus, we not unfrequently find that a detachment of the retina has occurred (perhaps to a considerable extent), and that a more or less extensive inflammation of the choroid has taken place. In some rare instances, however, the course may be more favourable; so that although the injury may be followed by severe inflammation, the foreign body becomes encysted in the vitreous humour, which gradually regains its transparency as the inflammatory symptoms subside, and finally the sight may be restored to its normal condition, the foreign body lying innocuous in the vitreous humour. Such instances are, however, very rare, and can only occur when the foreign body is but small. The following is a brief outline of such a case, which came under my care at the Middlesex Hospital in 1862.*

"Samuel P——, aged 20, was wounded in the left eye by a chip of iron flying off a hammer. This was followed by severe inflammatory symptoms, great swelling of the lids, lachrymation, photophobia, iritis. At the outer and upper side of the iris, quite close to the periphery, there was a small triangular opening, showing the passage of the foreign body, and, corresponding to it, there was a small cicatrix in the cornea. On his admission into the hospital (about a week after the accident) he could only count fingers up to a distance of 7 or 8 feet. The tension of the eye was then, and remained throughout, normal. When the inflammatory symptoms had greatly subsided, a short ophthalmoscopic examination was made, and it was found that the vitreous humour was clouded, with a few filamentous opacities floating about in it. The condition of the eye was soon so much improved that the patient could read No. 1 of Jäger, and No. 19 at 18 feet; the lens was clear, the vitreous slightly hazy, yet permitting the optic disc to be seen distinctly. At the outer and lower portion of the vitreous was seen a white, opalescent, oval mass, the encysted foreign body, whose passage through the vitreous could be traced by a faint bluish line running towards it. A local, circumscribed inflammation in the choroid had occurred in its vicinity, and small portions of choroidal pigment were agglomerated around and beneath the foreign body. I saw the patient occasionally for some years after the accident; the last time was about two years ago (in 1865), and the eye was then in precisely the same condition, and he could use it perfectly."

I must mention, however, that even after a foreign body has lain encysted and dormant for many years in the vitreous humour, it may give rise to severe inflammatory symptoms which may lead to atrophy of the globe, or awaken sympathetic ophthalmia.

* Vide "Lancet," Aug. 23, 1862.

The treatment must be chiefly directed to subduing the inflammation. Cold compresses should be applied to the eye, and perhaps leeches to the temple. The pupil must be kept widely dilated by atropine. If suppurative iritis or irido-cyclitis is set up, it may be necessary to put the patient rapidly under the influence of mercury. Or, if there is a considerable hypopyon, repeated paracentesis, or a large iridectomy may be indicated. The latter should never be neglected if the tension of the eye is increased.

With regard to removal of the cataractous lens, or of the eyeball, from its setting up sympathetic irritation or inflammation, I must refer the reader to the chapters upon "Traumatic Cataract" and "Sympathetic Ophthalmia." The question may arise as to the advisability of removing a foreign body in the vitreous humour, and we must be principally guided in deciding this by its position and nature. Interesting cases of this kind have been reported by Dixon (R. L. O. H. Rep., No. 6) and Critchett (Lancet, 1854).

Although *cysticerci* have been met with in various parts of the eye, as the cornea, anterior chamber, iris, and lens, as well as in the orbit, their most frequent seat appears to be in the background of the eye. Thus Von Graefe* states that amongst 80,000 patients he has found a cysticercus in the deeper tissues of the eye in rather more than 80 cases, in the anterior chamber three times, beneath the conjunctiva five times, in the lens once, and in the orbit once. The youngest individual was nine years old; about 90 per cent. of the cases occurred between the ages of 15 and 55, and nearly two-thirds of the cases were met with in men. In England the disease would seem to be very rare. I have only met with one case of cysticercus in the vitreous diagnosed with the ophthalmoscope, which occurred in a soldier who was sent to me for examination by Professor Longmore. If the membrane which envelopes the cysticercus in the vitreous humour is not too dense, the entozoon presents a very peculiar and characteristic appearance. Its original seat appears generally to be beneath the retina, and it is only at a later stage of its existence that it perforates the latter (with its head first) and makes its way into the vitreous humour. Sometimes it carries the retina with it, and thus produces an extensive detachment, by which it is covered. In other cases, it tears through the retina and lies free in the vitreous humour. Here it frequently becomes encysted, being surrounded by a more or less dense membrane, which may prevent the recognition of the real nature of the affection. If this is not the case, but the entozoon is without an investing membrane, it presents the appearance of a pale greyish-blue, or greenish-blue vesicle, somewhat circular or flask-shaped, with a short neck and round head,

* "A. f. O.," xii, 2, 174.

on which the suckers may be seen. If the animal is alive, we may by closely watching it, observe distinct undulating, tremulous movements of its outline, the head being perhaps alternately stretched out from, or drawn into the receptaculum. The position of the latter, in which the head and neck lie when they are retracted, is indicated by a small white spot at one point of the vesicle. The slightest movement of the head causes a gentle quivering motion of the vesicle, and on bright illumination of its surface we notice, especially near the margin, a peculiar bright iridescence, the play of colours constantly changing, but having a decidedly red tint. All these minutiæ are more easily distinguished when the cysticercus lies free in the vitreous humour, than when it is covered by the retina. If, in the latter case, its movements are very marked and considerable, the super-jacent retina may also undergo a distinct tremulous motion. Von Graefe has been able in four cases to watch the development of the entozoon from the very commencement. At the outset, there appeared a delicate greyish-blue opacity at some portion of the fundus, situated evidently in the retina or between the latter and the choroid. In the course of three or four weeks, the little cysticercus vesicle escaped, in two cases, from the most prominent portion of the opacity into the vitreous humour. In the two other cases, the outline of the vesicle became gradually more and more apparent from beneath the opacity, and was distinctly situated beneath the retina, the latter lying either in tense and close apposition to the entozoon, or being separated by an effusion of subretinal fluid, in which case there exists a greater mobility of the vesicle. The latter gradually glides along further and further beneath the retina, until at last, after perhaps several months have elapsed, it breaks through into the vitreous humour. The original position of the cysticercus beneath the retina is indicated by the faintly recognisable remains of a small greyish-white spot, from which can be traced a distinct greyish track, if the animal has made its way for some distance beneath the retina before perforation. Although opacities of the vitreous may appear at the commencement, this is not the rule, but at a later period the vitreous generally becomes clouded, and the eye is finally lost from slow and insidious choroiditis. Generally this occurs within two years of the outset of the disease.

The presence of a cysticercus being so extremely dangerous to the eye, Von Graefe* was led to attempt its extraction. By so doing, it may be possible to retain a certain degree of vision, to preserve the shape of the eyeball, or at the worst, to diminish the pain and protracted course of the atrophy of the eyeball. In Von Graefe's first case, he made a large iridectomy downwards and inwards, so as thoroughly to expose the exact position of the entozoon. Subsequently he passed

* "A. f. O.," iii, 2, 320.

a couching needle through the sclerotic, about one and a-half or two lines further back than the point where the needle would be inserted for the operation of couching. Through this opening he then passed the point of the closed canula forceps, and pushed it forward until it became visible between the posterior surface of the lens and the vesicle, along which he pushed it, until the instrument had reached the neck of the entozoon, the branches were then opened, the neck seized, and the animal slowly drawn towards the incision. When the latter had, however, been reached, the animal escaped, and the forceps had to be again passed in, when the entozoon was successfully extracted; the vesicle was, however, torn. The irritation produced by the operation caused, however, an increase in the vitreous opacities, and some months later the lens became clouded. In another case,* upon which Von Graefe operated, he endeavoured to extract the parasite without rupture of the vesicle. A large iridectomy was made downwards and outwards, opposite the cysticercus, and followed, a month later, by extraction of the transparent lens by the lower flap operation, a further portion of the iris being at the same time excised. Six weeks later, the cysticercus was extracted through a linear incision in the cornea. The operation was followed by an increase in the vitreous opacities, but these were subsequently almost entirely absorbed.

In Plate V, fig. 9, will be found an excellent illustration of the appearances presented by a cysticercus in the vitreous. Liebreich says, in explanation of this plate, "The parasite, which was originally developed beneath the retina, and then, after perforating it, penetrated into the vitreous humour, could be seen with such perfect distinctness, that the undulating movements and coarctations of the vesicle could not only be observed at its outline, but also at the posterior wall, which could be distinguished through the anterior wall. This was especially the case towards the centre, where, as the red tint in the illustration shows, more light can shine through than at the margin, on which the light falls more obliquely, and consequently suffers greater reflection. The neck, especially at its junction with the vesicle, is of an opaquer tint, and studded with minute white dots (chalky particles). This more opaque portion, where the neck joins the vesicle, is also the most firm, and we must endeavour to seize it here, if we wish to extract the animal. In a case upon which I operated last winter, I succeeded in seizing it at this point with the canula forceps, introduced through the sclerotic. By means of an ophthalmoscope, which was fixed to the forehead, I illuminated the animal and the instrument, so that I could see them accurately. In the illustration we recognise at the head two suckers (the other two being placed posteriorly), and the buccal extremity which is directed upwards. The shape of the head did not always

* "A. f. O.," iv, 2, 171.

present the appearance depicted in the illustration, but varied in a very remarkable manner."

In rare instances, the formation of new blood-vessels in the vitreous may be observed with the ophthalmoscope. Thus Becker* saw new vessels formed upon the anterior surface of an abscess in the vitreous humour, and again in purulent infiltration of the vitreous; in the latter case, the vessels were situated close behind the lens, and were distinguishable with the naked eye. Becker,† moreover, narrates an extraordinary case of an independent neo-plastic formation, in which the connection between the newly-formed vessels of the growth and those of the retina could be distinctly traced.

4.—PERSISTENT HYALOID ARTERY.

The hyaloid artery generally shrivels up and disappears during the later period of fœtal life. In some rare instances, however, remains of it in the vitreous humour have been subsequently traced with the ophthalmoscope, either in the form of a short, dark stripe, or of a dark thread running through the vitreous humour from the optic disc towards the posterior portion of the lens. If the vessel is still patent and carries blood, as was noticed by Zehender,‡ it appears like a red cord by incident light; which in this case underwent considerable undulations when the eye was moved, the vitreous humour being evidently fluid. Liebreich§ records a case in which there existed a physiological cup of the optic nerve together with the persistent hyaloid artery, and the latter could be distinctly traced up to its point of origin from the central artery of the retina.

* "Bericht über die Wiener Augenklinik," 114.
† Ibid., 106.
‡ "Kl. Monatsbl.," 1863, 259.
§ Ibid., 349.

Chapter VIII.

DISEASES OF THE RETINA.

1.—HYPERÆMIA OF THE RETINA.

We may distinguish two forms of hyperæmia of the retina, viz.: the arterial or active, and the venous or passive. The former is generally acute, and is characterised by the patient experiencing some symptoms of irritability in the eye, such as photophobia, lachrymation, subconjunctival redness, and an inability to continue for any length of time any work which necessitates a strong effort of the accommodation. There are often also subjective symptoms of an irritable state of the retina, such as flashes of light, etc. On examining the eye with the ophthalmoscope, we find that the optic disc is abnormally red and flushed, on account of the increased injection of the capillary twigs upon its surface. If this increased vascularity is very pronounced at the margin of the disc, its outline becomes somewhat ill-defined from its similarity in tint to the surrounding fundus. The size of the arteries may be slightly increased, and the smaller branches are more numerous and apparent, which is especially observable in the region of the yellow spot. The retinal veins are also somewhat dilated. According to Stellwag, more or less considerable portions of the fundus are rendered almost uniformly red by a very delicate and close-meshed network of vessels. It must always be remembered, that the degree of vascularity of the retina and optic disc varies much in different individuals, and in persons of different complexions. Thus, it is less marked in pale and anæmic individuals than in the florid and plethoric. If only one eye is affected, the appearances presented by it should always be compared with those of the other eye, as this will enable us more accurately to estimate the degree of vascularity of the retina, and guard us against an error in diagnosis.

Arterial hyperæmia of the retina is generally dependent upon causes which excite an increased vascularity of the eye, thus, it may be artificially produced by the application of a drop of some astringent collyrium to the conjunctiva. It is often due to prolonged exposure to very bright light, more especially if the eyes are at the same time

employed in some small and delicate work, as for instance in microscopizing, engraving, watch-making, etc., by artificial light. It is also frequently met with in hypermetropic persons who work or read much without the assistance of glasses.

In the venous or passive form of hyperæmia, we notice that the retinal veins are abnormally large, dark, and perhaps tortuous, which is especially marked in the smaller veinlets, which may present a somewhat corkscrewy appearance. There is also either a spontaneous or a very easily producible venous pulsation. If the venous congestion has lasted some length of time, we frequently notice a slightly œdematous condition of the retina around the optic disc, or along the course of some of the larger vessels, which appear to be fringed by a delicate greyish-blue opacity or halo. Care must be taken, not to mistake this for another form of opacity along the edge of the vessels which is due to hypertrophy of their coats, and which will be noticed hereafter. The sight after a time generally becomes somewhat impaired, but this disappears again when the cause is removed. This form of hyperæmia is mostly slow in its development, and is due to a state of venous congestion dependent perhaps upon some disturbance in the general circulation, caused by an affection of the heart or liver; or again, it may be dependent upon local causes which, by impeding the efflux of blood from the retinal veins, give rise to a mechanical venous hyperæmia. Amongst such causes we may instance intra-cranial tumours which press upon the cavernous sinus, or tumours situated in the orbit and compressing the optic nerves; or again, an increase in the intra-ocular tension (a glaucomatous condition of the eye). I must here point out that it is quite erroneous to assert, that the tension of the globe is more or less increased in the passive or venous hyperæmia of the retina. This is in fact mistaking cause and effect, and such a mistake is apt to lead to great errors in diagnosis and treatment. The intra-ocular tension is never increased when the venous retinal hyperæmia is simply due to disturbance in the general circulation, to tumours pressing upon the cavernous veins, or to intra-orbital tumours; it is only increased in a glaucomatous condition of the eye, and here the venous hyperæmia is due to the augmented tension of the globe, and does not produce it.

If the arterial hyperæmia of the retina is considerable, the patient should not be allowed to use his eyes at all, more especially by artificial light, until the symptoms have quite subsided. If the affection is due to some defect in the accommodation or refraction of the eye, as for instance presbyopia or hypermetropia, this must be corrected by suitable glasses. Blue or smoke-coloured eye-protectors should be worn to guard the eyes against the irritating influence of bright sun or artificial light, and the eye-douche will be found beneficial in relieving the irritability of the eye. In the treatment of venous hyperæmia our

attention must be chiefly directed towards the prevention of any disturbance and congestion of the venous system. The functions of the heart, liver, and uterus must be regulated, and special care be taken to prevent determination of blood to the head. Much benefit is often derived from hot stimulating foot-baths and a course of mildly purgative mineral waters. The congestion of the retinal circulation is best relieved by Heurteloup's artificial leech. It should be applied periodically, at intervals of six or seven days, and if the patient is anæmic or in feeble health, but little blood ($\frac{1}{2}$ or $\frac{3}{4}$ of a cylinder) should be taken, or dry cupping should be substituted.

2.—INFLAMMATION OF THE RETINA.

Before I pass on to the description of the different forms of retinitis which gain their distinctive characters either from the anatomical changes which accompany them, or from the constitutional affections which have given rise to them, it will be well to consider the various symptoms, ophthalmoscopic and anatomical, which are more or less common to all forms of inflammation of the retina, and which may be very well grouped under the head of "*idiopathic retinitis.*"

Idiopathic Retinitis.

Practically we may divide this into two principal forms. In the one, the pathological changes are chiefly those of œdema of the retina or of a serous infiltration of its connective tissue; in the other, the inflammatory changes affect the proper structure or parenchyma of the retina. We may, therefore, distinguish a *serous* and a *parenchymatous* form of idiopathic retinitis. The former is generally acute, the latter more chronic in its course.

As the *serous* retinitis does not give rise to striking ophthalmoscopic symptoms, it is not always easy to diagnose this disease if the effusion is but slight. This is especially the case if a strong illumination is employed, for these delicate changes in the retina are best observed by a moderate degree of illumination, and in the erect image. Serous retinitis is characterised by the appearance of a very delicate, bluish grey or bluish-green veil, which is spread over the surface of the retina, and hides the epithelium and vessels of the choroid. The opacity, which may affect a more or less considerable portion of the retina, is quite uniform, and presents no marked striæ, dots, or patches. It is only with a very weak illumination and a considerable magnifying power that we can observe a faint striation of the opacity. Mauthner*

* "Lehrbuch der Ophthalmoscopie," 361.

mentions two cases in which the retinitis presented very peculiar greenish striæ. This was, however, only observable by a weak illumination, and in the direct mode of examination. The opacity shades off towards the periphery, gradually and imperceptibly, into the transparent normal retina, which not unfrequently remains quite unaffected. The serous infiltration is especially marked in the vicinity of the optic disc, but gradually diminishes in intensity towards the region of the yellow spot, on account of the decrease in the thickness of the retina at this point. Hence the choroid also shines through more distinctly here, and thus lends a redder tint to the macula lutea. Indeed this redness is sometimes so very striking, more especially on account of its contrast with the neighbouring greyish opacity of the retina, that it might be readily mistaken for an effusion of blood. The periphery of the retina is often quite free from serous infiltration, and the details of the choroid can then be plainly distinguished at this point. The optic disc is always somewhat swollen and œdematous, and its outline indistinct and ill defined, the choroidal and sclerotic margins being rendered unapparent by the serous infiltration. The retinal arteries generally show but little alteration in their appearance, being, perhaps, only slightly veiled, and a little attenuated. The veins, on the other hand, are strikingly hyperæmic; they are large, dark, tortuous, the latter being especially marked in the smaller branches. On close examination we may often notice that the vessels do not throughout their whole course, lie always on the same level, but here and there dip a little into the effusion, or are pushed a little outwards (towards the vitreous) by it. In the former case, they will seem slightly indistinct and veiled, in the latter, the portion which is nearest to the observer will appear peculiarly dark and visible. These peculiarities are best distinguished with the binocular ophthalmoscope, or in the erect image. There are also sometimes small extravasations of blood on or beside the vessels. The sight is always much affected, sometimes so considerably that the patient cannot distinguish the largest letters, or count fingers. The field of vision is also contracted, but if the peripheral portion of the retina is unaffected, the corresponding portion of the field will not be impaired. The first complaint of the patient is, generally, that he notices a grey film or veil before his eyes, which gradually increases in thickness and surrounds the various objects, hiding them more and more from the sight, until he becomes almost totally blind. With all this, the external appearance of the eye remains normal and healthy, excepting that the pupil generally becomes sluggish and somewhat dilated, but even this is not always very marked, and might be easily overlooked. There is no marked photophobia, lachrymation, ciliary injection, or intense pain, none of the symptoms, in short, which are still so often erroneously described as characteristic of inflammation of the retina, but which are not due to retinitis, but to hyperæsthesia of

the retina—two perfectly different affections. We shall see hereafter, to what grave errors in treatment a diagnosis of retinitis from these symptoms but too frequently leads. It must be particularly remembered, that in serous retinitis the ophthalmoscopic symptoms are never so marked and striking as might be expected from the great impairment of sight, the latter being probably chiefly due to the compression of the nerve elements by the serous effusion.

The prognosis should always be very guarded, because if the affection lasts for some time, the nerve elements of the retina may become atrophied, and the sight be permanently destroyed. Or again, this form may pass over into a more chronic inflammation, affecting chiefly the parenchyma of the retina, and giving rise, perhaps, to diseases of the choroid or the vitreous humour. The danger of detachment of the retina must also be borne in mind.

The treatment should be chiefly directed towards relieving the congestion of the retinal vessels, and for this purpose local depletion by means of the artificial leech will be found most efficacious. The free action of the kidneys and skin should be maintained by saline diuretics and diaphoretics. A pair of dark blue glasses should be worn so as to protect the eyes against all glare and bright light. All employment of the eyes must be forbidden until they have quite recovered.

In the *parenchymatous* retinitis, the changes are not confined to a serous infiltration of the connective tissue, but this and the nervous elements of the retina undergo other inflammatory changes, such as proliferation of the cells, hypertrophy, sclerosis, and fatty or colloid degeneration. The sclerosis of the connective tissue may, according to Iwanoff,* be chiefly confined to the membrana limitans interna, or affect the basic connective tissue which pervades the retina in a vertical direction, and supports the other elements like a framework. On account of these various changes, the ophthalmoscopic appearances are far more marked and striking than in the serous retinitis. The optic disc is opaque, swollen, somewhat hyperæmic, and of a reddish grey colour; its outline is irregular and indistinct, passing insensibly over into the retina, without any clear line of demarcation. The swelling is due to serous infiltration or inflammatory exudation, which may have extended from the retina to the optic nerve, or *vice versâ*. If the effusion is serous in character, the opacity will be of a pale, greyish pink, or fawn colour; but where there is much exudation of lymph, it will be more opaque, white, and perhaps somewhat glistening. If the exudation occupies the more external layers of the retina, the vessels may be observed to pass distinctly over it without any dipping; whereas, if it is situated in the inner layers of

* Vide Iwanoff's very interesting papers on Retinitis, in the "Kl. Monatsblätter," 1864, 415, and also in the "Archiv. f. Ophthalmologie," xi, 1, 136.

the retina, or quite on the surface of the disc, the vessels will be more or less interrupted and hidden by it. The retinal arteries are sometimes but slightly changed in appearance, in other cases they are more or less diminished in size, and rendered indistinct by the exudations. The veins are increased in size, darker in colour, and their tortuosity is generally very marked.

Blood extravasations of varying size and extent, are strewn about on and around the blood-vessels in different portions of the retina, as well on the optic disc and its vicinity. If these extravasations are situated in the inner portion of the retina, they will present a peculiar striped or striated appearance, their edges being irregular; which is due to the radiating course of the optic nerve fibres, between which the blood is effused. If the hæmorrhages occupy the more external layers of the retina, the effusions will be round, and have a smooth uniform appearance quite free from striæ. The exudations into the retina also vary much in size and appearance. Sometimes, they look like small white or greyish-white dots strewn about singly or in small clusters. In other cases, they are larger, and form well marked white patches or flakes, of considerable size, the edges of which are perhaps fringed by the smaller dots. The colour of these exudations varies from a greyish white to a creamy tint, and they often have a peculiar glistening appearance, which is due to their containing fatty elements. They are met with in different parts of the retina, but especially in and around the optic disc, and in the region of the yellow spot.

Although I have used the term exudation for these patches in the retina, I must state that this is not always quite correct in the strict acceptation of the term, for they are often due to inflammatory changes in the connective tissue or nerve elements of the retina, giving rise to a proliferation of the cells and their contents, or they are caused by a degenerative metamorphosis of a fatty or colloid nature. But as it is difficult, and often quite impossible, to distinguish ophthalmoscopically between these different products, and as the term exudation has been generally accepted, I have thought it best to retain it.

When the exudations are situated in the external portion of the retina (in which case, they are generally due to proliferation of the cells, and fatty or colloid degeneration of the external granular layer with sclerosis of the membrana limitans externa, the bacillar layer becoming subsequently affected), we find that they afford the appearance of smooth greyish-white or cream-coloured, perhaps glistening patches, which do not show a striated arrangement, and are evidently situated beneath the retinal vessels, for the latter pass over them without dipping into them, or being interrupted or veiled in their course. We may at the same time often notice that the choroid in the vicinity of the exudations is undergoing certain inflammatory changes, which consist chiefly in a

thinning of the epithelium and an absorption of its pigment, so that the choroidal vessels become more apparent. The stroma of the choroid also becomes affected, and it is now no longer a case of simple retinitis, but of choroido-retinitis. When the retinal exudations subsequently become absorbed, we find that extensive changes in the choroid have taken place beneath them. In such cases the inflammation, although apparently chiefly affecting the retina, often commences in the choroid, and extends thence to the retina.

The inflammatory changes may, however, be chiefly confined to the inner portion of the retina, giving rise at first to hypertrophy of the stroma, formation of nuclei in the layer of the optic nerve fibres, and neo-plastic formations of connective tissue (Iwanoff)*. These fibres of connective tissue are often arranged in bundles, and if they increase very greatly in quantity, they may gradually compress and destroy the nerve fibres. The optic nerve fibres and ganglion cells may also undergo proliferation and sclerosis of their elements, and subsequently perhaps fatty degeneration. Another very interesting fact is, that in this form of retinitis the membrana limitans interna becomes thickened, and occasionally shows, at certain points, small excrescences which bulge into the vitreous humour. The latter is often affected, becoming hazy and pervaded by opacities, which are chiefly observable at its posterior portion. Detachment of the retina may also occur. This form of retinitis is very frequently associated with irido-cyclitis or irido-choroiditis, and then it generally commences at the peripheral portion of the retina, near the ora serrata, and extends from thence towards the centre. When these inflammatory exudations are situated in the inner layers of the retina, we find that they are rather striated in appearance, and that the retinal vessels, instead of passing straight and uninterruptedly over them, are seen to dip into them here and there, becoming indistinct or even invisible at these points.

After the disease has lasted for some time, the exudations and hæmorrhagic effusions may undergo absorption, the stasis in the circulation be relieved, the blood-vessels assume a more normal appearance, and the swelling and œdema in and around the optic disc subside, so that it regains a more sharply defined outline. The sight at the same time improves considerably, and this amelioration may become permanent. But the disease does not always run so favourable a course, for the nerve elements of the retina may have suffered so considerably as to render any improvement of the sight impossible. This may be due either to the inflammatory changes (sometimes even assuming a purulent character) which they have themselves undergone, or to the great hypertrophy and sclerosis of the connective tissue, which encroaches more and more upon the nerve elements, compresses them, and gradually

* "A. f. O.," xi, 1, 139.

leads to atrophy of the retina. If the optic nerve has been much implicated in the inflammatory process, the atrophic changes may also commence in it.

The coats of the blood-vessels often undergo sclerosis and fatty degeneration, becoming thickened, and the channel of the vessel perhaps narrowed. The blood-vessels then assume the appearance of whitish bands, with a small central red streak of blood flowing through them. As this change in the coats of the vessels may take place to a greater or less extent in all forms of retinitis, I do not think that it is desirable to make a special form of it, even in those instances in which it assumes a very considerable extent, affecting perhaps nearly all the retinal vessels, as in some rare and very exceptional cases recorded by Wecker,* Nagel,† and Iwanoff. The latter has proposed to call it "Perivascular-retinitis." In the case mentioned by Nagel all the retinal arteries and their branches were changed in both eyes into white bands, which, on closer examination, were observed to be pervaded by a central red line or blood current. Only very few of the small arterial twigs were of a red colour. The veins, on the other hand, were normal in appearance, although somewhat narrow and irregular in calibre. At the periphery, there were a few fine veinlets changed into white bands. On account of this white appearance of the blood-vessels, it might easily be supposed that they were bloodless, and the case be mistaken for one of embolism of the central artery of the retina. The difference between these two conditions may, however, be best distinguished, as has been shewn by Liebreich, by attention to the two following points:—1. If the vessel is not changed in its entire course, we should commence the ophthalmoscopic examination from a point where it is still red, and trace from thence the *contours* of the vessel. If it is bloodless, we can observe the outline of the vessel going on, and the thickness of the latter remaining the same, whereas if there is hypertrophy of the coat there is an increase in its thickness. 2. Another method is, to throw a very small pencil of light close to the point of the vessel which we wish to examine. By this means we can illuminate the parts lying behind the vessel, and then, if the latter is empty, it still looks like a white streak, whereas, if its coats are hypertrophied, it will look red, on account of the column of blood shining through.

Retinitis is but rarely met with as an idiopathic affection, but sometimes it is difficult to determine its exact cause. It is probable that it may be produced by prolonged exposure to extremely bright light, as from a furnace or large cooking fire, or by excessive use of the eyes, especially by strong artificial light. At first, only a hyperæmic condition of the optic nerve and retina is noticed, and then, if the employment is

* Wecker, "Etudes Ophthalmologiques," ii, 323.

† "Klinische Monatsblätter," 1864, 394.

persisted in, retinitis may ensue. But retinitis is far more frequently due to some constitutional affection, or consequent upon some other disease of the eye, *e.g.*, choroiditis, etc. Thus, it may be dependent upon irregularities of the general circulation, and is therefore sometimes met with in affections of the heart, or in disturbances of the uterine functions, and in the later stages of pregnancy, in which case, however, albuminuria is generally present. It may also be caused by syphilis, by certain affections of the kidney, especially Bright's disease and diabetes, and by cerebral diseases. In the latter case, it generally assumes the form of neuro-retinitis.

The prognosis will chiefly depend upon the cause and severity of the disease, and the extent to which the nerve elements of the retina are implicated in the inflammatory changes. We shall see, when considering the different special forms of retinitis, that the serous infiltration of the retina, blood extravasations, and fatty degeneration of its connective tissue, etc., may become absorbed, and excellent vision be restored as long as the optic nerve elements have not suffered much. For changes in them are not retrogressive, and consequently the sight remains permanently impaired. Vision is sometimes not very greatly affected if the region of the yellow spot is not implicated in the disease; so that the patient may be still able to read tolerably fine print. But his general impression of larger or distant objects is mostly indistinct and hazy, the objects appearing to be shrouded in a mist or cloud. In other cases, the impairment of sight is very considerable.

The field of vision may, as far as extent is concerned, be normal, but the perception at the periphery is generally somewhat diminished, often indeed considerably so; there may also be gaps in the field, the situations of which correspond to those of the more extensive exudations in the retina.

A peculiar phenomenon is sometimes observed, as consequent upon inflammatory changes in the regions of the yellow spot, either dependent upon retinitis or choroido-retinitis; I mean *micropsia*, so that objects appear smaller to the patient than they really are. If he be directed to copy or trace a given figure (such as a circle or quadrant) he will always draw it considerably smaller than it is in reality. The difference in the sizes of the image of the object in the two eyes (if only one is affected with micropsia) may also be estimated, as has been suggested by Von Graefe, by holding a prism, with its base downwards, before the affected eye; this will cause its retinal image to lie a little below that of the other eye, and the patient can thus easily estimate their relative sizes. This micropsia is evidently due to the fact, that the position of some of the rods and cones is deranged by the inflammatory changes in the retina. Besides the diminution in the size of the objects, the patients often notice that horizontal lines, instead of appearing

straight, seem bent and crooked; this is termed "metamorphopsia," * and is due to an alteration in the position of the rods and cones, which may be caused by the presence and pressure of inflammatory products, or by shrinking and contraction of the retina.

3.—RETINITIS ALBUMINURICA (NEPHRITIC RETINITIS, Plate III, Fig. 6).

As a certain form of inflammation of the retina is often met with in Bright's disease of the kidney, and as it presents some special and characteristic symptoms, it has been designated "retinitis albuminurica." The peculiar grouping and localization of the pathological changes in the retina are so marked and constant in this form of retinitis, that, as has been more especially pointed out by Liebreich, the presence of Bright's disease may be diagnosed with certainty by means of the ophthalmoscope alone. At the outset of the disease this is not, however, the case, for then the appearances do not yet afford any special characteristics. The affection commences with a fulness in the retinal veins, which are dilated, darker in colour, and more or less tortuous; whereas the arteries are either normal in appearance or but slightly narrowed in calibre. The optic disc is hyperæmic, and this is soon followed by a faint, bluish-grey, serous infiltration of the optic nerve and the retina in its vicinity. The outline of the disc then becomes somewhat veiled and indistinct, so that the choroidal and sclerotic rings are hidden from view, and the optic nerve appears to pass gradually over into the retina, without any sharply defined line of demarcation. The retinal vessels are also somewhat veiled, and covered by a pale bluish-grey film, which extends to some distance from the disc (perhaps three or four times its diameter), and hides the details of the subjacent choroid. The retinal hyperæmia may extend a considerable distance beyond this serous infiltration, and a few extravasations of blood are often noticed scattered about on different portions of the retina. As the disease advances, the symptoms of venous hyperæmia become much more marked, the veins look turgid, dark, and more tortuous, the smaller veinlets assuming a corkscrew appearance. The arteries, on the other hand, are narrowed and more or less hidden by the infiltration. The optic disc becomes more swollen and infiltrated, and its outline gradually merged into the retina. The infiltration of the disc and of the retina is of a serous character, and gives to these parts a faint greyish-red or fawn-coloured appearance, interspersed with delicate greyish-white striæ, which are due to sclerosis of the connective

* Vide Förster's very interesting paper upon this subject in his "Ophthalmologische Beiträge." Berlin, 1862.

tissue and of the optic nerve fibres. The retinal vessels are frequently interrupted at various points of their course, by being covered and more or less hidden by the exudation. As a rule, the swelling and infiltration of the optic nerve are not very great in retinitis albuminurica; but we occasionally meet with cases in which the reverse obtains and the disc assumes the peculiar appearance met with in optic neuritis. It is very prominent, swollen, and "woolly," and of a greyish-red and markedly striated appearance, which is due to the infiltration occupying the layer of the optic nerve fibres. The outline of the disc is indistinct and irregular, and its blood-vessels more or less completely hidden by the infiltration. According to Liebreich, this form of optic neuritis may occur only in the later stages of nephritic retinitis, after extensive degenerative changes in the retina have existed for some length of time, or it may precede these, or even exist by itself.

Numerous extravasations of blood are noticed in different parts of the retina, and even on the optic disc. They vary much in size and shape, and lie chiefly in the internal layers of the retina, as is shown by their striated appearance, and the fact that they are situated on the same level as the retinal vessels, some of which may even be partly covered and hidden by them. The hæmorrhage may, however, also occur in the external layers of the retina, or between the latter and the choroid. These blood extravasations into the retina are often very numerous, and of considerable size, a fact at which we cannot be surprised when we remember that the coats of the retinal vessels are frequently extensively diseased; that there is always a certain degree of stasis in the retinal circulation produced by the swelling of the optic nerve; and finally, that there is mostly a more or less considerable disturbance in the general circulation, owing to the hypertrophy of the left ventricle, which is so frequently met with in Bright's disease. If the effusions of blood are very extensive, they may alter the appearance of the exudation very considerably, giving to it a dirty, yellowish red tint.

As the disease of the retina progresses, we notice the appearance of small white spots or larger patches in different portions of the retina, at some little distance from the optic disc. These gradually increase in size, and, coalescing with each other, finally form a broad white mound or wall round the optic disc. The opacity extends especially towards the inner side of the retina, and somewhat further along the sides of the retinal vessels. This white mound does not reach close up to the optic disc, but is always separated from it by a broad zone of the faint grey or fawn-coloured infiltration, in the centre of which can be indistinctly traced the outline of the disc. The peripheral portion of the mound is irregular, and broken up here and there into small circumscribed dots of exudation, which form a kind of fringe round the larger figure. In the region of the yellow spot we notice a very

peculiar appearance, which, as was first pointed out by Liebreich, is especially characteristic of nephritic retinitis, viz., a collection of small, stellated, white, glistening figures, which look just as if they had been lightly splashed in with a small brush. Subsequently, if the exudation increases in size, these stellated spots may become merged into it, and this peculiar appearance be completely lost. The two ophthalmoscopic symptoms which are most characteristic of retinitis albuminurica are, these bright stellated dots in the region of the yellow spot, and the broad glistening white mound which encircles the optic disc. But it must be stated that similar appearances, especially the stellate dots may be met with in other forms of retinitis, more particularly in neuro-retinitis; with this difference, however, that the peculiar grouping of the ophthalmoscopic appearances is not the same. In a case of neuro-retinitis recorded by Von Graefe,* these peculiar white spots in the macula lutea were very evident, but, as he points out, such cases may be distinguished from nephritic retinitis by the following characteristics:—(a), that the white spots due to degenerative changes in the retina (neuro-retinitis) are situated much closer to the optic disc; (b) that the swelling of the retina in the vicinity of the disc is more considerable; (c) that the swelling of the optic nerve is also more pronounced; and (d) that the veins are much more dilated and tortuous, which lends a far more red and vascular appearance to the optic entrance.

Retinitis albuminurica does not, however, always manifest itself in so very characteristic a form. For the different symptoms above enumerated may assume considerably less prominence, or some of them may be altogether absent. Thus the optic disc and the retina in its immediate vicinity may appear almost normal, and there may only be a slight alteration in the retinal vessels, a few hæmorrhagic effusions, and here and there white patches of exudation, lying either isolated or along the coats of the vessels. In the region of the yellow spot these patches assume a streaky appearance (Mauthner).

Nephritic retinitis may become complicated with inflammatory changes in the choroid and vitreous humour, or with detachment of the retina. At a later stage atrophy of the optic nerve and of the retina may close the scene.

In favourable cases, the serous infiltration, the effusion of blood and certain of the white patches may subsequently become absorbed, so that the retinal vessels, which were previously hidden at certain points of their course, again become perfectly apparent. The veins diminish in size and tortuosity, and the arteries become more filled with blood. We may now, perhaps, also discover changes in the epithelium and stroma of the choroid, which had been previously

* "A. f. O.," vi, 2.

hidden by the exudations in the retina. Sometimes, we moreover find that sclerosis or fatty degeneration of the coats of the blood-vessels has taken place, so that they show a distinct and well-marked white margin. Whilst there can be no doubt that the serous infiltration, the hæmorrhagic effusions, the fatty degeneration of the granular layers, and the hypertrophy of the connective tissue may undergo a more or less considerable degree of absorption, this does not appear to hold good with regard to the sclerosis of the optic nerve fibres, which remain unaltered.

Let us now briefly glance at the pathological changes which occur in the retina in nephritic retinitis, and give rise to these peculiar and characteristic ophthalmoscopic appearances. The serous infiltration of the optic nerve and retina occurs principally in the connective tissue elements, and especially in those which support the optic nerve fibres; hence the striated character of the opacity, which is partly due to the serous transudation, and partly to sclerosis of the connective tissue elements. The white patches and the large white glistening wall which encircles the optic disc, are due to fatty degeneration of the cellular and connective tissue elements of the retina, more especially of the external granular layer. The striated appearance is due to hypertrophied nerve fibres, or sclerosis of the connective tissue. The peculiar little stellated white dots in the region of the yellow spot are owing to fatty degeneration of the radial connective tissue fibres. The stellated appearances being probably due, according to Schweigger,* to the peculiar anatomical arrangement of the radial fibres at the yellow spot. For Bergmann† has shown that these do not pass perpendicularly through the retina, but are slightly curved in such a manner that, as they pass from the inner to the outer portion of the retina, they converge towards the centre of the yellow spot. The optic nerve fibres also undergo sclerosis, which gives rise to peculiar opalescent spots. These are often arranged in little clusters, and thus produce a swelling of the layer of the optic nerve fibres. Within these little clusters of sclerosed nerve fibres may also be noticed globules of fat. It is of great importance, as far as the prognosis of the case with regard to the restitution of vision is concerned, to diagnose, if possible, this condition of sclerosis of the optic nerve fibres. This is, however, difficult, as the clusters or nests of sclerosed nerve fibres appear with the ophthalmoscope simply as little white spots or patches, very like those which are due to fatty degeneration. Our principal guide must be their position, for being situated in the innermost layer of the retina, they will lie in front of, and upon the retinal vessels, and they are often accompanied by small extravasations of blood (Schweig-

* "A. f. O.," vi, 2, 312; Lectures on the Ophthalmoscope, 107.

† Henle and Pfeufer's Zeitschrift, 1854, and 3 Reihe, ii, 83.

ger). Whereas the white patches due to fatty degeneration, are generally situated in the more external layers of the retina, and therefore lie behind the vessels.

The extent to which the connective tissue and the nerve elements of the retina are affected, does not necessarily correspond. Sometimes, the latter may be extensively implicated, the connective tissue being at the same time but moderately or only slightly affected. In such a case, the sight will be much more seriously and permanently impaired than if the reverse obtains.

Heinrich Müller* has also noticed sclerosis of the chorio-capillaris, on account of which, the calibre of the vessels is greatly narrowed or they are even obliterated at certain points. The peculiar fibrillar appearances occurring at the periphery of the vitreous humour which he described, are supposed by Schweigger to be probably due to post-mortem changes.

The coats of the retinal vessels are also frequently affected with sclerosis or fatty degeneration, and in the larger branches the tunica adventitia is often considerably hypertrophied, so that the calibre of the vessel is diminished in size, and it appears like a white band with a central red line.

The sight is generally considerably impaired, and the patients have sometimes become hypermetropic, which is evidently due to the thickening of the retina, in consequence of which it now lies within the focal distance of the eye. This hypermetropic state of the refraction is very evident with the ophthalmoscope, the retinal vessels and details of the fundus being quite visible in the erect image at some little distance from the patient, and moving in the same direction as the head of the observer. Sometimes, the patient is still able to read medium-sized type, in other cases, he can only decipher the largest print, or count fingers with difficulty. The field of vision, on the contrary, is often not at all contracted, and only perhaps somewhat impaired at the very periphery, whilst the central vision may be greatly deteriorated. We often find, however, that there are gaps in the field, certain portions being more or less impaired, and that these correspond to the portions of the retina in which the inflammatory changes are most marked and extensive. I must here call special attention to the fact, that the impairment of vision does not necessarily correspond with the striking changes in the retina presented by the ophthalmoscopic appearances. For the most marked and conspicuous symptoms, the white patches and the glistening white mound, are chiefly due to fatty and hypertrophic changes in the connective tissue and cell elements of the retina, and are capable of absorption. And hence these pathological changes are not of such

* Würzburger, "Medicinische Zeitschrift," i, 1, 1860; vide also translation of this paper by the author, "R. L. O. H. Reports," iii, 51.

importance with regard to the state of vision as those which implicate the nerve elements. But these alterations in the nerve elements afford far less striking ophthalmoscopic appearances than those due to fatty degeneration. The impairment of sight in nephritic retinitis is generally slowly progressive, and this will guard us against confounding it with the sudden attacks of amaurosis which are met with in cases of Bright's disease, and which do not depend upon inflammation of the retina, but upon uræmia. In the latter case, the attacks occur with startling suddenness, so that the patient may become perfectly blind within a few minutes or hours, the recovery being as rapid. Moreover, there are always present marked general symptoms of uræmic poisoning, such as intense headache, vertigo, loss of consciousness, sickness, epileptoid convulsions, etc. The ophthalmoscopic symptoms in these cases of uræmic amblyopia are, moreover, quite negative. But we may not unfrequently have a mixture and succession of symptoms of amblyopia dependent upon the retinitis and upon uræmia. Thus nephritic retinitis has perhaps existed, to a more or less advanced degree, for some time, giving rise to a certain amount of amblyopia, and suddenly the latter is greatly increased by an attack of uræmia. Mooren* has noticed the very rapid development of a high degree of hypermetropia in cases of uræmic amblyopia.

It was at one time supposed by some observers (especially Ladouzy) that the amblyopia is sometimes premonitory of and precedes the disease of the kidney. But this is not so, the affection of the retina occurs only when the nephritis (either acute or chronic) is already fully developed, and also in its later stages, more especially together with the small, contracted kidney. It is, however, also observed in the large flabby kidney.

Sometimes indeed, the amblyopia is the only marked symptom, the affection of the kidney being unknown and unsuspected by the patient and his medical adviser. In some of these cases there are, however, symptoms of derangement of the digestive functions, nausea, sickness, etc. We are consulted as to the condition of the sight, the ophthalmoscope reveals the symptoms of retinitis albuminurica, the urine is tested for albumen, and then it is discovered that the patient is suffering from Bright's disease. The affection of the retina attacks both eyes, either simultaneously or at a short interval.

Hypertrophy and dilatation of the left ventricle are almost constantly met with; indeed, in 32 cases Von Graefe found them present in all. The frequent occurrence of extensive retinal hæmorrhages is probably also due to the disturbance in the circulation caused by the hypertrophy, although it must also be remembered that the coats of the blood-vessels are often diseased. That nephritic retinitis may,

* Mooren, "Ophthalmiatrische Beobachtungen," 1867, p. 287.

however, occur without hypertrophy and dilatation of the left ventricle is proved by cases recorded by Mandelstamm and by Horner. The former* found that out of 13 cases of retinitis albuminurica, hypertrophy of the left ventricle was only present in two.

Great uncertainty still exists as to the connecting link between the affection of the kidney and that of the retina. The cause is yet unknown why, together with Bright's disease, we should so frequently meet with a special form of retinitis, the ophthalmoscopic symptoms of which are so constant and peculiar, both in the grouping and localization, that from their appearance alone we are able to diagnose with certainty the presence of albuminuria.

It has been supposed by some, that the inflammation and degeneration of the retina are due to an impairment of the nutrition of the latter, dependent upon the great amount of urea in the blood. By other observers (especially Traube†) it has been thought, that the secondary increase in the tension of the aortic system forms the starting point of the disease. In favour of the latter opinion, we must admit the extreme frequency of hypertrophy and dilatation of the left ventricle as an accompaniment of nephritic retinitis, as also the constant occurrence of more or less extensive extravasations of blood in the retina at the outset of the disease.

The prognosis as to the degree of sight that may be regained by the patient, must depend upon the extent to which the pathological changes in the retina have advanced, and still more upon the degree to which the nervous elements of the retina have suffered. It has been already stated that many of the inflammatory products may become absorbed. If this occurs, and the nerve elements have been but slightly implicated, vision may be restored almost, or even quite, to the normal condition. It is different, if the nerve tissue has been extensively affected, for then we find that even although the large white patches, the serous infiltration, and the blood extravasations become to a great extent absorbed, serious impairment of sight remains behind. Sometimes atrophy of the optic nerve may even ensue, especially if it has been much implicated in the inflammation. As a rule, however, nephritic retinitis leads only very exceptionally to complete blindness.

There is no direct connection between the improvement in the sight and the absorption of the exudations, etc., and the amount of albumen in the urine, or the condition of the kidney disease, for the former may occur without any amelioration in the constitutional affection. The best prognosis is afforded by those cases in which the albuminuria occurs in advanced pregnancy, after scarlatina, typhoid fever, etc.

The treatment must be chiefly directed towards the primary disease.

* Pagenstecher, "Klinische Beobachtungen," 1866, p. 80.

† "Deutsche Klinik.," 1859, p. 314.

I have found most benefit from the use of tonics, more especially the tincture of the muriate of iron, or from the citrate of quinine and steel. The free action of the skin should be encouraged and maintained. If symptoms of uræmic poisoning supervene, diaphoretics and purgatives should be freely administered. The only local application from which I have found any benefit is the artificial leech. In those cases in which it is unadvisable to abstract blood on account of the anæmic condition of the patient, I apply the dry cup to the temple, and have often seen this followed by marked improvement in the vision. It is to be repeated at intervals of five or six days.

The patient should, of course, be warned not to expose himself to the effects of very glaring light, nor should he be permitted to use his eyes for reading or working.

4.—RETINITIS LEUCÆMICA.

Liebreich has several times noticed a peculiar affection of the retina in connection with leucocythemia. It is chiefly characterised by the great palor of the retinal vessels, more especially the veins, which are of a faint rose colour, even although they may be dilated and tortuous. The optic disc is likewise very pale, there is a striated opacity in its vicinity, and small irregular patches in the region of the yellow spot. Finally, at the periphery of the fundus are noticed a number of brilliant white circular spots, which greatly resemble those met with in Bright's disease. In one case of retinitis leucæmica, which was examined by Liebreich with the ophthalmoscope, Recklingshausen subsequently found, on microscopical examination, that these white spots were due to the same form of sclerosis of the optic nerve fibres as that described by H. Müller in Bright's disease.

An admirable illustration of retinitis leucæmica is given in Liebreich's Atlas der Ophthalmoscopie, Plate x, fig. 3.

5.—RETINITIS SYPHILITICA.

A peculiar form of retinitis is sometimes met with in persons suffering from constitutional syphilis, and as it affords certain characteristic symptoms it is occasionally possible to diagnose the nature of the malady from the ophthalmoscopic appearances alone. It must be admitted, however, that the latter may in some cases be so slightly marked, that our diagnosis as to the syphilitic nature of the disease must chiefly depend upon the general history of the case, and upon the presence of other symptoms of constitutional syphilis.

At the outset, there is simply hyperæmia of the optic disc and retina.

The retinal veins are somewhat dilated, dark, and tortuous, but not markedly so, and the venous congestion diminishes as the disease progresses. Sometimes, the venous hyperæmia is only partial. The retinal arteries are attenuated and diminished in size. The optic disc is slightly swollen, and its outline hazy and ill-defined. The disc as well as the surrounding retina are veiled by a faint bluish-grey film, which is due to a serous transudation of the optic nerve and retina. This film is often extremely delicate and faint, assuming perhaps only the appearance of an exaggeration of the physiological, grey reflex which the retina of normal, darkly pigmented eyes presents. This uniform bluish-grey opacity does not extend regularly in all directions from the optic nerve, but is often principally developed in certain parts of the retina, and more especially along the course of the vessels, whence it shades off gradually and imperceptibly into the healthy retina. In the vicinity of the disc, the opacity is markedly striated. Although minute punctiform opacities generally occur in the region of the yellow spot, they are not so brightly glistening, or arranged in the peculiar stellate manner as those met with in nephritic retinitis, but are strewn about irregularly. They are, moreover, distinguished from these, by the fact that they undergo very rapid changes, perhaps disappearing and re-appearing in the course of a few days, the sight at the same time undergoing corresponding fluctuations. The spots in Bright's disease are on the other hand very persistent, and their remains may often be distinctly traced even many months after the acute retinitis has passed away, and its residue alone remains, or atrophy of the disc has set in. We also sometimes meet with a peculiar tawny, reddish-brown tint in the region of the yellow spot in syphilitic retinitis.

The inflammatory changes in syphilitic retinitis consist chiefly in a serous infiltration of the retina, and sclerosis of the connective tissue elements, more especially of the vertical trabecular fibres (stütz fasern), hence also the striated character of the opacity. The other portions of the retina are generally exempt from inflammatory and degenerative changes, but this is not always the case, and thus may arise a mixed form of syphilitic retinitis, in which the special and pathognomonic symptoms are accompanied, and perhaps somewhat masked, by other changes in the parenchyma, and great swelling of the optic nerve. Thus white spots or patches may be noticed in the retina. These may occur in small isolated patches, or in the form of large striped opacities situated in the innermost layer of the retina; their pressure perhaps causing complete emptiness of some of the vessels, which are changed into white bloodless bands (Liebreich). These, however, are never so brilliantly white as the spots met with in nephritic retinitis.

As a rule, retinal hæmorrhages are not usually met with in syphilitic retinitis, or only to a very moderate extent. Sometimes, however,

cases occur in which numerous and extensive extravasations of blood are noticed, which may be situated in different layers of the retina, and also between it and the choroid. Syphilitic retinitis is not unfrequently associated with inflammation of the choroid, and occasionally with irido-choroiditis, or iritis. If the symptoms of the inflammation of these tunics are very pronounced, the affection of the retina may be overlooked, more especially if the vitreous humour, as is often the case, is diffusely clouded and traversed by dark flakes, and the details of the fundus are thus rendered indistinct. Care must be taken not to mistake such an indistinctness of the optic disc and retina for that dependent upon retinitis, or to diagnose the presence of the latter simply from the great impairment of vision. A practised and careful ophthalmoscopist would not, however, fall into such errors of diagnosis.

Together with the symptoms of syphilitic retinitis, we often notice certain more or less extensive changes in the choroid. These may occur either in the vicinity of the retinal opacity, at some distance from it, or be chiefly confined to the periphery of the fundus. These changes consist principally in a thinning and discoloration of the epithelial layer, the pigment cells of which are collected together into small masses, giving rise to more or less considerable groups of small grey dots intermixed with little black spots, which are aggregations of pigment cells. The latter may, perhaps, subsequently invade the retina (Liebreich). In other cases the inflammatory changes affect the deeper portions of the choroid, and we then notice large grey patches in which the pigment cells of the epithelial layer and stroma of the choroid are absent, so that the choroidal vessels can be distinctly seen; such patches being generally fringed by a dark black zone of pigment.

Syphilitic retinitis generally occurs together with, or shortly after the appearance of secondary symptoms, and is sometimes, as has already been stated, accompanied by inflammation of other tunics of the eye, such as choroiditis or irido-choroiditis. It may also be due to hereditary syphilis (Hutchinson).

The course of the disease is generally slow, lasting many weeks or even months, and relapses are very apt to occur.

The sight often diminishes rapidly, so that in the course of a few days the patient may be only able to decipher No. 16 or 20 of Jäger, and may become greatly impaired, more especially if the region of the yellow spot is much affected. We find also, that the condition of the sight fluctuates considerably with the presence or absence of the little punctiform opacities in the macula lutea. Another interesting phenomenon is the frequency of micropsia in syphilitic retinitis. The field of vision is often either not at all, or only slightly impaired, but it frequently shows peculiar circumscribed zonular defects in the vicinity of

the yellow spot, to which, as well as the frequent presence of photopsies, particular attention has been called by Mooren.

The prognosis of the disease is favourable, more especially if the patient is seen at a very early period of the attack. Although the sight may be considerably impaired, the inflammatory changes in the retina do not, as a rule, affect the nervous elements, but chiefly consist in a serous infiltration of the retina, and hypertrophy and sclerosis of the connective tissue. But if the latter is greatly hypertrophied, it will press upon the nerve elements, and may thus even lead to their atrophy. There is much tendency to relapses, either after the attack has completely, or nearly completely subsided, or as the disease is progressing towards recovery. By the recurrence of such relapses, the ultimate functional condition of the retina may, of course, be greatly endangered.

In treating syphilitic retinitis we must place our chief reliance upon mercury, for the greatest benefit is generally experienced from bringing the patient rapidly under its influence. This may be done either by its administration internally, or by the inunction of the mercurial ointment. I myself prefer the latter method, and generally prescribe from ʒss. to ʒj. of the ointment to be rubbed into the inside of the arms and thighs three times daily, and this mostly causes salivation in the course of a few days. If the patient has been recently salivated, a combination of iodide of potassium and bichloride of mercury should be given.

As the hyperæmia and congestion of the retina are generally not marked, the application of the artificial leech is not always indicated.

Under the name of "*central recurrent retinitis*," Von Graefe* has described a very rare and interesting form of syphilitic retinitis, which is especially characterised by its being confined to the region of the yellow spot, and by its marked tendency to recur very frequently. He has known it recur 10, 20, 30, and in one case more than 80 times. The attack is generally very sudden, and disappears again in the course of a few days, but a relapse occurs in from a fortnight to three months. At first, there is generally no impairment of sight during the intervals between the attacks, but afterwards, when the latter become more prolonged, some amblyopia remains. When the attack is about to occur, the patient notices a dark, irregular spot in the centre of the field of vision, or certain portions of the latter are obscured. The sight is always greatly impaired, so that the largest letters can hardly be deciphered. If both eyes are affected simultaneously, the patient is almost perfectly blind, and quite unable to guide himself. During the attack there is generally some photophobia, and perhaps some slight ciliary injection, more especially in the morning on awaking. Ophthal-

* "Archiv. f. Ophthalmologie," xii, 2, 211.

moscopically, the affection may be distinguished from the common syphilitic retinitis, by the fact that the delicate bluish-green film of opacity is confined to the region of the yellow spot, culminating around the fovea centralis, and gradually and uniformly shading off towards the periphery of this region. The vicinity of the optic disc is quite free from opacity. Sometimes, small, delicate, white dots are noticed in the opacity, which are, perhaps, arranged in little groups, but they do not present the brilliantly white, lustrous appearance of fat granules. The effusion in the yellow spot becomes developed during the attack, but is preceded by the functional disturbances, and these again disappear sooner than the effusion. In the more recent cases the latter disappears completely during the intervals of the attacks, but at a later stage a faint, grey opacity remains behind in the close proximity of the fovea centralis. In one case, in which a great number of relapses were closely watched during six years, the opacity contained irregular masses of dark blue pigment.

This affection is undoubtedly due to syphilis, but does not show itself until a very long period (sometimes many years) after the secondary constitutional symptoms.

Von Graefe has only found the long-continued or repeated use of inunction of mercury beneficial. The intervals between the attacks become longer, and the latter less severe, until they gradually become extinguished. Whether or not the sight will be completely restored, will depend upon the fact whether permanent changes have taken place in the retina. Marked micropsia was noticed in several cases.

6.—RETINITIS APOPLECTICA (Plate VI., Fig. 7).

In this affection we find, that together with more or less hyperæmia and œdema of the optic nerve and retina, there is an extreme tendency to extravasation of blood into the retina. The condition of the optic nerve varies considerably, in some cases, there is only a moderate degree of hyperæmia and serous infiltration, rendering the disc somewhat indistinct, and its outline irregular; in others, the disc is of a deep red tint, and its margin so ill-defined, that it can only be distinguished from the surrounding retina by the emergence of the retinal vessels. The veins are dark, much dilated, and very tortuous, and along their course, more especially at their points of division, are seen numerous extravasations of blood. The arteries may retain their normal appearance, but generally become attenuated, and sometimes changed into white, bloodless bands. The extravasations of blood vary much in number, extent, and situation. They occur very frequently in the inner layer of the retina, and are then characterised by their peculiarly

irregular and striated appearance, and also by the fact that they cover the blood-vessels more or less completely, or that the continuity of the latter is interrupted, the gap being occupied by the hæmorrhage. The blood frequently makes its way from the optic nerve layer through the retina, the elements of which it pushes aside, to the outer layers, or even to the choroid, so that the hæmorrhages may be situated in the more external portions of the retina, or between this and the choroid. In such cases the effusions will be more sharply defined, uniform, and circular, and be distinctly situated beneath the retinal vessels. Effusions of blood into the retina always show more tendency to extend outwards towards the choroid, than inwards towards the vitreous humour, where the internal membrana limitans offers a stronger barrier to them. They may, however, break into the vitreous, and produce dense opacities. Sometimes, however, they extend along the inner surface of the retina, and then give rise to large, uniform, smooth-looking red patches, which completely cover and hide the vessels. The hæmorrhagic effusions occur in different portions of the retina, and may be chiefly confined to the vicinity of the optic disc or yellow spot, or to the periphery of the fundus. Extravasations may also occur on the disc.

There are generally no exudative or degenerative changes of the retina, such as are met with in other forms of retinitis, there being only a serous infiltration, often very slight, in and around the optic nerve.

The effusions of blood retain their colour for a very long time, more especially in old people, and then breaking up, they either slowly undergo absorption, or become changed into a dark crumbling mass (Liebreich). In the former case they gradually assume a lighter, greyish tint, which, commencing at the edge of the extravasation, slowly extends to the whole, the blood being gradually absorbed. Sometimes these extravasations undergo fatty or pigmentary degeneration. The latter occurs sooner in blood effused into the vitreous, than when it is situated in the retina (Liebreich). The disease shows a great tendency to relapses, and in this is to be found one of its chief dangers, for if they occur frequently, or to a considerable extent, the function of the retina may be greatly impaired, and even atrophy of the optic nerve and retina ensue. The prognosis should therefore always be guarded, especially if the extravasations are numerous, and situated in the yellow spot. The sight is in some cases not very markedly affected, or not in a degree corresponding to the striking ophthalmoscopic appearances presented by the numerous and extensive hæmorrhages. This depends entirely upon which part of the retina is the seat of the effusions. If the latter have occurred at the periphery, the sight may be quite unaffected; if in the yellow spot, it will be greatly impaired.

Sometimes the attack is extremely sudden, a patient finding that in the course of a few moments, or on awaking in the morning he has become nearly absolutely blind. The patients at the same time often experience a feeling of dizziness and faintness. The field of vision is not unfrequently somewhat contracted, and shows more or less extensive interruptions or gaps, or there may appear in it grey shadows or black spots, which are in all probability due, as was pointed out by Heymann, to entoptic shadows thrown by the blood extravasations upon the sensitive elements of the retina.

Retinitis apoplectica occurs frequently together with disturbances of the general circulation, which may be due to affections of the uterus, liver, or the heart; thus it is not unfrequently seen together with suppression of the menses, hypertrophy and dilatation of the left ventricle, and affections of the aortic valves. Also, if any impediment exists to the venous reflux from the eye, either from tumours etc., pressing upon the optic nerve within the orbit, or situated within the cranium. In such cases, however, the blood extravasations are generally soon followed by œdema and inflammation of the optic nerve. Another frequent cause is fatty or atheromatous degeneration of the coats of the blood-vessels, and it is consequently often met with in old persons, and in such cases it may be of prognostic importance, as it leads us to suspect that the vessels of the brain may also be degenerated, and that imminent danger may consequently be apprehended. The treatment must consist chiefly in attempting to remove the cause, and preventing if possible a recurrence of the disease. Diuretics and saline aperients, more especially mineral waters are often of much benefit. Locally the artificial leech should be employed.

7.—RETINITIS PIGMENTOSA (Plate III., Fig. 5).

This disease is principally characterised, as its name suggests, by the presence of pigment in the retina, which gives rise to a most peculiar and unmistakeable appearance, more especially when the pigment is deposited in considerable quantity. In the latter case, we notice that the greater portion of the retina is covered by large black masses, which are arranged chiefly along the course of, and in close proximity to the retinal vessels.

On close examination, we find that these black masses of pigment consist of circular or irregular shaped spots; of larger black spots with long narrow prolongations, and which are hence often likened to bone corpuscles; and of narrow black lines running along the side of a vessel or completely covering it. On account of the deposits of pigment along the coats of the vessels, the latter often appear, for a certain portion of

their course, changed into fine black lines. At the division of the vessels the pigment deposits assume a peculiarly characteristic stellate appearance. The pigment is sometimes deposited along the course of vessels which are still pervious and carry blood. For an illustration of the ophthalmoscopic appearances of retinitis pigmentosa, vide Plate III, fig. 5.

These deposits of pigment always exist in the greatest number at the periphery of the fundus, where they first make their appearance, and whence they gradually extend towards the posterior pole of the eye, so that they form a more or less broad girdle, which encircles the central portion of the retina; but at a later period the region of the yellow spot also becomes invaded by the disease. The pigment appears to be as a rule first developed at the inner (nasal) side of the retina; indeed it always remains more extensive on this than on the temporal side. The retinal vessels undergo in this disease certain constant and marked changes, which evidently greatly influence the condition of hemeralopia and contraction of the field of vision. These changes consist in a thickening of the coats of the retinal vessels, and a consequent diminution in their calibre; they, however, retain their transparency, and simply appear diminished in size, and this condition is consequently frequently described as being due to atrophy of the optic nerve. The smaller branches are often completely obliterated. Schweigger* has more especially pointed out this fact, and considers that the peculiar torpor of the retina, which is noticed when the illumination is moderate, is due to the fact that on account of the diminution in the calibre of the arteries an insufficient amount of blood is supplied to the retina. At a later stage of the disease, atrophy of the optic nerve and of the retina almost always occur. Changes in the choroid are also not unfrequently met with. These may be chiefly confined to a thinning and atrophy of the epithelium at certain points, so that the choroidal vessels become apparent, and are seen traversing these lighter patches, which are often fringed by a dark zone of pigment; or the stroma of the choroid may become affected, and if it be much thinned, the white sclerotic may be seen glistening through it. In such cases the fundus affords a very marked and striking appearance, being marbled with more or less extensive, reddish grey, or greyish white glistening patches, in the expanse and at the edge of which are agglomerations of pigment. It is now no longer a case of simple retinitis pigmentosa, but of choroido-retinitis.

At a later stage of retinitis pigmentosa, we often find that an opacity makes its appearance at the posterior pole of the lens, which remains either stationary or is but very slowly progressive. The retinitis almost always affects both eyes. In rare instances the vitreous humour also becomes

* Vorlesungen über den Augenspiegel.

affected, and small grey, circumscribed flakes are seen floating about in it. Externally the eyes present nothing abnormal, excepting that the pupil is generally small, and the anterior chamber somewhat shallow.

Great diversity of opinion still prevails as to the formation of the pigment, and whether it is primarily developed in the retina, or whether it makes its way into the latter from the choroid. Until several eyes, in which the typical form of retinitis pigmentosa has been diagnosed during life with the ophthalmoscope, have been submitted to careful microscopical examination, this cannot be decisively settled. At present it appears certain that the disease may arise in both ways. Thus Donders found that the pigment may be developed in the retina itself, probably in consequence of a chronic inflammation of this membrane. That such may actually be the case, without any participation of the choroid, is also proved by a case of Schweigger's,* in which he found, on microscopical examination, that the deposit of pigment on the retinal vessels may occur quite independently of any changes of the choroid, for in this case the choroidal epithelium was perfectly normal, even in spots where the retina was pigmented. The pigmentation was confined to the retinal vessels, the coats of which were thickened and the smaller branches obliterated, these changes extending beyond the pigmentation. In those cases, in which irregular roundish masses of pigment are strewn about the retina, Schweigger thinks that the disease is always due to choroiditis, and that the deposits of pigment partly become developed in the firm exudations which have forced their way into the retina from the choroid, or are due to the fact that the proliferating pigmentary epithelial cells of the choroid are floated into, or grow into the retina. Junge thinks that a deposit of pigment along the retinal vessels can only take place in the retina when the external layers are more or less destroyed, so that the pigment can make its way from the choroid into the retina.

There is, moreover, another way in which an infiltration of pigment from the choroid into the retina may occur, for an accurate knowledge of which we are chiefly indebted to the valuable researches of H. Müller and Pope.† It appears that a proliferation of the granular cells of the retina similar to that in nephritic retinitis may take place independently, accompanied by hypertrophy of the radiating connective tissue fibres in the external granular layers, which become bent in an arcade-like manner. The baccillar layer of the retina becomes destroyed, and the hypertrophied granular layer protrudes above the external layer of the retina; between these protrusions there exist corresponding depressions, into which the pigment cells of the epithelial layer of the choroid become pushed and heaped up into little black masses, which lend a peculiar

* Vorlesungen, p. 113.

† "Wurzb. Med. Zeitschrift," iii; also "Oph. Hosp. Reports," iv, p. 76.

marbled appearance to the retina. It is doubtful, however, as Schweigger points out, whether this morbid process yields the peculiar ophthalmoscopic appearances characteristic of retinitis pigmentosa.

The most striking symptom of which the patients complain is that of hemeralopia, or night blindness. During the day, or in a bright illumination, they may be able to see perfectly well, but as soon as it becomes dark, or they are taken into a dimly-lighted room, their sight becomes greatly impaired. I need hardly point out that this peculiar impairment of vision is quite independent of the fact whether it be night or day, and is simply due to the retina being in a condition of torpor, which demands a very bright illumination in order to enable it to distinguish objects which a healthy eye could see with ease, even by a moderate amount of illumination. This torpor of the retina is in all probability not due to the pigmentation of the retina, but, as Schweigger insists, to the obliteration of the retinal vessels or the diminution of their calibre through hypertrophy of their coats, so that the retina obtains a diminished and insufficient supply of blood. The truth of this opinion is proved by the fact, that Schweigger has noticed the presence of hemeralopia and contraction of the field of vision in children before the appearance of any pigment in the retina; but in all these cases there was a marked contraction of the retinal arteries, whilst the older brothers and sisters had retinitis pigmentosa. He also observed this, in some rare instances, in older persons (between the age of 40 and 50), who suffered from all the symptoms of retinitis pigmentosa, *e.g.*, hemeralopia from torpor of the retina, great contraction of the visual field, without any trace of pigmentation of the retina or any other symptom except contraction of the arteries and paleness of the disc. In similar cases Von Graefe has subsequently found a deposit of pigment in the retina.

The field of vision is often very greatly contracted in cases of retinitis pigmentosa, so that there may only be a very small portion remaining, the diameter of which perhaps only measures a few inches; whilst the sight in the optic axis may yet be excellent, enabling the patient to read the very finest print, although all around him is shrouded in darkness. On account of the considerable contraction of the field, these patients acquire a very awkward and restless appearance, for their eyes are always turned slowly about in various directions, so as to bring the optic axis to bear upon surrounding objects, which they would otherwise not perceive or stumble over. They therefore experience great difficulty and danger in passing along a crowded thoroughfare, and still more in crossing the street, as, although they may see well straight before them, they cannot distinguish anything that lies in the lateral portions of the field.

As long as the region of the yellow spot remains unimpaired the

sight may remain good, but between the ages of 35 and 50 the disease almost invariably leads to complete blindness, the retina and optic nerve becoming atrophied. Retinitis pigmentosa almost invariably occurs in both eyes. Padraglia mentions a case in which it affected only one eye, as I have also met with one amongst my patients at Moorfields. The disease is very frequently congenital and also hereditary. Although it may be present at birth, it always slowly and gradually increases in extent with advancing years. Schweigger has noticed that the pigmentation of the retina is not only preceded by contraction of the arteries, but also by small light coloured dots or faint stripes in the choroid. The disease may first show itself about the age of 8 or 10, or even later in life, at 30 or 40. It frequently occurs in several members of the same family, and is then often hereditary. Such cases are mentioned amongst others by Laurence, Mooren, and Hutchinson. Laurence* met with it in four members of the same family (of eight); in this case it was not hereditary. Mooren has also seen it in four persons of the same family. Liebreich has pointed out the important fact that it occurs very frequently in marriages of consanguinity, and often together with deaf-mutism. Other malformations—such as supernumerary fingers and toes, are also sometimes seen together with retinitis pigmentosa.

The prognosis is, of course, very unfavourable, as these cases always end sooner or later in total blindness. With regard to treatment, I can only recommend care of the eyes, more especially against bright glare and over work, and attention to the general health. Occasionally some temporary improvement of the central vision has taken place after the application of the artificial leech, and the administration of bichloride of mercury, iodide of potassium, etc., but it has been noticed in some of these cases, that this improvement has been followed by a marked and rapid deterioration of the field of vision.—(Mooren).

8.—DETACHMENT OF THE RETINA (Plate V., Fig. 10).

If the detachment of the retina from the choroid is very extensive and reaches far into the vitreous humour, the symptoms presented by it are so marked and characteristic that it may sometimes be recognised with the naked eye, but certainly with the greatest ease by the aid of the ophthalmoscope. On examining in the direct method an eye affected with an extensive detachment of the lower half of the retina, we at once notice that, when it is moved in different directions, we gain

* "Ophthalmic Review," vol. ii, 32.

the usual bright red reflex from the upper part of the fundus, but that in the lower half this is not the case. Here, on the other hand, the reflex has a bluish-grey or greenish tint, and on closer inspection we observe a bluish-grey, floating, wavelike opacity, which is thrown into marked undulating folds with every movement of the eye, and which is traversed by dark, crooked, and distorted vessels. On account of the bulging forward of the detached retina into the vitreous, these details can be readily seen with the direct examination at some little distance from the eye. The detached retina also reflects the light very strongly, which is chiefly due to the difference between the colour and refracting power of the fluid situated between the retina and choroid and those of the vitreous humour. The minute details may be examined either in the erect or reverse image, and the extent of the detachment, as well as the course and displacement of the vessels, should be carefully studied. It will be noticed that the vessels are darker than on the normal retina, and that they are very crooked and tortuous, riding, so to speak, on the folds of the retina, between which they may even be completely hidden for a part of their course. With every movement of the eye they, as well as the undulating grey folds of retina, quiver and tremble. On tracing out the limits of the detached portion, we generally find that, even beyond its marked commencement, there is a faint greyish opacity or thickened appearance of the retina, and that the vessels are somewhat darker, and show a slight tendency to be curved. This opacity of the retina is due to serous infiltration. If the detached fold of retina is large and prominent, it throws a distinct dark line of shadow upon the neighbouring fundus.

Whilst little or no difficulty can be experienced in recognising a considerable detachment of the retina, the same cannot always be said of the slighter degrees, the diagnosis of which often demands considerable dexterity and experience on the part of the observer. This is more especially the case if the subretinal fluid is transparent, and the vitreous humour is somewhat clouded. Sometimes, it is only by tracing out most carefully and with the greatest exactitude, the course of each individual retinal vessel from the optic disc towards the periphery of the fundus, that we are enabled to detect a very slight degree of detachment. In such a case, we notice that as the vessels reach the detached portion (which is generally somewhat opaque and thickened looking, or thrown into a slight fold), they assume a darker tint, and instead of preserving a straight course, they become tortuous and bent, forming a more or less marked deflection.

On close examination, we also notice that the vessels lie on a different level to those which retain their normal position, being closer to the observer, who has consequently slightly to alter his accommodation in order to obtain as distinct an image of them. Indeed the apprecia-

tion of this difference in the plane of the vessels, is one of the most delicate aids in the diagnosis of commencing detachment of the retina. We can, moreover, detect a well-marked parallax; for if we make a lateral movement with the object lens, the portion of the vessel which is elevated by the detached retina, will be seen to make a greater movement than that part which lies in the normal retina. The detached portion of retina also reflects the light more strongly, which is especially appreciable in the direct examination.

On tracing the course of the vessels further, we often find that as we approach the periphery of the fundus, the detachment becomes more conspicuous and extensive, the retina being, perhaps, near the equator of the eye, thrown into distinct whitish-grey folds. In the portion of retina which is still *in situ* and in close proximity to the detachment, we may sometimes notice small, reddish-white exudations, and also, as was especially pointed out by Von Graefe,* small, red, isolated patches, which are made up of minutely coiled blood-vessels. Small partial detachments of the retina are often difficult to recognise, as they may simply appear in the form of little, faint, grey streaks. These details are best appreciated with the binocular ophthalmoscope. The colour of the detachment depends chiefly upon that of the fluid which lies beneath it; at first, the detached portion of retina is generally transparent, but at a later period it becomes more or less opaque and clouded. This may, however, be the case from the commencement, if the detachment supervenes upon inflammation of the retina. The sub-retinal fluid also varies considerably in composition. When recent, it is transparent, or of a faint straw colour, and of a serous nature, containing a good deal of albumen (Bowman),† which coagulates on exposure to heat, or may even do so in the eye, and then it becomes adherent to the walls of the detached retina in the form of opaque flakes (Liebreich). It may also contain blood, fibrin, nuclei, pigment and fat molecules, or cholesterine.

The detachment most frequently occupies the lower portion of the fundus, and its extent varies considerably. It may for some time remain confined to the periphery of the fundus, and then gradually extend further and further, until it reaches the optic nerve, and thus involves the whole of the lower half of the retina. It often, also, mounts up somewhat on one or both sides of the disc. When the detachment occurs in the upper portion of the retina, it soon extends from thence downwards, which is due to the gravitation of the fluid, and in such a case the greater portion of the retina may become detached all round the optic disc, forming a funnel-shaped detachment, whose apex is at the optic nerve. But we may sometimes also observe

* "A. f. O.," i, 1, 367.

† Bowman, "Ophthalmic Hospital Reports," vol. iv, p. 136. 1864.

that as the fluid gravitates downwards, the upper portions of the retina fall again into apposition with the choroid, regaining perhaps a considerable or even normal degree of transparency; this being, moreover, accompanied by a great improvement of vision. This, I may state, in passing, is a most important point with regard to the indications of treatment.

Sometimes, if the retina has been tensely stretched by the fluid beneath it, a rent may occur in it, and we can then observe with the ophthalmoscope that there exists a gap, within which the vessels and intra-vascular spaces of the choroid are distinctly apparent;* the edges of the torn retina being curled or rolled up into little folds.

The first symptom which the patient generally notices is that of a faint grey cloud floating before him, or of a dark spot, surrounded by a lighter halo. This cloud has a wavy, indistinct outline, and its position in the field of vision corresponds accurately with the situation of the detached portion of retina. Thus, if the detachment be situated at the lower part of the retina, the patient notices a little cloud or curtain hanging down into the upper part of the visual field, like the edge of a veil, or peak of a cap. He also notices that linear objects, instead of preserving a straight outline, appear to be wavy and broken. This metamorphopsia is probably due to a change in the normal position of the nerve elements of the retina in the close vicinity of the detachment, this displacement being, perhaps, caused by a slight dragging upon that portion of the retina which is no longer *in situ*. Knapp† points out that the metamorphopsia due to detachment of the retina, is distinguished by the fact, that the objects are fringed with a coloured ring, and undergo slight undulating movements. Sometimes, this metamorphopsia is the principal symptom which leads us to detect a small circumscribed detachment of the retina. The patients also often complain of bright flashes of light, bright circles or stars, etc., these photopsies being due to the irritation and stretching of the retina, produced by the change in its position. The black spots and flakes which float about in the field of vision, assuming various peculiar forms, are caused by opacities in the vitreous humour, which are very frequently met with in detachment of the retina, and may even be the cause of it.

On examining the field of vision, we find a more or less marked impairment and contraction of certain portions of it, which correspond to the situation of the detachment. Thus, if the latter has occurred below, the upper portion of the field will be impaired, and *vice versâ*. If the detachment is very irregular in its outline, the field presents corresponding irregularities, the outline of the defective portion rising and falling according to the rise and fall of the detachment. We find

* Vide Liebreich's Atlas, Plate VII, Fig. 1.

† "Klinische Monatsblätter," 1864, p. 307.

that the field of vision is contracted not only quantitatively, but also qualitatively; although there is no doubt that the retina, even when actually raised by fluid from the choroid, may retain a certain degree of perceptive power, the patient being able to tell the movements of the hand or even to count fingers.

The indistinctness or contraction of a certain portion of the visual field is also seen occasionally to precede the detachment of the retina, and is, therefore, of great prognostic importance. Thus, in cases of extensive sclerectasia posterior, we may sometimes detect a marked contraction of the field in a certain direction (say upwards, or upwards and inwards), but the most careful and accurate ophthalmoscopic examination will fail to discover any detachment. But some time afterwards this may occur, and at a point of the retina corresponding to that portion of the field which was defective.

The causes of detachment are numerous, and sometimes obscure. It may be produced by blows upon the eye, or by penetrating wounds of the posterior portion of the eyeball, in which case there is often a cicatricial contraction of the retina; also by effusions of blood or serum between the retina and choroid. In such a case, the hæmorrhage generally occurs from the choroid, on account of the greater vascularity of this membrane. When speaking of hæmorrhage into the vitreous humour (p. 316), it was mentioned that when the bleeding occurs in the central portion of the fundus, it is prone to lead to detachment of the retina, whereas, in the equatorial region it is more apt to break through into the vitreous humour. But hæmorrhage from the retina itself, by making its way outwards between the choroid and retina, may lead to a detachment of the latter.

The serous effusion between the retina and choroid which produces the detachment, may be the product of inflammatory lesions of these tunics, or may be due to a sudden compression of the vessels of the eye and an impediment of the venous reflux, as for instance in cases of exophthalmos due to intra-orbital tumours, etc.

The most frequent cause is undoubtedly an elongation of the optic axis, as in cases of sclerectasia posterior, for the elongation of the sclerotic is accompanied by a corresponding stretching of the choroid and retina. The former, on account of its firm union with the sclerotic, and its greater elasticity, follows this gradual distension, but the retina is less elastic, and will therefore have a greater difficulty in following the traction of the sclerotic and choroid; its connection with the latter will be rendered lax, and any slight effusion or exudation from the choroid will suffice to produce an extensive detachment. Such effusions are the more likely to occur in these advanced cases of sclerectasia posterior, as there is generally some choroiditis present, or a disturbance of the intra-ocular circulation.

A cysticercus, making its way through into the vitreous humour may give rise to a considerable detachment of the retina, which will be tense, and not undulating or falling into folds. It may also be produced by a tumour springing from the choroid, and here the early diagnosis of the cause of the detachment is of much consequence. This may be difficult when the tumour is small, as the detachment may then be loose and undulating, whereas, when it increases in size, and protrudes more into the vitreous humour, the retina may be stretched tensely over it, and not fall into wrinkles or folds; or distinct nodules, perhaps of a dark pigmented appearance, are seen stretching out the detached retina here and there. The diagnosis of a tumour is still more strengthened, if, with the increase in the size of these nodules, the eye tension progressively augments (Graefe).* Indeed the tension of the eyeball is of great importance in the differential diagnosis between a simple detachment of the retina, and one produced by a subretinal tumour. In the former case, the eye-tension is almost always decidedly diminished, whereas the reverse obtains in cases of intra-ocular tumour, the tension being either normal, or, as the growth advances, markedly augmented. Bowman,† has, however, in a few rare instances met with a tendency to increased tension in cases of simple detachment of the retina.

The retina may also be detached by traction from in front, through the contraction and shrivelling up of opacities in the vitreous humour, which are by one extremity attached to the retina. In contracting, they draw the latter from the choroid, its connection with which is often already but very slight, as for instance in cases of sclerotico-choroiditis posterior.

The *prognosis* of detachment of the retina is unfavourable. In some very rare instances, the disease may remain stationary at an early stage, and whilst the detachment is still but inconsiderable. Or the detachment may even disappear, the subretinal fluid having become absorbed, or penetrated into the vitreous humour after a spontaneous rupture of the retina. In such cases, the retina is re-applied to the choroid, and may regain its functions, even after the detachment has lasted for some time, for the rods and bulbs retain their anatomical characters for a long time. Such cases are, however, very rare. One is described by Von Graefe, in which the detachment occurred in consequence of an orbital abscess, and where after the escape of the discharge, the retina became re-attached to the choroid, and the sight restored.‡ A similar case is recorded by Dr. Berlin.§

Mr. Bowman has also mentioned a case to me, in which he has

* "Arch. f. Ophth.," xii, 2, 239.
† "Ophthal. Hosp. Reports," iv, 134.
‡ "Klin. Monatsblätter," 1863, p. 49.
§ Ibid., 1866, p. 77.

observed the total spontaneous disappearance of a considerable detachment. Other cases have been narrated by Liebreich, Galezowski, Steffan, etc.

But in the great majority of cases the natural course of the disease is slowly, but surely progressive, leading finally to total blindness, sometimes in consequence of irido-choroiditis and atrophy of the globe. Although the detachment generally remains confined to one eye, it may extend to the other, and this is to be especially feared, if the same cause exists in the latter, *e.g.*, extensive sclerectasia posterior.

Until the last few years, the treatment has been entirely directed towards endeavouring to procure the absorption of the subretinal fluid, or to prevent and retard the progress of the detachment. The chief remedies that were employed for this purpose were derivatives, mercury, the application of the artificial leech, etc. The patients being at the same time strictly ordered to abstain from all employment that necessitates any prolonged effort of the accommodation, or that might produce congestion of the eye or head. The results, however, of this mode of treatment were not favourable, and only in very rare instances did the detachment disappear. I must confess that I have never succeeded in achieving this result by medicinal means, although I have been sometimes able to retard the progress of the disease by suitable treatment, together with complete rest of the eyes, and the occasional and guarded application of the artificial leech. The latter should, however, be employed with extreme care, as its application is always followed by a certain degree of intra-ocular hyperæmia, which might easily tend to increase the detachment. For this reason, I often prefer dry cupping at the temple or the back of the neck, more especially in those cases in which the hyperæmia might prove particularly dangerous, *e.g.*, sclerectasia posterior accompanied by marked symptoms of congestion and vascular excitement.

The fact that the absorption or gravitation of the subretinal fluid, or its escape into the vitreous after spontaneous rupture of the retina, is followed by a marked return of sensibility in the re-attached retina, has led some of the most distinguished ophthalmologists, especially Bowman and Graefe, to endeavour to gain a similar favourable result by operative treatment, by dividing the retina and permitting the fluid to escape into the vitreous humour.

Von Graefe,* in order to gain this end, divides the retina with a peculiar cutting-needle, having two sharp edges. The eye being steadied with a pair of forceps, he enters the needle in the sclerotic about 4—5 lines from the edge of the cornea, and in the meridian corresponding to the most prominent part of the detachment, and if the

* "Archiv. f. Ophthalm.," ix, 2, 85; vide also Mr. Roger's able translation of this Article in "Ophthal. Hosp. Rep.," vol. iv, p. 213.

situation of the latter permits it, the puncture should be made in the outer hemisphere. The needle should be passed perpendicularly behind the lens into the vitreous chamber for about 6 lines, and then, the apex being turned by a simple lever movement towards the fundus, the one edge is to be pressed against the retina. This movement is to be continued whilst the needle is simultaneously withdrawn. By the latter retracting incision, the continuity of the prominent retina is to be divided. Care must be taken not to bring the point of the needle in contact with the choroid.

Mr. Bowman states that his object in operating in detachment of the retina "has never been to give external vent to fluid, though this has almost always been one immediate effect of my punctures, but rather to open a permanent communication inwards from the subretinal space, under the idea of allowing the effused fluid to escape into the vitreous chamber, rather than to spread further between the retina and choroid, thereby further severing their organic connection. So slight is this connection that fluid effused at one part easily gravitates to another more dependent part."* At first Mr. Bowman only used one needle, simply puncturing the retina through the sclerotic, but he now employs two, dilacerating the retina in a manner similar to that in his double needle operation for opaque capsule. This operation is performed in the following manner:—The lids are to be kept apart with the spring speculum, and the eye, if necessary, fixed with a pair of forceps. The needles, which should have a fine lancet point, are then to be introduced separately through the sclerotic at a short distance from each other, and at a point corresponding to the most prominent part of the detachment; the points are then directed towards each other so that they may pierce the retina at the same spot; by then separating their points the retina is torn between them (as in Fig. 54). Generally a little oozing of the subretinal fluid takes place under the conjunctiva, indeed it may even give rise to a small elevation. The vitreous often becomes somewhat turbid after the operation, but soon clears again, and then the small tear in the retina may sometimes be detected. The points of puncture of the sclerotic must vary of course with the position and extent of the detachment, but they will generally lie from $\frac{1}{4}$ to $\frac{1}{2}$ an inch from the margin of the cornea, and between the tendons of the recti muscles. As the operation gives but little pain, chloroform need not, as a rule, be administered. The operation is generally followed by some, often by very considerable improvement of the sight and the state of the

Fig. 54.

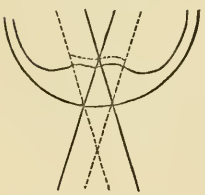

* Vide Mr. Bowman's very interesting Article, "On Needle Operations in cases of Detached Retina," "Ophth. Hosp. Reports," iv, 134.

field of vision. It is true that this improvement is mostly but temporary, and that the operation may have to be repeated several times, each repetition being again followed by a diminution of the detachment and amelioration of the sight; such repetitions should not, however, follow too closely upon each other, otherwise serious irritation of the eye may be set up. I have seen instances in which the improvement after one operation has lasted for many months, and Bowman and Graefe have observed cases in which it has been maintained for about two years. Arlt* mentions one in which the cure still continued 14 months after the operation.

The operation is free from danger, and is generally followed by but slight symptoms of irritation.

If we consider the striking results often obtained by it, and compare these with the want of success accompanying the former plan of treatment, it must be conceded, I think, that its adoption is to be strongly recommended. From my own favourable experience of its results I have no hesitation in speaking strongly in its favour. We should, however, be careful distinctly to warn our patients that the effect may only be slight and temporary. The operation should, if possible, be done at an early stage, so as to limit the extent of the detachment, and prevent the risk of the retina undergoing organic changes, leading to the permanent impairment of its perceptive functions. For a more complete exposition of these points I must refer to the articles of Bowman and Von Graefe already quoted.

I should mention that Wecker employs a small trocar for puncturing the retina, which he enters from the opposite side of the eye, and, after withdrawing the subretinal fluid, tears the retina in removing the instrument.

9.—EPILEPSY OF THE RETINA.

Dr. Hughlings Jackson has described a very peculiar condition of the retina met with during the epileptic fit, and has given to it the name of epilepsy of the retina. With regard to it he says:†—"In one case, however, a case of 'epileptiform convulsions,' I had the opportunity of examining the fundus of the eye, if not during a genuine fit, at least during a condition in which consciousness was lost, and in which the pupils, ordinarily small, were dilated as if under the influence of atropine. The optic discs were extremely pale. Once the vessels disappeared for an appreciable time. After a while, however, they reappeared and were found to vary with the respiration. When the patient *in*-spired the vessels disappeared, returning again on

* "Bericht der Wiener Augenklinik.," 1867, 85.

† "Ophth. Hosp. Reports," iv, p. 14.

expiration, like lines of red ink on white paper." It appears to be a temporary complete anæmic condition of the retina, dependent in all probability upon a contraction of the retinal vessels, just as the unconsciousness occurring during the epileptic fit is, according to Brown-Sequard, due to a contraction of the vessels of the brain, and consequent anæmia of the latter.

10.—ISCHÆMIA RETINÆ.

In this affection the retina is also extremely anæmic, the arteries being greatly attenuated and almost bloodless, the veins hyperæmic, but irregularly filled, the optic disc either normal or but slightly pale, with its edges perhaps faintly indistinct, the tension normal and dioptric media clear. The blindness comes on very suddenly, affects both eyes, and is complete. Such at least were the principal symptoms in cases of this very rare affection recorded by Alfred Graefe,* Rothmund,† and Heddäus‡. In Graefe's case the patient, a little girl 5½ years of age, suddenly overnight became totally blind in both eyes, so that not the faintest perception of light remained. On examination, the eyes presented the following appearances:—The tension of the eyes normal, conjunctivæ very pale, the eyeballs of marble whiteness, pupils much dilated, without any reaction on the stimulus of light, but a faint uniform contraction on the application of laudanum, only slight increase in dilatation on the application of atropine. With the ophthalmoscope, the dioptric media were found transparent, the retinal arteries extremely attenuated, the veins tortuous and dilated, but irregularly so. The retina and optic nerve were normal, the outline of the latter being, however, very slightly indistinct.

The colour of the skin, but especially of the mucous membranes, was extremely pale. The child was otherwise perfectly well; the only peculiar symptoms being the extreme rapidity of the pulse, which was very small, and numbered 160 beats in the minute. Graefe considered that the probable cause of the blindness was an insufficient supply of blood to the retina, the faint and rapid contractions of the heart not being sufficient to overcome the normal, but proportionately too considerable, intra-ocular tension; he therefore gave the name of "ischæmia retinæ" to this affection. The correctness of this view of the cause is strengthened by the fact that, after all other remedies, such as mercury, suppurating blisters behind the ears, artificial leeches to the temple, etc., had failed, an iridectomy, made upon the right eye

* "Archiv. f. Ophthalm.," viii, 1, 143.
† "Klin. Monatsb." 1866, p. 106.
‡ Ib., 1865, p. 285.

ten days after the complete loss of sight, proved successful. The object in performing this operation was to diminish the intra-ocular tension, and thus to obtain mechanically a greater filling of the vessels ex vacuo. Paracentesis was performed on the left eye. The effect was most marked and interesting; twenty hours after the operation the child could, with the right eye, see the movements of a hand, and in two days count fingers up to 2 feet, the pupil acting more freely. The paracentesis having proved ineffectual in the left eye, which was still absolutely blind, iridectomy was also performed on this eye on the second day. This was also successful. The ophthalmoscopic symptoms were equally favourable, for on the third day after the second operation the retinal arteries were found to be normal, as also the veins, excepting a slight irregularity in their fulness. In three months, the sight was perfectly normal in each eye. Rothmund mentions two similar cases of ischæmia of the retina, in which paracentesis proved effectual, having, however, to be repeated in the second case.

11.—EMBOLISM OF THE CENTRAL ARTERY OF THE RETINA (Plate IV, Fig. 8).

The first case of embolism of the central artery of the retina leading to sudden and complete blindness was diagnosed by Von Graefe.*

The patient generally complains that the loss of sight upon the affected eye has taken place very suddenly, and is so great, that he can hardly distinguish between light and dark. On ophthalmoscopic examination, we notice very marked and characteristic appearances. The optic disc is very blanched but transparent, the vessels upon it being greatly attenuated. The retinal arteries are extremely thin, resembling small narrow threads, and are perhaps, to a greater or less extent, bloodless and changed here and there, for the whole or a certain part of their course, into white bands. Sometimes small red plugs or coagula may be noticed in the vessels. The retinal veins are also thinner, irregularly filled, and showing in some of the branches a complete emptiness for a part of their course, alternating with a column of blood or plugs of coagula. In Von Graefe's case a very peculiar condition was observed in a vein, viz., a very irregular movement of the column of blood, which moved with a sudden start towards the optic nerve, and then again became stationary; the alternatingly full and empty portions of the vessels remaining as before, excepting that their situation was changed. The next change is observed in the region of the yellow spot, which some days after the outset of the affection becomes opaque and covered by a faint bluish-grey or bluish-

* "Archiv. f. Ophth.," v, 1, 136.

green film, hiding the subjacent choroid, and gradually shading off at the periphery into the normal retina. This opacity is due to a serous infiltration of the retina at this point, and varies considerably in extent, reaching or even exceeding somewhat the size of the optic disc. It is generally ovoid in shape, with its longest diameter horizontal. It often shows a somewhat mottled appearance, being studded with small, grey granules. In the centre of the film, at the foramen centrale, is noticed a marked, bright cherry-red spot, which is not an extravasation of blood, as is often erroneously supposed, but is due, as Liebreich has pointed out, to the fact that at this point the retina is transparent, permitting the choroid to shine through, which assumes a redder tinge on account of the contrast with the surrounding greyish-blue opacity. The vessels running towards the yellow spot are often hyperæmic, so that their finer branchlets can be distinctly traced, and they often also show well-marked blood coagula.

The following case which came under my care at King's College Hospital illustrates well the appearances presented by embolism of the central artery of the retina :—

W. P., æt. 42, married, has always been in good health. About the beginning of April, 1867, he had a severe cold, which kept him in bed. On the second morning he noticed that the right eye was somewhat inflamed, and smarted, and on trying his sight he found that it was much affected. No more reliable history could be obtained. On May 16th he first came under my care. The right eye looks healthy, the pupil somewhat dilated and sluggish, refracting media clear. He is, however, totally blind, being hardly able to distinguish between light and dark. The ophthalmoscope shows that it is a case of embolism of the central artery of the retina. The optic disc is very pale, but transparent, the vessels, on its expanse, much attenuated and anæmic, so that it is somewhat difficult to trace their exact relations to each other. The outline of the disc and the retina in its vicinity are somewhat hazy. This film-like opacity increases in density and extent towards the region of the yellow spot, where it assumes a greyish-blue tint. The vessels running from the disc towards the yellow spot are numerous and somewhat hyperæmic, so that their terminal branches are very observable. In some, the blood current is distinctly interrupted, small red portions of vessel alternating with bloodless ones. I could not, however, on the closest examination, detect any jerky movement of the blood in these vessels; and as the red portions of the vessel did not appreciately alter their position during several weeks, I attributed them to blood coagula in the vessel. In the centre of the yellow spot is noticed a red, cherry-coloured irregular patch, which evidently depends upon the contrast in colour above referred to. Another smaller red patch is observed somewhat above and to its outer

side, resembling it in appearance, but being due to an effusion of blood. The whole aspect of this region, otherwise resembles very closely the appearance presented in the figure illustrating embolism of the central artery of the retina (Plate iv, fig. 8). The appearance of the retinal vessels is also very characteristic of this affection. Thus, from the lower side of the disc a small artery emerges, which is perfectly white in the disc and for some portion of its course over the retina (about twice the diameter of the disc), where it becomes again filled with blood. It looks, indeed, like a small white band. The accompanying vein is filled for a short distance from the disc, but at its first division there is a well-marked plug, and on the peripheral side of this, it is bloodless for a considerable portion of its course. Some of the other vessels in the vicinity of the disc show marked irregularities in their fulness, being, at certain points, hardly apparent or resembling small white threads, and at others well filled. These irregularities extended even to some of the peripheral branches. The left eye was quite normal. The heart was examined by Dr. Duffin, and found healthy. Although the patient's health is good, he appears suffering from some cerebral affection, as he is very forgetful, inconsequent, and somewhat wandering.

The case was kept under constant observation, and examined with the ophthalmoscope at intervals of a few days. Although the state of some of the blood-vessels changed somewhat, no marked alteration in the condition of things took place until the beginning of June, when the disc became more vascular, but its outline more indistinct, the retina at its margin, more especially upwards, looking œdematous. The vitreous humour became clouded, showing diffuse and floating opacities. At the lower portion of the fundus, small circumscribed specks of disseminated choroiditis were observed. In about a fortnight two large extravasations of blood appeared, one at the periphery of the fundus, the other running from the disc to the upper part of the yellow spot. They were evidently situated in the retina, just beneath the internal elastic lamina, as they covered the retinal vessels, and were uniform and smooth, without any striated appearance. At the commencement of July he was sent to Walton Convalescent Hospital. In the beginning of October his eye presented the following appearance, which it has retained more or less up to the present time. The vitreous is quite clear, the retina is undergoing transparent atrophy, the vessels are extremely small, and the retina is so thin that the epithelium of the choroid can be abnormally well seen. The inner half of the disc is covered by a thick network of blood-vessels (collateral circulation), which are so closely arranged that they present the appearance of an extravasation of blood, but on pressing upon the eye, they can be emptied, and be observed to re-fill when the pressure is relaxed. The extravasation

running from the disc to the yellow spot has disappeared, but that at the upper part of the fundus, though much smaller, is yet very apparent.

12.—HYPERÆSTHESIA OF THE RETINA.

Before the discovery of the ophthalmoscope, this affection was generally mistaken for inflammation of the retina, and we still meet with this error in some books treating of diseases of the eye. Such a mistake is a grave one, as it has led to a most injudicious and improper treatment of cases of hyperæsthesia retinæ, viz., by antiphlogistics, depletion, salivation, etc., thus increasing the severity and the duration of the symptoms.

Hyperæsthesia of the retina generally occurs in young persons, especially in females of a very excitable, nervous, and hysterical temperament, and in delicate, feeble health. It is sometimes due to an accident, shock, or a blow on the eye, etc., to exposure to very bright light, such as a flash of lightning, or to prolonged use of the eyes by strong artificial light. It may also occur without any apparent cause, except some derangement in the general health, more especially of the uterine functions.

On examining the eye, we find that there is intense photophobia, together with lachrymation, accompanied perhaps by a spasmodic twitching of the eyelids, or even a severe spasm of the orbicularis muscle. There is often great ciliary neuralgia, the pain extending to the face and the corresponding side of the head. The retina is extremely irritable, and the patient is greatly troubled by photopsies, such as bright, dazzling stars, coloured rings, etc., before the eyes, these photopsies being either spontaneous, or very easily producible by the slightest pressure upon the eyeball. Moreover the retina retains impressions for an abnormally long period, so that if any object is regarded, its image is retained for a very appreciable space of time. The eye itself will be found quite normal, the refracting media clear, the fundus perfectly healthy. The sight is but very slightly, if at all impaired, and is always greatly improved when the intensity of the light is diminished by the use of blue glasses, with which the patient will be able to read the smallest print. But whilst the central vision is perfect, the peripheral portion of the retina is anæsthetic, so that the field of vision, as is pointed out by Von Graefe, is markedly concentrically contracted. This fact might easily mislead a superficial observer to mistake it for a case of commencing amaurosis. The phosphènes* are, however, very marked in the portion of the retina which is anæsthetic, and are very readily produced by slight pressure upon the eyeball.

* The luminous rings which appear when the eyeball is firmly pressed.

The photophobia is often most severe, the patient being quite unable to face the light, or it comes on directly he attempts to use his eyes in reading, etc. It is always greatly relieved by the use of dark blue glasses. Mooren* mentions an extraordinary case of hyperæsthesia, in which the sensibility of the retina was so greatly increased, that the patient could read large print in the dark, in which a normal eye could not distinguish a letter. It was indeed a true case of nyctalopia. All these symptoms had become developed in a very short time. The treatment must consist chiefly in improving the general health, encouraging the patient, and diminishing the excitability of the retina. If the photophobia is severe, it may be necessary to confine the patient in complete darkness for six or eight days, and then gradually to accustom him to an increasing amount of light (Von Graefe). In the open air he should wear blue glasses. Internally, tonics should be administered, more especially preparations of zinc or steel, according to the special indications of individual cases. Zinc (either the valerianate or lactate) should be given in increasing doses, commencing with ½ to 1 grain twice a day, and gradually increasing this to 4 or even 5 grains. Subsequently, steel and quinine will be found very useful. Great care must be taken not to weaken the patient, especially by depletion. Although the artificial leech may be occasionally employed with benefit, it must be used with extreme care, otherwise it is apt to increase the severity of the symptoms, and retard the cure. I prefer dry cupping, either at the temple or the back of the neck. If the patient's spirits are much depressed, everything must be done to cheer him up and encourage him in believing in a speedy cure.

13.—TUMOURS OF THE RETINA.

According to Virchow† only two kinds of tumour occur in the retina, viz., *Glioma* and *Glio-sarcoma*. The intra-ocular tumour generally known as medullary cancer, encephaloid tumour, or fungus hæmatodes, is in reality, as Virchow has shown, developed from the retina. As it originates in the interstitial connective tissue (*neuroglia*) of the retina, and in this, as well as in its minute structure, closely resembles cerebral glioma, he has termed it *Glioma retinæ*, a name which has been already extensively adopted by British and Foreign pathologists.

The symptoms presented by the disease are generally very marked and characteristic. In the earlier stages, the external appearance of the eye is quite healthy and normal, there being, as a rule, no pain or

* "Ophthalmiatrische Beobachtungen," p. 271.

† "Die krankhaften Geschwülste," ii, 159.

symptoms of inflammation. But the sight is lost. The pupil is more or less widely dilated, and, shining from the bottom of the eye, is noticed a bright, glistening, yellowish-white reflection, which is often already noticeable at some little distance. On account of this yellow luminous reflex, this condition was formerly called "amaurotic cat's-eye." With the ophthalmoscope, the details of the growth can be beautifully seen. At the outset, the disease is limited to one portion of the retina, which becomes opaque, thickened, and somewhat mottled in appearance. The morbid growth gradually increases in extent and prominence, until it protrudes in the form of a yellowish-white nodulated mass into the vitreous humour. According to Virchow, the increase in the size of the tumour is partly due to the growth of the original mass, and partly to the formation of new foci of disease in its vicinity; and hence, on becoming larger, the growth assumes a lobulated appearance, certain portions of the retina being thicker than others. On the expanse of the tumour, we can generally observe with the ophthalmoscope numerous blood-vessels, which anastomose very freely with each other, and between these vessels are often noticed small effusions of blood. Indeed, these tumours are very vascular, and this fact, as Hirschberg* points out, is not only valuable in a diagnostic point of view, but tends to explain the rapidly developed glaucomatous symptoms and the temporary atrophy of the eyeball, which are often noticed in eyes affected with glioma.

The above are the symptoms generally presented by the disease when the surgeon first sees it, for as it occurs in the vast majority of cases in children, little heed is paid to the condition of the sight, and the affection is unnoticed until the attention of the parents is arrested by the bright yellow reflex coming from the bottom of the eye, and only then is medical aid sought. Hence we but seldom enjoy the opportunity of seeing the earliest development of the disease, and of following its gradual progress. In the very earliest stage, there are noticed, according to Von Graefe,† numerous small white patches, of varying size, which lie partly behind the retinal vessels, and partly pervade the retina as far as its inner surface, and then give rise, already at a very early stage, to a marked elevation. They may be distinguished from inflammatory infiltrations of the retina by their circular, sharply defined outline, the periphery of such figures not being broken up into punctated or striated opacities, as occurs in the former case. Moreover, they are of a decidedly white tint, and not of the creamy

* "A. f. O.," xiv, 2, 50. Both Dr. Hirschberg's and Von Graefe's articles upon Intra-ocular Tumours in this vol. of the Archiv. are of the greatest interest and importance, as they afford information and explanations upon many points which were hitherto still in doubt.

† Ib., p. 129.

yellow hue met with in inflammatory infiltrations. These small patches soon coalesce, and increase in size and thickness, but spread at first only along the surface. But as the disease advances, the posterior surface of the retina bulges forward (Hirschberg),* the little individual nodules which are thus formed, coalesce and give rise at a circumscribed spot to a lobulated cauliflower growth of the external surface of the retina (glioma retinæ circumscriptum tuberosum). At this period, there is already noticed a considerable dissemination of secondary foci. The retina is generally already partially detached at a very early stage, and the tension of the eye mostly somewhat increased. The detachment is often peculiarly defined, perhaps forming an acute angle, at whose apex a white patch may be noticed (Graefe).† The peculiar reflex and the details of the tumour are rendered still more marked and conspicuous on the retina becoming detached. When the disease is more advanced, and the whole retina is implicated in it and thickened, the detachment is generally complete and funnel-shaped, the apex being situated at the optic nerve, and the base at the ora serrata. As a rule, the morbid growth can be very readily detached from the choroid, but in some cases the retina is firmly glued to the latter (Virchow),‡ the tumour gradually filling the eyeball and causing the vitreous humour to shrink and become absorbed to a corresponding degree. The retina in such cases becomes folded inwards, so that the different folds are super-imposed upon each other.

When the growth enlarges still more, the lens and iris become pushed forward towards the cornea, the lens often becoming opaque and partially or even completely absorbed. The intra-ocular tension, which has generally been already for some length of time augmented, becomes now very markedly increased, and this may be accompanied by more or less acute inflammatory symptoms and severe pain. The state of the eye-tension is of consequence with regard to the differential diagnosis between an intra-ocular tumour and a simple detachment of the retina, for in the latter case it is as a rule always diminished. As glioma occurs in the vast majority of cases in young children, in whom glaucoma is hardly ever met with as a primary affection, an increase in the intra-ocular tension (other causes for this being absent) should at once arouse our suspicions (Graefe).§

When the tumour has filled the cavity of the eyeball, the latter generally soon gives way at some point. The perforation takes place at the cornea or near its margin, or at the anterior portion of the sclerotic, and but seldom at its posterior part. Perforation at the latter situation, and the extension of the growth into the orbit must be suspected if the movements of the eyeball are markedly curtailed,

* "A. f. O.," xiv, 2, p. 88.
† Ibid., p. 129.
‡ Loc. cit., p. 162.
§ "A. f. O.," xiv, 2, 130.

and the eye protruded. When the tumour has once burst through the coats of the eyeball its growth is very rapid. It sprouts forth between the eyelids, which are greatly swollen and often much everted, and acquires, from its exposure to the atmosphere and external irritants, a dusky-red, fleshy, and very vascular appearance, and hence the name "fungus hæmatodes." From it there exudes a sanious fluid, which becomes crusted on its surface, and if any excoriation of the latter occurs, the tumour bleeds very freely.

Sometimes, however, the disease does not run so regular a course, for after the tumour has attained a certain size within the eye, symptoms of irido-choroiditis supervene, the pupil becomes blocked up with lymph, the eye-tension falls below the normal standard, and the disease for a time assumes the character of an irido-choroiditis, passing on to temporary atrophy of the eyeball. The latter is generally due to suppurative choroiditis, but may, in rare instances, be also caused by suppuration of the cornea (Von Graefe). Together with this atrophied condition of the eyeball, there are often very intense, spontaneous paroxysms of pain, the eye itself being but slightly, if at all sensitive to the touch. Whereas, in the atrophy dependent upon irido-cyclitis the reverse obtains. But the most intense and sudden pain occurs if intra-ocular hæmorrhage takes place. At a subsequent period, the symptoms of an intra-ocular tumour again manifest themselves in the partially atrophied eyeball, the tension increases, the tumour augments in size, the cornea or sclerotic gives way, and a rapidly increasing morbid growth sprouts forth.

Virchow considers that glioma commences in the external layers of the retina, more especially the connective tissue elements of the granular layers. Schweigger* thought it probable that it originated in the internal granular layer, and Hirschberg† has succeeded in proving the truth of this supposition, having found in one case that the disease commenced in a proliferation of the cells in the inner granular layer of the retina. At a more advanced stage of the disease the retinal tissues often disappear almost entirely, so that it is then quite impossible to trace its origin.‡ The membrana limitans interna and the innermost portion of the trabecular connective tissue fibres (Stützfasern), seem to resist the longest, and may, according to Virchow, be often traced within the tumour, and seen to divide it into segments.

The principal masses of tumour are composed of aggregations of nuclei and cells. The latter are round or oval, small in size, and occa-

* "A. f. O.," vi, 2, 326. † Ib., xiv, 2, 40.

‡ For further information upon the anatomical characters of these tumours, I would also refer the reader to Mr. Hulke's valuable papers on "Intra-ocular Cancer," "R. L. O. H. Rep.," iii, iv, and v.

sionally have small prolongations. They are sometimes arranged in rows, and contain one or more nuclei. The free nuclei are small and round, and, according to Virchow, correspond exactly to the little light-refracting nuclei of the granular layer. The inter-cellular substance is so scanty that it can be hardly distinguished, but on adding chromic acid it becomes finely granular. In the soft variety of the tumour the cells are larger than in the hard, and in the latter the cellular tissue is fibrillated. The tumour may subsequently undergo fatty and chalky degeneration. Sometimes the cells augment in size or assume a spindle shape, and the nuclei increase in number, and then the morbid growth must be considered to be of a sarcomatous nature. Indeed, Virchow has shown that the tumour sometimes assumes a mixed character, one part resembling glioma in structure, another sarcoma, so that it may be termed "glio-sarcoma," and he thinks this to be far more dangerous in character than simple glioma.*

Iwanoff† regards the small outgrowths from the membrana limitans interna observed in cases of retinitis, and which sprout into the vitreous humour, in the light of small gliomata. They do not, however, appear to have anything in common with glioma. Virchow thinks that a sharp line of demarcation cannot be drawn between glioma and inflammatory neoplasms of the retina, as the former may in its course be accompanied by inflammatory symptoms. He considers "that the name glioma is apposite, as the neo-plastic formation, even if of an inflammatory nature, assumes a more permanent character and tumour-like form, it being, however, of course, always understood that its structure must be composed of homologous elements. A suppurative retinitis can never give rise to glioma."‡

Von Graefe, however, does not believe that glioma is due to an inflammatory hyperplasia, and thinks that observations which have been advanced in support of such a view, have depended either upon the fact that the sequelæ of intra-ocular inflammations, *e.g.*, plastic inflammations of the vitreous humour, or subretinal deposits, have been mistaken for gliomas; or that the first period of the tumour has been completely overlooked, and the consecutive inflammatory complications were supposed to form the origin of the disease. Moreover, as he points out, clinical observation shows a marked difference between the first period of glioma and an inflammatory hyperplasia.

The question whether glioma is to be regarded as a malignant disease is still considered doubtful by some observers. Von Graefe,§ however, now speaks in the most decided manner as to its malignancy, and thinks that this increases with the length of its existence and the increase of its development. Glioma differs, however, from sarcomatous

* "Krankhafte Geschwülste," ii, 167.
† "A. f. O.," xi, 1, 143.
‡ Loc. cit., 159.
§ Loc. cit., xiv, 2, 110.

tumours of the choroid, etc., in this, that it does not appear secondarily to affect distant organs, being only prone to local infection.* Thus Rindfleish† found in a case of glioma that there was a small nodule of tumour between the choroid and sclerotic, and that similar products existed in the optic nerve. Hulke‡ mentions a case in which the retinal glioma in each eye extended above the optic nerves within the skull, and in which he distinctly observed the growth of the glioma in the connective tissue separating the bundles of nerve fibres in the nerve-trunk, in front of the optic commissure. The propagation of the disease from the retina occurs in two directions—(1) towards the choroid; (2) to the optic nerve; and the disease of the latter is, according to Hirschberg, more frequent than has been generally supposed. Out of the eight cases which he reports,§ the optic nerve was implicated in six, and in most to a very considerable extent. In this tendency to extension of the disease to the optic nerve and thence to the brain, is to be sought the extreme danger of retinal glioma, for a secondary tumour of the brain may be formed, or *encephalitis* ensue. Hence the necessity of excising the eye at the earliest opportunity, and dividing the optic nerve as far back as possible. The first retro-ocular extension of the disease is very difficult to diagnose, but Von Graefe‖ has found that when degeneration of the optic nerve has ensued, the eyeball becomes slightly more prominent, and its lateral movements somewhat curtailed. There is also more resistance felt, if the eye is pressed back into the orbit, and the little furrow between the eyelids and wall of the orbit is obliterated. When the orbital adipose tissue is once implicated, the progress of the disease is very rapid.

The *causes* of glioma are often quite obscure; but in some cases it is clearly due to a traumatic origin. It occurs far more frequently in children than in adults, and generally between the ages of two and ten. It may, according to Travers, be sometimes congenital, he having extirpated such an eye in a child of eight months old. Sometimes both eyes are affected with the disease, and in such cases Graefe thinks that we must not consider the affection as having been propagated from one eye to the other by way of the chiasma, for in the cases of Saunders and Hayes, reported by Wardrop, the optic nerve of the secondarily affected eye was found to be quite normal. Nor does the idea of a dyscrasia hold good, on account of the immunity of other organs from metastatic or secondary gliomata. Von Graefe rather seeks the explanation in the peculiar symmetry which exists between the two eyes, the influence

* At the Heidelberg Ophthalmological Congress of this year, Knapp, however, narrated a case of glioma of the retina in which there were found, after death, secondary gliomata in the liver, lung, and the diploe of the skull.

† "Kl. Monatsbl.," 1863, 341.

‡ "R. L. O. H. Rep.," v, 172.

§ "A. f. O.," xiv, 2, 56.

‖ "A. f. O.," xvi, 2, 137.

of which is so often and very markedly illustrated in inflammatory diseases of the eye. In some instances, glioma appears to be hereditary, and occurs in several members of the same family. Thus Lerche mentions four children being affected with it out of a family of seven; Sichel saw it in four children of the same mother. The children affected with glioma are often of a peculiarly fair and beautiful complexion, although perhaps somewhat delicate in constitution.

The *prognosis* of the disease is always extremely grave, as the affection is very apt to recur, and we have no guarantee that the optic nerve is not already implicated, even although the intra-ocular tumour may still be very small. For this reason, the immediate removal of the eye should be very strongly urged as soon as the diagnosis of glioma is established, for this is the only chance of saving the patient's life. The opinion that the disease may become spontaneously arrested, or may retrograde, is according to Von Graefe quite erroneous. For he* has found that the affection progresses steadily and surely, indeed with greater steadiness than sarcoma of the choroid, and that, reckoning from the earliest appearance of the disease, when the tumour still only occupies a small portion of the eye, from one to three years elapse before its extra-ocular development becomes manifest. In those cases in which this occurs at very early age, *e.g.*, at the termination of the first year of the child's life, he considers it probable that the glioma was congenital.

It has been urged by some surgeons, that the extirpation of the eye is useless, as the disease is sure quickly to recur and end fatally. But cases are on record in which several years have elapsed after the operation, without a return of the disease.† The rule is, therefore, to remove the eye at the earliest possible period, so that there may be the chance of the optic nerve being still unaffected.

The chief danger is, that the disease should extend to the brain, or that the tumour, increasing more and more in size, should perforate the eyeball, and from the severe pain, the great enlargement of the tumour, the occurrence of hæmorrhage, etc., undermine the patient's health. Cerebral complications should be suspected, if the patient becomes drowsy, languid, and stupid, lying about and sleeping a great deal, if there is great and constant headache, or if symptoms of paralysis manifest themselves. But even when the tumour has burst through the coats of the eyeball, and is fungating extensively, its removal is advisable, more especially if there is much pain and hæmorrhage. It must, moreover, be remembered that it is the only chance of prolonging life, and of alleviating the dreadful sufferings of the patient. In excising the eye, the optic nerve should be divided

* "A. f. O.," xiv, 2, 135.

† Vide "R. L. O. H. Rep.," iv, 87; also V. Graefe's Article, loc. cit.

very far back, in order, if possible, to remove all the disease. Von Graefe is in the habit, in such cases, of passing a neurotome (after he has divided the conjunctiva) along the outer wall of the orbit to the bottom of the latter, then pulling the eye as far forward as possible, and dividing the optic nerve quite close to the optic foramen; he then proceeds with the excision in the usual manner. If the disease has extended to the tissue of the orbit, it will be advisable to apply the chloride of zinc paste after the removal of the eyeball, so as to destroy, if possible, all the morbid tissue.

14.—ATROPHY OF THE RETINA.

Atrophy of the retina is met with as the final stage of many of the intra-ocular inflammations, of glaucoma, and cerebral amaurosis. It may be partial and confined to certain portions or elements of the retina, or complete, the whole retina becoming greatly attenuated and changed into a thin, transparent, fibrillar connective tissue, which is so delicate that the details of the choroid can be seen with unusual distinctness, and the faint, normal reflex of the retina is entirely absent. The retinal vessels become excessively attenuated, and at last changed into thin streaks or lines, or disappear more or less completely. The optic nerve at the same time shows all the symptoms of advanced degeneration (perhaps glaucomatous excavation) and atrophy. In the retinal atrophy which ensues upon inflammation, the retina is generally for a time more or less opaque, and studded perhaps here and there with patches of exudation, but subsequently it becomes more and more thinned and transparent. Deposits of pigment and cholesterine are sometimes noticed in the atrophied tissue.

15.—CYSTS IN THE RETINA.

These may occur in varying number, and differ in size from a small pea to a hazel nut. On a section of the globe, they appear to the naked eye as small transparent vesicles, studded over the outer portion of the retina. They are probably produced by the development of colloid material in the external granular layer, and by a proliferation of the radiating trabecular fibres (Iwanoff).* The latter form the outer and lateral walls of the cyst, the internal wall being formed by the internal layers of the retina. Mr. Vernon has met with cysts in the retina in four instances, which will be fully reported in "R. L. O. H. Rep.," vi, 3.

* "Kl. M.," 1864, p. 417.

Chapter IX.

DISEASES OF THE OPTIC NERVE.

1.—INFLAMMATION OF THE OPTIC NERVE (OPTIC NEURITIS, NEURO-RETINITIS) Plate VI, Figs. 13 and 14.

Inflammation of the optic nerve is distinguished by the following ophthalmoscopic symptoms. At the outset, there exists a certain degree of hyperæmia and œdema of the optic nerve entrance and of the retina in its vicinity, so that the disc appears abnormally red and somewhat opaque and swollen, its outline being hazy and indistinct. In some cases the neuritis is partial, the serous infiltration and swelling being at first chiefly or entirely confined to one portion of the disc. But the inflammatory symptoms soon become more marked. The optic disc becomes enlarged, swollen, and prominent, and its outline irregular and indistinct (from the exudation of lymph covering the choroidal ring), so that it passes over into the retina without any sharp line of demarcation. Moreover, the smooth, transparent, delicate pink appearance of the disc is lost, and it assumes an opaque reddish-grey tint; the effusion of lymph into the optic nerve causing it to appear striated and "woolly." On account of the great swelling and prominence of the disc, it can be seen at some little distance in the erect image; the refraction having in fact become hypermetropic. The inflammation generally extends more or less on to the retina in the vicinity of the disc, rendering the former hazy and indistinct. The appearance of the retinal vessels is also markedly changed. The veins are much dilated, dark, and often very tortuous, dipping here and there into the infiltration, so as to be more or less covered and hidden by it, and interrupted in their course. The arteries may, on the other hand, be so much diminished in calibre as to be hardly distinguishable. On account of the development of numerous small vessels on the disc, the latter is very red and vascular, its edge looking perhaps as if it were covered by a reddish fringe. On and around the disc, are scattered numerous striated blood extravasations, of varying size and shape. On using a high magnifying power, we are often able to make out that the apparent hæmorrhagic effusions in reality consist of minute, closely packed, newly

developed blood-vessels. The inflammatory swelling and exudation may, however, be so considerable that the vessels are completely hidden on the disc, and can only be followed up to its margin, and only here and there can the outline of a vessel be faintly traced on its expanse. Although cases of retinitis, more especially the parenchymatous and nephritic, are generally accompanied by a certain degree of inflammation of the optic nerve, I shall here confine myself to the description of optic neuritis as an idiopathic disease, and not as a part symptom of inflammation of the retina.

We may distinguish two principal forms of optic neuritis, viz., 1. The "*engorged papilla*,"* (Stauung's papille of V. Graefe), in which the inflammation commences in the papilla (optic disc) and extends upwards along the trunk of the nerve, but generally stopping short at the lamina cribrosa. Hence it might very well be termed "ascending" neuritis.

2. The "descending neuritis," in which the inflammation commences extra-ocularly and extends downwards to the optic disc.

The engorged papilla is almost always due to an impediment in the circulation within the nerve, which may be caused by an intra-orbital tumour pressing upon the nerve, or by an increase in the intra-cranial pressure and consequent retardation and impediment of the circulation in the ophthalmic vein. This mechanical obstruction to the circulation in the central vessels of the retina, is soon followed by serous infiltration of the optic nerve, and subsequently by inflammatory proliferation of its connective tissue elements. Hence, there is a considerable swelling of the nerve, and as the firm scleral ring cannot yield, but closely embraces it, the nerve is here more or less strangulated, which impedes the circulation still more. The irritation produced by this compression is soon followed by inflammation.

Von Graefe† was the first to recognise the connection between optic neuritis and affections of the brain, as well as certain morbid conditions of the orbit. According to him, the engorged papilla is chiefly distinguished by great, but perhaps partial, swelling and prominence of the disc, numerous and considerable hæmorrhages on and around the papilla, and great dilatation, darkness, and tortuosity of the veins; the arteries being on the contrary very small, attenuated, and often almost bloodless. The inflammatory infiltration of the retina is confined to the close vicinity of the nerve entrance. In the *descending* neuritis the tissue of the nerve is more diffusely clouded, but the swelling and redness of the disc are much less, and its tint is of a faint grey. The

* The "ischæmia of the disc" of Dr. Allbutt, whose interesting Lectures on Optic Neuritis, "Med. Times and Gazette," 1868, I would strongly recommend to the attention of the reader.

† "A. f. O.," vii, 2, 58.

opacity of the retina is more diffuse and extensive, and reaches deeper into its structure. The retinal arteries are considerably diminished in calibre, but the veins are less dilated and tortuous than in the engorged papilla. On account of the more extensive implication of the retina, as well as the appearance of white patches on it, the disease sometimes assumes a certain similarity to nephritic retinitis, and might even be mistaken for it by a superficial careful observer. The chief points in the differential diagnosis of these two diseases have been already mentioned in the article upon the "Retinitis Albuminurica" (page 338). On account of its involving so considerable a portion of the retina, this form might be called neuro-retinitis.

It must be stated, however, that the distinctive characters of these two forms of neuritis are not often so strongly marked, and also that the one may pass over into the other, and thus give rise to a mixed group of ophthalmoscopic appearances. Sometimes in the descending neuritis, the opacity, swelling, and redness are chiefly confined to the periphery of the disc, the central portion being relatively but little involved.

In some cases of optic neuritis in children, Mr. Hutchinson has met with a peculiar appearance of the retina in the region of the yellow spot, viz., a group of highly refractive globules, resembling at the first glance a cluster of spider's eggs; these groups are almost symmetrical and very definite.*

When the inflammatory symptoms subside, the morbid products become gradually absorbed, the swelling and prominence of the papilla diminish, and it gradually becomes flat; at the same time assuming a paler tint, the neighbouring retina remaining perhaps a little clouded. The retinal veins diminish in size and tortuosity, the blood extravasations become absorbed, the opacity of the retina disappears, and the disc may gradually regain a more normal appearance, and vision may be restored. As the swelling and infiltration of the nerve are far more considerable in the engorged papilla than in the descending neuritis, the absorption is also less rapid than in the latter. In severe cases recovery is, however, the exception not the rule, for the nerve generally becomes atrophied. Even in those cases in which vision is restored, the disc remains somewhat opaque and of a palish creamy tint. We are, however, generally able for a long time to distinguish the atrophy ensuing upon optic neuritis, from that which is met with in cerebral or cerebro-spinal amaurosis, and which is termed simple or progressive atrophy. In the atrophy consecutive upon optic neuritis, the outline of the disc remains somewhat hazy and indistinct, and does not show the clearly cut, sharply defined contour so characteristic of the other form. The disc may also remain somewhat swollen, and its

* "Ophth. Hosp. Rep.," v, 4, 308.

whiteness lacks transparency and lustre, being dull and of an opaque and somewhat creamy tint. The retinal veins, moreover, retain for a long time a certain degree of dilatation and tortuosity, but as time passes on these differences gradually fade away, and finally the disc assumes the appearance of that met with in simple progressive atrophy. When the infiltrations into the optic nerve and retina become absorbed, we often notice a slight thinning and atrophy of the choroid at these points.

The disease generally affects both eyes (especially where it is due to cerebral causes), either simultaneously or at a very short interval, being, according to Bouchut, most marked in the eye corresponding to the hemisphere which is most severely involved. If the cause is intra-orbital, it is, of course, quite different. I have, however, met with an instance in which the disease (the cause of which could not even be surmised) remained entirely confined to one eye.

The sight is often greatly impaired. Sometimes, the loss of vision is very sudden, the patient becoming perhaps so blind within a few hours or days, as to be quite unable to distinguish between light and dark. But the impairment of vision does not necessarily correspond to the striking morbid alterations presented by the disease; indeed, the sight may even be perfectly normal in cases of marked optic neuritis.

I have at the present time a case of monocular neuritis under my care, in which the acuity of vision has remained perfectly normal throughout, and a short time ago I saw two cases of optic neuritis with Dr. Hughlings Jackson, in each of which the patient could read No. 1 of Jäger; indeed, Dr. Jackson assures me that such cases are by no means of unfrequent occurrence, but are not often observed by the oculist, simply because the latter is only consulted when the sight is beginning to fail. Whereas, the physician is called in on account of some other symptom, he suspects cerebral disease, examines the eyes with the ophthalmoscope, discovers optic neuritis, and yet finds that the sight is unimpaired. Mauthner* narrates an interesting case, in which a patient affected with optic neuritis retained a normal acuteness of vision up to the time of his death (which was sudden). The post-mortem examination revealed the existence of interstitial optic neuritis, but the retina was healthy quite up to the optic nerve.

The field of vision is generally also more or less affected, and this is a point of much prognostic importance, for according to Von Graefe,† we almost always find that in those cases of optic neuritis in which the field of vision is contracted, at least a partial atrophy of the optic nerve and retina ensues. The pupil is, as a rule, dilated and sluggish, or even perhaps almost immovable. But if the sight is good, it may be hardly,

* "Lehrbuch der Ophthalmoscopie," p. 293.

† "Kl. Monatsbl.," p. 9, 1863.

if at all, affected. The patient is often much troubled with subjective appearances of light (photopsies and chromopsies) which, from their fantastic shapes and constant presence, may prove a source of great distress and anxiety. If the neuritis is due to a cerebral cause, it is generally accompanied by more or less marked symptoms of brain disease, such as loss of memory, giddiness, vomiting, impairment of the sense of smell, taste, or hearing, epileptoid fits, paralytic affections, severe headache, etc. The cephalalgia is often very great and protracted, the patient being, perhaps, unable to localise it exactly, as it extends over the whole head. Von Graefe calls attention to the fact that in cases of cerebral tumour, the position of the latter may sometimes be ascertained by the acute pain produced by sharply tapping with the finger the corresponding portion of the cranium, which also temporarily increases the severity of the general headache.

Causes.—The engorged papilla may be caused by morbid processes within the orbit, which give rise to great protrusion of the eye, or pressure upon the optic nerve, and consequently impediment of the circulation. Amongst such causes, must be especially instanced tumours, and inflammation of the periosteum or the cellular tissue of the orbit. In such cases, we often enjoy an opportunity of watching how the symptoms of optic neuritis disappear, and the sight becomes restored, when the tumour has been removed, or the inflammation has subsided and the eye returned to its normal position.

This form of optic neuritis is, moreover, very frequently produced by certain cerebral affections which exert a direct pressure upon the cavernous sinus, and thus impede the venous circulation, or effect this by an increase in the pressure of the intra-cranial circulation (*e.g.*, in hydrocephalus). Amongst these causes, cerebral tumours must be especially mentioned, being situated, perhaps, at the base of the brain, or in the hemispheres. This impediment of the circulation in the ophthalmic vein, gives rise to mechanical congestion of the papilla, which, as has been already mentioned, is soon followed by serous infiltration, and subsequently by inflammatory proliferation of the connective tissue elements of the optic nerve. But, as was originally pointed out by Von Graefe, the obstruction in the cavernous sinus alone would not suffice for this, but the effect of the firm, unyielding sclerotic ring in increasing any tendency to stasis in the circulation must also be taken into account. Cases of engorged papilla, in which cerebral tumours were found after death, have been recorded by Von Graefe* and others. But although this form of optic neuritis will lead us to suspect the presence of a cerebral tumour, it is by no means always diagnostic of it, as such tumours may in some cases produce simple atrophy of the optic nerve by direct pressure upon the latter. Or they may set up

* "Kl. Monatsbl.," p. 9, 1863; also "A. f. O.," vii, 2, 58.

inflammation of the meninges, which, extending to the optic nerve, gives rise to descending neuritis. The latter disease is, therefore, sometimes met with in cases of meningitis or arachnitis, in which the inflammation extends to the optic nerve, and travels down to the papilla and retina. We may, however, have mixed forms of neuritis, in which the phenomena presented by the disease are partly due to inflammation of the trunk of the nerve, and partly to obstruction in the circulation.

In one case of descending neuritis narrated by Von Graefe,* the circumscribed basilar meningitis was found to be caused by a peculiar entozoon, situated partly in the right hemisphere and partly at the base of the cranium.

Indeed, according to Dr. Hughlings Jackson,† who has made so many interesting and valuable researches upon the affections of the eye met with in cerebral diseases, optic neuritis may be produced by "coarse" disease of almost any part of the cerebrum, or cerebellum. This being so, I cannot do better than give the following summary of his experience and views, which appeared in the Hospital Reports of the "British Medical Journal" (March 28, 1868).

"We now report remarks on an acute condition of the optic nerves, which is followed by another kind of atrophy. It is to be kept in mind that the following remarks apply to cases of optic neuritis ('descending neuritis') seen in physicians' practice, and contain an accurate although a very brief statement of the chief conclusions at which Dr. Hughlings Jackson has arrived.—Optic neuritis from intracranial disease is always double, even when the disease giving rise to it is quite limited to a single cerebral hemisphere.—Not unfrequently one eye suffers more than the other, but, even when one cerebral hemisphere is alone diseased, there does not seem to be any constant relation betwixt the side of the brain affected and the eye more affected.—Although, in physicians' practice, the local disease causing optic neuritis is most often of the cerebral hemisphere, it may be in any part of either the cerebral or cerebellar hemispheres, or at the base of the skull.—Dr. Hughlings Jackson has not yet found optic neuritis, nor indeed optic atrophy of any kind, with disease limited to the optic thalamus, to the pons, or to the medulla oblongata.—The intracranial disease is almost always *coarse*.—The intracranial disease may be of many kinds, probably of any coarse kind. Thus Dr. Hughlings Jackson has found optic neuritis with tumour, with abscess, with blood-clot, with syphilitic "deposit," and with hydatid cyst, and all these of the cerebral hemisphere.—He has not found, with one exception, any but the most trifling unusual intra-ocular appearances in the chorea of children; a disease which he supposes (*see*

* "Kl. M.," 1864, p. 367.

† Vide Dr. Hughlings Jackson's contributions upon these subjects in the "R. L. O. H. Reports," "The London Hospital Reports," "Med. Times," etc.

'London Hospital Reports,' vol. i., 1864; 'Lancet,' Nov. 26th, 1864; 'Med. Times and Gazette,' Jan. 28th, 1865) to depend, at least frequently on plugging of small branches of the middle cerebral artery. Chorea in children does not at all events depend on *coarse* disease of the brain. From a superficial point of view it is, Dr. Hughlings Jackson thinks, somewhat striking that marked pathological changes in the optic discs are not unfrequently found with unilateral spasm, and with unilateral palsy, and scarcely ever with unilateral irregular movements. Choreiform movements are sometimes observed during recovery from the 'epileptic hemiplegia' which occasionally occurs with optic neuritis. However, the real association is not of optic neuritis with one-sided spasm or palsy, but with intracranial coarse disease, which coarse disease, when it is of one cerebral hemisphere, may produce both optic neuritis and the condition (corpus striatum neuritis?) on which the one-sided spasm, or palsy, or both depend. We should not, he thinks—making a mistake analogous to that the old astronomers made—consider amaurosis, from optic neuritis, or the atrophy which follows it, to be the centre point of a case around which all the other symptoms 'revolve;' but rather try to find the central disease—in physicians' practice often coarse disease of one cerebral hemisphere—to which each of the symptoms (headache, convulsions, amaurosis from optic neuritis), is equally subordinate. He thinks it is not warrantable, even when we find a lump of syphilitic disease in the cerebral hemisphere *post mortem*, to say that optic neuritis is 'caused by syphilis,' since just the same ophthalmoscopic appearances may occur with other sorts of 'foreign bodies' in the very same part of the brain. How it happens that a foreign body in the brain sometimes 'excites' changes about itself, and sometimes does not, is the subject of speculations of very different kinds into which we do not now enter.—Optic neuritis does not depend on *loss of function* of the part which the coarse disease destroys, as does loss of power of intellectual expression (aphasia).—Optic neuritis requires time for its production. Thus, although it occurs with blood-clot, it never, in Dr. Hughlings Jackson's experience at least, occurs with *recent* blood-clot.—When coarse disease of one cerebral hemisphere gives rise to headache, vomiting, unilateral spasm, amaurosis from optic neuritis; or, let us say, to the larger uproar called 'cerebral fever,' involving all or most of these, the probability is that there is but one idea throughout, viz., a 'foreign body,' and changes diffused from it in different directions, on which diffused changes the symptoms directly depend.—The most important clinical fact about optic neuritis is, that it may exist for a varying time—a few days, a few weeks, or a few months—without any apparent defect of sight. *It must be looked for* in every case of cerebral disease, at all events in every case of cerebral fever.—It is necessary to look for it in cases of loss of speech from

disease of the hemisphere. As implied in the foregoing, it is only likely to occur in cases where the speech defect depends on *coarse* disease, let us say on a large clot, and then only some time after the seizure. A blood-clot causes loss of speech as a destroyer of an elaborate structure, and subsequently optic neuritis in its character as a foreign body. However, optic neuritis is rarely associated with blood-clot."

But we sometimes meet with cases of optic neuritis, in which it is quite impossible to detect any cause or any impairment of the health, except perhaps some derangement of the uterine functions, *e.g.*, insufficiency of the catamenia. I have seen several instances of this kind in young and delicate females, who otherwise enjoyed perfect health. Such cases recover completely, if they are seen at the outset of the disease, and are actively and efficiently treated. Mr. Hulke, in an interesting paper on optic neuritis,* narrates such cases, and also others, in which it occurred in connection with diphtheria, rheumatic fever, etc.

To prove that the distinction between the engorged papilla and the descending neuritis is not a theoretical or arbitrary one, we need only pay attention to the differences in the anatomical changes met with in these two forms. In the engorged papilla, the inflammatory changes are generally chiefly confined to the intra-ocular end of the optic nerve, and do not, as a rule, extend backwards beyond the lamina cribrosa, although the intimate structure of the latter is often greatly changed, and its characteristic features rendered indistinct.† Mauthner‡ has seen some preparations of Iwanoff's, in which the proliferation of the connective tissue, instead of stopping short at the lamina cribrosa, had extended somewhat along the trunk of the nerve, and had thus given rise to ascending neuritis.

In descending neuritis, Virchow§ found that besides hypertrophy of the vessels and increase in the width of the nerve fibres, the whole trunk of the nerve had undergone inflammatory changes. The neurilemma was thickened, and showed cystoid detachments. Besides this peri-neuritis, the elements of the interstitial connective tissue had undergone proliferation, producing degeneration and destruction of the nerve tubules.‖

The prognosis must *in all cases* be extremely doubtful and guarded, and in the great majority unfavourable, for as a rule optic neuritis ends in more or less complete atrophy of the nerve and loss of sight. Besides the question of vision, it must also be remembered that there arises the still more important one of life, for but too frequently optic

* "R. L. O. H. Rep.," vi, 2.

† Schweigger, Vorlesungen, p. 136.

‡ "Lehrbuch der Ophthalmoscopie," p. 289.

§ "A. f. O.," xii, 2, 117.

‖ Vide also Dr. Leber's interesting paper on Optic Neuritis, "A. f. O.," xiv, 2, 333.

neuritis is caused by most dangerous and incurable affections of the brain. The most favourable cases are those in which the disease is due to some temporary and relievable cause, such as irregularities in the catamenia, etc., or a tumour or inflammation in the orbit. But even in these, the morbid changes in the optic nerve may have been so great as to prevent any restitution *ad integrum*, and the end is, atrophy of the nerve and blindness. On the whole, the cases in which the progress of the disease and the loss of sight have been very rapid, afford a more favourable prognosis than those in which they have been slow and gradual. In the former instance, a perfect recovery may result, even although all quantitative perception of light has been temporarily lost.*

With regard to the treatment, we can only lay down general rules, as it must be varied according to the nature of the cause and the exigencies and peculiarities of individual cases. If the disease is seen at the outset, the patient should be placed as soon as possible under the influence of mercury (inunction). If the patient is delicate, tonics should be at the same time administered. I have several times observed that this line of treatment has exerted a markedly favourable influence upon the progress of the disease and the morbid effusion, the absorption of which it hastens and facilitates. This is especially the case when the disease occurs without any special intra-orbital or cerebral cause, as in females suffering from derangement of the uterine functions, or persons affected with the suppression of some customary discharge, or great inaction of the skin. In some of these cases I have seen a complete recovery resulting from the combined influence of mercury and the local application of the artificial leech. The action of the skin should be stimulated by diaphoretics, and, if the patient will submit to it, a course of treatment by Zittmann's decoction, which proves especially beneficial in syphilitic cases. If the disease is not seen till a later stage, when permanent changes in the nerve have already occurred, I do not think that any benefit will be derived from salivation, and should prefer the administration of small doses of the bichloride of mercury, perhaps in combination with the iodide and bromide of potassium.

The severe and often very violent pain in the head with which the patients are frequently affected when the disease depends upon a cerebral lesion, is generally relieved by a suppurating blister, or, still better, a seton in the nape of the neck.

To alleviate the congestion of the optic nerve and retina, the artificial leech should be applied several times at intervals of a few days, but should then be desisted from if no benefit results. If the patient is weak and delicate, dry cupping should be substituted.

* "A. f. O.," xii, 2, 133.

Under the head of optic neuritis, Von Graefe* has lately called attention to cases in which there was an extremely sudden loss of sight, the patient becoming, without any clearly defined cause, so absolutely blind in the course of a few hours as to be unable to distinguish between light and darkness. He says:—"After constitutional diseases of different kinds (I have observed it occurring after measles, febrile gastric catarrh, and anginæ), but without any marked disturbance of the general health, the field of vision becomes clouded, with or without the presence of chromopsies and photopsies, and within the course of a few hours or days absolute blindness ensues. Both eyes are generally symmetrically affected, and only in a single case have I seen the disease confined to one eye. This case, however, presented some slightly irregular characters. The pupil generally becomes unusually dilated, and quite inactive to the stimulus of light, retaining but a slight degree of mobility during the movements of the eye or the impulse of accommodation. There is, therefore, reason to assume the existence of a special state of irritation in the fibres of the sympathetic. With the ophthalmoscope may be observed undoubted, though not very conspicuous, changes in the papilla, which are, however, of a markedly transitory character. Its tissue is veiled by a delicate, diffuse opacity, as is also the neighbouring retina, the level of the disc is, however, hardly raised, or only in a very slight degree, and only for a few days. The arteries are narrowed, but by pressing upon the eye we can still succeed in producing a slight pulsation (the surest sign of the existence of a continuous circulation),† the veins are dilated and tortuous, but their course is tolerably regular on account of the but slight opacity of the tissues." Von Graefe narrates four cases of this kind. In two a complete recovery occurred, even although there had been absolute loss of even quantitative perception of light for some little time. In another case the absolute blindness continued, and the disease passed over into rapid atrophy of the nerve. In the fourth, there was incomplete recovery with partial atrophy.

Von Graefe considers that in all probability these were cases of

* "Archiv. f. O.," xii, 2, 135.

† If a thrombus in the central artery of the retina has produced ischæmia of the retina, the arteries of the latter will also be extremely small, but even a considerable pressure on the eyeball with the finger will not succeed in producing arterial pulsation or emptying of the arteries. With regard to this subject, Von Graefe says at another place: "If together, with a free venous efflux, thrombosis occurs in the region of the lamina cribrosa or behind it, we must expect to find the retinal arteries empty. But if the venous efflux has been impeded by the swelling of the tissues, either simultaneously or at an earlier date, the arteries may remain partially filled, but on the other hand pressure upon the eyeball will not produce the usual phenomena, on account of the stoppage in the influx of the blood." ("Arch. f. O.," xii, 2, 134, note.)

retro-ocular neuritis, the swelling and diffuse opacity being due to an interstitial serous infiltration (œdema). The difference between this form and the descending neuritis consists principally in this, that the more marked tissue alterations do not extend to the papilla, that the disease occurs only at certain points, and does not involve continuously the whole trunk of the nerve. In fact, the degree of inflammation is only very moderate, and the disease but seldom depends upon grave intra-cranial lesions.

Von Graefe thinks, moreover, that certain cases of ischæmia retinæ, as also perhaps of embolism of the central artery of the retina, may have been in reality cases of retro-ocular neuritis.

2.—ATROPHY OF THE OPTIC NERVE (Plate VI., Figs. 11 and 12).

I shall here confine myself to a description of the various ophthalmoscopic symptoms presented by different forms of atrophy of the optic nerve, and reserve the consideration of the causes, prognosis, and course of this disease until we come to treat of the amblyopic and amaurotic affections of the eye.

Some observers have thought that the atrophic changes in the optic nerve are usually ushered in by a well marked hyperæmic condition of the papilla. Great care is, however, required, not to mistake physiological peculiarities in the colour of the disc as being of pathological import. Thus, as has been already stated, the nasal side of the disc is often considerably redder than the outer side, its edge being therefore slightly indistinct; and yet this is quite a physiological appearance. In the amblyopia dependent upon irregularities (congestion) in the cerebral circulation, hyperæmia of the papilla is often seen, as also after prolonged straining of the accommodation; but I do not think that, as a rule, it is met with as a premonitory stage of the primary, progressive atrophy of the optic nerve. The more intimate anatomical nature of the simple, progressive atrophy of the optic nerve is still very doubtful. Some observers believe that there exists a primary stage of irritation in the interstitial cellular tissue, which leads secondarily to the disappearance of the conductive nerve elements. In favour of this view might be urged the symptoms which not unfrequently occur in the progress of the disease, *e.g.*, pains in the head, unconsciousness, etc. But neither in amaurosis nor in tabes dorsalis does there appear to be inflammation of the cellular tissue of the nerves in the ordinary sense of the word.*

The ophthalmoscopic symptoms which especially characterise atrophy of the optic nerve are a pale, white or bluish-white discolouration

* Vide Graefe's Lectures on Amaurosis, "Kl. M.," 1865, p. 157.

of the papilla, diminution in the calibre and number of the little nutritive blood-vessels upon the expanse of the disc, attenuation of the retinal vessels, more especially the arteries, and frequently a peculiar excavation of the optic nerve.

In atrophy of the optic nerve (more especially the forms met with in cerebral or cerebro-spinal amaurosis) the papilla does not present the normal, greyish-pink tint, but looks pale and white. Sometimes, this whiteness is so great as to cause the disc to resemble a piece of smooth white paper, but there is frequently a bluish-white or greenish reflex, yielding a peculiar lustre. In the former case, the plane of the disc is quite level, and the dead white colour is chiefly due to the atrophy of the nerve tissue and the hypertrophy and thickening of the connective tissue elements of the nerve. The bluish-white reflex is, on the other hand, due to changes in the nerve tubules between the meshes of the lamina cribrosa, which render the details of the latter peculiarly distinct. In such cases there is always excavation of the nerve. Very frequently these two conditions co-exist, so that we have a shallow excavation with the details of the lamina cribrosa only partially exposed, the other portion being covered by a thick layer of connective tissue (Graefe).

Besides being pale and discoloured, the disc has also lost its transparency and peculiar clearness of tint, so that the retinal vessels cannot be distinctly traced passing into the substance of the papilla. Although the outline of the disc may be somewhat irregular in shape, it is very clearly and sharply defined, and the choroidal ring appears unusually distinct. The size of the papilla may also seem to be somewhat diminished, but not much importance should be attached to this symptom, which is, moreover, often due to causes situated in the refraction of the eye. The bluish, or bluish-green tint is often met with in cases of spinal amaurosis, of which indeed some authors consider it almost pathognomonic.*

The retinal vessels are generally diminished in size, and often considerably so. The little blood-vessels upon the disc are attenuated or have disappeared, and this of course also tends still more to blanch the papilla. The retinal arteries are often so narrow, as to resemble minute threads, being hardly traceable upon the retina at some little distance

* Mauthner calls attention to the blue or bluish-green discolouration of the papilla which was first described by Jaeger, but does not consider that it is pathognomonic of atrophy of the nerve except other symptoms (*e.g.*, attenuation of the retinal vessels) of the latter affection are also present. Where this is not the case, he still considers the prognosis hopeful as regards the sight, for not only may the degree of vision remain stationary, but even undergo wonderful improvement. He points out, moreover, that these changes in the colour of the disc are best seen in the erect mode of examination and by a weak illumination, as with Helmholtz's or Jaeger's ophthalmoscope. ("Lehrbuch der Ophthalmoscopie," p. 294.)

from the disc, but their principal trunks can generally be easily recognised upon the papilla. The retinal veins are mostly also somewhat diminished in calibre, but to a less extent than the arteries. We, however, sometimes meet with cases of chronic, complete amaurosis with well marked symptoms of nerve atrophy, and yet the principal retinal vessels retain their normal diameter. The most marked attenuation of the vessels is seen in cases of atrophy consequent upon retinitis or choroido-retinitis.

Whilst the above are the symptoms presented by progressive atrophy of the optic nerve, the form of atrophy which is consecutive upon optic neuritis retains for a long time special characteristic peculiarities, which generally enable us to distinguish it from the former kind, and also from that which ensues upon retinitis pigmentosa, etc. Finally, however, these distinctive characteristics gradually fade away, and it assumes the appearance of progressive cerebral atrophy. In the earlier stage, it is chiefly distinguished from the latter by the fact that the papilla remains slightly swollen, having a dull and opaque, greyish-white, faintly clouded appearance. Its outline, moreover, is not sharply defined, but uneven and indistinct, passing over gradually and almost insensibly into the faintly clouded retina, so that the disc appears surrounded by a slight halo. The retinal veins also remain somewhat dilated, veiled, and tortuous. Sometimes we may distinctly follow the atrophic changes in one portion of the papilla, whilst the other still retains the peculiar characters of neuritis. These appearances are well illustrated in Liebreich's Atlas, Plate xi, figs. 8 and 9.

I must here call attention to the fact that Mr. Wordsworth, Mr. Hutchinson and some other observers, consider that a peculiar and characteristic form of atrophy of the optic nerve is met with in tobacco-amaurosis.

Mr. Hutchinson in a paper on Tobacco-Amaurosis, read before the Roy. Med. Chir. Society,* says:—"The cases which form the subject of this paper are recognised by the loss of vascular supply to the optic nerve itself. There is not usually much diminution in the size of the vessels which supply the retina, and often these remain of good size when the nerve itself is as white as paper. The first stage (one which is usually very transitory, and perhaps often altogether omitted) is one of congestion, during which the disc looks too red. Then follows pallor of the outer half of the nerve disc, that part which is nearest to the yellow spot. During these stages the patient complains of dimness of vision merely. Everything seems in a fog to him, but he has no pain in the eyes nor any photophobia or photopsiæ. In a later stage the whole of the optic disc has become pale, even to blue-milk whiteness;

* "Transactions of the Roy. Med. Chir. Society," 1867, p. 411.

and later still there is proof, not only of anæmia of the nerve, but of advanced atrophy. The stages generally occupy from four months to a year. In many cases the patient becomes at length absolutely blind, but in others, the disease having advanced to a certain point, is arrested. There is from first to last no evidence of disease of any structure in the eyeball, excepting the optic nerve, and even after years of absolute blindness, the retina, choroid, etc., remain healthy and their blood supply good. Almost always both eyes are affected, and progress almost *pari passu*. Sleepiness, a little giddiness, and a little headache are usually the only constitutional symptoms which attend it, and these disappear at a later stage and the patient regains his usual health. As there is no tendency to fatal complications, opportunities for post-mortem examination of the brain are hardly ever obtained."

In cases of lateral hemiopia, we may also in rare instances meet with a partial atrophy of the disc with excavation, which corresponds to that half of the optic nerve which is supplied by the fibres from the affected optic nerve. But a long time elapses before symptoms of such atrophy begin to show themselves; indeed, hemiopia may exist for a very long period without the slightest trace of atrophy being recognisable.

3.—EXCAVATION OF THE OPTIC NERVE.

There are three forms of excavation or cupping of the optic nerve, viz., 1. *The congenital physiological excavation.* 2. *The excavation from atrophy of the optic nerve.* 3. *The glaucomatous or pressure excavation.*

In the *congenital physiological excavation*, we find that the cupping is generally limited to the central portion of the optic disc; that it is mostly very small and shallow, and that it may continue throughout life without undergoing any changes. In some cases, the cup is not situated in the centre of the disc, but slightly towards the outer (temporal) side. Sometimes the excavation is well marked and easily recognisable, the central portion of the optic disc presenting a peculiar white, glistening appearance, of varying size and form. This central glistening spot may be oval, circular, or longitudinal, and its size is generally very inconsiderable in comparison with that of the optic disc; it is surrounded by a reddish zone, which may even be almost of the same colour as the background of the eye. The width of this zone varies with the extent of the excavation; if the latter be small, the zone will be very considerable; but if it be large, the zone will be narrow, and limited to the periphery of the disc. The edges of the cup are generally slightly sloping, and never abrupt or steep, the excavation passing gradually over into the darker zone, without there being any sharply-defined margin. But if the excavation is conical or funnel-

shaped, the edges are more abrupt, and the margin more defined. We find that the retinal vessels also undergo peculiar changes in their course from the periphery towards the centre of the disc, for when they arrive at the margin of the excavation, instead of passing straight on, they describe a more or less acute curve as they dip down into it. This curve may be very slight and gradual if the cup is shallow, but if it is deep and extensive, the curve may be abrupt, giving rise to a displacement of the vessels. In the expanse of the excavation, the vessels generally assume a slightly darker shade; sometimes they, however, appear of a lighter, more rosy hue, and seem to be enveloped by a delicate veil.

In some cases, as was first pointed out by H. Müller, the surface of the same disc may show a physiological depression and elevation. The outer portion of the disc is slightly excavated, whereas the nasal half is elevated, and the two halves of the papilla present most marked and striking differences, which might easily be mistaken for pathological appearances by a careless observer. In such a case, we find that the cup has no sharply-defined border, and that in its expanse the peculiar stippling due to the lamina cribrosa is very observable, which is not the case in the other half. The colour of the excavated portion is pale and whitish, being in strong contrast with the elevated part, which appears abnormally red and vascular. The outline of the disc also differs, for at the temporal side it is sharply defined and the scleral ring very apparent; whereas, at the nasal side it is indistinct and more or less hidden. The retinal vessels can be seen to mount up from the centre of the disc over the edge of the elevation, at which point they are somewhat bent, sometimes to such a degree, that their continuity may be slightly lost.

In the excavation from atrophy of the optic nerve, we also meet with well marked and very characteristic symptoms. The retinal vessels will be found greatly diminished in calibre, the arteries small and thread-like, perhaps hardly apparent; the veins may at first retain their normal size, or be even slightly dilated, but in the course of the disease they also diminish greatly in diameter. The colour of the disc is likewise changed; instead of the rosy-yellow appearance which it presents in the normal eye, it assumes a more or less greyish-white or bluish-white colour, which may be limited to a portion of the disc or extend to its whole expanse, lending it a peculiar glistening, tendinous, or mother-of-pearl appearance. The bluish-grey colour of the optic nerve, as has been already stated, is often met with in spinal amaurosis; being by some considered almost characteristic of this affection. The atrophic excavation, although perhaps extensive on the surface, is generally very shallow, the descent being gradual and sloping, not abrupt; consequently, the retinal vessels, on arriving at the edge of the cup from the periphery

of the disc, do not show any marked displacement, but only describe a more or less acute curve. Sometimes this curve is so slight that it is hardly perceptible. Even in those rare cases in which the excavation is tolerably deep, the descent is not abrupt, and for this reason there is no marked displacement of the vessels at its edge; and on moving the convex lens of the ophthalmoscope to and fro, so as to make it act as a prism, the bottom of the excavation does not move as a whole, but only certain portions of the excavation undergo a slight displacement; and this parallax is very different to, and easily distinguishable from that met with in the glaucomatous cup. Moreover, the sudden interruption of the over-filled veins at the edge of the excavation, which is so very characteristic in the glaucomatous form, is also wanting.

The glaucomatous or pressure excavation (Plate vi, figs. 15 and 16) is distinguished by the following typical symptoms. The cup is not partial and confined to the central portion of the optic disc as in the physiological form, but it extends quite to the edge of the disc, its diameter equalling that of the latter, and the lamina cribrosa being stretched and pushed backwards. Even although it may not yet have attained a considerable depth, the edge is always abrupt and precipitous, thus differing greatly from the atrophic excavation, in which the descent is gradual and sloping. The edges may also overhang the cup, which has undermined the margin of the papilla. The disc is surrounded by a light yellowish-white ring, which is due to the reflection of light from the anterior laminæ of the scleral ring, the choroid being thinned and atrophied at this point. This zone varies in width according to the depth of the excavation; the deeper and more advanced the latter, the broader and more marked will be the ring. The colour of the disc is also much changed. Instead of the yellowish-pink appearance of the normal disc, the central, highly shining stippled portion is surrounded by a deep bluish-grey or bluish-green shadow, which gradually increases in darkness towards the periphery of the disc, where it may assume the appearance of a dark well-defined rim. On slightly moving the mirror or the object lens, this shadow will vary in intensity, more particularly in the central portion. On account of this peculiar shading of the disc, the latter looks, at the first glance, rather arched forward than hollowed and excavated. The course of the retinal vessels at the edge of the cup is also very peculiar. They do not pass, as in the normal eye, straight over the margin of the disc on to the retina without showing any curve or displacement; but if we trace their course from the retina, we find that when they arrive at the margin of the excavation, the dilated veins increase somewhat in size, and, making a more or less abrupt curve, descend into the cup; at the point of curvature the veins also appear somewhat darker in colour. If the excavation is deep, the veins seem to curl round over the edge, and are

considerably displaced, so that the prolongations of the veins on the optic disc deviate so considerably from those at the retinal edge of the cup, that they do not appear to belong to the same vessel. Their continuity seems interrupted, and this displacement of the two portions may equal the whole, or even more, of the diameter of the vessel. The extent and suddenness of this displacement vary with the depth of the cup. In the disc, the vessels appear indistinct and faded, and diminished in calibre; sometimes they may almost completely disappear, so that they can only be traced with difficulty. If the object lens be moved, so as to give it the action of a prism, a very marked parallax will appear; the whole bottom of the excavation shifts its position, and the broad scleral ring may seem to move over it, as if a frame were moved over a picture, the different portions of the excavation, however, shifting their individual positions but very slightly. The degree of the parallax also varies according to the depth of the excavation. It is particularly well seen, stereoscopically, with the binocular ophthalmoscope. The peculiarity of this parallax distinguishes, in a marked manner, the glaucomatous excavation from that met with in atrophy of the optic nerve; for in the latter case, as has been already pointed out, although certain portions of the excavation may shift their position, the bottom of the cup does not move as a whole. The displacement of the vessels in the glaucomatous excavation will also enable us to distinguish between this and the physiological form. In the former, the displacement is more or less abrupt, and occurs at the edge of the disc, whereas in the partial or physiological cup, the displacement or curvature is not abrupt, but slight and gradual, and does not occur at the edge of the disc, but within its area, at a greater or less distance from the margin, according to the extent of the excavation. Should a glaucomatous cup supervene upon a physiological one, we may at the outset of the disease sometimes observe the two existing together, the vessels showing the double displacement—the one at the edge of the physiological excavation and within the area of the papilla, the other more abrupt and marked, and situated at the edge of the optic disc. But at a later period the appearances of the physiological cup are lost, the latter becoming involved in the glaucomatous excavation.

In the majority of cases it is not difficult to distinguish the glaucomatous excavation from the others, even before it has reached any considerable depth; the extent of the cup, the abrupt and precipitous edges, the peculiar displacement of the vessels at its margin, and the spontaneous or easily producible arterial pulsation, will be found the surest guides. Where symptoms of atrophy of the optic nerve accompany the formation of a glaucomatous excavation, there may be some difficulty in ascertaining which is the primary affection, more particularly in those cases in which atrophy of the optic nerve, dependent

upon cerebral amaurosis, has become complicated with inflammatory glaucoma. In such, a comparison of the two eyes, and a careful and searching examination into the history of the case, will generally clear up the difficulty. But we must remember, that in glaucomatous excavation the optic nerve often undergoes atrophic changes and becomes very white.

At the commencement of the glaucomatous excavation, the cupping may be partial, being confined to one portion of the optic disc; but it will already show the typical symptoms of the pressure excavation. The optic disc is perhaps completely surrounded by a broad scleral zone, the veins become somewhat dilated and abruptly displaced at the edge of the cupped portion, and there is a bluish shadow at the periphery of the latter, which is gradually shaded off to a lighter colour towards the centre.

Von Graefe has pointed out the very interesting and important fact, that a glaucomatous excavation may become shallower after the operation of iridectomy, thus proving that the cup depends upon an increase in the intra-ocular pressure. The best cases to illustrate this fact are those in which acute symptoms have supervened upon chronic glaucoma. In such cases, the excavation becomes more shallow and saucer-like, the ends of the vessels less abruptly displaced, and their interruptions disappear, so that the continuation of the vessel from the retina on to the disc can be distinctly traced, although it may be somewhat curved. We may also notice that vessels which were slightly curved at the edge of the disc, now become straight again.

4.—PIGMENTATION OF THE OPTIC NERVE.

In speaking of the normal appearances presented by the fundus, I mentioned that we frequently meet with a more or less marked and extensive deposit of pigment at the edge of the disc, and that this is quite physiological and has no pathological signification. Sometimes this deposit is but slight, and forms a narrow crescent at one part of the disc; in other cases it is more considerable in size, and may embrace a larger portion of the edge of the optic nerve entrance.

In rare instances, pigment has been observed to be deposited in the expanse of the disc in cases of atrophy of the optic nerve. Liebreich* has published a case in which there was, in both eyes, atrophy of the optic nerve with marked pigment deposit within the disc, more especially in the left eye. In the latter the whole of the disc, except the very centre, and a portion of the outer (temporal side) was occupied by dense, black pigment. Sometimes there are noticed small, bright, superficial particles on the papilla (after morbid changes,

* "Annales d'Oculistique" lii, 31. Vide also Knapp. "A. f. O.," xiv, 1.

e.g., neuritis) having quite the appearance of cholesterine crystals (Mauthner).

5.—TUMOURS OF THE OPTIC NERVE.

Tumours of the optic nerve are of rare occurrence, and difficult to diagnose with the ophthalmoscope. Von Graefe* records a case in which there was a large retro-ocular orbital tumour, causing a protrusion of the eye to the extent of 9‴. The sight was completely lost. With the ophthalmoscope, the retinal veins were found to be dilated and tortuous, but the arteries attenuated. At the inner half of the disc (to which it was confined) was noticed a peculiar steep and abrupt elevation. The latter projected about 1‴ above the perfectly level outer half of the disc, and hung slightly over the inner edge. Within this elevated portion, the substance of the disc was of an opaque greyish-red tint, and the retinal vessels were completely hidden. On microscopic examination by Drs. Recklingshausen and Schweigger, it was found to be a tumour (myxoma) of the optic nerve. In another case of orbital tumour reported by Dr. Jacobson,† the ophthalmoscope also revealed a striking projection of a portion of the optic disc, in which the retinal vessels were lost. The whole appearance of the disc, the variations in colour of different portions of it, as well as the course of the retinal vessels were most peculiar. This was also found to be a myxo-sarcomatous tumour of the optic nerve.

6.—OPAQUE OPTIC NERVE FIBRES.

Amongst the physiological peculiarities of the retina which are sometimes met with, is one which, if it be at all fully developed, may easily be mistaken for an exudation into the retina. It is a well-known fact, that in the human subject the nerve tubules of the optic nerve lose their neurilemma at the cribriform tissue, passing on to the most anterior portion of the papilla, and thence to the retina, denuded of their sheath, *i.e.*, simply in the form of transparent axis cylinders. In certain animals, however, especially rabbits, the sheath is continued on to the retina. Now, this sometimes also happens in the human subject (as was first pointed out by Virchow), the optic nerve fibres retaining their neurilemma for a short distance on to the retina, so that the latter, instead of being transparent, will at such points show a marked, white opacity. The ophthalmoscopic diagnosis of opaque nerve fibres is by no means difficult, and a little care and reflection should guard any observer from mistaking these appearances for morbid changes in the retina. We notice in such cases, that the optic nerve,

* "A. f. O.," x, 1, 194. † Ib. x, 2, 55.

instead of being sharply and clearly defined and surrounded by transparent retina, shows at certain points peculiar white, striated, tongue-like projections, which extend a little way into the retina. These patches terminate in an irregular manner, their outline showing faint "feathery" striæ. It is a fact of much diagnostic importance, that the retina in the immediate vicinity of these patches is perfectly healthy and transparent, there being not the faintest trace of haziness of the retina due to serous infiltration. Whereas, in exudations into the retina the contiguous portions always show a certain degree of cloudiness.

The retinal vessels may be partly or completely hidden in these white patches, which is especially the case if the latter are considerable in size. We then find, that the vessels pass from the centre of the disc up to the edge of the opacity, become hidden by this, and re-appear at its periphery, being thence distributed in a normal manner over the retina. These opacities vary much in size and number. In some cases there are only two or three small patches; in others there is one large, irregular white figure which surrounds the greater portion, or even the whole of the disc, and extends perhaps for a considerable distance on to the retina. (For a beautiful illustration of such a condition, *vide* Liebreich's Atlas, Plate XII., Figs. 1 and 2.) Sometimes the little white patches may even show themselves on the retina at some little distance from the disc, not being in contact with it, but separated from it by a portion of normal retina.

The opacity due to thickening of the optic nerve fibres may be particularly distinguished from an inflammatory exudation into the retina and optic nerve by the following symptoms:—

1st. The optic disc itself is perfectly normal both in colour and transparency, and the vessels within its expanse are also quite healthy in appearance. In retinitis, especially where the morbid products are so close to the optic nerve, the disc is always more or less hyperæmic, indistinct, opaque, and perhaps somewhat swollen; the veins on its surface are dilated and perhaps tortuous, the arteries generally somewhat attenuated, and both sets of vessels perhaps slightly veiled. 2nd. The opacities caused by thickened nerve fibres terminate, as has been already stated, in a peculiar manner, like the fine divisions of a tongue of flame. They end abruptly in the healthy retina, and only here and there can a faint trace of thickened nerve fibre be followed for a very short distance. 3rd. The retina is perfectly normal, both in colour and transparency, quite up to the opaque spot, the retinal vessels are also absolutely normal; whereas in retinitis, accompanied with inflammatory deposits in the retina, the condition is quite different, for then we find that the retina is more or less opaque and cloudy within a certain area around the exudations, this cloudiness gradually shading off into the normal retina. The vessels are also changed, the veins

being dark, tortuous, and dilated, the arteries attenuated, and there are generally also extravasations of blood scattered about on and between the vessels. 4th. If the eye is otherwise healthy, the sight and the field of vision are perfect. If the opacity is extensive, the "blind spot," corresponding to the area of the disc, will be enlarged.

*Mauthner** narrates a very interesting and peculiar case, in which there was a bifurcation of the optic nerve fibres, which appeared to be collected into two bundles, the one passing upwards, the other downwards, the retinal vessels taking the same course, whilst on the inner and outer portion of the disc there were no vessels. The fibres were devoid of their sheath, and hence their tint was not brilliantly white, but their situation and course were very marked and distinct, on account of the close super-imposition of the individual fibres, which rendered the upper and lower margin of the papilla quite lost and indistinct.

* Op. cit., p. 267.

Chapter X.

AMBLYOPIC AFFECTIONS (AMAUROSIS AND AMBLYOPIA).

Under the vague term "amaurosis" were formerly included all kinds of intra-ocular diseases that were not distinguishable with the naked eye, but since the discovery of the ophthalmoscope has revealed the true nature of the diseases of the inner tunics of the eye and of the optic nerve, we are able to confine the term "amaurosis" to very narrow limits. Indeed it is of great practical importance, that a definite understanding should be arrived at, as to what diseases are to be included in the group of "amblyopic affections." Thus only can we remedy the confusion which still exists, from the fact that some writers apply the name amaurosis indiscriminately to all cases of total blindness dependent upon deep-seated intra-ocular affections, whilst others give to it a more limited signification, and confine it to the loss of sight dependent upon intra-cranial disease. I think, therefore, that Von Graefe's signification should be universally adopted. He excludes from the term "amblyopic affections" (amblyopia and amaurosis) all disturbances of sight dependent upon material, perceptible changes in the refractive media, in the internal tunics of the eye, on neuro-retinitis and embolism of the central artery of the retina.* It may be questioned whether we should exclude cases of optic neuritis from this group, as they are generally due to intra-cranial disease, and but too frequently pass over into consecutive atrophy of the optic nerve and retina, and more or less complete blindness. But even in such cases, I think it would be better and more definite to term such blindness, amaurosis from optic neuritis, just as we should speak of amaurosis (or amblyopia as the case may be) from retinitis pigmentosa, from glaucoma, or embolism of the central artery of the retina; in fact that we should strictly confine the term amaurosis to cases of blindness from primary atrophy (degenerative atrophy) of the optic nerve, and that of amblyopia (in a special sense), to impairment of vision produced by irregularities in the circulation or the nervous system, which may lead in the end to primary atrophy of the optic nerve.

* Vide Von Graefe's Lectures on "Amblyopic Affections," "Kl. M.," 1865. An able translation of these important and valuable Lectures by Mr. Z. Laurence will be found in the "Ophthalmic Review," ii, 232.

Amblyopic affections are also sometimes classified according to the degree of impairment of sight.

Liebreich* distinguishes three different forms—1st. *Amaurotic amblyopia*, in which the sight is so much deteriorated that even large objects are only distinguished with difficulty, or the patient is not able to guide himself. 2nd. *Amaurosis*, in this condition even large objects can no longer be distinguished, there being no qualitative but only quantitative perception of light, which may exist either in the whole or only a part of the field of vision. 3rd. *Absolute amaurosis*, where the patient has not the faintest power of distinguishing between light and darkness.

In examining the sight of cases of amaurosis and amblyopia, it is very important to ascertain the condition of the field of vision with the greatest accuracy. In these diseases, it does not suffice to examine the field by daylight, because slight contractions or interruptions may thus easily escape detection, which will however become at once apparent if the field is tested by a more subdued light, for which purpose Von Graefe's graduated disc of light will be found the best. The mode and extent of the contraction or interruption of the field of vision, are of great importance in enabling us to form our prognosis as to the risk of a total loss of vision, or the chances of an improvement, or even a restoration of the sight.

In the following description of the different kinds of contraction and interruption of the visual field, and their bearing upon the prognosis as to the ultimate condition of the sight, etc., I have mainly followed the views of Von Graefe as expressed in the above-mentioned lectures on amblyopic affections; indeed he is the first writer who has attempted to lay down anything like definite rules with regard to the chief points that should influence our prognosis in this class of diseases. This, in fact, could only be done by one who had for many years closely watched the course of a vast number of cases, and carefully studied their minutest details. A mere hypothetical generalization, not founded upon absolute, sufficient, and closely scrutinized data would be simply valueless.

Several different forms of contraction of the field of vision may be observed in amblyopic affections.

The contraction frequently commences at the temporal side of the field of vision (the nasal portion of the retina being the first to suffer), and from thence either passes on laterally towards the centre, or along the periphery in an upward and downward direction, extending finally towards the nasal side; and then, when the whole periphery of the field has become impaired, the contraction advances concentrically towards the axis of vision. The outlines of both these forms of contraction of the

* "Nouveau Dictionnaire de Med. et de Chir. prat.," 785.

field are often very irregular and undulatory. The contraction of the field in cases of amaurosis generally commences at the temporal side, but this is not always the case, for it may begin at the nasal. Whereas, in the contraction met with in glaucoma, it is a very characteristic feature that as a rule it commences at the nasal side (the outer portion of the retina becoming first impaired). We occasionally find that some time after the first eye has become affected (and perhaps even amaurotic), a gradually progressive contraction of the field shows itself in the second eye, commencing perhaps at a point quite symmetrical to that in which the contraction began in the eye originally affected. Such cases afford a most unfavourable prognosis, more especially if the central vision is greatly impaired, or already perhaps sunk below that of the eccentric portion of the retina, for these symptoms indicate but too surely a progressive atrophy of the optic nerve.

The contraction of the field may be equilateral in both eyes, *e.g.*, the right half of each field may be wanting, and the line of demarcation between this and the normal half of the field be quite sharply defined, and situated in the axis of vision. This is termed equilateral or homonymous hemiopia, on account of the corresponding halves (the right or left as the case may be) being affected. The nature of this condition is self-evident, when we remember the anatomical relations of the optic nerves to each other, and the fact that their fibres decussate at the optic commissure (chiasma) in such a manner, that the right optic nerve supplies the right half of each retina (the temporal side in the right eye, the nasal in the left), and the left optic nerve the left half. A glance at fig. 55 will explain this arrangement.

Fig. 55.

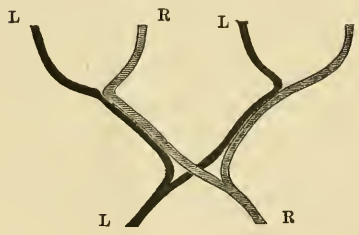

This figure represents the commissure of the optic nerves and their prolongation to the retina. R the right optic nerve. L the left optic nerve.

If, therefore, a tumour or an hæmorrhagic effusion compresses the right optic nerve on the central side of the commissure, in such a manner as completely to destroy its conductibility, the right half of each retina will be impaired, and consequently the left half of each field of vision be wanting. But if the compression is limited to the commissure, affecting only the crossed fibres, and leaving the lateral ones unimpaired, the appearances will be different, for then the nasal half of each retina will be affected, and the temporal half of each field be wanting. In such cases, however, the hemiopia is not so sharply defined as in the equilateral form, for there is generally a more or less

broad line of transition, in which the defective portion of the field passes over gradually into the healthy part. The seat of the disease may not, however, be confined to the commissure, but be situated principally in front of or behind the latter. This may be suspected if other symptoms co-exist with the hemiopia, such as paralysis of other nerves, hemiplegia, impairment of the mental functions, etc. It will be seen, hereafter, that the prognosis is less favourable in the temporal than in the equilateral hemiopia. It is extremely rare to meet with hemiopia of the upper or lower halves of the field, and the real nature of such cases is at present quite unexplained.

If the cause of the compression is situated at the distal end of the optic nerve, *i.e.*, after the crossing of the fibres in the commissure, of course the corresponding eye is alone affected.

In addition to the contraction of the field of vision, we often meet with interruptions in its continuity, which appear in the form of dark, irregular clouds or spots before the patient's eyes. These "scotomata" (as they are called) may be situated in or near the centre of the field, or at its periphery. On examining the field in cases of scotomata, we find that within a certain area there is a more or less considerable gap, in which the object becomes indistinct, or even lost. If the scotoma is situated in the axis of vision, it of course produces great impairment of sight, and the patient often squints in a certain direction, in order that the rays from the object may fall upon a more sensitive (in this case eccentric) portion of the retina. Whereas, if the interruption occurs at the periphery of the field, and is only inconsiderable in size, it is generally altogether overlooked by the patient.

These scotomata generally make their appearance very suddenly; sometimes, however, a few weeks elapse before they become fully developed. They are not unfrequently met with after exhausting general diseases, and after great mental emotions, and are accompanied, perhaps, by cutaneous insensibility to pain. According to Von Graefe they occur most frequently in young persons, and are never seen in connection with hæmorrhagic diseases of the brain. Their cause is at present unknown. In cases of peripheral anæsthesia of the retina, we often meet with the interesting phenomenon that the phosphènes continue to exist in portions of the retina which are quite insensitive to light, and this is of prognostic importance, as it does not occur in amaurosis. The sight is generally very considerably affected, and may finally become quite lost, so that the patient cannot distinguish between light and dark.

In cerebral amaurosis, the pupil is generally somewhat dilated and sluggish, or immoveable and large, if the eye is quite blind. If the pupil is dilated to its fullest extent, so that the narrow rim of iris is hardly discernible, we must assume that there co-exists an irritation of the

sympathetic fibres, causing a contraction of the dilator pupillæ. If one eye only is affected, we often find that its pupil is dilated and immoveable under the stimulus of light when the other eye is closed, but that it at once contracts consentaneously with the pupil of its fellow, when the latter is uncovered. This fact may prove of use in detecting the simulation of blindness in one eye by the dilatation of the pupil by atropine, when of course this consentaneous action could not occur. Great importance cannot, however, be attached in cases of amaurosis to the behaviour of the pupil, for we sometimes find that even in complete blindness it retains its activity. In spinal amaurosis, the pupil is unusually and perhaps irregularly contracted (oval), and acts but very sluggishly and imperfectly upon the application of atropine. The great contraction is due to the paralysis of the sympathetic fibres.

The ophthalmoscopic symptoms of cerebral and cerebro-spinal amaurosis, consist in certain changes in the appearance of the optic nerve, indicative of its progressive atrophy. Care must, however, be taken not to mistake simple anæmia, or blanching of the disc, for incipient atrophy. The small nutritive vessels, which are distributed upon the expanse of the disc, disappear, and this partly produces the white colour; whilst the vessels distributed over the retina may retain their normal calibre, even when the optic nerve is quite atrophied, but generally they soon become attenuated. The symptoms of atrophy of the optic nerve have already been fully described (p. 385).

We have now to turn our attention to the various causes which may produce cerebral and cerebro-spinal amaurosis. But this subject is far too extensive for the scope of this work, and I must therefore confine myself to giving a mere outline of the principal causes, and must refer the reader for fuller information to special works and articles upon this subject. Amongst these I must especially recommend those of Von Graefe, Hughlings Jackson, Hutchinson, Ogle, Galezowski, etc.

It must, however, be candidly confessed that we cannot diagnose the special cerebral cause, or localise its seat, simply from the ophthalmoscopic symptoms presented by the optic nerve. In order to aid and guide us in arriving at a conclusion as to the cause and its situation, other local and general symptoms must be searched for. But, even with their aid, we often fail to determine these points with anything approaching to certainty, and may find, on *post mortem* examination, that we have been quite mistaken. Indeed we sometimes meet with cases of simple progressive atrophy of the optic nerve, leading to blindness, in which it is quite impossible to detect any special cause, either cerebral, spinal, or constitutional. On the other hand, the trunk of the optic nerve may be seriously implicated in the intra-cranial disease, without the sight being in the least affected.*

* "A. f. O.," xii, 2, p. 111.

Still the ophthalmoscope proves of immense use to the physician in the practice of his art, and may often lead him to the discovery of diseases which he would, without it, have passed over, or misinterpreted.

As I have already mentioned the various affections of the brain which may produce optic neuritis, I shall now only consider those which may give rise to progressive atrophy of the optic nerve.

Meningitis of the base of the brain is a very frequent cause of disease of the optic nerve. The symptoms of acute meningitis are generally so marked and characteristic that the diagnosis is not difficult, but it is different with the chronic form, the course of which is often very insidious, and its symptoms masked and indistinct. But its presence may be suspected, if there are febrile attacks accompanied by violent and recurrent paroxysms of headache, severe vomiting and retching, unconsciousness, and sensitiveness of the cranium to palpation. Moreover, as the inflammation of the meninges is generally somewhat diffuse, we find that other cerebral nerves become affected, being either paralysed or in a state of irritation. Thus, we sometimes find that some of the muscles of the eye are paralysed, whilst others are in a state of spasmodic contraction (Graefe). The inflammation of the meninges may extend from the membranes to the cortical substance of the brain, perhaps to a considerable depth, reaching, according to L. Meyer,* even to the optic thalami.

With regard to the headaches which may occur in cases of amblyopia, we must be on our guard not to attribute them always to some cerebral affection; for, as Von Graefe has pointed out, they are often only due to the failing sight, and are produced by the intent endeavour of the patient still thoroughly to realize the visual impressions. On account of this, there occur disturbances of sensibility akin in nature to those which are met with in double vision, circles of diffusion upon the retina, etc. If the headache be simply due to this cause, cessation from work will rapidly cure it; for it can be easily understood that its intensity may be materially increased by any cause that produces congestion of the brain or the eye, such as stooping, etc.

Acute meningitis, more especially the tubercular form, generally gives rise to optic neuritis, and this often ensues rapidly upon the outbreak of the cerebral affection; whereas, in the chronic form, the optic nerve often remains altogether, or for a long time, unaffected, and then it undergoes progressive atrophy, its nutrition becoming impaired by the chronic congestion of the brain and meninges.

Chronic Periostitis of the base of the brain may also produce amaurosis.

* L. Meyer, "Centralblatt für Med. Wissensch.," Nos. 8, 9, 10, 1867.

Tumours within the brain may cause progressive atrophy of the optic nerve, either by the latter becoming directly implicated in the morbid process, and its nervous elements destroyed, or by its being compressed, stretched, or pushed aside by the tumour, so that its conductibility and its nutrition are greatly interfered with; but the impairment of nutrition may also be due to pressure upon the blood-vessels of the optic nerve. Although sarcomatous and carcinomatous tumours are the most frequent morbid growths, we must include other neo-plasms, such as masses of tubercle, syphilitic gummata, exostoses, etc. Such morbid growths may be situated at the base of the brain or within its substance. Their diagnosis is very uncertain and obscure, except other general or local symptoms co-exist, which may aid us in determining the probable nature and seat of the cerebral disease. Thus in equilateral hemiopia (say of the left half of the visual field) we should suspect that a tumour or hæmorrhagic effusion is pressing upon the right optic nerve.

If the temporal half of each field is impaired, the crossed fasciculi of the nerves are involved, and the seat of the disease is at the commissure. In such cases the impairment of vision is often very rapid, the sight being perhaps utterly destroyed within a few days. The contraction of the visual field begins at the periphery of the temporal side and extends up to or beyond the centre, so that finally only a slight glimmer of light may be left at the nasal side. If the cerebral tumour is very slow in its development, the brain substance and the nerves may gradually accommodate themselves to its growth, and there may only periodically arise some compression of the vessels at the base of the brain, which, setting up disturbance in the intra-cranial circulation, will give rise to ephemeral hemiplegia, ischæmia, and fainting or epileptoid fits. But symptoms of paralysis of the cerebral nerves may supervene if the tumour pervades, irritates, or presses upon the nerve substance, or if the vessels become compressed and the nutrition of the nerves impaired.*

Tumours in the cerebellum nearly always produce blindness (generally from optic neuritis) by setting up a general disturbance (Hughlings Jackson), whereas abscess of the cerebellum, as a rule, does not do so on account of its limited extent and effect.

Cerebral hæmorrhage may be suspected if the amaurosis comes on very suddenly; thus sudden equilateral hemiopia of the left side would make us suspect hæmorrhage in the right hemisphere. Such equilateral contractions of the field often remain behind in persons who have been affected with an apoplectic fit. Loss of the right side of the field is more irksome than that of the left, more especially in reading, as the patient cannot read so easily and rapidly on account of his not being able to

* "Kl. Monatsbl.," 1865, p. 259.

foresee the words (Graefe). In slight degrees of cerebral hæmorrhage, the sight is often quite unaffected. Hemiopia may, however, be also produced by temporary affections of the nerve trunk, *e.g.*, syphilis.

Senile softening of the brain is not, as a rule, accompanied by amaurosis, but, of course, the atrophic changes in the brain may extend to the optic nerves, the nutrition of the latter becoming impaired on account perhaps of the disease of the vessels.

Epilepsy may produce amaurosis when it is due to some disease of the brain, for instance meningitis, for epilepsy must be looked upon as a symptom and not as a disease.

In diseases of the spinal cord, more especially chronic myelitis and locomotor ataxy, amaurosis, from progressive atrophy of the optic nerves, is not unfrequently met with. But it hardly ever makes its appearance in locomotor ataxy until a late period of the disease of the spine, long after the impairment of the mobility and sensibility of the lower limbs, and the paralytic affections of the muscles of the eye, the latter often being amongst the first symptoms of the spinal disease. In some very rare instances, the atrophy of the optic nerves has preceded by a long period (several years) the first symptoms of spinal disease (Graefe). This late occurrence of amaurosis is explained by the fact that the degeneration ascends from the vertebral canal to the cavity of the cranium. Amblyopia often occurs at the commencement of the spinal affection, and a careful examination as to the true nature of this impairment of vision should be made, for it may only be due to a loss of the power of accommodation from paralysis of the ciliary muscle, and be not at all dependent upon any disease of the optic nerve. A want of care in the examination as to the true cause of such amblyopiæ, has led to much confusion amongst writers upon this subject. In cases in which the atrophy of the optic nerve is dependent upon locomotor ataxy, the former may remain stationary for a few weeks and then again progress (Graefe).

The affection of the optic nerve in diseases of the spine is probably due to a lesion of the great sympathetic, through its communication with the anterior roots of the spinal nerves.

In some cases simple atrophy of the optic nerve exists for a long time without any appreciable cause, or the appearance of any symptoms indicative of a cerebral or spinal lesion; and, even after death, nothing is perhaps found except atrophy of the optic nerves or atrophy of those parts of the brain which are continuous with the optic nerve. In some of these cases, however, insanity may supervene. And this brings us to a very important point, viz., the great use of which the ophthalmoscope is likely to prove to the alienist in establishing the study of insanity upon a more positive basis.* In England we are almost entirely

* For further information I would particularly recommend Dr. Leber's very

indebted to Dr. Allbutt for our knowledge of this subject, and I would refer the reader to his valuable and interesting paper, entitled "On the state of the Optic Nerves and Retinæ as seen in the Insane," read before the Roy. Med. Chir. Society, February 25, 1868. In this, he mentions that in general paralysis of the insane, atrophy of the optic nerve is constantly found, and is commonly accompanied by atrophy of the olfactory nerves. It is not distinctly seen till the end of the first stage, as it slowly travels down from the optic centres, and it is in relation with the state of the pupil, which is contracted in the early stage and dilated in the fatty atrophic stage.

In mania, the ophthalmoscope often reveals symptomatic changes. In dementia organic disease and affection of the eye generally occur together.

In idiots atrophy of the optic nerve is of frequent occurrence. Out of twelve cases, it was found of a marked character in five; one was changing, and two were noted as doubtful.

We have now to consider the *prognosis* which may be made in cases of amaurosis or amblyopia, as to whether the impairment of vision will improve, remain stationary, or become permanently lost. In framing such a prognosis, we must be especially guided by the mode of attack, the condition of the field of vision, and the appearances presented by the optic nerve. The nature of the primary disease which has caused the affection of the eye must naturally also be taken into anxious consideration. For the prognosis will, of course, be materially influenced by the fact, that the intra-cranial affection is of a kind that permits of resolution or amelioration through the absorption of morbid products, or hæmorrhagic effusion, or the amendment of irregularities in the circulation.

If atrophy of the optic nerve has already set in, the prognosis as to the arrest of the disease must be very guarded, as in such cases there is always a great tendency to progression, and termination in absolute blindness. But this is not necessarily always the case, and it would be committing a grave error to irrevocably condemn an eye, simply because the optic nerve shows symptoms of commencing atrophy. The state of the field of vision is our best guide in such cases.

If the loss of sight has occurred with great suddenness and rapidity, the prognosis need not necessarily be bad, for we occasionally meet with cases in which great improvement, or even complete restoration of sight takes place after its sudden loss. Sudden equilateral hemiopia is generally due to hæmorrhagic effusions (apoplexies), which is seldom the case in double central scotomata. Von Graefe* considers

interesting paper "On Grey Degeneration of the Optic Nerve," "A. f. O.," xiv, 2, 177; also Dr. Westphal's important papers in the "Archiv. für Psychiatrie."

* "Kl. Monatsbl.," 1865, 149.

that the prognosis of sudden amaurosis is better in children than in adults. He also states that the best prognosis is furnished by those cases in which the sudden loss of sight is the result of mental shock; also if the phosphènes continue to exist in the blind retina, and complete darkness proves beneficial. This form of anæsthesia is often associated with cutaneous insensibility to pain, and is perhaps referable to vaso-motor action.

The prognosis is also inclined to be favourable, if the disease has remained stationary for some length of time, for although the dangerous forms of amaurosis likewise halt in their progress, yet this interruption does not extend beyond a few weeks or months, when they again progress. The former cases often depend upon a combination of deleterious causes, such as alcohol, tobacco, dissipation of every kind, overwork of the eyes and brain, irregularities in the digestive organs or the uterine system.

The prognosis is bad, if the atrophy of the optic nerve is of slow development and manifests a persistent, though perhaps tardy, progress.

When the atrophy of the nerve cannot be traced to any particular cause, but appears to be a disease *per se*, the prognosis is generally also very unfavourable.

In those cases in which the condition of the visual field is quite normal (even after the affection has existed for several months), and the acuity of vision has not sunk considerably (only to one-sixth or one-tenth), we may decidedly regard the disease as not being due to progressive atrophy. The impairment of vision may not, however, undergo much improvement.

With regard to the prognosis afforded by the different forms of contraction and interruption of the visual field, we may briefly state, that it is more favourable when it is equilateral with a sharply-defined line of demarcation than when it is concentric, or its edges (in the lateral form) are undefined and irregular. Indeed, patients affected with equilateral hemiopia never become absolutely blind, except the disease extends to the commissure, or some other cerebral affection supervenes.* Such patients often enjoy excellent central vision, being able to read the finest print, and the affection frequently remains unaltered for a very long time. I have cases still under supervision in which

* Von Graefe says: "Total blindness in cases of unilateral brain disease can only ensue (1), when the other hemisphere likewise becomes the seat of disease; (2), when fresh effusions in the hemisphere originally affected occasion diffuse cerebral disease, haply through anæmia cerebri; (3), when a basilar affection supervenes, directly affecting the trunks of the optic nerves; (4), when some encroachment on the space of the cerebral cavity results in compression of the sinus cavernosus with consequent venous incarceration of the papillæ; (5), when propagated encephalo-meningitis leads to neuritis descendens." ("Kl. Monatsbl.," 1865, 220; "Ophth. Review," ii, 359.)

equilateral hemiopia has existed for some years, and the patients are still able to read perfectly, nor has the condition of the eye changed, nor have any other symptoms shown themselves.

The most dangerous cases are those, in which irregular contractions of the field of vision occur either simultaneously in both eyes, or in quick succession. Also those, in which the condition of the one eye being already very bad (the degree of its central vision being perhaps even less than the eccentric), the second eye becomes affected in an exactly similar manner, the contraction of its visual field commencing at a point symmetrical to that at which it began in the first eye.

Central scotomata never indicate progressive atrophy, if the periphery of the visual field is normal. But if they have existed unaltered for several weeks, and the optic nerve begins to show symptoms of commencing atrophy, a restitution *ad integrum* can no longer be expected. If the central portion of the retina maintains its superiority of vision over the outlying parts (so that the patient can see through the scotoma), the prognosis is always better than when the reverse obtains. If the peripheral portion of the field of vision beyond the scotoma is impaired, progressive atrophy is to be feared, which is not the case when this part of the field is normal, for this shows that the power of conductibility in the part of the retina affected with the scotoma is perfectly retained (Von Graefe).

We cannot form our prognosis of the case simply from the appearances presented by the optic nerve, for, as Von Graefe remarks, it is impossible to tell from these alone, whether the atrophy be progressive or stationary. In conjunction with the appearance of the optic nerve, we must therefore be guided by the condition of the field of vision, and the mode in which the attack occurred. Even the absence of atrophic symptoms in the nerve does not exclude the most unfavourable result. In cases of amblyopia due to disturbances in the circulation, or to alcohol, or in that form which is sometimes met with in very nervous females and in children, the presence of symptoms of atrophy of the optic nerve are always of material consequence, as they greatly cloud the prognosis.

Treatment.—This must of course be specially directed against the primary cause of the affection of the eye. In those cases of simple progressive atrophy, in which we fail to detect any appreciable organic or functional cause, we must be extremely upon our guard not to submit the patient to a very active course of treatment, more especially of a lowering or depressing kind. For great mischief is thus often produced, and the progress of the disease hastened, instead of being arrested or retarded. The best treatment for such cases consists in the administration of tonics, especially the tincture of the muriate of iron, or a combination of steel with quinine or strychnine. The lactate or sulphate of zinc may also be given in gradually increasing doses,

commencing with one grain daily, and augmenting this gradually until the patient takes three or four grains a-day. The diet should be nutritious but light, and the effect of stimulants be closely watched. The patient's course of life should be carefully regulated, a sufficiency of sleep be insisted on, and all amusements or employment, that may prove injurious to his eyes or general health, be strictly forbidden. The use of tobacco must also be absolutely given up.

If there is any evidence of the existence of chronic meningitis, irregularities in the circulation (more especially the cerebral), or a suppression of customary discharges, such as the menstrual, or the exhalations from the skin, more particularly the feet, a derivative course of treatment must be employed. Leeches should be applied behind the ears, or the artificial leech to the temple, and a seton may be inserted at the nape of the neck, which often affords great and speedy relief to the severe and persistent headache. The bichloride of mercury should be given in small doses, in combination perhaps with the iodide and bromide of potassium, more especially if any syphilitic taint is suspected. The sudden suppression of the normal exhalations from the skin is not an unfrequent cause of amblyopic affections, more especially after long exposure to cold and wet. Thus persons who have stood for many hours in the water (sportsmen, fishermen, etc.), are sometimes affected with amblyopia, on account of the suppression of the exhalations from the feet. In such cases hot stimulating pediluvia, together with diaphoretics and diuretics should be prescribed. Graefe also advocates the Roman or Turkish bath, as specially exciting the action of the skin, which will also prove of benefit in the different forms of congestive amblyopia.*

If the affection of the eye is due to some sudden fright or shock to the nervous system, tonics should also be prescribed.

In the amaurosis due to locomotor ataxy, innumerable remedies have been tried. Dr. Althaus† states that he has derived much benefit in cases of locomotor ataxy from the administration of small doses of nitrate of silver. He gives the silver together with the hypophosphite

* An important and interesting fact in connection with this subject has been noticed by Dr. Leared. Having found that persons affected with fulness and congestion of the head, were often much benefited by the Turkish bath, he thought that the readiest mode of ascertaining the effect of the latter upon the cerebral circulation would be by observing its influence upon the blood-vessels of the retina. Mr. Wordsworth therefore examined Dr. Leared's eyes with the ophthalmoscope just prior to his entering the bath, and again after he had remained in the hottest chamber (196 F.) for a quarter of an hour, and then found a decided and marked paleness of the optic nerve, and a diminution in the size of the retinal vessels. The same effect was noticed in four persons employed in the bath (a negro, an East Indian, an Englishman, and a German), under a temperature of 120 F., who were examined at the same time by Mr. Wordsworth.

† Lectures on Epilepsy, Hysteria, and Ataxy, 1866.

of soda, and he never goes beyond the dose of half a grain of the nitrate of silver. It should be employed for from four to six weeks consecutively, and then discontinued for a fortnight or three weeks, a slight aperient mineral water being given in the meanwhile. Then the use of the remedy may be again commenced and continued for a month or so. The gums should be examined from time to time, as the peculiar dusky discolouration of the skin, which the long continued use of nitrate of silver produces, first appears in the mucous membranes.

Cases of amaurosis have been recorded in which it has been stated that great benefit has been derived from the subcutaneous injection of strychnine.* But the histories of these cases, more especially the condition of the eyes, have not been given with sufficient accuracy or minuteness to permit of our forming any opinion as to the value of this remedy. The amount to be injected at first, is about one-fortieth of a grain, to be gradually increased to one-twentieth.

If central scotomata have been developed during protracted enfeebling general illness, such as typhoid or scarlet fever, diphtheria, childbed, etc., tonics and a generous diet, with stimulants, are the best remedies; and subsequently, when the sight is beginning to improve, much benefit is often derived from methodically practising the sight (even the eccentric) with strong convex lenses, as is done in cases of amblyopia from non-use. An improvement upon the ordinary single convex lens is recommended by Von Graefe, viz., a combination of two bi-convex lenses (the one 6 inches the other 4) set in a tube or ring at a distance of one inch from each other. We thus gain a relatively considerable magnifying power with only slight spherical aberration. The eye should at first be only practised for a very short time (about two or three minutes), and with print that can be tolerably easily deciphered.

If there is any disturbance in the functions of the liver or digestive organs, mild aperient mineral waters should be prescribed, such as the Pullna, Karlsbad, or Kissingen waters.

1.—AMBLYOPIA.

This affection is often due to passive congestion of the brain, the eye, or other organs, such as the liver, uterus, etc., or to disturbance of the nervous functions.

We must admit that the term passive congestion is very vague, and that we do not know with any certainty the mode in which the sight becomes affected, and whether this is due to a retardation of the blood supply and a consequent insufficiency of its aëration, or whether it is loaded with noxious ingredients, such as alcohol, nicotine, lead, etc.,

* Vide Frémineau, "Gaz. des Hôp.," 1863; Sämann, "Deutsche Klinik.," 1864.

which exert a toxic influence and thus impair the functions of the nervous system.

For practical purposes we must, however, draw a line of demarcation between the amblyopiæ which are due to simple irregularities in the circulation or nervous functions, and those which depend upon some blood poisoning, if this term may be accepted.

The insufficiency of blood supply which gives rise to the *anæmic amblyopia* may be due to some excessive discharge from the uterus, to the debility consequent upon very severe illnesses,* to a prolonged and very exhausting confinement, or to over-suckling. Copious hæmorrhages (*e.g.*, after confinement) may likewise produce it. Cases are also recorded in which vomiting of blood (probably dependent upon an ulcer of the stomach) has produced amaurosis.* In these cases, the loss of sight had come on rapidly (leading to complete blindness in the course of a few days), which affected both eyes, and was incurable. The ophthalmoscopic appearances were either negative, or were those of anæmia of the optic nerve and retina, leading subsequently to atrophy. When the loss of blood is very considerable, the function of the optic nerve is probably impaired by the anæmia of the brain and the insufficient excitation of the retina. But it is remarkable (as Von Graefe has pointed out) that the sight does not necessarily return with a restoration of the blood-supply and a restitution of the other functions. This is probably owing to the fact, that the temporary deficiency in the blood supply has caused permanent changes in the nutrition of the more delicate nerve structures.

The amblyopia which is met with in diabetes is sometimes due to paralysis of the accommodation, or to retinitis, somewhat akin in its nature to that met with in Bright's disease, and only rarely to anæmia. In *cholera* we might expect that there would be great amblyopia on account of the poverty of the blood, but this is not so.

Congestive amblyopia may be due to over-fulness of the system and congestion of the eye, brain, or other organs. It is not unfrequently met with in cases of suppression of customary discharges, deficiency or absence of the catamenia, and insufficient action of the skin or kidneys. Mr. Lawson† narrates a case in which suppression of the menses produced, within a few days, complete amaurosis in one eye and great impairment of vision in the other.

Under the use of iodide of potassium, and with the re-appearance of the catamenia, the sight was restored.

A very interesting and extraordinary case is also reported by Mr. Lawson,‡ in which amaurosis repeatedly recurred during the period of gestation.

* O'Reilly, "Lancet," 1852; Von Graefe, "A. f. O.," vii, 2, 143.

† "Med. Times and Gazette," 1863. ‡ "R. L. O. H. Rep," iv, 65.

The real nature of the amblyopia which is observed in certain cases of so-called blood poisoning is at present quite obscure. It is generally supposed to be due to some disturbance in the circulation, producing what is termed passive congestion of the brain. But this explanation is indefinite and unsatisfactory, for, as Von Graefe says,* "Whether there is a real inundation of the nervous centre, with venous blood,—whether the current and change of the blood is too slow only,—or whether the visual function is affected from the blood being overloaded with alcoholic and narcotic substances, are so many questions suggested by the term 'passive cerebral congestion.' This term, therefore, only serves to designate a condition where, failing all evidence of active congestion, the functional, or, as the case may be, also the nutritional excitation of the cerebral centre of the optic nerve is interfered with by circulatory influences of the aforesaid order."

This toxic influence may be especially produced by alcohol, tobacco, lead, and quinine.

The amblyopia met with in drunkards (amblyopia potatorum) generally commences with the appearance of a mist or cloud before the eyes, which more or less surrounds and shrouds the object, rendering it hazy and indistinct. In some cases, the impairment of vision becomes very considerable, so that only the largest print can be deciphered, but if progressive atrophy of the optic nerve sets in, the sight may be completely lost. The visual field may remain normal or become more or less contracted. The affection may exist for a very long time without causing any organic changes in the optic nerve or retina, excepting those of hyperæmia, and a certain loss of transparency in the disc. In other cases, if the disease progresses or the cause persists, atrophy of the optic nerve supervenes, and this always materially clouds the prognosis; for although we may, even in such cases, sometimes succeed in securing a great improvement of sight and an arrest of the atrophic degeneration, yet the vision is but seldom restored *ad integrum*.

In many of these cases, we cannot detect any abnormal appearances with the ophthalmoscope, and must therefore regard the impairment of sight as due to a functional, and not to an organic, lesion. In other cases there is some hyperæmia of the retina and optic nerve, with, perhaps, a certain degree of passive congestion, together with a diminution in the transparency of the disc, and subsequently symptoms of atrophy of the optic nerve may make their appearance. But I must here again warn the reader against too readily assuming the existence of hyperæmia and congestion of the optic nerve and retina, simply because the disc may seem to him to be slightly too red, or the veins somewhat large. It has been already stated that the appearances of the optic disc and of the retinal circulation vary very greatly within a perfectly physiological

* "Ophth. Review," ii, p. 340.

standard, and that it often requires an experienced and careful observer to determine whether or not some marked peculiarity in the appearance of these structures is physiological or pathological. In judging of these conditions, we must take into especial consideration the age, the habits, the complexion, etc., of the patient.

The prognosis will depend chiefly upon the condition of the optic nerve, the length of time which the disease has existed, and the fact whether or not the patient is willing entirely to give up any habits which may have caused it.

The effect of tobacco in producing amblyopia and amaurosis was originally pointed out by Mackenzie; more lately Critchett, Wordsworth, Hutchinson, and Sichel have, amongst others, paid much attention to this subject, and believe that it gives rise to a peculiar and distinctive form of loss of sight, which they have therefore termed "tobacco amaurosis." It is supposed to produce a peculiar form of atrophy of the optic nerve, the symptoms of which are so special as to be considered characteristic of tobacco amaurosis (*vide* article on Atrophy of the Optic Nerve, p. 387). One argument which has been brought forward to lend special weight to the theory that tobacco may produce amaurosis is, that simple progressive atrophy of the optic nerve occurs far more frequently amongst men than women. Whilst readily conceding this, I must also call attention to the fact that the causes which may produce amaurosis obtain far more amongst men than women. Thus the former are, as a rule, exposed to far greater corporeal and mental labour, to greater vicissitudes, and to a greater indulgence in free living of every kind. Moreover, in all probability, the amaurosis is far more due to a combination of such deleterious influences than to the prevalence of one special one, *e.g.*, tobacco. At least, in by far the greater number of cases of amaurosis which I have met with in heavy smokers, the patients readily admitted their free indulgence in other excesses. I fully admit the fact, that the excessive use of tobacco (but most frequently together with other causes) may produce considerable impairment of vision, and finally, if the habits of the patient be not entirely changed, and the use of tobacco, stimulants, etc., given up, even atrophy of the optic nerves. But I cannot, from my own experience, accede to the doctrine that there is anything peculiar in the form of atrophy of the optic nerve, which would at once enable one to diagnose the nature of the disease, as depending upon excessive smoking. For the three peculiarities particularly insisted on, viz., the premonitory hyperæmia of the disc, the blanching of the latter first at the outer side, and the diminution in the size or even disappearance of the nutritive vessels of the optic nerve, whilst the retinal vessels for a very long time retain their normal calibre, are met with in other forms of atrophy of the optic nerve, and are therefore not at all distinctive of tobacco

amaurosis. Indeed it is impossible to understand why tobacco alone should produce these peculiar changes. I believe that in the commencement of the amblyopia of smokers and drunkards the disturbance of sight is at first only functional, the retina being, so to say, "blunted," and its sensibility impaired, so that it does not re-act with normal acuteness. This impairment of its function is probably chiefly due to some irregularity in the circulation in the nervous centres, although it is also probable that in many cases (especially of tobacco amaurosis) there is some depressing influence exerted directly upon the nervous system. The truth of this hypothesis is proved by the fact that at first the optic nerve and retina are quite healthy or only somewhat hyperæmic, and that great and rapid improvement takes place when the patient relinquishes smoking, drinking, etc., and is submitted to a tonic course of treatment, together, perhaps with local depletion. But if the cause persists, if the patient continues his indulgence in smoking, drinking, etc., combined, perhaps, with severe mental or corporeal exertion, then the disease does not remain confined to mere functional derangement, but generally passes over into an organic lesion. The optic disc begins to show symptoms of atrophic degeneration, and the latter may gradually but steadily advance until the sight is greatly impaired or even quite lost (Graefe).

The absorption of *lead* into the system will produce amaurosis. I have only met with one case in which the loss of sight could be distinctly traced to lead-poisoning. This was in a young woman, who a few months ago came under my care at Moorfields. She had been a worker in lead, and had suffered from severe lead poisoning. She was completely blind, and both optic nerves showed marked symptoms of atrophy consecutive upon optic neuritis. Mr. Hutchinson has mentioned to me that he has seen similar instances, in which lead-poisoning had given rise to optic neuritis, followed by atrophy of the optic nerves. Very generally, however, the only symptoms revealed by the ophthalmoscope are congestion and hyperæmia of the optic nerve and retina, the veins especially being somewhat dilated and tortuous. The sight and field of vision are even in such cases often considerably impaired. It must be mentioned that albuminuria is sometimes met with in lead poisoning, and that consequently albuminuric retinitis may occur (Ollivier, Desmarres).

Quinine in large doses has been in rare instances observed to produce amaurosis, probably by causing great congestion of the cerebral circulation, as much benefit was derived from the use of the artificial leech.

Uræmic amblyopia. In the article upon retinitis albuminurica, it was mentioned that very sudden and complete blindness sometimes occurs in Bright's disease, and is due to uræmic blood poisoning. The

sight may be lost within a very few hours, together with the appearance of symptoms of uræmic blood poisoning, such as great pain in the head, epileptoid fits, etc.* Then, on the subsidence of these symptoms, the sight is also restored. This impairment of vision must be carefully distinguished from that dependent upon retinitis albuminurica.

Amblyopia is sometimes due to reflex irritation originating in one of the branches of the fifth nerve, or in other parts of the nervous system. Thus severe and prolonged dental neuralgia may produce impairment of vision, which mostly disappears with the removal of the carious teeth. The ophthalmoscopic examination generally only affords negative results.† In a case of abscess of the antrum from a carious tooth, narrated by Dr. James Salter, the eye was considerably protruded and blind—the ophthalmoscope revealing extreme anæmia of the optic nerve (atrophy?). The sight was not improved by the removal of the tooth. In a case of herpes frontalis, accompanied by great pain, recorded by Mr. Bowman, the optic nerve was atrophied.‡

When one eye is excluded for any length of time from binocular vision, its sight generally begins to fail from non-use of the eye. This condition is termed *amblyopia ex anopsia*, and is especially met with in cases in which, on account of the presence of some opacity of the cornea or lens, or of strabismus accompanied with diplopia, the acuteness of vision of one eye is considerably greater than that of the other, so that the difference in the distinctness of the two retinal images proves very confusing to the patient, and, in order to remedy this, he unconsciously suppresses the recognition of the less distinct image. This *active* suppression of the one image by the mind must be distinguished from its *passive* suppression caused by a dense opacity of the cornea or lens, the presence of which prevents any image being formed upon the retina. The active suppression of the retinal image is far more injurious to the sight than the passive. But both are especially so in children, for in them we often find that after a strabismus has existed for some time (six or twelve months), the sight of the eye may be so much impaired that only large print can be deciphered with this eye, and yet it appears in all other respects perfectly normal. Moreover, if the squint is operated upon, and the eye then practised separately with strong convex glasses, the sight may be rapidly restored, if the impairment of vision had not reached too high a degree. This proves that the defect of sight is not congenital, as has

* A case of this uræmic amaurosis followed afterwards by retinitis albuminurica is recorded by Graefe, "A. f. O.," vi, 2, 277.

† Cases of amblyopia, accompanying dental neuralgia, have been recorded by Mr. Hutchinson, "R. L. O. H. Rep.," vol. iv, 381; also by Wecker, "Ann. d'Oculist," 1866.

‡ "R. L. O. H. Rep.," v.

been sometimes supposed, but is due to the exclusion of the eye from binocular vision and consequent disuse of the retina. Besides, if the squint is alternating, so that each eye is used in turn, the sight of both remains perfectly good. The rare cases of non-alternating strabismus, in which the sight of the squinting eye still retains its normal acuteness, are probably due to their not enjoying binocular vision, in consequence of which there is no diplopia, and of course no active suppression of the double image. This subject, however, is more fully treated of in the article upon Strabismus. In children, even the passive exclusion of the eye (*e.g.*, from cataract) leads to amblyopia far sooner than in adults, in whom complete cataract may exist for very many years (Von Graefe has recorded such a case in which a cataract had existed for sixty years), and yet, when it has been successfully removed by operation, the patient can see perfectly. In children, however, this is not the case, and the sensibility of the retina is apt permanently to suffer; hence the rule, that in children cataract as well as strabismus should be operated upon soon after its appearance.

Sudden and severe blows upon the eye may produce complete and instantaneous blindness, apparently from paralysis of the retina (*commotio retinæ*). The same has been observed after a stroke of lightning.* The ophthalmoscope generally reveals no symptoms at all commensurate with the degree of blindness; perhaps there is only some hyperæmia of the retina and optic nerve, or a few scattered blood extravasations. In other cases nothing abnormal is observed, and the loss of sight is probably due to some disturbance or derangement in the retinal elements, which are, however, invisible with the ophthalmoscope. But Wecker mentions a case in which atrophy of the optic nerve subsequently supervened.* The sight in these cases of paralysis of the retina, often becomes perfectly restored, even although all perception of light may at first have been lost.

The treatment of the different forms of amblyopia must vary with the cause of the affection. Thus, in cases where the latter is evidently due to great debility, consequent, perhaps, upon severe illness, hyperlactation, etc., tonics, a generous diet, plenty of exercise in the open air, sea bathing, etc., must constitute the chief remedial agents. Whereas, in the congestive amblyopia great attention must be paid to the free action of the various eliminative organs, more especially the liver, skin, and kidneys. For this purpose saline mineral waters, diuretics, hot stimulating pediluvia, and the hot air or Turkish bath, will prove of special advantage. In Germany the prolonged use of the decoction of Zittman is a favourite remedy, but this mode of treatment is accompanied by so much inconvenience, that but few English patients will submit to it. In the congestive amblyopia, I have often derived

* Vide also Sämisch, "Kl. Monatsbl.," p. 22, 1864.

the greatest benefit from the repeated use of the artificial leech. In some cases, even its first application was followed by the most marked and surprising improvement in the sight. Hence, I would particularly insist upon the necessity of always giving the artificial leech a trial in cases of amblyopia or amaurosis, in which there is evidence or suspicion of congestion, or of irregularities in the circulation; for this remedy is at present far too much neglected in England. The blood should be drawn rapidly, so that the glass cylinder becomes filled in three or four minutes. One or two cylinders full from each temple (if both eyes are affected) will generally suffice. The operation may be repeated at intervals of five or six days, but if there is no improvement of sight after it has been performed two or three times, it should not be repeated. After each application of the artificial leech, the patient should be kept in a darkened room for about 24 hours, as the operation is generally followed by a good deal of reaction in the intra-ocular circulation.

We must also insist upon the patient leading a most regular life, and abstaining from excesses of every kind, and in the amblyopia potatorum the allowance of spirituous liquors must be cut down to a minimum. If the nervous system is enfeebled, tonics must be administered in considerable doses, more especially steel, either alone or in combination with quinine or strychnine. The Tinct. Ferri Muriat. (from gtts. xv to ʒss. or more, two or three times daily) often proves of much benefit.

In order to alleviate the extreme restlessness and nervous irritability of such patients, digitalis or hyoscyamus should be prescribed, and morphia should be administered at night to relieve the great and very trying sleeplessness, or the subcutaneous injection of morphia may be employed with advantage.

In tobacco amaurosis the greatest stress must be laid upon the *absolute necessity* of the patient's entirely giving up the use of tobacco. Only in this way can we hope to cure or arrest the disease. Moreover, it is generally more easy for a great smoker to break himself at once and altogether of the habit, than to limit himself to one or two cigars or pipes a day, for then the temptation of exceeding this amount is constantly presented to him. At the same time tonics (particularly the tincture of steel, alone or in combination with strychnine) should be prescribed. By pursuing this course of treatment, we may generally succeed in rapidly curing the amblyopia if it be still only functional, or of arresting it and greatly improving the sight if the optic nerve is only slightly atrophied.

In the impairment of vision from lead poisoning many remedies have been recommended, of which the most reliable is probably opium. This has been found to shorten the course of the constitutional disease, to diminish the frequency of paralytic affections, and to prevent

relapses. The subcutaneous injection of morphia has been employed with much benefit in amblyopia saturnina by Dr. Haase.* As a rule, such cases afford a favourable prognosis if symptoms of optic neuritis or atrophy of the optic nerve have not supervened. The patient must, however, be warned not again to expose himself to the risk of renewed lead-poisoning, otherwise a relapse may occur.

The amblyopia due to disuse of the eye is best treated by methodically exercising the sight in reading, etc., with the aid of a strong convex lens, or still better, Von Graefe's combination of two lenses set in a small tube. The eye should be practised frequently during the day, but only for the space of two or three minutes at a time.

In the loss of sight, dependent upon paralysis (commotio) of the retina, antiphlogistics (more especially the artificial leech, blisters, etc.) should be at first applied. Subsequently electricity should be tried, and strychnine (perhaps in combination with tonics) be administered. Wecker recommends the use of subcutaneous injections of strychnine.

2.—HEMERALOPIA.

This disease is especially characterised by the fact that although the patient may be able to see very well during the bright daylight, his sight rapidly deteriorates towards dusk, and still more so at nightfall; hence the term night blindness. When the illumination is insufficient, a more or less dense grey, or purple cloud surrounds and renders all objects indistinct and hazy, and also impairs the power of distinguishing colours. Thus, according to Förster,† certain colours, especially white, yellow, and green, can be more readily distinguished than blue, violet, or red. The pupil is wide and sluggish on the admission of light, but reacts normally on irritation of the branches of the fifth., *e.g.*, on the instillation of tincture of opium. In retinitis pigmentosa, the pupil is, on the contrary, contracted. In severe cases the impairment of sight may be so great, that even large objects cannot be distinguished when the light is much diminished. It is, however, an error to suppose that the dimness of sight is due to the setting of the sun, and that it is thus linked to a certain time of the day. Identically the same symptoms appear if the illumination is artificially diminished, by placing the patient in a darkened room. This fact was most satisfactorily proved by Förster, with his ingenious optometer. The dimness of vision is only due to an impairment of the sensibility (torpor) of the retina, so that the patient requires the full stimulus of bright daylight, or artificial light, in order to see distinctly. This impairment of the sensibility of

* "Klin. Monatsbl.," 1867, 225.

† "Uber Hemeralopie," Breslau, 1857.

the retina may either be due to an insufficiency of blood supply, to the impoverished condition of the blood, or to the nerve elements of the retina having been over-stimulated by prolonged exposure to extremely bright light. Very frequently, the hemeralopia is a result of a combination of these causes.

It appears however, to be true that in the early morning, after a sound and refreshing sleep, the sensibility of the retina is greater than at a subsequent period of the day, so that the patient is then able to see even by a somewhat diminished illumination.

It is of great consequence to distinguish between the simple hemeralopia, and that condition of night blindness which accompanies *retinitis pigmentosa.* The former is simply functional and curable, the latter depends upon organic changes in the retina, and at a later period in the optic nerve, and is incurable. Inattention to, or ignorance of these facts has led to great confusion in the writings of some authors.

Hemeralopia may be caused by prolonged exposure to extremely bright light, such as the rays of the sun in tropical climates, or the glare of a vast expanse of brightly glistening snow. The ill effects of such exposure make themselves especially felt, if the individual is in a condition of great debility or exhaustion, as after severe illness, or long deprivation of food. Thus, we not unfrequently find hemeralopia existing amongst sailors returning from the tropics, who have been kept for a length of time without sufficient food, and have, perhaps, been suffering from scurvy. I have several times had four or five sailors from one vessel under my care at Moorfields, for hemeralopia. Their story was always the same. They had just landed from their vessel, after a long exposure to a tropical sun and a scanty allowance of food, and they had generally been suffering from great debility, or from scurvy. The hemeralopia had diminished somewhat on their reaching a more temperate zone, and rapidly disappeared on their arrival in England, under the administration of tonics and the enjoyment of a generous diet. In none of these cases was I able to discover anything peculiar with the ophthalmoscope, the retinal veins were, perhaps, slightly dilated, but I could not trace any diminution in the calibre of the arteries. Indeed, in almost all cases of this form of hemeralopia, the ophthalmoscopic examination yields a negative result. In several of these patients there were distinctly noticed those peculiar, silvery grey, scaly patches of thickened epithelium at the outer portion of the ocular conjunctiva near the cornea, to which particular attention has been called by Bitot.* He considers these patches pathognomonic of hemeralopia, and states that they disappear consentaneously with the disappearance of the night blindness. I have, however, found them absent in several cases of hemeralopia, and they are evidently quite uncon-

* "Gazette Hepdom," 1863.

nected with this disease, and only due to a thickening and desiccation of the conjunctival epithelium from exposure to intense heat, which sets up a state of chronic congestion or inflammation of the conjunctiva. The appearance of these patches at the outer part of the cornea, is due to this portion of the ocular conjunctiva being most exposed, on account of the wideness of the palpebral aperture at this point.

Hemeralopia has also been observed to break out epidemically in gaols, camps, etc. I need hardly point out that in such cases, a careful examination should always be instituted, in order to guard against "malingering." According to Alfred Graefe, the accommodative power of the eye is often somewhat impaired, there being also a certain degree of insufficiency of the internal recti muscles.

The treatment must be chiefly directed to strengthening the general health by tonics and a generous diet. Amongst the former, quinine, steel, and cod-liver oil are the best; indeed cod-liver oil is considered by Desponts as a specific for hemeralopia. At the same time the patient must be carefully guarded against bright light. His room should be darkened, and he should only be allowed to go out when there is no sun, and even then wear dark eye protectors. If the attack of hemeralopia is severe, it may be even necessary to insist upon keeping him in perfect darkness for several days, and he should then be gradually accustomed to a greater and greater amount of light. Blisters and local depletion have been strongly recommended by some authors, but they are generally contra-indicated by the debility and feeble condition of the patient. But if there are marked symptoms of congestion and hyperæmia of the retina and optic nerve, the effect of the artificial leech should be tried.

In *snow blindness* the impairment of vision is also chiefly due to a diminution of the sensibility of the retina from the great and prolonged glare, but it may likewise perhaps be due to the effect of the great rarefaction of the atmosphere in high mountain ranges, which may produce not only inflammation of the conjunctiva with extravasations of blood into its tissue, but also perhaps hæmorrhagic effusions into the choroid and retina.

Closely allied to the above form of amblyopia, is the anæsthesia of the retina which occurs in consequence of prolonged exposure to extremely bright light (ueberblendung der retina). Instances of this kind, are met with amongst persons who have been long exposed to strong sunlight, or have greatly tried their eyes by excessive microscopising, etc., more especially by artificial light. They are often seized with a sudden dimness of sight, and notice (more especially if the illumination is but moderate) a more or less dense dark cloud or disc, which appears suspended before their eyes, and veils the central portion of an object or of the field of vision, leaving the periphery, perhaps,

quite clear. The density and extent of the cloud, and the consequent degree of amblyopia, as also its duration, are subject to considerable variation. Thus the cloud may only be observed for a few minutes after the exposure, or it may last for days and weeks, or even longer. The treatment should principally consist in guarding the patient against all use of the eyes and exposure to bright light. Indeed, if the case is severe, it may be necessary to insist upon his being kept in the dark for some length of time. The artificial leech is also often of much benefit. Cod-liver oil and steel should be prescribed internally.

3.—COLOUR BLINDNESS (DALTONISM).

By this term is meant the inability which many persons have of distinguishing between certain colours. The most frequent form of colour blindness is that, in which red and the colours in which it forms an ingredient, as well as its accidental colour, green, are more or less indistinguishable. Thus red either appears to be simply a dark colour, or the finer shades of red cannot be at all appreciated, and the difference between purple, orange, and brown is only distinguished with difficulty, whereas the difference between yellow and blue is readily recognised. Violet is also distinguished, but is often mistaken for blue. In rarer instances, green is the colour which cannot be recognised. The rarest cases of all are those in which the colour blindness is complete, the individual only distinguishing two colours, white and black.

It is generally held, that the inability to distinguish a certain colour (*e.g.*, red) is due to an insensibility of those nerve fibres of the retina which are sensitive to red. This view has, however, been lately strongly opposed by Max. Schultze,* who considers that in such cases it probably depends upon an excessive development of the yellow pigment in the region of the macula lutea, which has the effect of diminishing the intensity of the red rays of light.†

Colour blindness has been, as a rule, supposed to be congenital, and even hereditary, but the interesting fact has been observed by Benedict, Schelske, etc., that colour blindness may show itself in atrophy of the optic nerve, and according to Galezowski,‡ also in other diseases.

In a practical point of view the existence of colour blindness may often be of great importance, for instance in the case of railway guards, signal men, etc., who have to distinguish between lamps of different colours.

* Vide Max Schultze, "Ueber den gelben Fleck, etc.," 1866; also his work, "Zur Anatomie und Physiologie der Retina," 1866.

† In connexion with this subject, it is of interest that during Santonin intoxication everything acquires a yellow or greenish-yellow tint, but violet and red become indistinct. Vide articles upon this subject by Rose, "A. f. O.," vii, 2, 72; also Hüfner, ib., xiii, 2.

‡ Chromatoscopie Rétinienne, 1868.

4.—SIMULATION OF AMAUROSIS.

We occasionally meet with cases of simulated blindness, more especially amongst nervous, hysterical females, or persons who wish to shirk their duties, as soldiers, prisoners, etc. In sharp and clever individuals it is sometimes very difficult to convict them of deceit. Absolute blindness of both eyes is but seldom simulated, except, perhaps, in those cases, in which so considerable a degree of amblyopia really exists, that the patient is unable to gain his livelihood, and therefore pretends to be absolutely blind, in order to excite the commiseration and assistance of the charitable. In such cases, the behaviour of the pupil under the stimulus of light, is the best guide. For if a patient declares that he is so blind that he cannot distinguish between light and dark, and the pupils yet contract under the stimulus of light, we may with safety insist upon its being a case of simulation. Such patients, however, sometimes dilate the pupils artificially with atropine, and this may be suspected if they are dilated *ad maximum*, for in the mydriasis due to amaurosis (except the branches of the fifth nerve supplying the dilator pupillæ are irritated), the pupil is but moderately dilated. If the action of atropine is suspected, but a conviction appears impossible, paracentesis should, if practicable, be performed, and the aqueous humour applied to some other eye to see if it will produce dilatation of the pupil. Where the atropine has only been applied to one eye, the detection is far more simple, for not only will the pupil be dilated *ad maximum*, but it will not act consentaneously with that of the other eye, with the movements of the eyes, or during the act of accommodation (*vide* the article Mydriasis, p. 160). But there are several other methods of detecting the simulation of monocular amaurosis. One of the best of these is Von Gräefe's test with prismatic glasses. Thus, if a patient complains that he is absolutely blind in one eye, and the examination of this eye is concluded, that of the other (both eyes, however, being open) should be proceeded with, and a prism of 10° or 15° be held with its base upwards or downwards before the healthy eye. The patient should then be casually asked (so as not to arouse his suspicion that we suppose him to be deceiving), whether this improves the sight or not. If he says that it causes diplopia, the simulation is proved, for if he was absolutely blind in one eye diplopia could not be produced, whereas this would not exclude a considerable degree of amblyopia. The prism should be turned in different directions, in order that we may ascertain if the double images correspond to the position of the prism.

Dr. Von Welz* places before one eye a prism of 10° or 15°, with

* Congress Ophthalmologique, 1866; Compte-Rendu.

its base turned horizontally outwards or inwards. If a corrective squint arises, or if, on removal of the prism, there is any change in the position of the optic axes, it proves at once that the patient enjoys binocular vision.

Mr. Zachariah Laurence* employs the stereoscope for the purpose of detecting simulation of monocular amaurosis. The slide used for this purpose has two different words or figures (*e.g.*, a circle and quadrant) upon it, so arranged as to undergo an optical transposition when seen through a stereoscope. Mr. Laurence says, "Where blindness of one eye is simulated, the test is certain, if care is taken not to let the patient see the slide before putting it into the stereoscope, which for the purpose should be enclosed on all sides with ground glass. The patient would, from the fact of the transposition, expose the fraud by his own evidence, and condemn himself out of his own mouth."

Javal directs the patient to read some print, and then places a ruler between the eyes and the print, in such a manner that a portion of the type is excluded from the eye which is stated to be blind; the position of the ruler is then somewhat shifted to the other side, so that the affected eye can see the whole page, and a portion of the print is excluded from the healthy eye. If the patient can see with both eyes, the ruler will produce no disturbance, whereas if the one eye is really blind, a part of the type will be rendered invisible to the sound eye.

* "Handy Book of Ophthalmic Surgery," 17.

Chapter XI.

DISEASES OF THE CHOROID.

1.—HYPERÆMIA OF THE CHOROID.

A hyperæmic condition of the choroid is by no means so easy to diagnose with the ophthalmoscope as is often asserted, indeed it is frequently quite impossible to do so. On the one hand, the epithelial layer of the choroid may be so dense as completely to hide the choroidal vessels; on the other, the diversities, both in the amount and distribution of the pigment in the stroma of the choroid, are so various, as often to render it quite impossible to decide whether or not there is any hyperæmia. It is especially difficult, if both eyes present the same appearances, for we then lose the opportunity of comparing the affected with the healthy eye. Hyperæmia of the choroid may be suspected, if we notice, at one portion of the fundus, that the size and redness of the choroidal vessels seem to be increased, more especially of their smaller branches, so that the intra-vascular spaces appear encroached upon and somewhat crowded together; and more particularly if these symptoms have come on rather rapidly. The disc may also look somewhat flushed and hyperæmic. The external symptoms (*e.g.*, ciliary injection, dilated and tortuous ciliary veins, etc.) which have often been quoted as being indicative of hyperæmia of the choroid, are quite unreliable.

2.—DISSEMINATED OR EXUDATIVE CHOROIDITIS
(Plate II, Fig. 4.)

When this disease is at all advanced, it presents most characteristic and striking ophthalmoscopic appearances, which cannot fail to arrest the attention of the most superficial observer. But in the earliest stages it may easily be overlooked, more especially if it commences, as is very frequently the case, in the form of small, circumscribed exudations, situated quite at the periphery of the fundus. These small, round greyish-white spots of exudation vary much in size and shape. In some cases, they may not be larger than a millet seed, in others, they attain a considerable magnitude. The larger ones are, however, generally met

with in the centre of the fundus. The exudations occur both on the inner surface of the choroid and in its stroma. They are of a dull, whitish-yellow, or creamy tint, the epithelium around them being either normal, or but slightly thinned. At a later stage the exudations become absorbed, and the choroid, perhaps, undergoes some atrophic changes, becoming thinned and permitting the white sclerotic to shine through, which gives a peculiarly white and glistening appearance to the patch. On the expanse of the latter, we may also sometimes be able to trace the outlines of the faint choroidal vessels which traverse it. Around these atrophic patches, the epithelium does not retain its normal appearance, but its cells proliferate, increase in size, and contain a great quantity of pigment, which becomes collected around the margin of the white figure, in the form of a more or less broad, irregular, black girdle. The individual exudations often increase in size and coalesce one with another, thus giving rise to larger patches, which finally attain, perhaps, a considerable magnitude. From the periphery of the fundus, the disease extends more and more towards the posterior pole of the eye, so that at last the whole background of the eye may be thickly studded with innumerable white, or yellowish-white patches of varying size and shape, surrounded by a deep black fringe, and perhaps divided from each other by strips of healthy choroid. In such cases, we often have an excellent opportunity of watching side by side the various changes which the exudations undergo; from their first appearance, as opaque, creamy white spots, surrounded by unchanged epithelium, to the last stage of glistening white, atrophic patches, embraced by a deep black circlet of pigment.

In other cases, the disease commences in the region of the yellow spot, sometimes in its very centre. One or more small specks are noticed, the centre of which is of a paler red than the surrounding choroid; or the patch may be of a greyish white or creamy colour, with perhaps a faint, pale-red areola round it. The choroid in the region of the yellow spot is generally in such cases of a somewhat deeper tint. The white spots soon increase in number and size, are arranged perhaps in groups, and gradually extend towards the circumference. The periphery of the choroid may remain unaffected, or show only a few scattered groups of exudation.

Although we cannot with certainty diagnose the syphilitic character of the disease simply by the ophthalmoscopic symptoms, as we find that sometimes the most varied forms of this affection are due to syphilis, yet some authors consider that certain appearances are more especially symptomatic of the specific disseminated choroiditis. Thus Liebreich thinks that the latter is distinguished by the fact, that the little masses of exudation are small, circumscribed, isolated, and do not show any tendency to coalesce, even when they are grouped closely

together. The tissue changes extend deeply into the stroma of the choroid. These appearances are well illustrated in the ophthalmoscopic plates (Plate II, fig. 4). Von Graefe thinks that syphilitic disseminated choroiditis shows itself most frequently in the form of numerous circumscribed white patches, with a pale red zone around them, and occurring at the posterior pole of the eye; and which but rarely pass over into any other form of choroiditis. I have also found this form of choroiditis more frequently associated with syphilis than any other. But yet it must be admitted that it may occasionally assume most varying appearances. Thus I have seen cases of syphilitic choroiditis in which a large bluish-grey exudation has occupied the region of the yellow spot, and around this were scattered to a considerable distance numerous smaller exudations and atrophic patches, the periphery of the fundus being almost free from any exudations. These appearances (more especially the grey, nebulous effusion) at the yellow spot, were almost perfectly identical in both eyes.

The *areolar choroiditis* of Förster* is distinguished by certain peculiar features, which show under what different forms the disseminated choroiditis may present itself. I would therefore rather consider it as a subdivision of this affection, than as a special disease. The spots are large, oval or circular, sharply defined, and of a white, or yellowish white colour, having traces of faintly marked choroidal vessels in their area. They are separated from each other here and there by strips of normal choroid. They are chiefly grouped around the optic disc, but are divided from it by a portion of healthy choroid, so that they do not reach up to it. Their size varies considerably, some being nearly as large as the optic disc, others about the size of a pea; they always diminish, however, towards the periphery. The patches are surrounded by a dark zone of pigment, which is the more broad and marked the smaller that the central white spot is. Quite at the periphery of the group of white patches, are noticed dark, black spots, having no white centre.

The diagnosis of disseminated choroiditis is not difficult, and it could not very easily be mistaken for any other disease. The fact that the little white exudations are situated in the choroid, and not in the retina, may be easily ascertained by attention to the following points, viz.: the retinal vessels can be traced distinctly over them, and are not the least interrupted or rendered indistinct in their course; there are no appearances of blood effusions into the retina, which generally occur together with exudations into the latter; the retina is also transparent, and of normal appearance around the exudations, and the retinal veins are not dilated or tortuous. When the exudations are absorbed and the choroid undergoes atrophy, the patches become fringed with pig-

* Förster, "Ophthalmologische Beiträge." Berlin, 1862, page 99.

ment, and upon their expanse can be noticed remains of the choroidal tissue and of the vessels. Care should be taken to distinguish this form of pigmentation, from the deposits of pigment in the retina which may occur in various forms of choroido-retinitis, as also in the disseminated choroiditis, in which the external layer of the retina becomes more or less glued against the choroid, and destroyed or atrophied, or the pigment of the epithelial layer of the choroid becomes infiltrated into the retina. In such cases, the rods and bulbs are especially apt to suffer, but the changes may extend deeper, and even involve the ganglion cells.

Again, the retina may suffer by becoming compressed by the exudations and aggregations of the pigment cells, and if this lasts for any length of time, the retina gradually becomes thinned and atrophied, being changed into a kind of fibrillar tissue, and its normal elements rendered quite indistinguishable. Thus, consecutive atrophy of the retina and optic nerve not unfrequently ensue upon disseminated choroiditis. In Plate II, fig. 4, these appearances are illustrated. The optic disc is seen to be perfectly atrophied, of a bluish grey tint, and utterly devoid of blood-vessels, excepting the two little twigs which can just be discerned running over its edge. Not a single retinal vessel can be distinguished over the whole fundus. It is but very seldom that we meet with so extreme a case of atrophy, and Liebreich supposes that in all probability a syphilitic retinitis had co-existed with the disseminated choroiditis.

The vitreous humour also frequently becomes affected during the progress of the disease; indeed floating or fixed opacities in it are sometimes the first or even the only premonitory symptoms, which call the patient's attention to his eye. I have met with several cases, in which a few small floating opacities in the vitreous humour formed the first symptom, there being at that time no trace of disseminated choroiditis to be detected by the most careful ophthalmoscopic examination. But some time afterwards, small circular patches made their appearance in the choroid. Sometimes, however, the vitreous does not become affected till a late stage of the disease, and it may then be so diffusely clouded as to render the details of the fundus quite indistinct, or be traversed by large, dark, floating or fixed membranous filaments. Subsequently a posterior polar cataract is often formed.

The iris sometimes becomes inflamed, but hardly ever to a considerable degree, there being only a few delicate synechiæ, and very little alteration in the structure of the iris. The inflammation often assumes a serous character, and small opacities are noticed on the posterior wall of the cornea. The external appearance of the eye is generally quite normal; there is hardly any conjunctival or subconjunctival injection, photophobia, or lachrymation, and little or no pain; the pupil being often of a

normal size, or but little dilated; and yet the sight may be greatly impaired; and it is only with the ophthalmoscope that we detect the great and striking changes in the fundus.

The sight is often very considerably affected, the patient complaining of a dark cloud, or of black, fixed, and floating objects before his eyes. These scotomata are either due to diffuse and floating opacities in the vitreous humour, or to injuries which the retina has sustained by compression or destruction of some of its elements. The impairment of vision will, of course, be proportionately greater, if the disease is situated at the posterior pole of the eye, than if it be confined to the periphery of the fundus. In the former situation, a very small and circumscribed group of exudations may suffice to destroy central vision; in the latter, even considerable deposits may not materially affect the sight, except in the outline of the field. Not only does the central vision suffer as regards distinctness, when the exudations occur in the region of the yellow spot, but the objects appear distorted and crooked (metamorphopsia), on account of the compression and alteration in the arrangement of the retinal elements. We sometimes notice a marked improvement in the sight, when the exudations are absorbed and the pressure diminished, but of course this can only occur if the retinal elements have not suffered too much, or for too long a period.

The field of vision is frequently considerably contracted, and shows more or less extensive interruptions (scotomata) within its area.

The prognosis of the disease must always be extremely guarded, more especially if the exudations appear in the region of the yellow spot. Of these, the little spots surrounded by a pale-red rim, which are so characteristic of syphilis, afford comparatively the best prognosis.

In the most favourable cases the exudations may become absorbed, leaving behind them only faint traces of a change in the epithelial layer, in the form of light red patches in which the choroidal vessels can be distinctly traced; or they may give rise to somewhat deeper cicatrices. More frequently, however, they produce extensive atrophy of the stroma of the choroid, which is especially apt to be injurious to the sight if the exudations are large, situated in the region of the yellow spot, and coalesce together so as to form extensive atrophic patches. Moreover, in forming our prognosis we must always bear in mind that the retina is very prone to suffer, both from direct compression of its elements and from their destruction (more especially the rods and bulbs) from becoming glued to the choroid, and pigment being infiltrated thence into the retina. Atrophy of the retina and optic nerve are therefore not an unfrequent consequence of disseminated choroiditis.

The causes of this disease are often obscure, but by far the most frequent is syphilis. The insidious choroiditis, which is accompanied

by serous iritis, is sometimes observed in delicate, scrofulous, or consumptive individuals.

The treatment must consist chiefly in the administration of mercurials. Indeed the inflammatory diseases of the choroid appear to be most beneficially influenced by small doses ($\frac{1}{20}$ or $\frac{1}{16}$ of a grain 2 or 3 times daily) of the bichloride of mercury, continued for a very long period. If there are distinct evidences of syphilis, and if the disease is rapid in its progress, salivation should be quickly induced, so as, if possible, to check the further effusion of lymph and hasten the absorption of that already exuded. If this be not done, larger doses of the bichloride, in combination with the iodide of potassium, should be given. The artificial leech should be applied occasionally, but if the patient is very feeble but little blood should be taken, or dry cupping should be substituted. He must be strictly ordered to abstain from all use of the eyes in reading, etc., and they should be guarded against bright light by the employment of blue glasses. If the functions of the liver, uterus, or digestive organs are out of order, these should be attended to; and much benefit is often experienced from the use of mildly purgative mineral waters, such as the Pullna, Marienbad, Karlsbad, etc.

3.—SCLEROTICO-CHOROIDITIS POSTERIOR (POSTERIOR STAPHYLOMA, SCLERECTASIA POSTERIOR). Plate II, Fig. 3.

This disease is but seldom absent in the more considerable degrees of myopia, and must be regarded, more especially if it is progressive, as a more or less serious complication.

Eyes affected with sclerotico-choroiditis posterior generally appear to be abnormally large, prominent, and ovoid in shape. The palpebral aperture is widely open, which is especially conspicuous if only one eye is affected. The eyeball also appears lengthened in its antero-posterior diameter, and the infundibulum or hollow, which is seen in the normal eye (when it is much turned in) between the outer canthus and the globe, has disappeared; so that the posterior segment of the eyeball appears lengthened and square, and perhaps of a slightly bluish tint. The lateral movements of the eye may be somewhat curtailed if the disease is extensive. The patients often complain of a feeling of tension and fulness in the eyeball, as if the latter were too large for the socket, and there may also be pain in and around the eye.

The disease can, however, only be diagnosed with certainty with the ophthalmoscope; for a considerable posterior elongation of the eyeball (posterior staphyloma) may exist without any appearance of sclerotico-choroiditis posterior.

The ophthalmoscopic symptoms are generally very marked and unmistakeable. The characteristic symptom is a brilliant white or pale

yellow crescent at the edge of the optic disc, generally at the outer side (in the reverse image it will of course appear towards the nasal side). This crescent may vary much in size, from a small white arc to a large zone, and extends perhaps all round the disc and embraces even the region of the yellow spot, its greatest extent being always in the direction of the latter.* Its edges may be either sharply and distinctly defined, or may be irregular, and gradually lost in the surrounding healthy structures; irregular patches of pigment are strewn about its margin, and also, perhaps, on its surface, so that little dark islets of varying size and form appear in its expanse. The crescent itself is of a brilliant white, so much so indeed, that the disc, by contrast, appears to be abnormally pink. On account of the white background, the small retinal vessels can be traced more distinctly, and their minute branches be more easily followed over this patch than in the neighbouring fundus. This white crescent is due to a thinning and atrophy of the stroma of the choroid, indeed the latter has occasionally been found quite wanting in this situation. The pigment cells are not necessarily destroyed, but there is an absence of pigment molecules, for the irregular black patches mentioned above are pathological agglomerations of pigment. On account of the loss of pigment and the atrophy or thinning of the stroma of the choroid, the glistening sclerotic shines through the latter, and lends the brilliant white appearance to the figure. This want of pigment also gives rise to the sense of glare, which the patient experiences in a bright light. The amblyopia which frequently exists in this disease, is also undoubtedly partly due to this fact, for we find that the sight of such patients is often remarkably benefited by blue spectacles. The amblyopia, however, as a rule, depends chiefly upon the disturbance in the intra-ocular circulation, produced by the state of chronic congestion of the venous system of the eye. Hence we find that vision is generally greatly improved by depletion, and more especially by the artificial leech.

The retina generally suffers only in so far from this loss of pigment in the choroid, that a slight diminution in the distinctness of perception is produced. The "blind spot" (answering to the optic entrance) is somewhat enlarged, but this increase does not correspond at all to the size of the crescent, and vision is only impaired, not destroyed, in this extra portion of the blind spot. But sometimes there arises a state of great irritability of the retina, producing considerable amblyopia

* We must, however, be careful not to call every little white rim at the edge of the disc sclerotico-choroiditis posterior, for this may be caused simply by the choroid receding somewhat from the optic nerve, and permitting the light to fall at this spot through the retina upon the denuded sclerotic, thus affording the appearance of a white glistening rim. But this arc is very narrow, and there are no appearances of atrophy of the choroid, or irregular patches of pigment at its edges.

and disturbance of vision, together with photopsia and a feeling of pain and tension within the eye on the slightest exertion in reading, etc.

The disease may remain stationary or progress. In the former case the myopia does not increase, the circum-orbital and intra-ocular pains diminish or cease, and with the ophthalmoscope we find that there is no augmentation in the size of the crescent, and that, perhaps, a regular deposit of pigment again takes place.

Far different is it if the disease progresses, which is generally the case when the atrophy is at all advanced. The myopia is then found to increase more or less rapidly, vision becomes dimmed or greatly impaired, the patients are often continually haunted by "blacks" floating before their eyes, which may assume all kinds of fantastic shapes, and are due to opacities in the vitreous humour. At other times, they are greatly disturbed by showers of bright stars and flashes of light, which are due to a state of irritation of the optic nerve and retina; and they become more and more dazzled by the light on account of the increased atrophy of the choroid and the loss of pigment. But the progress of the affection is best watched with the ophthalmoscope. The edges of the crescent show symptoms of hyperæmia, and become irregular and ill-defined. Small white patches appear around it (symptomatic of the progressive atrophy of the choroid), and these, gradually increasing in size, coalesce with each other and with the original crescent, so that the latter may in time extend completely round the disc, which thus becomes embedded in a more or less broad, white, glistening ring, which extends chiefly in the direction of the yellow spot. In such cases, a superficial observer might suppose that the optic disc was greatly enlarged, or even that the optic nerve (from the white appearance) was atrophied. On closer examination, however, the distinction between the disc and the white zone is easy, for the entrance of the optic nerve looks abnormally pink, on account of the contrast with the bright white of the surrounding ring, and its vessels are more easily traceable over the latter than on the disc.

A similar process may also occur in the region of the yellow spot. Little white patches appear, which increase in size and coalesce, giving the whole an appearance of alternate white and dark reticulated spaces, the white spots being due to the sclerotic shining through the atrophied stroma and pigment layer of the choroid. Von Graefe thinks that the retina may in this situation participate more rapidly in the disease than otherwise, on account of its being thinner at this spot. If the atrophy of the choroid in the region of the macula lutea, as well as that around the optic entrance, progress, the two separate processes may gradually extend towards each other (leaving less and less healthy structure between them), until they finally pass into each other, and form one large white figure.

The occurrence of the disease at the macula lutea generally causes great impairment of vision, and the patients then also complain of the constant appearance of one or more central, fixed, dark spots (scotomata) in the field of vision. It should be remarked, that they may be apparent to the patient long before we are able to detect with the ophthalmoscope any corresponding changes in the region of the yellow spot.

Von Graefe* has called attention to the important fact that glaucoma may supervene upon sclerotico-choroiditis posterior, and lead to great impairment of vision, or even blindness. The eye becomes hard, the ciliary vessels injected, the anterior chamber more shallow, the pupil dilated. The edge of the disc contiguous to the arc becomes sharply defined and slightly excavated, and the vessels somewhat displaced and curved as they pass over it. The cup extends quite up to the margin of the disc, which distinguishes it from the physiological form. This glaucomatous complication occurs chiefly in elderly persons, and is probably due to the fact that the sclerotic, losing some of its elasticity with advancing age, cannot, as heretofore, yield to the increased intra-ocular pressure, and hence the latter now exerts a deleterious effect upon the optic nerve, and causes it to become cupped. It is also sometimes met with in young individuals. The increased tension is, as a rule, not considerable in degree. Generally both eyes are simultaneously attacked. Iridectomy should be performed at an early stage, as no other remedy will stay the progress of the disease.

Complications.—Vitreous opacities are of very frequent occurrence in sclerotico-choroiditis posterior, and are often a source of great anxiety to the patient, for even the physiological motes are rendered very distinct in short-sighted eyes, on account of the circles of diffusion upon the retina. The vitreous opacities may be dark, fixed specks, or floating membranous films of varying size and shape (vide article on Opacities of the Vitreous Humour, p. 315).

Detachment of the retina is unfortunately another not unfrequent complication of the more considerable degrees of sclerotico-choroiditis posterior. Its extent may be at first but slight, and be produced by a serous or hæmorrhagic effusion between the choroid and retina; or it may be caused by the contraction of some of the exudations in the vitreous humour exerting traction upon the retina, and thus detaching it† (vide article on Detachment of Retina, p. 358).

Opacity at the posterior pole of the lens sometimes occurs in the later stages of the disease. This opacity is generally situated very close to the turning point of the eye, and hence remains immoveable, although the eye is turned in a different direction. Cataracta accreta, irido-choroiditis, and atrophy of the globe may close the scene.

* "A. f. O.," iv, 2, 153; and ib., viii, 2, 304.

† Heinrich Muller, ib., iv, 1, 372.

Causes.—The origin of the affection is still a matter of controversy. Without doubt, there generally exists a congenital (and often hereditary) tendency to elongation of the eyeball in the optic axis; and this must necessarily cause a stretching of the choroid in this direction, which is generally soon followed by consecutive atrophy of this membrane. The development of this prolongation of the visual axis is greatly favoured by the strong convergence of the optic axes, and the state of congestion of the eye which is produced during accommodation for near objects, more particularly if these are small and insufficiently illuminated. For during such accommodation, a certain pressure upon the eye always occurs, accompanied by increased intra-ocular pressure; in consequence of which the venous circulation within the eye becomes retarded, and a more or less considerable state of mechanical congestion is produced. Instances of such intra-ocular congestion are furnished by cases of amblyopia due to opacities of the cornea or lens, in which the myopia is caused by the patient's bringing small objects very near to the eye, in order to gain larger retinal images. A similar thing may occur if the patient, whilst using concave spectacles for reading, gradually approaches the book too near to his eyes. We occasionally find that vitreous opacities, and even detachment of the retina, occur in such cases soon after long-continued reading or working with spectacles.

This state of congestion and increased pressure of the intra-ocular fluids lead to softening and extension of the tunics of the eyeball. As the latter receives no support at the posterior pole from the muscles, the prolongation occurs chiefly at this point, the choroid being stretched and generally undergoing consecutive atrophy.

This secondary atrophy of the choroid, which gives rise to the crescentic white patch at the margin of the optic disc, has been considered by Von Graefe to be most likely due to a chronic inflammation of the sclerotic and choroid, and he has, therefore, designated it sclerotico-choroiditis posterior. Others again, have thought that it depends upon a circumscribed staphylomatous bulging of the sclerotic at this point, and hence have termed it staphyloma posticum. But against both these opinions exception might be taken.

This choroidal atrophy may, however, exist without any posterior staphyloma. Indeed, Schweigger states that a real staphyloma posticum, *i.e.*, a more or less sharply defined local ectasia of the walls of the eyeball, does not take place in the majority of cases of myopia. The presence of a posterior staphyloma may be diagnosed by means of the ophthalmoscope, particularly with the binocular, for we then see that the white, shining portion of the sclerotic exposed through the thinning of the choroid is not of normal curvature, but is peculiarly cupped backwards, giving rise at this part to a slanting position of the optic disc. Schweigger, moreover, thinks that the acuteness of vision is

diminished to an unusual degree in those cases of myopia, in which posterior staphyloma exists beside the optic nerve. This is the more likely to happen, as he has observed that in cases in which the existence of a posterior staphyloma was proved anatomically, the retina in the expanse of the bulging portion was generally found to be more or less changed in structure, and even atrophied and adherent to the remains of the choroid and sclerotic.

In opposition to Von Graefe's view, it has been urged that all symptoms of irritation and inflammation are frequently completely absent, at least at the commencement of the affection, and that the latter may even attain a considerable degree without their occurrence. But there is no doubt that such symptoms are almost always developed when the disease becomes considerable, and the myopia is high in degree. In the slightest forms they may be easily overlooked, but even in moderate degrees of myopia, and in youthful individuals, we not unfrequently observe symptoms of irritation, such as hyperæmia of the optic nerve, retina, and choroid, and it appears probable that a state of irritation, if not of inflammation, exists prior to the atrophy. Donders* thinks, "that almost without exception, the predisposition to the development of staphyloma posticum exists at birth; that it is developed with symptoms of irritation, which, in a moderate degree, do not attain any great clinical importance; but that in the higher degrees an inflammatory state almost always occurs, at least at a somewhat more advanced time of life, as a result, and as a co-operative cause of the development of the distension and of the atrophy."

Jäger† considers that this crescent or posterior staphyloma, as he terms it, is almost always congenital and often hereditary. It may, indeed, exist for many years, or even throughout life, without increasing in size, or without the occurrence of any choroidal changes in its vicinity, its margin remaining distinctly and sharply defined. But we more frequently find if the eyes are much used and the myopia increases at all considerably in degree, that the edge of the crescent becomes somewhat irregular and broken, and gradually increases in size; this being evidently due to inflammatory changes in the choroid. Indeed it may well be questioned whether even the congenital crescents may not be of inflammatory origin.

Prognosis.—This should be always very guarded when the disease is at all advanced, when the myopia is progressive, and when the opacities in the vitreous humour are considerable. It becomes still more questionable if the vitreous opacities are diffuse, or large and numerous, if the upper or lower portion of the visual field becomes clouded, which is premonitory or symptomatic of detachment of the

* "Anomalies of Refraction and Accommodation," p. 384.

† "Ueber die Einstellung des dioptrischen Apparates." Vienna, 1861.

retina; and, lastly, if the choroidal changes make their appearance in the region of the yellow spot. They show themselves in the form of small, isolated, whitish spots, around the edges of which there are little accumulations of pigment; these small whitish spots increase in size, and coalesce, and then the atrophy of the choroid becomes very apparent. During this process, the retina is more or less irritated, and this produces dimness of vision, which, however, disappears again when the retinal irritation subsides. These atrophic changes in the region of the yellow spot, give rise to fixed black spots in the visual field, which, if considerable, may render working at small objects impossible. The changes in the macula lutea generally commence first in one eye, and may for a time be confined to it, but sooner or later they mostly extend also to the other eye.

Treatment.—Patients suffering from sclerotico-choroiditis posterior should be particularly warned against working for any length of time at near objects, or with their head bent forward, for intra-ocular venous congestion is thus easily produced. It is also very injurious to read in a recumbent position. The best posture for reading is, to sit with the head thrown back, and to have the light falling on the book from behind, so that the page may be well illuminated, but the eye not exposed to the direct glare of the light. In writing, it is advantageous to use a sloping desk, so that the person need not stoop. If such patients are permitted the use of spectacles for reading and writing, we must particularly point out the danger of bringing the object too near when the eye becomes somewhat fatigued, as this will cause a strain of the accommodation. The work or book should then be laid aside, until the eyes have been thoroughly rested. In extreme cases, we should strictly forbid all work at near objects, either with or without spectacles.

The irritation of the retina which gives rise to the appearance of flashes of coloured light, or showers of bright stars, etc., is best relieved by the application of flying blisters to the temple or behind the ear. They may be with advantage repeated at intervals of six or eight days.

The feeling of glare and dazzling, of which many of these patients complain when they are in a bright light, and which often produces severe ciliary neuralgia and headache, is effectually alleviated by the use of blue spectacles.

If the inflammatory changes in the choroid are at all considerable or progressive, we should always prescribe a prolonged course of small doses of the bichloride of mercury (one-twentieth to one-twenty-fourth of a grain). Derivatives acting on the skin and kidneys, and hot stimulating foot-baths at night also prove beneficial.

If the eye is very irritable, the external tunics of the eyeball injected, the optic disc reddened and hyperæmic, and if the patient

experiences pain in and around the eye, together with a feeling of weight and heaviness in the eyeball, as if he can hardly keep his eyelids open, we must insist upon a complete rest of the eyes, and an absolute cessation, for some length of time, from all working at near objects. We must be extremely stringent in the enforcement of such directions, as the patients are too apt to resume work as soon as their eyes feel a little better, and then at once call up again all the symptoms of irritation and congestion, which may cause a rapid increase of the myopia and of any existing sclerotico-choroiditis posterior. Such cases are also much benefited by the use of stimulating lotions to the closed eye and its vicinity, by the eye-douche and by the application of the artificial leech. The greatest benefit is generally found from the use of the latter. I have often been able by its application to relieve the irritation of the eye, and the peculiar and very distressing feeling of heaviness and aching in the eyeball, when all other forms of treatment had proved of no avail. But when the disease is very considerable, and when there is any fear of a detachment of the retina, its use is often dangerous, for the sudden relief of the intra-ocular circulation is followed by a severe reaction, and temporary hyperæmia of the vessels of the choroid and retina; and hence an effusion of blood may take place and produce detachment of the retina.

4.—SUPPURATIVE CHOROIDITIS. (PANOPHTHALMITIS).

The course of this disease is generally very rapid and severe. It commences in the form of an acute and violent inflammation of the eye. The eyelids become very swollen, red, and œdematous, the upper lid hanging down in a large massive fold. The conjunctiva and subconjunctival tissue become injected, and there is a considerable, firm, gelatinous chemosis, which surrounds the cornea like a dusky-red girdle, and perhaps protrudes between the aperture of the eyelids when they are slightly opened. Thin muco-purulent discharge oozes out between the lids, but sometimes it is absent, and the edges of the lids and the chemotic swelling look dry and crusted. On opening the eye, we may find that the cornea is quite clear, but the anterior chamber is diminished in size, and occupied, perhaps, by a more or less considerable hypopyon; the aqueous humour is clouded, the iris pushed forward, discoloured, and of a yellowish hue; the pupil is sometimes dilated, in other cases of a normal size or slightly contracted and tied down by lymph, or its area occluded. The tension of the eye is often increased, and it is acutely sensitive to the touch; it is also prominent and its movements are greatly impeded, on account of the infiltration into the subconjunctival tissue. If the refractive media and the pupil are sufficiently clear, we observe a peculiar, yellowish, golden reflex from behind the

lens, in the anterior portion of the vitreous humour, which is due to a purulent infiltration of the latter. The retina may become infiltrated with serum, or undergo suppurative changes, and the latter also extensively affect the choroid and ciliary body. These changes cannot be seen with the ophthalmoscope, on account of the exudation into the pupil, or the opaque condition of the vitreous humour. There is often a serous effusion from the choroid, which causes either a circumscribed or complete detachment of the retina, or this may be produced by hæmorrhagic effusion from the choroid. Moreover, it must be remembered that, together with this pressure of serum or blood behind the retina, the contraction and shrinking of the exudations in the vitreous humour, and the consequent traction upon the retina from in front, tend to produce a very extensive detachment, generally of a funnel shape. Indeed, although the detachment may for a time remain partial and circumscribed, it almost always becomes complete as the disease advances.

The cornea may remain transparent throughout, but, as a rule, it becomes clouded, infiltrated with pus, and then gives way, shrivelling up into a little yellowish membrane, like wash leather; or it may remain entire, and a spontaneous perforation of the eyeball occur through the sclerotic, generally at or between the insertion of the recti muscles. The disease is mostly accompanied by very intense pain in and around the eye, which often extends over the corresponding side of the head and face. It is frequently most agonizing, until the eyeball perforates, or paracentesis is performed, on which it rapidly subsides. There are often also marked febrile symptoms, accompanied, perhaps, by severe vomiting. In other cases, the inflammatory symptoms and the pain are far less pronounced, and the whole course of the disease is more insidious and of a milder type, although its results may be just as disastrous. The sight becomes rapidly and very greatly impaired, so that the patient may only just be able to distinguish between light and dark, or not even this. He is, moreover, much troubled by subjective flashes of light, showers of bright stars, etc.

Amongst the most frequent *causes* of suppurative choroiditis are injuries* and wounds of the eye, and the lodgement of foreign bodies, more especially portions of gun cap or metal, within the eyeball, particularly in the ciliary body and vitreous humour; such cases being often accompanied by very severe inflammatory symptoms and intense pain. Although foreign bodies may remain for a length of time suspended in the vitreous humour without doing much harm, or may become surrounded by lymph, and thus encysted or encapsuled, yet this is only of very exceptional and rare occurrence, more particularly if they are considerable in size, and of a nature to set up irritation by undergoing

* Vide Arlt's "Bericht der Wiener Augenklinik," 1867.

chemical changes. Inflammation of the vitreous humour supervenes, extending to the retina and choroid, and the eye becomes destroyed by plastic irido-choroiditis, or suppurative panophthalmitis.

It may also ensue upon operations, such as those for the removal of cataract, either by extraction, or still more frequently after couching (vide the article upon Cataract). It occurs most frequently in old and decrepid individuals, or in instances in which the patients are exposed after the operation to bad ventilation, over-crowded rooms, or other influences which impair the purity of the air (pyæmia in a hospital, typhoid fever, etc.). It is an interesting and important fact, that eyes operated upon for chronic irido-choroiditis show very little tendency indeed to take on suppurative inflammation, even although the lens may have been removed, together with a portion of the iris and dense masses of exudation. Indeed, such eyes bear a great deal of operative interference with impunity.

Suppurative inflammation of the cornea and iris (as for instance in purulent and diphtheritic ophthalmia) may also be followed by panophthalmitis.

It may likewise be produced by a direct extension of the inflammation from the meninges to the eye, as in cases of typhus, cerebro-spinal meningitis, etc.; but it may also in such instances be due to metastasis, examples of which are not unfrequently seen in puerperal fever. A very short time after the occurrence of the embolism suffices to set up secondary metastatic foci of disease in even distant organs. According to O. Weber,* two days will suffice for this. This metastatic form of the disease may either assume a very severe and acutely inflammatory type, rapidly leading to suppurative disorganization of the globe; or it may run a more insidious but equally destructive course. It is chiefly met with in cerebro-spinal meningitis, puerperal fever, and pyæmia; and then almost invariably attacks both eyes.† It is a question whether it may not, in cerebro-spinal meningitis, be sometimes due to the exposure of the cornea to traumatic injuries, on account of the great lagophthalmos.

The prognosis is most unfavourable, for this is one of the most destructive and intractable diseases of the eye. It is but seldom that we can arrest its progress in time to save any useful degree of sight. In most cases it soon ends in atrophy of the eyeball, either with or without a previous perforation of the cornea or sclerotic and escape of some of the contents of the eye. The dangerous nature of the disease is especially terrible in cases of metastatic choroiditis, for instance in puerperal fever, or cerebro-spinal meningitis, as both eyes are generally

* Billroth, "Handbuch der Chirurgie."

† Vide Dr. Knapp's article on Metastatic Choroiditis, "Archiv. f. O.," xiii, 1, 127; also Dr. Wilson's paper on "Diseases of the Eye in Cerebro-spinal Meningitis," "Dub. Quart. Journ.," May, 1867.

affected, and then, if the patient should survive, it will be only to pass his days in utter blindness. But in some cases, the danger is not confined to the loss of sight, for even life may become imperilled, as Von Graefe has shown, by the extension of the suppurative inflammation to the brain, there setting up suppurative meningitis, which may prove fatal.

After perforation of the cornea or sclerotic has taken place, the intense pain and inflammatory symptoms generally at once subside to a very considerable degree. The eye diminishes in size and gradually becomes shrivelled up and changed into a small contracted stump, which, as a rule, does not remain painful, and is not prone to give rise to sympathetic ophthalmia, except indeed it contains a foreign body, which keeps up a considerable degree of irritation, and is always a source of danger to the other eye. Sometimes, however, the eye retains a certain size and consistence, not becoming completely atrophied, and, on the aqueous and vitreous humour becoming more transparent, we may be able to examine them with the ophthalmoscope, and find that fresh masses of exudation are effused; the lens subsequently becoming opaque.

The *treatment* must in the first place be directed to saving, if possible, some remnant of sight, and then if this be out of the question, to mitigating the great sufferings of the patient. Thus, if it be produced by a foreign body which it is possible to seize and extract, this should be done without loss of time, even although it may be necessary to pass the instrument into the vitreous humour (vide article upon The Presence of Foreign Bodies in the Vitreous Humour). If the lens is injured and swollen, it should be at once removed together with a considerable portion of the iris, if symptoms of severe inflammation supervene.

If there is a perforating ulcer of the cornea with hypopyon, either paracentesis (perhaps frequently repeated) or iridectomy should be performed.

If a foreign body has entered the vitreous humour and lies beyond our reach, and if it be small and has not injured the lens or committed any considerable mischief in its course, we must endeavour by the strictest antiphlogistic treatment to subdue the inflammatory complications, and if possible to prevent suppurative choroiditis. Indeed in some of these cases, the foreign body becomes encapsuled and remains inocuous, an excellent degree of vision being perhaps restored. But when a foreign body remains in the eye, we must always keep in mind the great danger of sympathetic ophthalmia. If the eye is hopelessly destroyed by the accident, it will be by far the wisest and safest course to remove it at once, so as not only to avoid all danger of sympathetic ophthalmia, but also the occurrence of suppurative choroiditis.

For when symptoms of panophthalmitis have supervened, it will be no longer safe to do so, because there is imminent risk of the suppuration extending to the brain and producing fatal suppurative meningitis. Cases, in which this has occurred after excision of the eyeball during acute panophthalmitis, have been recorded by Von Graefe, Knapp, Manhardt, etc.*

If the inflammatory symptoms are very severe, and of a sthenic character, cold compresses (iced) should be constantly applied as long as they prove agreeable to the patient. Leeches should be placed on the temple, and if the patient is strong and the suppuration has not already become too extensive, so as to afford little or no chance of arresting it, rapid salivation should be induced, in the hopes of checking the inflammation and preserving some degree of sight. Generally, however, this proves futile. The severe pain in and around the eye is often most relieved by hot poppy fomentations or poultices, and by the subcutaneous injection of morphia at the temple. If there is hypopyon, or the tension of the eye is much increased, paracentesis of the anterior chamber should be performed, and repeated at intervals of a day or two, or even less. If the eye is very distended and causes great suffering to the patient, the paracentesis may be made into the vitreous humour instead, which often affords great relief.

The patient's strength must be sustained by very nourishing diet, the free use of stimulants, and by the administration of tonics.

If the pain and inflammation are very severe and protracted, and so greatly enfeeble the patient as even to endanger life, it will be best to remove the eye at all hazards, even at the risk of an extension of the disease to the brain, in order at once to remove all source of pain, and thus enable the patient to regain his strength.

Knapp† has lately described two very interesting cases of embolism of the choroidal vessels. In each patient there existed well marked cardiac disease (in the one endo-carditis, in the other insufficiency and stenosis of the aortic valves with hypertrophy of the left ventricle). The affection of the sight was quite sudden, the patients noticing a dark cloud before the eye, which at first pervaded the whole visual field, but then became concentrated in the central portion. The impairment of vision does not occur with such great suddenness as in embolism of the central artery of the retina, nor to such an extent, for in the one case $V = \frac{1}{10}$, in the other, the patient could read the finest print, and only noticed a large scotoma lying near the axis of vision. There were marked chromopsy and photopsy. The ophthalmoscope revealed a circumscribed cloud or veil in the central portion of the fundus (and

* "Kl. Monatsblät.," 1863, p. 456.

† "A. f. O.," xiv, 1.

corresponding to the scotoma), which was due to a serous effusion into the retina which extended to the disc. The vessels were also hyperæmic in this clouded portion of the retina. These conditions were evidently those of collateral effusion and hyperæmia, and due to embolism of some of the choroidal vessels at this point. These phenomena are easily explained when we remember the anastomosis between the central artery of the retina and those ciliary arteries which perforate the sclerotic in the vicinity of the disc. The patients subsequently quite regained their sight, and the fundus resumed its normal appearance.

5.—COLLOID DISEASE OF THE CHOROID.

This affection was first described by Wedl,* and consists in the formation of peculiar, transparent, bead-like globules on the inner surface of the choroid. Donders† supposed them to be due to senile changes, dependent upon a colloid metamorphosis of the nuclei of the hexagonal pigment cells, whereas H. Müller‡ thought that these little bodies lie horizontally behind the pigment cells, and are due to an adventitious thickening of the elastic lamina. From the researches of Mr. Hulke, the latter view appears to be the true one;§ he moreover found that the capillary vessels of the choroid do not appear to be primarily affected, as the blood corpuscles could be distinctly seen gliding along the capillary vessels in unbroken column *beneath* the globules, *i.e.*, to the outer side of them.

The colloid globules are highly refracting, and are arranged singly, or in little groups or clusters. They assume various shapes, being globular, oval, or club-shaped. They are but slightly, if at all affected by reagents. Their size varies from $\frac{1}{1250}$ to $\frac{1}{430}$ of an inch (Hulke). They are very apt to undergo chalky and fatty degeneration, and then present a finely granular appearance.

On account of the colloid masses pushing aside, or even destroying the hexagonal pigment cells, the latter are crowded together, so as to form a narrow, dark rim or fringe around the single or aggregated globules. Hence, the choroidal epithelium presents here and there a somewhat variegated, patchy appearance. Indeed this is about the only sign by which the presence of colloid disease of the choroid can be recognised with the ophthalmoscope. We notice‖ small, faintly pigmented pale patches, surrounded by a dark fringe of pigment cells, the choroidal vessels being hidden by the chalky deposits. These patches may be strewn about at small intervals over a considerable portion of the choroid, more especially towards the equator of the fundus.

* "Grundzüge der Histologie," 1854.

† "A. f. O.," i, 2, 107.

‡ Ibid., ii, 2, 1.

§ "R. L. O. H. Rep.," i, pp. 70 and 180.

‖ Liebreich, "A. f. O.," iv, 2, 290.

It was supposed that these colloid formations were due to some senile changes, as they are most frequently met with in old persons. But Hulke* has seen them also occur in quite young individuals, and considers that inflammation is the cause of these adventitious thickenings of the elastic lamina, as he has frequently found colloid disease associated with inflammatory changes. He states that it is almost always present in shrunken globes which have been repeatedly inflamed, and he has also seen it several times in acute traumatic inflammation.

On acconnt of the atrophy of the choroidal epithelium, and consequent injury to the rods and bulbs of the retina, the sight is often much impaired at an advanced stage of the disease, and if the latter has invaded the posterior pole of the eye. Fortunately, however, it frequently remains confined to the periphery of the fundus (the vicinity of the ora serrata), and then of course only the outline of the visual field will be affected.

6.—TUBERCLES OF THE CHOROID.

It was formerly supposed by some surgeons that a peculiar form of plastic choroiditis was sometimes met with in the later stages of chronic tuberculosis, and was consequently termed "tubercular choroiditis." The extensive and very carefnl researches of Cohnheim have shown, however, that this is not the case, for he has failed to detect the presence of tubercular deposits in the choroid in any case of localised tuberculosis of the lungs or intestines.† Manz,‡ however, discovered anatomically in three instances, the important and interesting fact of the presence of tubercles in the choroid in acute miliary tuberculosis. Bush§ subsequently narrated another case. On account of the paucity of these instances, it was generally supposed that the co-existence of tubercles in the choroid with acute miliary tuberculosis was very rare and exceptional. The great error of this supposition has, however, been shown by Cohnheim, who found in 18 cases of miliary tuberculosis (which underwent *post mortem* examination in the Berlin Pathological Institution) tubercles in the choroid of one or both eyes *in every instance*. Whilst their presence was thus proved anatomically, it was reserved for Von Graefe‖ to make the first ophthalmoscopic diagnosis of the disease.

With the ophthalmoscope, tubercles in the choroid appear in the form of small circular, circumscribed spots of a pale rose-colour, or

* "R. L. O. H. Rep.," i, 181. † "A. f. O.," xiv, 1, 188, note.
‡ Ib., iv, 2, 120, and ix, 3, 133. § Virchow's "Archiv.," vol. 36, p. 448.
‖ "A. f. O.," xiv, 1, 193.

greyish-white tint, and vary in size from $\frac{1}{3}$ to 2·5 mm. They are chiefly situated in the vicinity of the optic disc, but may extend occasionally to a considerable distance from it. Although the smaller tubercles only produce a stretching or widening-up of the choroidal epithelium, without any loss of the pigment molecules, and hence only give rise to a moderate discoloration of the choroid at this spot (Graefe), yet they should not escape the detection of a careful and dexterous ophthalmoscopist, more especially if they are situated near the centre of the fundus. If they occur near the equator it may be different, more especially as these patients are often difficult to examine on account of their restless or comatose condition. The larger nodules give rise to more marked changes, and are distinctly elevated above the level of the choroid, as is evidenced by the parallax which can be noticed if a retinal vessel is found to pass over one of these nodules. The choroid around the latter is quite normal, and there is, except in very few cases, no collection of pigment around them, although at their margin there is a feint red zone, by which the paler red or greyish central portion gradually passes over into the normally tinted choroid. Together with these changes in the choroid, there may exist more or less marked hyperæmia of the retina, but there is not the least trace of any loss of transparency of the latter, even in the vicinity of the dilated vessels. The number of the tubercles may vary from 1 to 52 (Cohnheim).

Although there is no doubt that the tubercles are formed in the stroma of the choroid, their exact mode of development is yet uncertain. Thus Manz supposed that they originated primarily in the tunica adventitia of the larger choroidal vessels; Bush thought that they were formed from the colourless cells of the stroma of the choroid; whereas, Cohnheim considers that they are developed from peculiar cells (Wanderzellen) resembling lymph corpuscles, which lie strewn about in the choroid.

Soon after the publication of Cohnheim's paper, I was fortunate enough to diagnose, with the ophthalmoscope, the presence of tubercles in the choroid, and submitted the preparation to the Pathological Society at the commencement of this year.

As this is the first case in which tubercles of the choroid have been met with in England, and as it illustrates well their ophthalmoscopic characteristics, I give it *in extenso*.

M. J. P., a little girl æt. 8, was admitted on November 5th, 1867, into King's College Hospital under the care of Dr. Garrod, with symptoms of acute tuberculosis. She had become rapidly emaciated during the last month, and had during that time suffered from dypsnœa and dry cough. On admission there was great febrile disturbance, pulse 132, respirations 66, temperature 101°. Slight dulness of left side of chest, and crepitation about the second intercostal space. November

6th.—Temperature 106°, pulse 148, respiration 96. Urine acid, no albumen. Puerile respiration on right side, slightly tubular on left. I examined the eyes with the ophthalmoscope, and diagnosed the presence of tubercles in the choroid. November 11th.—The patient grew rapidly worse and died on this day.

Post mortem examination by Dr. Kelly.

The brain substance was apparently normal, but on the superior aspect of the left hemisphere were seen two or three small opacities in the pia mater. Both lungs were filled with miliary tubercle. Liver and heart healthy, kidneys contained tubercles in their cortical substance and were throughout congested. Capsule of spleen had some tubercular (?) deposits, the organ itself being healthy. The mesenteric glands were somewhat increased in size and number, and some solitary glands of the small intestines were enlarged. The surface of the peritoneum was healthy.

Examination of the eyes during life.

I found that the eyes appeared externally quite normal. The sight was perfect (No. 1 Jaeger). The field of vision normal. The refracting media perfectly transparent. With the ophthalmoscope, it was found that the optic nerve and retina were healthy, the retinal veins slightly dilated; the outline of the disc perfect. In the choroid—which was otherwise perfectly normal—were noticed numerous small, circular, prominent, greyish-white nodules, which were chiefly situated in the vicinity of the optic disc, more especially in the region of the yellow spot. Towards the periphery of the fundus they were more sparsely scattered. The epithelium of the choroid around the nodules was only very slightly altered in appearance, the cells being evidently opened up or pushed aside by the nodules, and there was no agglomeration of pigment around the latter, but the thinned portion of the epithelium passed insensibly over into the normal condition. At some points, a nodule could be seen lying beneath a retinal vessel which passed distinctly over it. The nodules were prominent, but whether or not the retinal vessel was arched forward by the tubercle could not be accurately determined, as it was quite impossible to distinguish with certainty as to the presence of a parallax, on account of the restless movements of the patient's eye. The condition was very similar in both eyes.

The diagnosis of tubercular deposits in the choroid was verified by a careful dissection made by Mr. Bowater Vernon, the curator of the Moorfields Hospital, an account of which will be found in the "R. L. O. H. Reports," vi, 2, 163.

Other interesting facts in connection with this subject are, that Cohnheim found that the thyroid gland, which was supposed to enjoy a special immunity from tubercular deposits, was in most cases implicated.

He has, moreover, succeeded, in guinea-pigs, in producing tubercles in the choroid by inoculation. The matter was taken from a tuberculous lymphatic gland, and the animal died five weeks after the inoculation, when, besides those in the choroid, miliary tubercles were met with in all the organs, viz., in the lungs, liver, kidneys, spleen, serous membranes, etc.*

7.—TUMOURS OF THE CHOROID.

We meet with two forms of tumour in the choroid—1. sarcoma; 2. carcinoma or cancer; the latter being again subdivided into medullary and melanotic carcinoma. But in many instances the tumour presents a mixed character, being partly sarcomatous and partly carcinomatous. According to Von Graefe,† the great majority of choroidal tumours are of a sarcomatous nature; a much smaller proportion are of a mixed character; and only in exceptional instances are they carcinomatous. These differences in the nature of the tumour are, however, only recognisable with the microscope, as the eye does not present any special symptoms which would enable us to decide, whether or not a given case of intra-ocular tumour is of a sarcomatous or carcinomatous nature.

(1.)—SARCOMA OF THE CHOROID.

The disease presents itself at the outset, as a small nodule in the posterior or lateral portion of the choroid, being developed from the pigmented connective tissue of the latter. During the earliest stage, the choroidal epithelium and the retina may remain unaffected, passing intact over the little nodule. But as the latter increases in size, the retina generally becomes more or less detached by the effusion of a serous or hæmorrhagic reddish-brown fluid, which causes the detached portion of the retina to fluctuate and tremble on every movement of the eye. Subsequently, the retina mostly becomes completely detached (the vitreous humour undergoing a corresponding diminution in volume), giving rise to the well-known funnel-shaped detachment, the apex of which is situated at the optic nerve, the base at the ora serrata; the space external to the detached retina being occupied by the tumour, and more or less fluid. The lens now soon becomes cataractous, if this has not already occurred, more especially at its posterior pole. The vitreous humour may lose its transparency at an earlier stage of the disease, whilst the detachment is still but partial, so that the details of

* "A. f. O.," xiv, 1, 205.

† "A. f. O.," xiv, 2, 115. The reader will find in this article a very interesting and valuable account of the chief differences between the symptoms, development, and course of sarcoma of the choroid and glioma retinæ.

the fundus are perhaps obscured by a diffuse haziness of the vitreous, intermixed with more or less filiform or membranous opacities. If the retina retains its transparency and lies in close contact with the tumour, it may be possible, in some cases, to recognise the latter with the ophthalmoscope, as it presents the appearance of a distinct, smooth, or slightly nodulated swelling, the colour of which may vary from a pale brown to a dark coffee-coloured tint, according to the amount of pigment which it contains. If the detached retina should undergo inflammatory or fatty changes and become thickened, a yellow reflex may take the place of the brown colour of the tumour. But this reflex differs from that met with in glioma, by not being of so brilliantly white or whitish-yellow a tint, or so brightly opalescent (Von Graefe).* As a rule, the early stage of the disease is accompanied by a serous detachment of the retina, which will completely hide the presence of the tumour; and it is only when the latter increases in size and reaches up close to the detached retina, that small, dark, knob-like protuberances may appear beneath the latter, side by side, perhaps, with portions of detached retina, which show a distinct tremulousness when the eye is moved. I have already (p. 358) called special attention to the fact that the degree of the intra-ocular tension is of great diagnostic importance in cases of detachment of the retina; for whilst it is, as a rule, diminished in cases of simple detachment, it either remains normal or is more or less increased when the latter is due to the presence of an intra-ocular tumour. Indeed, in the more advanced stages of sarcoma, the disease often assumes marked glaucomatous symptoms. The tension of the eye is greatly increased, the cornea perhaps steamy, roughened, and anæsthetic, the anterior chamber very shallow, the iris pushed forward and its tissue atrophied, the pupil dilated (often irregularly), the lens perhaps opaque, the sight lost. The patient complains of great ciliary neuralgia, extending, may be, to the corresponding side of the head and face. The sufferings are especially acute and sudden if intra-ocular hæmorrhage has occurred. At a later date staphylomatous bulgings may appear in the ciliary region, and might be mistaken for masses of tumour; their transparency, when a strong light is thrown upon them will, however, guard us against such an error (Graefe). After the increased tension has existed for some length of time, a severe attack of acute glaucomatous inflammation may supervene. Von Graefe calls attention to the fact, that he has several times noticed this occurrence after atropine had been applied for the purpose of facilitating the ophthalmoscoping examination. Now if we do not know the history of the case (the prior detachment of the retina, etc.) and the media are too clouded to permit of an ophthalmoscopic examination, it may be very difficult to recognise the true nature of

* "A. f. O.," xiv, 2, 109.

the disease, and it will be perhaps considered a simple case of glaucoma. An iridectomy is made, and the pain temporarily relieved by the diminution of the tension. But it soon recurs with all its former violence, the eye again becomes hard, our suspicions are aroused as to the presence of an intra-ocular tumour, the eyeball is enucleated, and our conjectures are verified. This fact has led some surgeons to the belief that melanotic sarcoma is very prone to become developed in glaucomatous eyes. But this does not appear to be the case, the glaucomatous condition being simply one phase of the disease. Such cases of supposed glaucoma in which intra-ocular tumours were subsequently found, have been observed by Bowman,* Graefe,† Hutchinson,‡ Dor,§ etc.

Sometimes, however, the presence of the tumour sets up great irritation, and finally gives rise to a plastic form of irido-choroiditis, which leads to a more or less considerable temporary atrophy of the eyeball. The shrunken globe becomes the seat of intense, persistent pain, for the relief of which enucleation is performed, and then the tumour, the real source of the mischief, is discovered. It must be mentioned, however, that whilst temporary atrophy of the globe is not unfrequently observed in the course of glioma retinæ, this is only exceptionally the case in sarcoma of the choroid; as the choroidal inflammation generally assumes a secretory or serous-hæmorrhagic character, indeed the glaucomatous condition may even continue after the extra-ocular development of the disease. The atrophy generally depends upon sloughing of the cornea from paralysis of the corneal nerves, which is followed by more or less severe suppurative panophthalmitis (Von Graefe).‖ Attention has been called by Von Graefe¶ to several points which may enable us to distinguish between simple atrophy of the eyeball, and that which is dependent upon intra-ocular sarcoma. In the latter case, very severe spontaneous paroxysms of pain occur, whilst the ciliary region is hardly, if at all, sensitive to the touch; whereas, in the atrophy ensuing upon irido-cyclitis, the reverse obtains, there being but little, if any, spontaneous pain, but the eye remaining for a long time sensitive to the touch. Moreover, if a sarcoma is present in the atrophied globe, the diminution in size, or flattening of the eyeball, occurs in the antero-posterior axis, the equatorial region not contracting to the same extent. The depressions caused by the four recti muscles are, therefore, unusually apparent upon the anterior surface of the globe. Again, on account of the subsequent contraction of the connective tissue elements, which have been formed within the eye in the course of the panophthalmitis, a barrier is, to a certain extent, placed against the development of the tumour in

* "R. L. O. H. Rep.," iv, 81.
† "A. f. O.," x, 1, 179.
‡ "R. L. O. H. Rep.," v, 88.
§ "A. f. O.," vi, 2.
‖ "A. f. O.," xiv, 2, 120.
¶ Ib.

front. Hence, although the latter increases in size, the collapsed eyeball does not fill out and become plumper, but remains flattened, and a retro-ocular extension of the morbid growth occurs, pushing the eyeball forward, and thus causing a certain degree of exophthalmos. In estimating the degree of the latter, we must not forget that the eyeball is diminished in size, otherwise, we may easily undervalue the extent of the protrusion.

The progress of sarcoma of the choroid is generally slow as long as it is confined by the firm sclerotic within the cavity of the eye, and it may remain stationary for a considerable length of time; but if it has once perforated the coats of the eyeball, its progress is very rapid. Its exposed surface becomes ulcerated, and covered by a dark red crust of blood and ichorous discharge, upon the laceration of which it bleeds freely, often very profusely. Perforation may take place at the cornea (generally at or near the sclero-corneal junction), at the front part of the sclerotic, or at its posterior portion, close to the optic nerve. The disease may also extend into the optic nerve; small, dark, stringy patches being found to pass backwards from the lamina cribrosa between the nerve tubules, and thus causing an extension of the disease into the orbit, or towards the brain. With regard to the implication of the optic nerve, Von Graefe is of opinion that the disease at the outset extends from the lamina cribrosa along the inner surface of the nerve-sheath, or along the septa of the perineurium. Whereas in glioma, the whole thickness of the nerve is simultaneously affected. Or again, small, circumscribed, black patches make their appearance on the sclerotic, being apparently independent of the disease, and their presence is generally prognostic of a rapid extension of the tumour. According to Virchow, the microscope, as a rule, reveals a progressive implication of the sclerotic.

The appearance which the tumour presents on section, varies with the amount of pigment which it contains. It is generally marbled or speckled, some portions being pale, others of a more or less deep brown tint. These melanotic-sarcomatous tumours may, however, be of a uniform, black, inky colour. But according to Virchow* sarcoma of the choroid may, in very exceptional cases, be quite colourless, and this is probably due to some local cause, it being perhaps primarily developed from the less pigmented inner portion of the choroid.

Sarcoma is characterised, microscopically, by the presence of cells of varying size and shape. They may be stellate, spindle-shaped, oval, or round, having, perhaps, well marked prolongations. They contain nuclei and nucleoli. Sometimes the cells are of an extremely large size (giant cells of Virchow), and contain a great number of nuclei.

* "Krankhafte Geschwülste," ii, 284; vide also Hulke, "R. L. O. H. Rep.," iii, 283, and iv, 85.

Between the cells is observed a variable quantity of scanty, fibrillated, intercellular tissue. But there is a complete absence of an areolar mode of arrangement, and in the pure form of sarcoma the cells are not collected into groups or nests within large meshes of connective tissue. Where the latter arrangement prevails in a portion of the tumour, it proves that it is not a simple sarcoma, but of a mixed nature, viz., carcinomatous sarcoma. The cells often contain a considerable amount of pigment, and the disease is then termed melanotic sarcoma. This is very frequently the structure of intra-ocular tumours.

With regard to the prognosis of simple sarcomatous tumours, there is no doubt that they are decidedly malignant, and manifest a great tendency to metastasis. According to Virchow, the degree of malignancy varies with their structure. Thus he states* that those sarcomas which contain small cells (quite irrespective of the shape of the cell) are far more dangerous than those in which the cells are large. On account of the small size and vast quantity of the cells such tumours are generally soft, and should be viewed with great suspicion, whereas, the giant-cell (myaloid) sarcomas afford a relatively favourable prognosis.

There can be no doubt of the fact, that the intra-ocular growth is the primary affection, and that the metastatic tumours are secondary. They occur chiefly in the liver, lungs, brain, and kidney. A peculiarity of the sarcomatous tumours, which distinguishes them from the carcinomatous, is, that they show little or no tendency to affect the lymphatic glands, and hence it is more than probable that the infection of distant organs is caused through the blood, and not through the lymphatic system.

The causes of intra-ocular sarcoma are yet uncertain, but there is no doubt that it not unfrequently becomes developed after injuries of the eye. It may also be formed in eyes which have undergone atrophy after irido-choroiditis, etc. Here, however, we must be upon our guard not to mistake cause and effect. But if the eye has been for many years lost from irido-choroiditis, before symptoms of an intra-ocular growth reveal themselves, it may, I think, be fairly assumed that the latter is a secondary affection. Thus, Mr. Bowman removed an eye affected with melanotic sarcoma, which had been lost from acute inflammation twenty years previously.†

Sarcoma of the choroid occurs most frequently after the age of 30, being but very rarely seen under the age of 15.‡ Von Graefe has never observed a single instance in which choroidal sarcoma affected both eyes, although he has met with cases in which the second eye became amaurotic; the ophthalmoscopic examination yielding at first a perfectly negative result, but at a later period, atrophy of the

* "Krankhafte Geschwülste," ii, 269.

† "R. L. O. H. Rep.," iii, 279. ‡ "A. f. O.," xiv, 2, 106.

optic nerve set in. In two of these cases, melanotic nodules were found at the base of the brain, reacting on the chiasma and the optic nerve of the other side.

*Sarcoma of the ciliary body** is also sometimes met with, and when it has acquired some size, it can be distinctly observed protruding into the anterior chamber. The iris is, at this point, pushed aside from its ciliary insertion by a dark brown tumour, which more or less fills up the anterior chamber, its apex perhaps lying in contact with the cornea; the pupil is at the same time irregularly distorted. On examining the position of the morbid growth behind the iris, with the oblique illumination, we may perhaps observe it encroaching upon the area of the pupil and extending backwards into the vitreous humour, the lens being generally displaced to a corresponding degree backwards or upwards. The surface presents a dark brown appearance, being either quite smooth or somewhat lobulated.

(2.)—CARCINOMA OF THE CHOROID.

We may distinguish two forms of cancer of the choroid, viz., the medullary and the melanotic. I have, however, already stated that we cannot with any degree of certainty diagnose the true nature of these tumours, except by an examination of their minute structure. We may, however, find some assistance in framing our diagnosis, by remembering that cancerous tumours show a more rapid progress than simple sarcoma, leading at an earlier period to metastatic affections, and manifesting a great tendency to implicate the lymphatic glands.

On a microscopic examination of *medullary carcinoma*, we notice large areolar spaces, formed by fibrillæ of connective tissue; and within these spaces are contained nests of variously shaped cancer cells. The latter may be stellate, fusiform, ovoid, or round, and closely resemble epithelial and ganglion-cells. They contain a large nucleus, and within this there are numerous nucleoli.

The *melanotic carcinoma* is only distinguished from the medullary, by the more or less considerable amount of pigment contained in the cells and the trabeculæ forming the areolæ. It may be so great as to give a dark inky colour to the tumour. In the melanotic cancer there are also large areolæ enclosing nests of pigmented cancer cells.

The melanotic cancer is extremely dangerous, and is very prone to recur at an early date. Von Graefe states that he does not remember any case in which the apparent cure exceeded four years. In the

* Vide V. Graefe's cases, "A. f. O.," xii, 2, 233.

majority of cases the disease recurred locally or in other organs within three, six, or twelve months.

Sometimes the tumour presents a mixed character, being in part sarcomatous, in part carcinomatous, and the relative predominance of the one over the other may influence the rapidity of the progress and of the recurrence. More probably, however, the sarcoma may have existed for some time, when the cancer elements become developed and greatly hasten the growth. Virchow does not believe that the sarcomatous elements pass over into those of cancer, so that the latter is developed from the sarcoma, but that the two conditions exist side by side, arising out of the same primary structure, and growing together like two branches from one stem.*

The treatment to be adopted for these tumours (both the sarcomatous and carcinomatous) is the same, viz., the extirpation of the eye as soon as the diagnosis can be established with anything like certainty. The early removal of the eye is indicated, not only because we may thus perhaps be in time to prevent the infection of other organs, but also to prevent the extension of the disease to the optic nerve. In removing the eyeball, the optic nerve should be cut very far back, so that we may, if possible, get beyond the seat of the disease.

If on removal of the eye, the cut end of the optic nerve looks swollen and dark, it should be pulled out as far as possible with a pair of forceps, and divided quite close to the orbit. This is often very difficult if we endeavour to look for the nerve, and hence it is best, as Mr. Hutchinson† suggests, to feel for its trunk with our forefinger, and when it is thus found to seize its extremity with a pair of strongly toothed forceps, and draw it forth and divide it.

Where the optic nerve is found to be diseased, or the tumour has extended into the orbit, the chloride of zinc paste should always be employed (*vide* Tumours of Orbit).

Wecker‡ describes a unique case of *myoma* of the choroid which occurred in his practice. The patient's left eye was hard, the anterior ciliary vessels dilated and tortuous, and he suffered from severe paroxysms of pain. Nearly the whole of the internal half of the iris was pressed forward towards the cornea by a reddish brown tumour, which also occupied the greater portion of the pupil. The vitreous humour was clear, the optic disc somewhat hyperæmic. The eye was enucleated, and the microscopic examination of the tumour was made by Iwanoff, who found that it was a myo-sarcoma, there being in it distinct unstriped muscular fibres.

* "Krankhafte Geschwülste," ii, 182. † "R. L. O. H. Rep.," v, 1, 92.
‡ "Maladies des Yeux" (2nd edition), 1, 545.

Leber* again, describes a very interesting and peculiar case in which the sarcoma of the choroid assumed a distinctly cavernous character.

8.—FORMATION OF BONE IN THE CHOROID.

A formation of true bone is not unfrequently met with† on the inner surface of the choroid, in eyes which have undergone atrophy and become shrunken. These osseous deposits may appear in the form of small circumscribed spots or plates, or they may be so extensive as to form a complete hollow cup, reaching from the ciliary processes to the optic nerve, and being perforated by the latter. In close apposition to this formation of bone may often be noticed cartilaginous tissue.

The shrunken eyeball in which a deposit of bone has taken place, is not unfrequently very painful, both to the touch and spontaneously, and may give rise to sympathetic inflammation.

9.—COLOBOMA OF THE CHOROID.

The ophthalmoscopic symptoms presented by this condition are very striking and characteristic, and show a remarkable similarity in all cases, although, of course, the extent of the coloboma and of the bulging backwards of the sclerotic greatly influence these appearances. Liebreich gives an admirable illustration of this condition in his Atlas.‡

With the ophthalmoscope, there is observed a most peculiar, large, white figure at the lower part of the fundus, extending perhaps nearly up to the disc, or even embracing this in its expanse. Anteriorly it may reach more or less closely up to the ciliary processes, or even quite up to the corresponding coloboma of the iris. Together with this coloboma of the choroid, there always exists a staphylomatous bulging backwards of the sclerotic. This may be nearly of the same depth throughout, or suddenly and abruptly increase in depth, which can be distinctly observed with the ophthalmoscope, as it produces a peculiar appearance in the course of the retinal vessels, which will be seen suddenly to dip round this edge and be slightly interrupted in their course, thus giving rise to a marked parallax. These appearances can be well studied in Liebreich's illustration.

On the white expanse are noticed the retinal vessels, which do not, however, pursue their regular course, but undergo peculiar windings, some twisting and curling round over the edge of the coloboma. The

* "A. f. O.," xiv, 2, 221.

† Vide Wedl's Atlas der Pathologischen Histologie des Auges.

‡ Plate XII, fig. 5.

presence of the retina, or at least of some attenuated, vicarious membrane, is proved by the appearance of the retinal vessels on the surface of the coloboma. The retina may either lie in apposition with the sclerotic, or be stretched across the bulge in the latter, and in this case it is often slightly folded, so that branches of its vessels may appear to spring directly from the sclerotic, on account of their continuity with the other retinal vessels being hidden by the folds. Traces of choroidal vessels may also be noticed upon the white figure. The margin of the latter is very sharply defined, of a dark reddish-brown or coffee-coloured tint, and strongly pigmented. If the cleft stops short of the disc, it will be divided from the latter by a sharp line of demarcation, and a more or less normal portion of fundus; whereas if the disc is included in the coloboma, its appearance is remarkably changed, for it can hardly be distinguished from the rest of the white figure except by a more rosy-grey tint; its form being elliptic, with its long diameter placed horizontally.

If the anterior extremity of the coloboma does not reach up to the cleft in the iris, there are noticed small rudimentary ciliary processes, and it is divided from the coloboma of the iris by a more or less extensive portion of perhaps darkly pigmented fundus, traversed by a kind of raphé, or white stripe* (sometimes there are two or three). Where the coloboma of the choroid touches that of the iris, the ciliary processes may be completely wanting. Sämisch† narrates a very interesting case of coloboma of the iris and choroid, in which the former was divided from the pupil by a narrow band, which was probably a remnant of the pupillary membrane. Bäumler‡ has also noticed such little bands traversing the area of the pupil in cases of coloboma.

If the region of the yellow spot is not involved, the sight may be tolerably good, but there is always an interruption in the field of vision (scotoma), corresponding in size and situation to the coloboma of the choroid.

Liebreich has also observed and figured (Atlas, Pl. xii, fig. 4) the very rare and curious condition of a coloboma of the sheath of the optic nerve.

10.—RUPTURE OF THE CHOROID.

Severe blows upon, or contusions of the eye by the fist or some blunt body, as, for instance, a piece of wood, may produce rupture of the choroid by simple concussion of the eye, without any injury or rupture

* Vide Arlt, "Krankheiten des Auges," ii, 128; also Sämisch, "Kl. Monatsbl.," 1867, p. 87.

† L. c., p. 87.

‡ "Würzburger Med. Zeitschrift," iii, 84.

of the sclerotic or retina. The accident is generally followed by extensive hæmorrhage from the choroid, and more or less severe inflammatory symptoms. The vitreous humour often becomes diffusely clouded and traversed by membranous opacities, which may be due to inflammatory exudations or hæmorrhagic effusions. If the vitreous humour is sufficiently clear to permit of an examination of the fundus, we notice the presence of one or more pale linear stripes in the region of the yellow spot. This appearance is produced by the rupture of the choroid, which is generally somewhat irregular in outline, and divided, perhaps, into one or more offshoots. Its edges are smooth, or slightly notched and irregular, and fringed or studded with deposits of pigment, or little hæmorrhagic effusions. As the blood becomes absorbed, the effusions may either entirely disappear or leave behind small pale patches in the choroid, and the linear rupture assumes a bright, glistening, tendinous appearance, which is due to the sclerotic being quite exposed on account of the absorption of the blood. Within the expanse of the white figure a choroidal vessel may, perhaps, be observed. The fundus around the rupture (except perhaps in its immediate vicinity) is generally quite normal. The retina is also frequently uninjured and free from any rupture, for its vessels either pass quite unaltered over the scar in the choroid, or present only a very faint interruption. Ruptures in the choroid generally occur in the region of the yellow spot, and run in a vertical direction; they are sometimes straight, in other cases arched or crescentic, the concavity of the arch being turned towards the disc. In some cases there is only one rupture, in others two or three, of nearly equal or varying size, and the one end of the rent may split up and be divided into two or three little branchlets.*

The sight is at first often greatly impaired, on account of the hæmorrhagic effusions into the choroid and vitreous humour, or the inflammatory complications. As the former become absorbed and the vitreous humour regains its transparency, the sight may become greatly improved, and even quite restored; but this is exceptional, for mostly it remains more or less considerably impaired. The field of vision is sometimes contracted at the periphery, and there may also be interruptions (*scotomata*) in it, corresponding in situation to the rupture in the choroid.

Although in favourable cases, the cicatrization of the rupture in the choroid is not followed by any subsequent affection of the retina or optic nerve, yet the former may afterwards become detached.†

* Amongst other interesting cases of rupture of the choroid, I would especially call the reader's attention to the following, described by Von Graefe, "A. f. O.," i, 1, 402; Von Ammon, ibid., i, 2, 124; Frank, "R. L. O. H. Rep.," iii, 84; Sämisch, "Kl. Monatsbl.," 1866, 111 and 1867, 32; Haase, "Kl. Monatsbl.," 1866, 257.

† "Kl. Monatsbl.," 1866, p. 111.

Dr. Frank* also narrates a case in which rupture of the choroid was followed by atrophy of the optic nerve.

The treatment must principally consist in hastening the absorption of the hæmorrhagic effusions into the choroid and vitreous humour, and for this purpose the compress bandage and the repeated application of the artificial leech will be found most serviceable.

Incised wounds of the sclerotic and choroid are not generally accompanied by a protrusion (hernia) of the choroid but the edge of the wounded choroid may be forced out between the lips of the sclerotic incision by the exuding vitreous humour. In wounds of the choroid, there is often a considerable effusion of blood into the choroid and vitreous humour.

11.—HÆMORRHAGE FROM THE CHOROID.

Extravasations of blood from the choroid may be produced by an accident, such as a blow upon the eye, or a wound implicating the sclerotic and choroid. But it also occurs in diseases of the eye which influence the intra-ocular circulation—as for instance glaucoma, sclerotico-choroiditis posterior, etc., and produce a congestion of the choroidal vessels, more especially if the latter should be diseased. In such cases, any sudden strain, such as violent vomiting or retching, or the sudden relief of the intra-ocular tension by paracentesis or iridectomy, may cause a rupture of some of the smaller choroidal vessels, and perhaps considerable hæmorrhage. It may also occur spontaneously, or after severe and protracted exertion of the eye, as in engraving, sewing, microscopizing, etc.

The blood may be effused between the choroid and sclerotic, into the tissue of the choroid, or between the latter and the retina. If the hæmorrhage is but slight, it will simply produce small circumscribed ecchymoses in the choroid, but if it is considerable in quantity, it may cause detachment of the retina, or perforate the latter, and escape into the vitreous humour. This, as has been already stated in the article upon hæmorrhage into the vitreous humour, p. 316, will chiefly depend upon the situation of the hæmorrhage, for if the latter takes place near the *ora serrata*, it is more likely to perforate the retina (on account of the thinness of the latter at this point), and to escape into the vitreous humour. Whereas, if the extravasation occurs near the posterior pole of the eye, it is more apt to produce detachment of the retina. Esmarch† has narrated a very interesting case of extravasation of blood from the choroid, with perforation of the retina in the region of the yellow spot and escape of the blood into the vitreous humour, where it gradually underwent absorption, until nothing remained but a small dark speck about the

* "R. L. O. H. Reports," iii, 84. † "A. f. O.," iv, 1, 350.

size of a pin's head, the perforation in the retina having healed without leaving any trace behind it. Sometimes, however, the position of the little cicatrix may remain recognisable as a small black pigment spot. Effusion of blood between the sclerotic and choroid may produce detachment of the latter.

With the ophthalmoscope, effusions of blood into the choroid may be recognised by their presenting the appearance of uniform, dark, cherry-coloured patches, of varying size and shape, being irregular, circular, ovoid, etc. Their edges may be sharply defined, or somewhat indistinct and irregular. The colour of the apoplexy is uniformly red, and not striated, nor are its edges serrated or "feathery," as is the case when blood is effused into the inner layers of the retina, and follows the course of the optic nerve fibres. Again, the retinal vessels can be distinctly seen to pass straight over the effusion, without being interrupted or hidden by it. If no retinal vessel should be situated over, or in very close proximity to, the hæmorrhage, the situation of the latter, upon a plane deeper than that of the retina, is best recognised by the aid of the binocular ophthalmoscope. If the disease has lasted some little time, some of the neighbouring extravasations have probably undergone partial absorption, and given rise to peculiar appearances in the choroid, which will aid us in our diagnosis of the exact situation of any special ecchymoses. During the process of absorption, the effusion gradually assumes a paler and more yellowish white tint, and becomes fringed by a circlet of pigment. The smaller ecchymoses may leave no trace behind them, or only a small pigment spot.

If the hæmorrhage is but slight, and is situated at the periphery of the fundus, it may produce no impairment of vision, or only a small scotoma; but it is very different when it is situated at or near the yellow spot, for then it may very greatly affect the sight, and render the patient unable to read even large type; a more or less dense cloud or spot covering the letters and rendering them indistinct.

The treatment must be the same as that which is adopted for hyperæmia of the choroid and retina, and hæmorrhagic effusions into the latter.

12.—DETACHMENT OF THE CHOROID FROM THE SCLEROTIC.

A few cases of this very rare affection have been described, more especially by Von Graefe and Liebreich,* and a very beautiful illustration of this condition will be found in the latter's Atlas.† Iwanoff‡

* "A. f. O.," iv, 2, 226; Liebreich, ibid., v, 2, 259.
† Pl. vii, fig. 4. ‡ "A. f. O.," xi, 1, 191.

has also given a very careful description of the dissection of an eye affected with detachment of the choroid.

The ophthalmoscopic symptoms of this disease are very marked and characteristic. A more or less considerable, globular protrusion is observed in the vitreous humour. Its outline is sharply defined, its surface tense and smooth and devoid of all wrinkles or foldings, and upon it, the retinal vessels can be distinctly traced as they pass over it from the normal fundus. But the most characteristic symptom of all, is the appearance of the choroidal vessels and intravascular spaces lying close beneath the retina. At the angle where the protrusion springs from the normal fundus, the retina is not unfrequently somewhat detached, becoming still more so at a later date. The colour of the protrusion varies from a pale yellowish-grey tint to a darker red, according as the fluid causing the detachment is of a serous or hæmorrhagic nature. Its surface is not unfrequently studded with small ecchymoses. On account of the protrusion being situated so far in front of the focal length of the eye, it can be distinctly seen in the erect image at some distance from the eye, affording a faint yellow reflex in place of the bright red glow of the normal fundus. The retinal vessels can also be distinctly seen to traverse its surface. It may be especially distinguished from simple detachment of the retina, by the fact that it does not oscillate, tremble, or fall into small wavy folds when the eye is moved in different directions, but retains its tense, smooth, bladder-like appearance.

It may be very difficult, or indeed quite impossible, to determine whether the detachment of the choroid is due to a serous or hæmorrhagic effusion, or to some morbid growth pressing it forward. And only as the disease progresses shall we able to decide this question with certainty, for simple detachment of the choroid by fluid always ends in irido-choroiditis, and softening and atrophy of the eyeball. Whereas, in intra-ocular tumours, symptoms of increased tension and glaucomatous inflammation generally supervene as the disease progresses.

Chapter XII.

GLAUCOMA.

We have now to turn our attention to one of the most important and dangerous diseases of the eye, viz., glaucoma; a disease whose timely treatment by iridectomy will yield the most favourable results, but which, if allowed to run its course unchecked, except perhaps by inefficient remedies, sooner or later dooms the eye to irremediable blindness. It is, therefore, of the utmost consequence that all surgeons should be thoroughly conversant with the different symptoms which it may present in its various forms, so that they may be able at once to recognise this dangerous and insidious affection, and to combat and subdue it before it is too late.

The term glaucoma was applied by Hippocrates to all opacities situated behind the pupil. After a time, it was confined to those which presented a green appearance, the nature of which was not, however, understood, although the fact was recognised that such green opacities were not curable by operation.* By some, the seat of the affection was supposed to be in the vitreous humour, by others, in the retina and optic nerve. At a later period, it was thought that glaucoma was due to a peculiar inflammation of the choroid, which occurred most frequently in gouty persons, hence it was termed arthritic ophthalmia, a name still retained by some writers. Lawrence considered that the symptoms of glaucoma were caused by an affection of the retina and choroid. Weller gave a most excellent and graphic description of the symptoms of glaucoma, including in it many of the principal and most important points, *e.g.*, the intermitting course of the disease, the sluggishness and dilatation of the pupil, the circumorbital pain, the rainbows round a candle, &c. He also made mention of the tenseness of the eyeball, but Mackenzie first pointed out (in 1830) the importance of the latter symptom.

In 1851, Helmholtz discovered the ophthalmoscope, which has

* For an interesting historical *resumé* of glaucoma, I would refer the reader to Dr. Hoffmann's excellent paper on Glaucoma, "A. f. O.," viii, 2. With regard to the literature of this subject, I would direct his attention especially to Von Graefe's Papers, "A. f. O.," iii, 2; iv, 2; viii, 2.

proved of such incalculable value in diseases of the eye, and has so completely revolutionized ophthalmic surgery. The first results of the ophthalmoscopic examination of cases of glaucoma were negative; soon, however, it was ascertained that there always existed a peculiar alteration in the optic disc in all cases of well-marked glaucoma. In 1854, Edward Jäger gave an excellent illustration of the ophthalmoscopic appearances of the optic nerve entrance in a case of glaucoma, showing the peculiar displacement of the vessels at the edge of the disc, the slight rim surrounding the latter, &c. It was, however, reserved for the great genius of von Graefe to unite these various and disjointed links of the chain of symptoms presented by glaucoma, and, welding them into one connected whole, not only to found the modern doctrine of glaucoma, but, at the same time, to bless humanity with a cure for this hitherto irremediable disease. Soon after Jäger's delineation of the ophthalmoscopic appearances of the optic disc, von Graefe described these peculiar appearances still more accurately, and at the same time pointed out a most important fact, viz., that an arterial pulsation exists in the optic nerve in glaucoma, being either spontaneous, or producible by a very slight pressure upon the eyeball, a pressure far less than is necessary for its production in the normal eye. Within a short time afterwards, he also discovered that the peculiar appearance of the optic disc, which had been supposed by him and other observers to be caused by an arching forward of the optic nerve entrance, was in reality due to its being excavated or cupped. He at once recognised the connection of these two symptoms (the excavation and the spontaneous, or easily producible arterial pulsation) with the increased hardness of the globe, and his clinical observations soon showed him that all the other symptoms were also closely connected with this augmented tension. The next problem was, to solve how this tension might be permanently diminished. All the usual remedies, such as mercurials, antiphlogistics, diuretics, diaphoretics, had proved as insufficient in his hands, as in those of other practitioners. Mydriatics, which had been found to diminish intra-ocular pressure, were next had recourse to, but they also proved of no avail. He then tried tapping the anterior chamber, but this was only followed by a temporary benefit, which soon passed away again. The disease gradually progressed, nor could the relapses be stayed by a methodical repetition of the paracentesis, for he found that its therapeutical effect became each time less, and finally null, as far as the sight was concerned. In only two cases, out of a great number thus treated, did it prove of lasting benefit.

Paracentesis having been of no avail in permanently reducing the intra-ocular tension, he next had recourse to iridectomy, having found that it proved of great benefit in ulcerations and infiltrations of the cornea, by diminishing the tension; and that in cases of partial staphy-

loma of the cornea, and in staphyloma of the sclerotic, the protruding part often receded completely after this operation.

He first tried iridectomy in glaucoma in 1856, and soon found that it not only permanently diminished the intra-ocular tension, but that it might indeed be regarded as a true curative treatment of the glaucomatous process, having, however, like every other therapeutic agent, its natural limits. Since that time, iridectomy has been recognised by most of the eminent oculists in Europe as the only cure known, at present, for glaucoma; but although it has achieved most brilliant results in the hands of many of our most distinguished English ophthalmic surgeons—amongst whom I would more particularly instance, Messrs. Bowman and Critchett, who have from the commencement been its stanch and warm supporters—there are yet some English oculists of repute who either condemn the operation completely, or uphold it in so luke-warm a manner as in reality to "damn it with faint praise."

My own wide experience of the beneficial effects of iridectomy in glaucoma enables me, not only to recommend the operation most strongly, but even to urge upon the profession to trust to no other remedies, as they have all proved insufficient, and as we should thus permit the most valuable time, when an iridectomy might still save the eye, to pass irrevocably away. We shall see, hereafter, that an accurate prognosis of the benefits to be expected from iridectomy may be made in the majority of cases, and it will be shown why the operation may have proved unsuccessful in the hands of some practitioners. But too frequently impossibilities were expected of it; it was tried, for the first and only time perhaps, in chronic cases of glaucoma, which were beyond all help; it proved, as might have been foretold, unsuccessful, and was then at once discarded as useless.

The commencement of the disease, the development of the different symptoms, and the course which glaucoma may run, present numerous variations, and for this reason a precise classification is somewhat difficult. But on closer observation, it will be found that the several varieties also show a great tendency to pass over into each other. The family resemblance of these different forms is very marked, for they are distinguished from the commencement by certain characteristic symptoms, and although they will vary somewhat in their course, they all, but too surely, lead, sooner or later, to that last hopeless condition in which the eyeball is stony hard, the pupil widely dilated and fixed, the refractive media clouded, the optic disc cupped, and the sight either entirely or nearly entirely, lost; that condition, in short, to which our forefathers confined the term glaucoma. The modern school of ophthalmology, however, no longer limits the name glaucoma to this last hopeless condition, but embraces in it all the varieties of the disease from their commencement, which lead to this

last stage. In regarding the different varieties of glaucoma from a clinical point of view, we are particularly struck by the fact, that one class of cases is distinguished from the commencement by more or less marked inflammatory symptoms; whilst another appears to be free from inflammation, although in its course inflammatory symptoms, even of an acute kind, often make their appearance. We may, therefore, divide cases of glaucoma into two principal classes:—

I. Cases attended with inflammatory symptoms.

II. Cases in which there are *apparently* no inflammatory symptoms present.

Glaucoma may exist as a primary disease, or may complicate a previously existing affection.

We find that the different varieties of glaucoma show certain common characteristics, and we may generally recognise the four following stages:—

1. A premonitory stage (glaucoma imminens, incipiens, of Von Graefe).

2. A stage in which the glaucoma is fully developed (glaucoma evolutum, confirmatum, Von Graefe).

3. A stage in which quantitative perception of light has been completely lost for some time (glaucoma absolutum, consummatum, Von Graefe).

4. A stage in which the eye undergoes glaucomatous degeneration (Von Graefe).

We distinguish two principal forms of inflammatory glaucoma, the acute and the chronic.

1.—ACUTE INFLAMMATORY GLAUCOMA (SYNOM. ARTHRITIC OPHTHALMIA).

Premonitory Stage.—In the great majority of cases (75 p. c.) there is a premonitory stage, which is characterised by the presence of several or all the following symptoms, which are, however, of *periodic* occurrence, there being in the interval a *perfect intermission.* When this ceases to be the case, when there are no longer perfect intermissions, but only remissions of the symptoms, we can no longer designate it the premonitory stage, but must regard it as confirmed glaucoma.

1. *Increased Tension of the Eyeball.**—This is generally not very

* The method of ascertaining and noting the degree of intra-ocular tension is fully explained in the Introduction, p. 2.

considerable, and never reaches the highest degree. In families in which glaucoma is hereditary, a marked increase of tension is often met with, even in early life, although the disease may not break out till a much later period, or even not at all. In such cases there can be no objection to look upon this abnormal tension as a predisposing element of glaucoma, more particularly if it be accompanied by hypermetropia, and a disproportional diminution of the range of accommodation. It has been supposed by some, that the increased degree of tension always precedes, for a longer or shorter period, the other symptoms of glaucoma; von Graefe has, however, met with several marked exceptions to this rule. In some cases in which he operated for glaucoma in the one eye, the other was found to be of a perfectly normal tension at the time of operation, but was soon after attacked by glaucoma, in one case even by glaucoma fulminans. But an increase in the tension of the eyeball should always excite our suspicion, and should at once lead us to examine as to the presence of other symptoms of glaucoma; if we find none, we should still watch the eye with care, and warn the patient carefully to observe whether any other symptoms begin to show themselves, *e.g.*, rainbows round a candle, rapidly increasing presbyopia, periodic dimness of vision, &c. We must be upon our guard against the but too frequent error, that a sense of fulness or tension within the eye experienced by the patient, is any proof of the increased hardness of the eyeball. For this feeling of fulness may exist without the slightest increase of tension. Another frequent error is, to suppose that all acute inflammations of the eye are accompanied by an increase in the intra-ocular pressure. A careful examination of ordinary cases of acute inflammation of the conjunctiva, cornea, iris, &c., will at once prove the fallacy of this opinion, for the tension will be found normal. If the degree of tension is increased, we must regard it as a dangerous complication, which is to be carefully watched, lest it be the precursor of other glaucomatous symptoms.

2. *Rapid Increase of any pre-existing Presbyopia.*—As the persons attacked by glaucoma are mostly beyond 45 or 50 years of age, some degree of presbyopia is generally already present, but it is found that this often increases in a very rapid and marked manner during the premonitory stage of glaucoma; so that the patient may be obliged, in the course of a few months, frequently to change his reading-glasses for stronger and stronger ones. This rapid increase in the presbyopia appears to be not so much due to a flattening of the cornea through an increase in the intra-ocular pressure, as to the action of this pressure upon the nerves supplying the ciliary muscle, thus causing paralysis of the latter. Haffmann has called particular attention to the fact that hypermetropia very frequently occurs together with glaucoma. It appears probable that hypermetropic eyes are more prone to glaucoma

than others ; but hypermetropia may also be developed in the course of the disease. The cause of this is, however, still quite uncertain, it is probably to be sought for in some changes in the crystalline lens (rapidly progressive senile involution), by which the refractive power of the latter is considerably diminished.

3. *Venous Hyperæmia.*—The congestion of the ciliary veins is generally slight during the premonitory stage, and they never present that peculiar tortuous, dilated appearance, so characteristic of chronic glaucoma. Generally, only a few scattered, dilated veins are seen running over the sclerotic. On examination with the ophthalmoscope, the retinal veins are also found to be dilated and tortuous, there may be likewise spontaneous venous pulsation, or this may be produced by slight pressure upon the eyeball.

4. *Cloudiness of the Aqueous and Vitreous Humours.*—The aqueous humour is often found slightly but uniformly hazy, rendering the structure of the iris somewhat indistinct, and causing a slight change in its colour. The vitreous humour also becomes a little clouded, but uniformly so, for on ophthalmoscopic examination, we do not find dark masses floating about in the vitreous humour, but only a diffused cloudiness, which renders the details of the fundus more or less indistinct. This haziness of the humours is very variable in its degree and duration, sometimes, it is so slight as to be hardly perceptible, at others, it is so considerable as to prevent any ophthalmoscopic examination. In the majority of cases, however, it is but moderate in the premonitory stage. It may come on several times a day, lasting but for a few minutes at a time, or it may be less frequent, or of longer duration.

5. *Dilatation and Sluggishness of the Pupil.*—On comparing the pupil of the eye affected with premonitory symptoms of glaucoma, with that of the other (supposing this to be healthy), the former will be found somewhat dilated and sluggish, reacting but slightly on the stimulus of light. The dilatation is never so considerable as in the advanced stages of glaucoma, when we often find the pupil widely dilated and quite immovable; its sluggishness is, however, generally well marked.

6. *Periodic Dimness of Sight.*—The patient is troubled by occasional intermittent dimness of sight. At such times, surrounding objects appear veiled and indistinct, as if they were shrouded in a grey fog or smoke. The degree of dimness varies considerably, as does also the duration of these attacks; sometimes, they may last for several hours, at others, only for a few minutes. At such a time, there may also exist a slight contraction of the field of vision; generally, however, there is only indistinctness of eccentric impressions in certain directions. Although these obscurations may be due to transitory cloudiness of the aqueous and vitreous humours, they are generally caused

by disturbances in the circulation of the eye. The character of these obscurations may be imitated by pressure upon the healthy eye, and Donders has found that the dimness of vision shows itself as soon as retinal arterial pulsation is produced by this pressure upon the eyeball. I have experimented a good deal upon this point, and have arrived at the same results. I have also found, by experiments upon myself, that by regulating the amount of pressure, I have been able to produce any kind of obscuration, from the slightest, in which only the objects lying quite at the periphery of the field of vision appeared somewhat clouded, to that excessive dimness in which the light of a bright lamp was rendered quite unapparent. The increased intra-ocular pressure, acting directly upon the retina, does not, therefore, appear to be so much the cause of these obscurations; but we must seek for it rather in the impairment of the circulation, the stagnation and fulness of the veins, and perhaps, the emptying of the arteries. The increased pressure produces the changes in the circulation, and the latter cause the obscurations. The truth of this assertion is also proved by the fact that these attacks of dimness are generally brought on by anything that causes congestion of the blood-vessels of the eye—for instance, a full meal, great excitement, long-continued stooping, violent exercise, etc.

7. *The appearance of a Halo or Rainbow round a Candle.*—This is also a very constant symptom of the premonitory stage. On looking at a candle, the patient sees a coloured halo, or rainbow, round the light. The outer side of the ring is red, the inner bluish-green. This has been supposed by some to be a mere physical phenomenon, due to a diffraction (interference) of the rays of light, owing to some change in the refractive media, especially the peripheral portion of the lens.

It is seen when the pupil is dilated, but disappears when the patient is directed to look through a small opening. It may, however, be also due to congestion of the vessels, for I have seen it sometimes brought on by stooping.

8. *Ciliary Neuralgia*, *i.e.*, pains, more or less acute, in the forehead and temples and passing down the side of the nose, occur occasionally at an early period, but sometimes only at a later part of the premonitory stage, at the same time with the intermittent obscurations. In some instances they are, however, quite absent.

9. *The field of vision* is occasionally somewhat contracted; generally, however, there is only some indistinctness of eccentric impressions in certain directions, more particularly if the illumination is but moderate.

The intensity of these symptoms varies with the severity of the attack. They may be so slight as to escape all observation, or they may be very marked if the attack is severe, and then there are often added to the symptoms above enumerated, diminution in the size of the

anterior chamber, arterial pulsation, and indistinctness of eccentric vision. The latter symptom may be absent if the illumination is very bright, but becomes evident if it be moderated.

At the commencement, these premonitory symptoms only show themselves at long intervals, of perhaps several months, but gradually they become more frequent. At first, months may elapse between each attack, then weeks, then days, and when they occur at intervals of a few days, the second stage, the glaucoma evolutum, may be expected, although this may even occur when a long interval exists. This stage may also be suspected as close at hand, if the premonitory symptoms do not disappear after sleep, even of short duration (Graefe). If the periodic attacks no longer leave behind them a normal pupil, and a normal acuteness of vision, still more, if the optic nerve is already cupped, we must no longer designate it as the premonitory stage, but as a case of glaucoma evolutum, with periodic increase of the symptoms.

The premonitory stage may last for an indefinite period; years may even elapse before it leads to confirmed glaucoma; but in the majority of cases it does not extend beyond a few months, or it may pass over into glaucoma even after the second or third attack, there being only remissions, and not clear and well defined intervals between the attacks. Sometimes, as has been mentioned above, the premonitory symptoms are so slight as quite to escape the notice of the patient, particularly if the other eye is still perfectly healthy. It is different, however, where one eye has already been lost by glaucoma, for then the patient's attention and anxiety are at once aroused by any of the premonitory symptoms, and he early consults his medical attendant, fearful lest he should also lose the sight of the second eye.

In the great majority (about 75 per cent.) of cases, acute inflammatory glaucoma is preceded by a more or less marked premonitory stage of varying duration. The intervals between the premonitory attacks become less and less frequent, until the latter recur perhaps every two or three days, or even every day. The patient is then suddenly seized, frequently at night time and after having passed perhaps several sleepless nights, by a severe, often excruciating pain in and around the eye, which extends to the forehead, temple, and down the corresponding side of the nose, as far as the extremity of the bone. Sometimes this pain extends also to the corresponding half of the head, and even to the occiput, which causes it often to be mistaken for an attack of rheumatism. At the same time there may be considerable constitutional disturbance, febrile excitement, and severe nausea and vomiting, and these symptoms may be of such prominence that the

patient is supposed to be suffering from a severe bilious attack, and the affection of the eye is either overlooked, or is thought to be dependent upon this. But the eye shows marked symptoms of acute internal inflammation. The eyelids may be much swollen, red and puffy. The conjunctival and sub-conjunctival vessels are injected, the veins in particular being dilated and gorged. There may also be very considerable serous chemosis, which completely hides the deeper sub-conjunctival vascularity and the rosy zone round the cornea. There is also much photophobia and lachrymation, but they are accompanied by very little mucous discharge, and this chiefly of a thin, frothy character. The cornea is clouded on its posterior surface, being perhaps studded with minute opacities, deposited from the aqueous humour. The sensibility of the cornea may be also somewhat diminished, but this anæsthesia never attains the same degree as in chronic glaucoma, where it is often so great, that the cornea may be touched or even rubbed with a roll of paper or the brush of a quill pen, without its being felt. Occasionally, the anæsthesia is only partial, being confined to a certain portion of the cornea. This loss, or diminution, in the sensibility is due to the compression of the nerves supplying the cornea by the increased intra-ocular pressure, as is proved in cases of acute glaucoma, where the sensibility at once returns after diminution of the tension by iridectomy or paracentesis. The sensibility of the cornea is best tested by touching it delicately with a finely-rolled spill of silk paper, care being taken to keep the eyelids well apart, so that the conjunctiva is not touched. In healthy eyes, the cornea is so exquisitely sensitive that the slightest touch of a foreign body will be felt and resented.

The anterior chamber is found to be somewhat more shallow, the iris being pressed forward and even perhaps in contact with the cornea, the aqueous humour is clouded, the iris somewhat discoloured and of a dirty hue,—in some cases there may even be acute iritis, with deposits of lymph at the edge of the pupil,—the pupil is dilated and sluggish, and in elderly people a peculiar green reflex is often seen, coming apparently from the back of the eye.

It has already been stated that this green reflex was formerly considered as the principal and pathognomonic symptom of glaucoma. It is due to the following cause:—The lens undergoes certain physiological changes after the age of forty, amongst others assuming a yellowish tint. Now if the eye of an elderly person (and they are the most prone to the disease) is attacked by glaucoma, the aqueous humour becomes turbid and of a dirty, bluish-grey colour, and this bluish-grey tint, mixing with the yellow of the lens, gives rise to this peculiar green reflex. The latter is the more marked on account of the dilatation of the pupil which exists in glaucoma, as more light is thus reflected from the lens, more particularly its periphery, than when the pupil is

of the normal size. The greyish haziness of the vitreous humour, moreover, also tends to increase the intensity of the reflected light. Two facts prove that this is the true explanation of this green reflex. 1st. If the anterior chamber is tapped, and the aqueous humour flows off, the green reflex at once disappears. 2nd. If a youthful eye is attacked by glaucoma, this reflex is not visible, for at this period of life the lens has not yet acquired a yellow tint, and in such a case the pupil looks, therefore, only of a dirty, bluish-grey colour.

The eyeball will be found abnormally hard. The refractive media are generally so clouded as to render an ophthalmoscopic examination impossible. If they are, however, sufficiently clear to permit of the details of the fundus being seen, we find the retinal veins dilated, tortuous, and perhaps pulsating; the optic disc may be slightly reddened or of a dirty-yellow appearance, and there is either spontaneous arterial pulsation, or this may be readily produced by slight pressure on the eyeball. In the first attack of acute glaucoma, no cupping of the optic nerve is found, for this only occurs when the increased tension has lasted for some time. We also occasionally find choroidal ecchymoses, which are mostly situated at the equator of the eye, and generally likewise patches of retinal ecchymoses, chiefly at the point of division of the retinal veins. These are particularly seen after iridectomy, where the sudden relief of tension causes a rush of blood through the vessels and a rupture of the finer capillaries.

Vision may be either greatly impaired, so that the patient is only able to distinguish letters of the largest type or to count fingers, or it may be lost completely and suddenly, as at one stroke, being diminished to a mere quantitative perception of light, *i.e.*, to a mere distinction between light and dark, not an appreciation of colours and objects. In some very severe cases even this is lost. The field of vision is generally somewhat contracted, often concentrically. The patient is in the most cases also troubled with subjective appearances of light, balls of fire, showers of bright stars, etc.

The inflammatory symptoms may gradually subside, but the blindness continue; this is, however, very exceptional. In most cases, the inflammatory attack passes off after a few days or weeks, having, perhaps, undergone during this time several remissions, and vision may be entirely restored. Such a temporary recovery may occur spontaneously, or after treatment by antiphlogistics, mercury, opium, leeches, etc. But the eye does not return to its normal condition; the anterior chamber mostly remains somewhat shallow, the iris discoloured, the pupil dilated and sluggish, the field of vision somewhat contracted, and the tension of the eyeball more or less augmented. But the disease is not arrested. The acute inflammatory attacks may recur again and again, leaving the sight each time in a worse condition, and the visual

field more contracted, until the sight is finally completely destroyed. In other cases, no further acute inflammatory attacks occur, but chronic inflammatory exacerbations take place. Or the disease may progress insidiously, without any apparent recurrence of the inflammatory symptoms. The eyeball becomes more and more tense, the field of vision more contracted, often to a slit shape, the sight gradually lost, the fixation perhaps eccentric,* the cornea roughened and anæsthetic, the anterior chamber very small, the pupil greatly dilated and fixed, the iris discoloured, atrophied, and shrivelled up to a narrow rim, the subconjunctival veins turgid and tortuous, forming loops round the cornea. If the refractive media are sufficiently clear to permit of an ophthalmoscopic examination, we then find that there is a progressive excavation of the optic nerve, that the retinal veins are dilated and tortuous, and that there is either a spontaneous or easily producible arterial pulsation. We not unfrequently find, even after the disease has thus insidiously run its course without any inflammatory exacerbation since the first acute attack, that at a later stage these inflammatory attacks, even of a very acute kind, may again recur. When the disease has run its course, and all, even quantitative perception of light is lost, Von Graefe calls it glaucoma consummatum, or absolutum.

Sometimes we meet with a *sub-acute* form of glaucoma, in which all the inflammatory symptoms are much diminished in intensity; the pain is also less, nor is the sight so much impaired as in the acute cases.

There is likewise a hæmorrhagic form, which is peculiarly dangerous, as it is far less favourably influenced by iridectomy. The glaucomatous inflammation sometimes supervenes upon certain hæmorrhagic affections of the retina, particularly those met with in kidney disease. In these cases there is very considerable congestion and stagnation of the intra-ocular circulation. Now, although iridectomy may yield some temporary benefit, yet relapses but too frequently occur, and the operation is occasionally followed in this form by great intra-ocular hæmorrhage, which often destroys the eye. The power of absorption is also very much impaired in these cases, for we find, for instance, that hæmorrhage into the anterior chamber which is frequently produced by a very slight cause, such as a fit of coughing, etc., is very slowly and imperfectly absorbed.

Von Graefe† has called attention to a class of cases in which the

* By the term central fixation is meant, that a line drawn from the object through the centre of the cornea of the observer would strike his yellow spot; his optic axis being in fact fixed upon the object. Eccentric fixation, therefore, means that some other portion than the yellow spot is directed to the object, having retained more sensibility than the macula lutea.

† "A. f. O.," viii, 2.

course of acute glaucoma is most rapid, so that the sight, even all quantitative perception of light, of a previously perfectly healthy eye, may be entirely lost within a few hours, or even within half an hour, of the outbreak of the disease. He has termed this *glaucoma fulminans*. It is, however, a very rare form indeed, in comparison with the common acute glaucoma.

He has found that cases of glaucoma fulminans are also occasionally distinguished by a very rapid development of the other symptoms of increased intra-ocular pressure, viz., intense ciliary neuralgia, rapid dilatation of the pupil, soon reaching its maximum extent, rapid diminution in the size of the anterior chamber, anæsthesia of the cornea, and stony hardness of the eyeball. Sometimes, however, these symptoms are not more pronounced than in the common form of acute glaucoma, and yet the sight may be completely destroyed within an hour or two. The phenomena of vascular excitement may appear simultaneously with the loss of sight, but they occasionally lag behind in a peculiar manner. On ophthalmoscopic examination, the aqueous and vitreous will be found to be diffusely clouded, but if they are sufficiently clear to permit the details of the fundus to be seen, a considerable overfulness of the retinal veins will be observed. Decrease of the arteries and excavation of the optic nerve appear, comparatively, very rapidly. Von Graefe has in one case noticed the latter in a very deep form, even within a few weeks after the outbreak of the disease. He thinks we must assume that, in this form, the increase in the tension is either more considerable or more sudden than in the ordinary cases. On account of the great stagnation in the venous circulation of the eye in these cases, iridectomy is often followed by extensive hæmorrhage into the retina and choroid.

2.—CHRONIC INFLAMMATORY GLAUCOMA.

This disease may be insidiously developed from the premonitory stage. The premonitory symptoms become more frequent, and continue for a longer period; the intermissions are of less duration, until there are no longer any distinct intermissions, but only remissions, and the disease gradually and almost imperceptibly passes over into chronic glaucoma; the eye assuming the same condition as it did in the acute form, after the conclusion of the inflammatory process. It becomes more and more tense, until it may at last assume a stony hardness (T. 3), so that it cannot be dimpled by even a firm pressure of our finger. The subconjunctival veins become dilated and tortuous, the sclerotic assuming in the late stages of the disease a peculiar waxy hue, which is due to atrophy of the subconjunctival tissue, and to a diminution in

the calibre of the subconjunctival arteries. The cornea gradually loses its sensibility more and more, frequently, however, only in certain portions. It also becomes flatter. The anterior chamber becomes shallow, the aqueous humour clouded, and this turbidity may change with great rapidity, occurring, perhaps, several times a day. It may be produced by any excitement or fatigue, often coming on after a full meal, excessive exercise, etc. The iris is pushed forward, so as to be perhaps almost in contact with the cornea. It is dull and discoloured, its fibrillæ being more or less obliterated, and not showing a clear and distinct outline. The pupil is widely dilated, and either immoveable or extremely sluggish on the stimulus of light. The field of vision becomes greatly contracted, assuming, perhaps, a slit shape. As has been before pointed out, the contraction of the field in glaucoma begins, as a rule, at the inner side, extending from thence upwards and downwards, so that the outer portion is the last to become affected. Vision progressively deteriorates, the fixation often becomes eccentric, and finally the sight may be completely destroyed, so that not even a remnant of quantitative perception of light is left, even although the light be intensified by means of a powerful biconvex lens. On ophthalmoscopic examination, we find that the fundus always appears more or less clouded, often to such an extent as to prevent our distinguishing the details of the background of the eye. This haziness is due to opacity of the aqueous and vitreous humours, and in some cases also of the cornea and lens. But if the media remain sufficiently clear to permit of an examination, we find the retinal veins widely dilated and tortuous, the arteries diminished in calibre, and presenting either a spontaneous or easily producible pulsation; the optic nerve more or less deeply cupped, and the vessels displaced at its periphery. The chief and characteristic difference between the acute and the chronic inflammatory glaucoma is, that the latter may lead to even complete destruction of sight, without any symptoms of severe inflammation or great pain. There may only be insidious attacks of chronic, frequently recurring inflammation, leading gradually to loss of sight. At first these inflammatory attacks may be intermittent, occurring at considerable intervals, whereas, later they may only show remissions. In other cases again, after the eye has been suffering for some time from these insidious chronic inflammations, it may be suddenly attacked by a severe acute exacerbation, causing very great pain and suffering. These acute exacerbations may recur again and again, and the pain may be so severe that recourse must be had to an iridectomy for its relief, even although there is no chance of restoring any sight. In such instances, the patient and his friends must be warned beforehand that the operation is not performed for the sake of giving any sight, but only in order, if possible, to relieve the pain. In many cases, particularly if the iridectomy be

made sufficiently large, the relief may be permanent; in others, it is only temporary. When speaking of acute glaucoma, it was mentioned that after the first acute attack, the disease might gradually pass over into chronic inflammatory glaucoma, no fresh acute attack occurring, but only chronic, latent, inflammatory exacerbations. Sometimes the course of chronic glaucoma is so insidious that the sight of the eye may be completely lost without the patient being aware that anything was the matter with his eye, the other being well. Perchance he closes the good eye, and then discovers the blindness of the other, and thus often supposes the vision to have been suddenly lost. On being questioned, he may remember that he occasionally experienced slight pain in and around the eye, which he supposed to be rheumatic; that it occasionally became somewhat reddened, and watered a little, which was attributed to a cold; but otherwise he noticed nothing peculiar. This may not only occur amongst the humbler classes, following pursuits which require but little employment of sight in reading, etc., as amongst labourers; but it may even happen amongst men of literary habits and avocations, employed for many hours daily in reading and writing.

When the disease has run its course, and all sight is lost, Von Graefe terms it glaucoma absolutum. Then any chance of benefiting the sight by an operation is past. The lens frequently becomes opaque, assuming the peculiar greenish hue so characteristic of glaucomatous cataract. The glaucoma absolutum may exist for a length of time without the eye undergoing any changes, except that atrophy of the iris, choroid, and optic nerve become more and more apparent. In other cases, frequent—often very acute and violent—inflammatory symptoms show themselves, accompanied by intense ciliary neuralgia and headache. In the last stages of the disease other changes occur; the iris becomes reduced to a narrow streak, the cornea opaque and softened, more particularly in its central portion, and hæmorrhagic effusions take place into the anterior chamber, the vitreous humour, and the inner tissues of the eyeball. Sclerotic staphylomata are formed, and suppurative inflammation may even occur, leading to atrophy of the globe. Von Graefe calls this the stage of glaucomatous degeneration. In it, iridectomy no longer proves a sure remedy for the inflammatory complication. Generally the sight is completely lost. Sometimes the one eye may be lost from chronic inflammatory glaucoma, or from the apparently non-inflammatory form (glaucoma simplex), and the other be attacked by acute glaucoma.

3.—GLAUCOMA SIMPLEX (DONDERS).*

This disease was for a long time considered as distinctive from glaucoma, with which it was supposed to have nothing in common but the excavation of the optic nerve. Von Graefe described it first under the title of "Amaurosis with excavation of the optic nerve." But he has now also admitted it into the glaucomatous group of diseases.

The course of the disease is often exceedingly insidious, so that it may be considerably advanced before the patients pay any particular attention to it, supposing, but too frequently, that the increasing weakness of sight is simply owing to old age. Though this impairment of vision may be noticed also for distance, it makes itself particularly felt in reading, writing, sewing, etc., and convex glasses are found but of slight assistance. There is generally no premonitory stage, for the intermittent obscurations, rainbows round a candle, etc., are mostly due to some slight inflammatory attack, accompanied by cloudiness of the refractive media.

The external appearance of the eye may be perfectly healthy. The refractive media may be quite clear, the cornea sensitive, the anterior chamber of the normal size, the iris healthy and not discoloured, or but very slightly so, this being only apparent on comparison with the iris of the other healthy eye; the pupil perhaps slightly dilated and a little sluggish. But the eyeball is generally found to be abnormally tense, and with the ophthalmoscope, we observe that the optic nerve shows a glaucomatous excavation. Sometimes this increase in tension varies greatly, being very marked at one time, and hardly, if at all, apparent at another; it is of great consequence, therefore, to examine such eyes frequently, and at different periods of the day. There is still a good deal of discrepancy of opinion as to the invariable presence of increased tension of the eyeball in this form of glaucoma. Some assert that tension is always increased in all cases of glaucoma simplex; others, again, think that although this undoubtedly does occur in the majority of cases, yet that in others it is absent. Von Graefe, in particular, maintains that the intra-ocular tension is not in all cases increased in a marked manner. He thinks that the occurrence of glaucomatous excavation of the optic nerve, without any marked increase in the tension of the eyeball, may be explained thus:—That perhaps the resisting power of the optic papilla varies in different individuals, perhaps also at different ages. Just as iritis and iridocyclitis serosa may occasionally be observed, particularly in young individuals, to exist for some length of time with an unmistakeable increase of tension, without

* Haffmann, "Archiv." viii, 2.

any excavation, may not, on the other hand, the power of resistance of the optic papilla be absolutely (?) or relatively so diminished, that an exceedingly slight increase of tension, not exceeding the normal range of variation of tension, may already cause an excavation? But every, even the most considerable increase of tension, requires to act some time before it leads to cupping. The truth of this is shown in cases of acute glaucoma, where there is no cup directly after the first acute attack, although this may have lasted for some weeks, during which the intra-ocular pressure was greatly increased. In glaucoma fulminans it is somewhat different, for there it appears to supervene early. But a long-continued, though slight, increase of tension will lead gradually to an excavation of the optic nerve, which increases more and more in depth; the vessels then become interrupted at its edge, and there is spontaneous or easily producible arterial pulsation. The veins appear dilated, and perhaps somewhat tortuous. If the tension continues, the optic nerve gradually atrophies, the arteries become diminished in calibre, and complete blindness may supervene. It is found that if the increase in tension is very slow and gradual, the excavation of the optic nerve may become very considerable in depth, without the sight or field of vision being markedly impaired. Increased intra-ocular tension is, therefore, generally the first symptom of glaucoma simplex, being accompanied perhaps by a relatively rapid increase of presbyopia, and some hypermetropia; gradually, however, the optic nerve becomes cupped, and these symptoms may last for a considerable time without others supervening. In some cases, however, the augmented tension may exist for a long period without the presence of other glaucomatous symptoms.

Occasionally, glaucoma simplex may run its course, even to complete blindness, without the appearance of any inflammatory symptoms. The disease slowly, but surely, progresses, the eyeball becomes more and more hard, the cornea anæsthetic, the anterior chamber narrower, the vessels more turgid and congested, the pupil dilated and sluggish, the retinal veins gorged, the arteries diminished in calibre, and perhaps pulsating, the optic nerve deeply cupped and whitish in colour, the visual field more and more contracted, and the sight finally destroyed. But in the majority of cases, inflammatory symptoms show themselves during the progress of the disease, and these may assume an acute, a chronic, or an intermittent type. They present the same character as in acute or chronic inflammatory glaucoma; rapid diminution of vision, obscurations, rainbows round a candle, augmentation of tension, dullness of the aqueous and vitreous humours, etc. Sometimes, however, these inflammatory symptoms may not appear until the disease has long run its course, and the sight has been completely lost. In other cases, they may be so transitory as to escape our observation, and their previous existence may not be ascertained, except by a very

close examination into the history of the case. Where manifest symptoms of inflammation are apparently wanting in a case of glaucoma simplex, the condition of the other eye, if healthy, should be ascertained; and then, on a comparison of the two, we may often detect slight changes in the colour and structure of the iris, and slight haziness of the aqueous humour of the affected eye, which, but for this comparison, would have escaped our attention. Von Graefe also points out the necessity of examining such patients at a period of the day most favourable for the observance of any inflammatory symptoms, and calls attention to the important fact, that whilst the inflammatory symptoms, particularly the deeper injection, become commonly more apparent soon after sleep, the reverse obtains in glaucoma, for here they become the more prominent the longer the patient keeps awake, more particularly if he remains up beyond his customary time for retiring to bed. He mentions an interesting case, illustrative of the peculiar transitory character which the inflammatory symptoms may occasionally assume. The right eye of the patient in question ordinarily presented a perfectly healthy appearance, but for several years past, it assumes a well-marked glaucomatous condition when he has been playing cards for some length of time, and only then. On such occasions, the anterior chamber becomes shallower, the aqueous humour diffusely clouded, the pupil somewhat dilated and sluggish, the retinal veins dilated, particularly towards the edge of the optic disc, and arterial pulsation may be produced by the faintest pressure upon the eyeball; together with these symptoms, there is indistinctness of vision, surrounding objects appearing to be covered by a veil or cloud. Not till the following morning have all these symptoms disappeared, then the sight is again normal (No. 1 of Jäger's types at 12 inches), and the increase in the tension of the eyeball, which was very manifest during the attack, is no longer appreciable. We often find in glaucoma simplex, that the second eye becomes affected soon after the disease has manifested itself in the other; it, moreover, often attacks myopic eyes. In both of these points it differs materially from the majority of cases of inflammatory glaucoma.

Haffmann considers that glaucoma simplex is identical with the premonitory stage of glaucoma of Von Graefe, and maintains that all the symptoms enumerated as existing in the premonitory stage, are present in glaucoma simplex; but I think it of the greatest practical importance to maintain the existence of a premonitory stage, for we find, after all, that its course is generally very different from that of glaucoma simplex. The premonitory stage may exist even for many years without producing any glaucomatous changes in the eye, the symptoms may only show themselves at long intervals, and in their intermissions the eye may be perfectly healthy; or they may recur at

more frequent intervals, and pass over into acute or chronic glaucoma. In other cases, they may pass over into developed glaucoma after only a few premonitory attacks. Besides this, we find that the most brilliant results of iridectomy are to be expected in the premonitory stage; but this is by no means the case in glaucoma simplex.

4.—SECONDARY OR CONSECUTIVE GLAUCOMA.

We find that certain diseases of the eye may in their progress become complicated with glaucoma, the eye then presenting glaucomatous symptoms superadded to those of the original disease. This complication may especially occur in the following diseases, viz., 1, iritis; 2, sclerotico-choroiditis posterior; 3, traumatic cataract; 4, prominent cicatrix of the cornea (anterior staphyloma); 5, dislocation of the lens. A fuller account of this subject will be found in the different articles upon these diseases.*

But glaucoma may also complicate diseases which stand in no causal relation to it. Thus it may supervene upon common senile cataract, or upon cerebral amaurosis. In the former case, the cataract should never be removed at the same time that the iridectomy is made for the glaucoma, for this will greatly increase the danger of intra-ocular hæmorrhage, on account of the sudden diminution of the tension. Some months should elapse between the two operations, in order that the improvement in the circulation, tension, and nutrition of the eye may have become thoroughly established.

5.—OPHTHALMOSCOPIC SYMPTOMS OF GLAUCOMA.

The characteristic ophthalmoscopic symptoms of glaucoma are—pulsation of the central vessels of the retina, and excavation of the optic nerve (vide p. 390).

The stasis in the venous circulation of the retina is often very considerable, the veins are dilated and tortuous, the smaller veinlets assuming a corkscrew appearance; if the stasis be very great, the

* It is an interesting fact that glaucoma may also, in rare instances, become developed in an eye in which the lens is absent, and this, as has been pointed out by Rydel ("Bericht über die Wiener Augenklinik," p. 155), is an important point with regard to the theory that the beneficial effect of the iridectomy in glaucoma is due to its relief of the irritation and teazing of the iris, which occur when the latter, together with the lens, is pressed forwards owing to the increased intra-ocular tension. Now, in two cases of glaucoma in eyes without a lens, the anterior chamber was deep and the iris lying in its normal plane, so that there could be no question of its being teazed or irritated by pressure. Heymann also reports some cases of glaucoma becoming developed in eyes in which the lens was absent ("Kl. Monats.," 1867).

larger venous branches may even show peculiar bead-like swellings. This is, however, very rare. I have seen one case in which there was a distinct tendency to these swellings, but Liebreich figures a case, in his "Atlas d'Ophthalmoscopie" in which it existed in the most marked manner. After diminution of the pathological increase in the intra-ocular pressure, the stagnation in the venous circulation ceases, the calibre of the veins diminishes in size, and they lose their tortuosity. For instance, after the performance of iridectomy, and the consequent diminution in the tension of the eyeball, we frequently have an opportunity of observing the change in the venous circulation. Thus, extensive retinal ecchymoses are perhaps met with, and the veins, which, before the operation, were very dilated and swollen, are now much diminished in size and paler. The retinal arteries in glaucoma appear very thin and small, and much paler than in the normal eye.

Whilst spontaneous venous pulsation (vide p. 308) may occur in normal eyes, spontaneous arterial pulsation is only observed if the intra-ocular tension is markedly increased. The arterial pulsation is synchronous with the radial pulse, but slightly later than the carotid pulsation. It is confined to the disc, and presents a rapid to-and-fro movement, and a rhythmical filling and emptying of the arteries. The arterial diastole takes less time than the systole, and is characterised by a rapid, jerky entrance of a column of blood into a previously empty vessel.

6.—ON THE NATURE AND CAUSES OF THE GLAUCOMATOUS PROCESS.

The true nature and cause of the glaucomatous process are still involved in some obscurity and doubt. In the great majority of cases of glaucoma there are marked inflammatory symptoms, but it must be freely admitted that we do sometimes, although far more rarely, meet with cases of glaucoma simplex, in which no inflammatory symptoms can be detected. Indeed it is the latter fact which causes all the difficulty, for we can easily explain the increased tension, and all the symptoms which follow in its train, as due to an inflammatory origin; but we cannot as satisfactorily explain what constitutes the primary cause of the increased tension in glaucoma simplex, which leads to the gradual loss of sight from excavation and degeneration of the optic nerve without any appearance of inflammation. In the inflammatory forms of glaucoma, the seat of the inflammation is chiefly in the uveal tract, the choroid, ciliary body, and the iris. But other structures, such as the cornea, sclerotic, and retina may subsequently become involved. This irido-choroiditis causes an increase of serosity, more

especially in the vitreous humour, and an augmentation of the intra-ocular tension; the latter giving rise to all the glaucomatous symptoms described above. Together with this increase in the volume of the vitreous humour, there exists in glaucoma a diminution in the power of absorption, and this may explain why these serous effusions are not removed, as in other forms of choroiditis, by an increased activity of the absorbents. Attention has been called by some writers to the fact, that the sclerotic appears peculiarly rigid and unyielding in glaucoma, and it has been supposed that this is not unfrequently congenital or hereditary, and may form a predisposing element to glaucoma. Now, if such an abnormal rigidity of the sclerotic exists, we can easily understand how any rapid, though slight, augmentation in volume of the contents of the eyeball, must not only give rise to a disproportionate increase in the intra-ocular pressure, but must also augment the tendency to stagnation in the blood-vessels. Coccius has found in a case of glaucoma that the sclerotic had undergone fatty metamorphosis, and he thinks that the affection of the sclerotic may perhaps have been the cause of the increased intra-ocular tension. There can be no doubt that the rigidity of the sclerotic plays a very important part in glaucoma. For we find that in youthful individuals, in whom the sclerotic is more elastic and yielding, an increase of the intra-ocular tension dependent upon some inflammation of the uveal tract may exist for some time without exerting any deleterious effect upon the optic nerve or retina. The sclerotic, perhaps, yields a little as a whole before this increased tension and adapts itself to it, or it may become slightly bulged at a certain point; whereas, in older persons, in whom the sclerotic is more firm, rigid, and unyielding, the existence of an increase in the intra-ocular tension is much more dangerous, for it soon causes the least resistant tissue (in this case the optic nerve) to yield before it, and become excavated.

When considering the different forms of glaucoma, we had frequent occasion to point out the great variations in the intensity of the inflammatory symptoms. We saw that in acute glaucoma, the inflammation might be very severe during the first attack, but that after its subsidence, the inflammatory exacerbations might assume an insidious chronic character, and the disease gradually pass over into glaucoma absolutum, without the recurrence of any acute attack. Again, that in the chronic form the inflammatory symptoms might, at the outset, be but little marked, but that in the course of the disease acute exacerbations, even of a very severe character, might show themselves. In the third form (glaucoma simplex), it was stated that the disease might occasionally run its course without the apparent occurrence of any inflammatory symptoms—the eyeball becoming stony hard, the optic nerve deeply excavated, the sight destroyed—but the refractive media

remaining perfectly clear. But in the vast majority of cases of glaucoma simplex, inflammatory symptoms, of varying severity, do show themselves during the progress of the disease. Now, on account of the fact that glaucoma simplex may occasionally run its course without the apparent presence of any inflammatory symptoms, and on account of the increased tension being sometimes the first manifest symptom of the disease, it has been supposed by Donders that the inflammation is not the integral part of the glaucomatous process, but only a complication, which, though occurring in the majority of cases, need not necessarily be always present. He considers the increase in the intra-ocular tension as the essence of the disease, and, therefore, the glaucoma simplex, which runs its course without any inflammatory symptoms, as the primordial type of the disease; and he thinks that the acute or chronic inflammation which shows itself in the majority of cases of glaucoma is but a complication, which is of secondary importance, and not necessary to the glaucomatous process. He, therefore, speaks of glaucoma simplex, and glaucoma cum ophthalmiâ. The anomaly in the secretion of the fluids of the eye he thinks due to an abnormal irritation of the nerves regulating the intra-ocular secretion. Now from some very interesting and ingenious experiments made by Dr. Wegner (A. f. O., xii, 2, 1), it appears certain that the vaso-motor nerves of the iris, and in all probability those of the choroid also, are furnished by the sympathetic. He found in experiments upon rabbits that a division of the sympathetic in the neck leads to a dilatation of the vessels of the iris and choroid, and a diminution of the intra-ocular pressure. It may consequently be assumed that irritation of the vaso-motor nerves would produce an increase in the intra-ocular pressure. But, as Wegner states, the latter experiment is extremely difficult and uncertain, on account of the impossibility of regulating the degree of irritation with sufficient delicacy. The intimate relation between the branches of the fifth supplying the eyeball and the sympathetic, easily explains how an irritation of the former may be reflected to the sympathetic, and thus cause an hypersecretion of fluid within the eye, and an increase in the intra-ocular pressure. In this way the cases of glaucoma simplex are readily explained. Such cases have been observed by Hutchinson* and Horner.† In one case of Horner's, the attacks of neuralgia were simultaneously accompanied by glaucomatous symptoms. From these facts we might certainly venture upon the hypothesis, that in glaucoma simplex some extra-ocular irritation of the sympathetic gives rise to the hypersecretion of fluid and increase of tension within the eye. At present, however, it must be admitted that these questions demand still further investigation for their satisfactory solution.

* "R. L. O. H. Rep.," iv and v. † "A. f. O.," xii, 2.

It has also been urged that inflammatory glaucoma (glaucomatous ophthalmia) cannot occur primarily in a hitherto healthy eye, that an increase in the tension of the eyeball pre-existed; that, in fact, glaucoma simplex had existed, perhaps quite unknown to the patient, and that the inflammation supervened upon this. But we sometimes meet with cases of acute glaucoma in which there was no trace of increased tension, or any other glaucomatous symptom, prior to the outbreak of the disease. Thus Von Graefe mentions cases in which he has operated for glaucoma upon the one eye, the other being at the time of operation of quite a normal degree of tension; and yet the latter was soon after attacked by glaucoma, in one case even by glaucoma fulminans. He thinks, moreover, that the mere increase of tension should not be allowed to constitute a premonitory stage, for even a considerable increase of tension may exist for an indefinite period without the appearance of other glaucomatous symptoms. In families in which glaucoma is hereditary, an increased resistance, often of a marked degree, exists even in infancy, and the disease may not show itself till middle age, or even not at all.

The question whether the inflammation be but of secondary importance or not, is one of much consequence. The great difficulty lies in those cases (although they are but rare) in which we find the glaucomatous disease running its course without any, even the slightest symptom of inflammation; for if this be possible, then, indeed, we cannot look upon the inflammatory symptoms as the *sine quâ non* of the disease. In such cases we might, perhaps, venture upon the hypothesis that an extra-ocular irritation of the sympathetic was the cause of the glaucoma. But at present we have no certain proofs to rely upon. Von Graefe maintains the inflammatory nature of glaucoma, accompanied by an increased secretion of the fluids of the eye, and by augmented tension. He thinks that in the cases of glaucoma simplex a lengthened observation will generally show us that transitory inflammatory exacerbations (perhaps of a very ephemeral nature) do mostly occur. Such exacerbations may be but very slightly marked, and easily escape the attention of the patient or his medical attendant; or they may only occur at certain periods, or be produced only by certain causes, as, for example, in the case mentioned above, in which they only came on whenever the patient played at cards. The absence of any externally visible symptoms of vascularity is no proof of the non-existence of internal inflammation, for the ophthalmoscope constantly reveals to us the presence of even considerable inflammation of the choroid and retina, without the existence of any increased vascularity of the external tunics of the eyeball. The haziness of the aqueous and vitreous humours, which may arise during such an ephemeral exacerbation, may likewise be so slight and delicate as to escape detection with the ophthalmoscope, for

we know that fine diffuse opacities of the aqueous humour are often quite invisible by transmitted light.*

Glaucoma is a disease of old age. It is most frequently met with between the ages of 50 and 60, but may occur even at a much later period. It is seldom observed in early life, or before the age of 30. Females appear to be much more subject to it than males, and it is most apt to occur soon after the cessation of menstruation. We find that the males who are attacked by glaucoma frequently suffer from gout and disorders of the digestive organs, and are often subject to hæmorrhoids. There is no doubt that glaucoma may be hereditary, and, as has been already mentioned, the eyes of the individual members of families in which this disease is hereditary often show, even in early life, a peculiar increase in the resistance of the eyeball, and a rigidity and unyieldingness of the sclerotic; and these symptoms may exist for many years without any glaucomatous outbreak. In fact, the latter does not generally occur until middle age.

We have stated that glaucoma may appear as a primary or a secondary disease. In the former case, it may occur after severe external injuries, or without any apparent external or internal cause. It always attacks one eye first, and may remain confined to this; but when once the one eye has become affected by glaucoma, there is a great tendency in the disease to invade the other also. We must, therefore, always prepare such a patient for the eventuality—the great likelihood even—of the other eye becoming also affected. By careful and judicious treatment, and by abstinence from excessive fatigue and exertion of the eye, much may be done to retard the attack, and to break its force. The nature of the glaucomatous process in the first eye is no criterion as to the form which may occur in the other. We find, for instance, that the first eye may be suffering from glaucoma simplex, or chronic inflammatory glaucoma, and the other be attacked by the acute form, or even by glaucoma fulminans. The time which may intervene before the second eye becomes affected varies greatly; sometimes a few days only elapse, in other cases many months, or even years. In the secondary glaucoma, which may supervene upon another affection (traumatic cataract, irido-choroiditis, etc.), this disposition to extension of the disease to the other eye is far less than in primary glaucoma; but still such a tendency does exist, and may be called into activity by any injury to, or operation upon, the sound eye.

* For further information upon this interesting and important subject, I must refer the reader to Von Graefe's and Dr. Haffmann's papers on Glaucoma, "A. f. O.," viii, 2.

7.—PROGNOSIS OF GLAUCOMA, ETC.

If the disease be left to itself, or be treated by inefficient remedies, the prognosis is most unfavourable, as it leads sooner or later to destruction of sight. The old treatment, which consisted in leeching, cupping, mercury, opium, etc., fails, and is sure to fail, in staying the progress of the disease. The acute inflammatory attack may subside under their use, or even without any treatment whatever; the inflammatory symptoms may diminish, the refractive media again become transparent, the sight restored, and the patient and his medical attendant may deceive themselves with the fond hope that the dangerous disease has passed away and is cured. But this is not so. Sooner or later the eye again becomes attacked, perhaps by acute exacerbations, perhaps by insidious chronic inflammations, which gradually lead to total and irremediable blindness.

The chief and most important indication in the treatment is the diminution of the abnormally increased intra-ocular tension, for as long as this exists we cannot hope to arrest the progress of the disease. Paracentesis of the cornea has long ago been tried in the treatment of glaucoma, and has lately been again strongly recommended as a cure for this disease; but we know that its effect is but transient, that it relieves the intra-ocular pressure for a short time, but that this relief is not permanent, for increased intra-ocular tension and other glaucomatous symptoms soon manifest themselves again. Division of the ciliary muscle (as it has been termed) has also been much vaunted as a cure for glaucoma. That it may temporarily relieve tension by causing the escape of the aqueous, and perhaps of some of the vitreous humour, cannot be denied; but tapping the anterior chamber will do the same thing. If a considerable amount of vitreous humour flows off, the tension may even be permanently diminished. But the escape of vitreous in glaucoma is a thing to be avoided if possible, and not to be desired or courted; for we find that the loss of vitreous (for instance, in the operation of extraction of cataract) generally renders the eye more prone to chronic inflammatory affections of the choroid, accompanied by opacities of the vitreous humour, etc. At present no evidence has been brought forward by the supporters of this operation that would permit of our placing it side by side with iridectomy in the treatment of glaucoma.

Iridectomy, on the other hand, has been proved to diminish (and in the vast majority of cases permanently), the abnormally increased intra-ocular tension. The admirable results of this operation in the treatment of glaucoma have long admitted of no doubt, tested and

endorsed as they have been by most of the distinguished oculists of Europe.

Some opposers of the operation have, apparently, thought, that its supporters claimed for it the power of restoring sight in all cases of glaucoma, whatever their stage or nature might be. But none of its advocates have ever done this; they have only upheld its curative powers in those cases in which irreparable changes in the structures of the eye had not yet taken place. The extent of the benefit which may be expected from iridectomy will, therefore, depend upon the stage and form of the disease, in which it is had recourse to. It may be laid down as an axiom, that the sooner the operation is performed when the premonitory symptoms have become marked and frequent, or after the outbreak of the disease, the better; so that the affection has not yet had time to produce material changes in the structures of the organ. Let us now shortly consider what prognosis may generally be given of the beneficial effects of iridectomy in the various stages and forms of glaucoma.

The Premonitory Stage.—As long as the premonitory symptoms only occur at distant intervals and the intermissions are complete, the eye returning to its normal condition during the intervals, we may postpone the operation with safety. We should, however, warn the patient against any excessive fatigue or exertion of the eyes, and their exposure to very bright light or rapid changes of temperature; against everything, in fact, that may produce hyperæmia and irritation of the organ, and which may thus hasten the outbreak of the disease. He must also abstain from excesses of every kind. But the system of lowering and starving patients suffering from glaucoma is not advisable, indeed often most injurious, more particularly if they are elderly, and have been very free livers. Such patients should be placed upon an easily digestible, nourishing, and even perhaps generous diet, and should be permitted a moderate allowance of stimulants, the quantity being regulated by their former habits and the condition of their general health.

If the intermissions are no longer complete, but there are only remissions of the symptoms; if the periodic obscurations, the ciliary neuralgia, the iridizations, occur at short intervals of a day or two; if the eccentric vision becomes impaired, or the field even contracted, the vessels congested, and the eyeball tense, it would be dangerous to delay the operation any longer. The acute attack is then probably imminent, and we cannot foretell what its severity may be, and whether it may not burst forth in a very acute form, even that of glaucoma fulminans, and rapidly lead to such serious lesions of the structures as greatly to imperil, or even to spoil, the integrity of the organ, before operative aid can be obtained. But there is another reason why we should not

wait for the acute outbreak of the disease, for we cannot be certain that it will occur, as the affection may gradually, and perhaps almost imperceptibly, pass over into chronic glaucoma with excavation of the optic nerve, accompanied by such a deterioration of the retina and other tissues that the operation may then prove of but little avail. If iridectomy is performed during the premonitory stage, when the symptoms become marked and the attacks frequent, but before any structural changes have taken place, the prognosis is most favourable, for the progress of the disease is arrested, and the sight of the eye saved.

In *acute inflammatory glaucoma* the prognosis is also favourable, if the operation is only performed sufficiently early. If the impairment of vision increases very rapidly, if the sight is already diminished to a mere quantitative perception of light, or if the visual field is much contracted, the delay of the operation would be most dangerous, and it should be performed at once. We may generally expect a nearly perfect result if iridectomy be had recourse to within a fortnight after the outbreak of acute glaucoma; always remembering, however, that at least good quantitative perception of light must still be present. But we should never voluntarily wait so long, as there is always a risk that during the delay the tissues may undergo serious changes. Von Graefe lays particular stress upon the fact, that the immediate necessity for the operation depends less upon the intensity of the inflammatory symptoms, the acuteness of the pain, or the amount of increased tension, than upon the state of the vision. If this be not greatly impaired, if the patient is still able to read large type, the operation may be postponed, if it be necessary, for a day or two. But in the interim, the patient must be closely and anxiously watched, and if rapid diminution of vision occurs, no further delay must be permitted. Sometimes the question may arise, whether a patient suffering from an attack of acute glaucoma may be permitted, if necessary, to undertake a journey in order to have the operation performed, or whether he may be safely allowed to wait until the inflammation has subsided, and the eye has again become "quiet." Here I must strongly urge the necessity of not delaying, for if the journey be postponed until the inflammation is allayed, the eye may be found to be irretrievably lost. The journey would have proved far less dangerous than the delay. But even if the most favourable event should occur, if the inflammation should subside, and the eye apparently regain its former condition, we know but too well that the disease is not cured, that it will sooner or later recur, either in the acute form or as chronic glaucoma. In the latter case, the progress may be so insidious that serious and irreparable changes in the optic nerve, the retina, and the coats of the vessels may have occurred, before the patient's attention is attracted to the state of his eye.

In glaucoma fulminans the operation must be performed as soon as possible. The structures undergo such great and rapid changes, that the effect of the operation may not be perfect even when it is performed within three days after the outbreak of the disease, as was shown in a case of Von Graefe's.

In those cases of acute glaucoma in which the pain is very intense, and there is much inclination to vomit, but the impairment of vision is only moderate, Von Graefe thinks it may be better to wait a day or two before performing iridectomy. Here he employs the subcutaneous injection of morphia, gr. $\frac{1}{8}$ to $\frac{1}{3}$, in the region of the temple, in order to procure a good night's rest, and to quiet the nervous system before operating. But if we give chloroform the operation need not, I think, be postponed on this account. In fact, iridectomy proves the best antiphlogistic, and its beneficial effects in acute glaucoma are most marked and brilliant if it be performed sufficiently early. The relief of the often agonising pain is generally immediate; patients soon fall into a tranquil and refreshing sleep, after having perhaps passed several sleepless, miserable nights; the inflammatory symptoms rapidly subside; the sight is greatly improved, partly from the diminution in the intra-ocular pressure, and partly from the escape of the turbid aqueous humour. This improvement rapidly increases during the first fortnight, and is generally due to the absorption of the retinal ecchymoses which occurred during the operation. The improvement of sight reaches its maximum extent about two months after the operation. If the latter has been performed sufficiently early, vision is generally perfectly restored, the patient being able to read the very finest print (with, of course, the proper glasses, if he is presbyopic), and this improvement is, in the vast majority of cases, permanent. Such a result may even be expected up to within a fortnight after the outbreak, if, at the time of the operation, there was still good perception of light and no considerable contraction of the field.

In the later stages of acute glaucoma the results of the operation vary. In such cases, the prognosis will depend upon the extent to which the degenerative alterations in the tissues have already advanced. The prognosis may be favourable if the visual field is only moderately contracted, more particularly if the contraction is not slit-shaped but concentric, the fixation central, and vision not very greatly impaired, especially if the impairment depends upon cloudiness of the refractive media and increased intra-ocular tension. The operation will generally not only restore an excellent and useful amount of vision, but this improvement will mostly be permanent. It is different, however, if the field is greatly contracted, especially if it be slit-shaped, if the fixation is eccentric, vision much impaired, and the latter due, not to opacity of the refractive media, but to an already considerable excavation of the

optic nerve and deterioration of the retina. Here the prognosis must be guarded, for although the operation may do much even in such cases, the good results may sometimes not be permanent, but the sight be gradually lost again, either through recurrence of inflammatory attacks, or through progressive excavation and atrophy of the optic nerve.

I have already stated that iridectomy sometimes proves of but little avail in the hæmorrhagic form of glaucoma, on account of the extensive intra-ocular bleeding which ensues upon the operation. It may afford temporary relief, but relapses are but too frequent; and although these may be alleviated by repeating the operation, yet the eye cannot generally be finally rescued, although in some cases a certain amount of sight may be perhaps preserved.

In chronic inflammatory glaucoma the prognosis must also be guarded. The progress of the disease is but too often so insidious, that the patients do not apply for medical aid until very considerable changes have taken place in the tissues, more particularly the optic nerve and retina. Iridectomy will, however, generally arrest the disease, and preserve the existing amount of vision, or even improve it. This is particularly the case if the fixation is still central, the sight not too much impaired, the optic nerve not deeply excavated, and the field of vision not slit-shaped, but contracted laterally or concentrically. In such cases, the progress of the disease and of the structural changes is generally stayed, and the existing amount of vision permanently preserved. The beneficial effects of the operation are, however, far more slowly developed than in acute glaucoma. Months elapse before the improvement has reached its maximum degree, or before we can be certain that the effect will be permanent. But even when the field is greatly contracted and the fixation very eccentric, we may yet occasionally be able permanently to preserve a certain amount of sight, enough perhaps to enable the patient to find his way about. And even this little must be looked upon as a great boon in comparison with total blindness. But in such cases, the effect of the operation is sometimes only temporary, the tension of the eye again increases, the vision slowly but steadily deteriorates, leading at last to complete loss of sight. This is far more frequently due to progressive atrophy of the optic nerve, than to a recurrence of the glaucomatous symptoms. Should a recurrence of the glaucomatous inflammatory symptoms, with increased tension, take place, the operation may be repeated with benefit. This is particularly the case when the original iridectomy has not been sufficiently large, or the iris has not been removed quite up to its ciliary insertion.

Von Graefe has called attention to the fact, that a whitish discoloration of the optic nerve (which is generally a symptom of progressive atrophy) sometimes occurs in glaucoma, and even increases in intensity

for some months after the operation (particularly in cases of some standing), without endangering the sight. The discoloration progresses up to a certain point and then remains stationary. It is only dangerous, when this increasing whiteness is accompanied by a simultaneous deterioration of vision.

Even in those cases of glaucoma which are not accompanied by manifest inflammatory symptoms (glaucoma simplex), we find that iridectomy proves of service. Here, as in chronic glaucoma, the misfortune often is, that the patient does not apply until the disease has far progressed. If only one eye is affected, this may be nearly lost before the patient even discovers that anything is the matter with it, and then on examination we find that the disease has nearly, if not completely, run its course, that there are such serious changes in the structures that the operation can prove but of little if any avail. It is otherwise if the second eye becomes affected with the same form of disease; for then the patients speedily seek medical aid, and will consent to a timely operation, even although their sight may still be good. In order to arrest the disease permanently, the operation must be performed early, before irreparable changes in the tissues have been produced. Graefe particularly urges that the operation should be performed in time, and should not be delayed until considerable impairment of vision or inflammatory symptoms manifest themselves. Here also the beneficial effects of the iridectomy show themselves slowly and gradually. If the atrophy of the optic nerve has not proceeded too far, a steady, though slow, improvement will take place. He has seen cases in which, during a period varying from half a year to three years, the field of vision and the sight had gradually but persistently deteriorated, and where, after iridectomy (during a period of observation extending from one to three years), either a complete arrest, or even a considerable improvement, occurred. Such improvement also occurred in two cases in which, together with a perfectly typical excavation, all appreciable increase of tension was absent. He considers that the improvement is the more likely, if the impairment of sight depends not only upon the condition of the optic nerve, but is also due to a still evident impediment in the conducting power of the retina.

In *glaucoma absolutum*, in which all sight, even the quantitative perception of light, is lost, iridectomy is never indicated except to diminish the inflammatory symptoms or severe pain. For these purposes it is to be performed, care being taken to impress upon the patient and his friends that the object of the operation is to ameliorate his sufferings, and not to restore the sight. The iridectomy should always be of a large size. In cases of glaucomatous degeneration it may also be necessary to employ it for the same purpose. Should it prove unable to arrest the inflammatory exacerbations, should it be followed by

extensive hæmorrhages, or should these occur spontaneously, and all sight is lost, the question may arise whether it would not be better to remove the eye altogether; for there may be a fear of the other eye sympathizing.

I have endeavoured to point out as plainly and simply as possible, the facts which should guide us in forming a prognosis of the beneficial effects to be expected from iridectomy. Nor have I made any statement the accuracy of which I have not myself frequently tested. This part of the subject demands the most earnest attention, as too slight a regard for the different facts which should influence our prognosis of the effect of iridectomy in glaucoma, has been one of the chief reasons why this operation has proved unsuccessful in the hands of some practitioners.

How iridectomy diminishes the abnormally increased intra-ocular pressure in glaucoma has not yet been decided. That it does in the vast majority of cases permanently relieve the tension is, however, an undoubted and incontrovertible fact. Various theories have been advanced in order to explain the *modus operandi*. Amongst other hypotheses, some have thought that the tension was diminished by the excision of a considerable portion of the secreting (iris) surface; others, that the removal of the iris quite up to its ciliary insertion, and the consequent exposure of the zonula Zinnii, facilitates the interchange of fluid between the vitreous and aqueous humours, and thus diminishes the difference in the degree of tension between these humours. We must admit, however, that this problem has not at present been satisfactorily solved. Now some opponents of the operation apparently reject it, because the solution of the *modus operandi* has not yet been found. They would rather deprive their hapless patients of the benefits of iridectomy, which would, in all probability, either restore or preserve vision; they would rather permit them to lose their sight, than perform an operation the effect of which in diminishing tension, though fully proved, they cannot at present satisfactorily explain.

Some writers have stated that the operation of iridectomy, as it is to be performed in glaucoma, is just the same as the old operation for artificial pupil. Nothing could be more erroneous. The principle of the two operations is perfectly different. In the old operation, an opening was made in the cornea, and a small portion of iris, in proportion to the desired size of the pupil, excised. In the modern operation of iridectomy for glaucoma, the chief point is to make the incision in the sclerotic, or at the sclero-corneal junction, and of a sufficient extent to permit the removal of a large segment of the iris (about one-fifth) quite up to its ciliary attachment. The more intense the symptoms, the more considerable the increase in the intra-ocular tension, the larger should the iridectomy be. Many of the negative,

or only partially successful, results which have followed the employment of iridectomy in glaucoma, were undoubtedly often due to some fault in the performance of the operation. Either too small a portion of the iris was excised, or it was not removed quite up to its ciliary attachment. We sometimes find that if only a small portion is removed, and this not up to the ciliary insertion, the symptoms do not completely yield, and more or less increase of tension remains. If, in such a case, a second and larger iridectomy is made, and the iris removed quite up to its ciliary attachment, the beneficial effects at once become apparent, the tension diminishes, the inflammation subsides, and the vision improves. The iridectomy should be made upwards, for the upper lid generally covers the greater portion of the artificial pupil, and thus not only hides the slight deformity, but also cuts off much of the irregularly refracted light. But this operation is somewhat more difficult than that in the horizontal direction, and consequently the beginner will do well, at first to perform the operation outwards or inwards. For a full description of the mode of performing iridectomy, I must refer the reader to p. 172.

In those cases of fully-developed glaucoma, in which iridectomy has only been able to preserve a certain amount of sight, considerable benefit is often experienced from the application of the artificial leech to the temple some months afterwards.

I must in conclusion call attention to certain disadvantages which may ensue upon iridectomy, but these are slight indeed when compared with the inestimable boon which the operation affords in this disease.

In the first stages of acute glaucoma, the operation upon one eye may accelerate the outbreak of the disease in the other, even although the latter may have been quite sound. The patient should therefore be warned of such an eventuality, but it should not cause us to postpone or shrink from the operation, as we know how dangerous any delay is in acute glaucoma.

Again, some surgeons have thought that iridectomy may cause a rapid development of cataract. But this is not so, for wherever shortly after iridectomy a cataract is formed in a previously healthy lens, this must be considered as due to a solution of continuity of the capsule (generally by the point of the knife). As the anterior chamber is very shallow in glaucoma, and the pupil often widely dilated, the extract of Calabar bean should be applied shortly before the operation, in order that the pupil may become greatly contracted, and the lens be covered. Or, Von Graefe's narrow cataract knife may be used instead of the lance-shaped iridectomy knife, for with it we can skirt the margin of the anterior chamber, and yet obtain a very large and peripheral incision. We cannot, however, regulate the escape of the aqueous

humour so well with this instrument as with the iridectomy knife; and a sudden, forcible discharge of the aqueous, may not only give rise to severe intra-ocular hæmorrhage, but also to a spontaneous rupture of the capsule and a subsequent cataract.

Although the section as a rule heals perfectly, without leaving any or but the slightest trace behind, we occasionally meet with instances in which this is not the case, the lips of the incision being separated by a web of cicatricial fibres, which show a tendency to bulge out, owing to the intra-ocular pressure, in the form of small vesicular or bead-like elevations. Indeed the cicatrix may even give way repeatedly, and the aqueous humour escape under the conjunctiva. Von Graefe terms this peculiar mode of union of the incision "*cystoid cicatrix*." It occurs chiefly in those cases in which there has been considerable and marked increase of tension for some time before the operation, also where glaucomatous excavation has supervened upon sclerectasia posterior; and finally, according to Bowman, if the tension remains somewhat in excess after the iridectomy. Von Graefe, on the contrary, has found the tension of eyes with the cystoid cicatrix rather less than normal.

If a tendency to this form of cicatrization shows itself, a compressive bandage should be at once applied, and continued for several days or even longer, being afterwards, if necessary, periodically repeated. If the bulge is considerable, it should be pricked with the point of the narrow knife, or a broad needle, so as to allow the aqueous humour to escape, and the collapsed membrane is then to be snipped off with a pair of scissors. Mr. Bowman advises that it should be repeatedly pricked with a broad needle. It is not safe to touch it with caustic, as this might set up serious irritation.

Chapter XIII.

THE ANOMALIES OF REFRACTION AND ACCOMMODATION OF THE EYE.

1.—THE REFRACTION AND ACCOMMODATION OF THE EYE.

The affections of the refraction and accommodation of the eye are daily assuming more importance, and are engaging more and more the attention of some of our most able and scientific ophthalmologists. For it is now known that certain forms of asthenopia and amblyopia which had in former times set all remedies at defiance, are not due, as was generally supposed, to serious lesions of the inner tunics of the eyeball, but are in reality dependent upon some anomaly of the refraction of the eye, or a peculiar asymmetry of the organ (astigmatism). Since the discovery of these important facts a considerable group of cases has been found to be amenable to treatment; cases which had formerly sorely puzzled the oculist, and were by him but too often deemed incurable.

The greater the strides which have been made in the investigation of the affections of the refraction and accommodation, the more evident has it become how essentially necessary it is that they should be thoroughly and carefully studied, and scientifically treated. I would therefore impress upon the student the fact that, after he has made himself conversant with the theoretical portion of the subject, it is only by a practical and oft-repeated examination of a considerable number of cases, that he can acquire the requisite facility in the examination of the state of refraction and of the range of accommodation, or in the choice of spectacles. To those who may consider these subjects as somewhat abstruse and difficult, I would reply, that the difficulties lie only on the surface, and that a little perseverance and practice will soon enable them to unravel the knotty points.

Before we enter upon the subject of the refraction and accommodation of the eye, we must very briefly consider the properties of optical lenses. For spectacles, the spherical biconvex and biconcave lenses are almost solely used, and I shall therefore confine myself to their description. In the article upon astigmatism, the properties of cylindrical lenses will be explained.

The biconvex lens is formed by the apposition of a segment of two spheres, the radii of curvature of the two surfaces being equal. Such lenses are often also termed *converging* lenses, as they possess the power of deflecting a ray of light, passing through them, towards the axis. The line drawn through the centre of the lens (Fig 56, c) is termed the axis, and any ray passing through it (axial ray) is not deflected.

(1.) If parallel rays (from a luminous object at an infinite distance)* fall upon a biconvex lens, they are united at a certain point behind the lens, and this point is called the *principal focus* (or simply the focus) of the lens. The distance of this point from the optic centre of the lens (which equals the radius of curvature of the lens), is termed the focal length of the lens. Thus, if in Fig. 56 *l* is a biconvex lens of 6 inches focus, parallel rays (*r r*) will be united at *f*, 6 inches behind the lens. (2.) If the object be now brought closer to the lens to *r'*, so that the rays emanating from it assume a divergent direction, they will be brought to a focus at *f'*, lying at some distance behind the principal focus (*f*) of the lens. (3.) If the object is situated at twice the focal

Fig. 56.

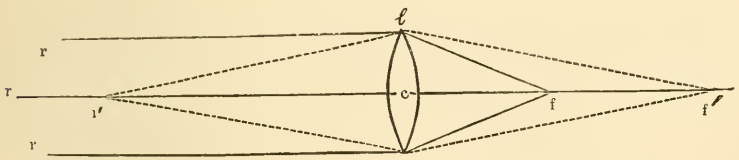

length of the lens, the rays from it will be united at a point placed twice the focal length behind the lens, and hence the distance of the

* As the term infinite distance will necessarily be of frequent occurrence in these pages, it will be well to explain its signification at the outset. We consider an object to be at a finite distance, as long as rays emanating from it fall in a divergent direction upon the eye. Of course rays, even from a very distant object, do in reality diverge, but this divergence (which naturally decreases in extent the further the object is removed), is already so slight when the object is placed at a distance of 18 or 20 feet, that the rays from it impinge, to all intents and purposes, parallel upon the eye. We therefore consider rays coming from an object situated further than 18 feet as parallel, and as emanating from an object at an *infinite* distance. Rays coming from a nearer object are divergent in proportion to its proximity, and are considered as coming from a *finite* distance.

object and of its focus from the lens will be the same. (4.) If the object be placed at the principal anterior focal point, *i.e.*, 6″ in front of the lens (Fig. 57 *f'*), the rays will emerge from the lens parallel to its axis *r r*. (5.) If the object is placed *inside* the principal focus (Fig. 57, *r'*) the rays from it will be so divergent that the lens will not be

Fig. 57.

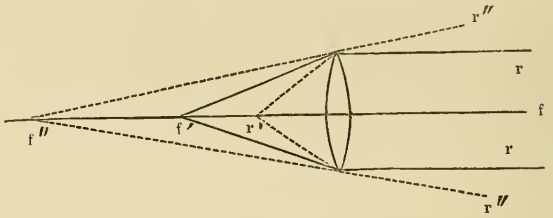

able to render them even parallel, and they will therefore emerge from it still somewhat divergent. This divergence will of course be less than before they entered the lens, and if the rays (*r″ r‴*) are prolonged back to the point at which they would cut each other, this point would lie at *f″*, being situated further from the lens than the object *r'*. The focus (*f″*) of these rays is therefore imaginary, and situated on the same side of the lens as the object. (6.) If convergent rays (rendered so by some other lens) fall upon the lens, they will be brought to a focus on the other side of the lens, at a point lying nearer than the principal focus.

It has been shown above, that the further the object, from which divergent rays fall upon the lens, is removed from the latter, the nearer will the focus of such rays approach the principal focus of the lens; whereas the closer the object is brought (provided that it remain further off than the principal focus) the more will its focus recede from the lens. On account of this dependence of these two points (the position of the object and its focus) upon each other, they are termed *conjugate foci*. Moreover, if the position of the object and its focus were changed, so that the object were placed at *f'* (Fig. 56), the rays from it would be brought to a focus on the other side of the lens at *r'*, the point where the object was situated before; hence *f'* and *r'* are *conjugate foci*. Again, if the object be placed at *f*, its rays will emerge parallel from the lens.

Hitherto we have only spoken of the refraction of rays which are parallel to the axis of the lens, and whose focus is situated upon the axis. We must now consider the focus of rays, the axes of which pass through the centre of the lens, but which are inclined to the axis. Such are termed *secondary axes*. The inclination must not, however, be too considerable, otherwise the rays will not be brought to an exact

focus, on account of the great spherical aberration which occurs. Thus in Fig. 58, let $A\ B$ be the principal axis of a lens, r a luminous point situated on this axis, and f the focus at which the rays from r are united. Now let r' be another luminous point situated at the same distance from the lens as r, but not on the principal axis, but at a certain inclination

Fig. 58.

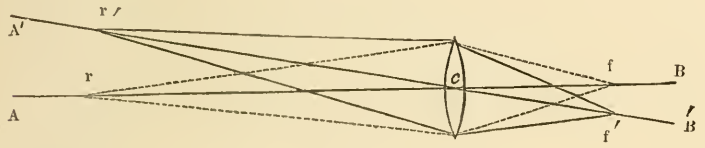

towards it. The secondary axis $A'\ B'$ will pass straight through the centre (c) of the lens without undergoing any deflection, and the rays from r' will be brought to a focus at f', which will be situated on the secondary axis $A'\ B'$, at the same distance behind the lens as f. Just as f is the conjugate focus of r, will f' be the conjugate focus of r'.

We shall now be able to understand the manner in which a biconvex lens forms an image of any luminous object situated in front of it. Let $A\ B\ C$ (Fig. 59) be an object situated in front of the lens. The rays

Fig. 59.

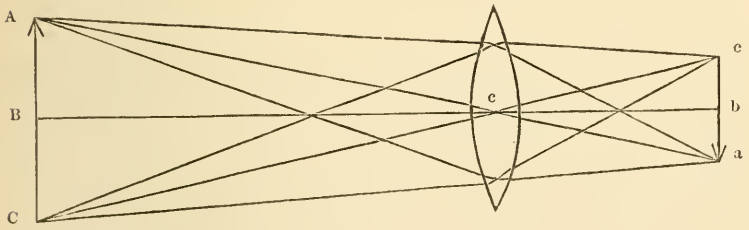

emanating from A will be focused at a point a situated on the secondary axis, drawn from A through the centre c of the lens; a is consequently the image of A; in the same manner c is the image of C, and the rays from B, situated on the principal axis of the lens, are united at b, likewise placed on this axis, hence b is the image of B. A reverse and smaller image of the object $A\ B\ C$ is therefore formed behind the lens at $a\ b\ c$. The rays which pass through the centre c of the lens are not deflected; and $a\ b\ c$ are the conjugate foci of $A\ B\ C$. The distance $C\ B$ and $c\ b$ is also conjugate, for if the object be placed at $a\ b\ c$, its inverted and enlarged image would be formed at $A\ B\ C$.

Now the size of the image formed by the lens will depend upon the distance at which the object is situated. (1.) If the latter is placed at an

infinite distance, the smallest inverted image will be formed behind the lens at its principal focus. (2.) If the object be approximated so as to lie at double the focal length of the lens, its inverted image will be situated at double the focal length behind the lens, and be the same size as the object. (3.) If the object be brought still closer, but yet further than the anterior focus, the inverted image will move further away from the lens and be larger than the object. (4.) If the latter be placed at the anterior focus no real image will be formed, for the rays will issue from the lens in a parallel direction. (5.) If the object is placed inside the focal length, the rays will still issue in a divergent direction from the lens, and the latter will act as a magnifying glass, the image will not be inverted and situated behind the lens, but will be erect, magnified, and situated in front of the lens., *i.e.*, on the same side as the object. Fig. 60 will explain this. If *A B* be an object situated

Fig. 60.

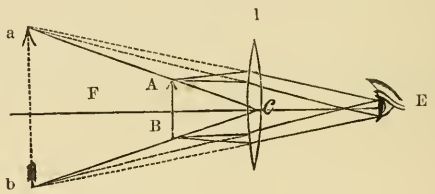

closer to the lens *l* than its anterior focus *F*, the rays from *A* will still diverge after their passage through the lens, and in such a direction as if they came from *a*, and the rays from *B* will diverge as if they came from *b*. If the eye *E* is placed on the other side of the lens, it will see instead of the object *A B*, its magnified, erect image, *a b*.

This magnifying power of the lens will be greater according to the shortness of its focal length, thus a 4-inch lens magnifies more than a 5-inch, and the latter more than a 6-inch lens. In order therefore to give the correct magnifying power, and to demonstrate at once that a 6-inch lens magnifies less than a 5-inch, we designate the magnifying power of a lens by fractions, the numerators of which are one, the denominators, the focal length of the lens. Thus one-fourth is stronger than one-fifth, the latter fraction being less than the former. Moreover, this way of expressing the strength of the lens is also correct, as indicating its power of refraction, for a lens of one-fifth will deflect rays of light impinging upon it more than a lens of one-tenth.

If parallel rays fall upon a biconvex lens, they are united into a real focus behind the lens. It is different, however, with a biconcave

or "diverging" lens, for this does not unite parallel rays, but renders them divergent. Thus (1), if parallel rays (Fig. 61, *r r*) fall upon a concave lens they will be rendered divergent, assuming a direction as if

Fig. 61.

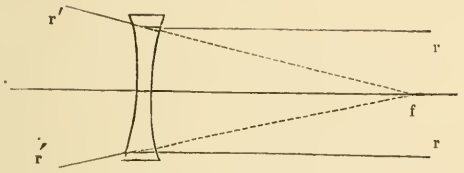

they had proceeded from *f*, in which the prolongation backwards of the divergent rays *r r* would cut one another, hence this point is called the negative virtual focus of the lens, and is an imaginary one, being situated upon the same side as the object. The distance of this point for parallel rays from the lens, gives the focal distance of the lens. Thus a concave lens of 10 inches focus, renders parallel rays so divergent, as if they came from a distance of 10 inches in front of the lens. (2.) If the object is brought closer to the lens, so that the rays emanating from it will diverge, they will be rendered still more divergent by the concave lens, and their focus will lie closer to the lens than its principal imaginary focus.

We have now to consider the manner in which the eye receives upon the retina a clear and sharply-defined image of an object placed in front of it.

We may regard the eye as a camera-obscura, upon the screen (retina) of which is formed a diminished and inverted image of the object. The impression of the object will be formed upon the bacillar layer (rods and cones) of the retina, be conveyed thence through the fibres of the optic nerve to the brain, be there received, and then projected back again in an inverted direction outwards to the object. The most sensitive portion of the retina being situated at the yellow spot, this point is always directed towards any object at which we are looking. The sensibility of the retina, which diminishes rapidly from the yellow spot towards the periphery, may be excited by the undulations of rays of light, or by mechanical means. The former excitation occurs when rays, emanating from a luminous object, impinge upon the retina; the latter, when the eyeball is slightly pressed by the point of the finger, which will produce the appearance of luminous rings (phosphènes), situated apparently in a direction opposite to that of the pressure. Thus, if the outer portion of the sclerotic be pressed upon, the luminous ring will appear at the nasal side, and *vice versâ*.

The refractive power of the normal, emmetropic eye is such, that rays which emanate from a distant object, and impinge in a parallel direction upon the cornea are brought to an exact focus upon the retina, and the eye receives a distinct image of such an object. The dioptric system of the eye which causes this refraction of the rays of light, consists of certain media, which, taken conjointly, act as a biconvex lens. These refractive media are the cornea, aqueous humour, crystalline lens, and vitreous humour. On account of the slight thickness of the cornea, the parallelism of its two surfaces, and the fact that the refracting power of the cornea and aqueous humour are nearly equal, we may assume that the two form only one refracting surface. The index of the refraction of the vitreous humour is almost the same as that of the aqueous. But the refraction of the cornea and of the aqueous and vitreous humours would not suffice to bring parallel rays to a focus upon the retina in an emmetropic eye, for the focus would lie considerably behind it, and the lens is required to render the rays sufficiently convergent. The axis of the dioptric system is called the *optic axis*, the anterior extremity of which corresponds to the centre or apex of the cornea, and the posterior extremity to a point situated between the yellow spot, and the entrance of the optic nerve. By the term *visual line* is meant the line of direction drawn straight from the object (through the nodal point) to its image formed at the yellow spot. It was formerly supposed that the optic axis and visual line were identical, but this is not so, for according to Helmholtz,* the visual line outside the eye lies somewhat above and to the inner side of the optic axis, and its posterior extremity on the retina consequently lies a little to the outer and lower side of the axis. This fact will be found of practical importance with regard to the question of real and apparent strabismus.

If we now apply to the eye, the principles laid down above as to the properties of biconvex lenses, we can easily understand the mode in which the reverse image of an object is formed upon the retina. Thus, if *A B C* (Fig. 62) be an object placed at the proper distance from the

Fig. 62.

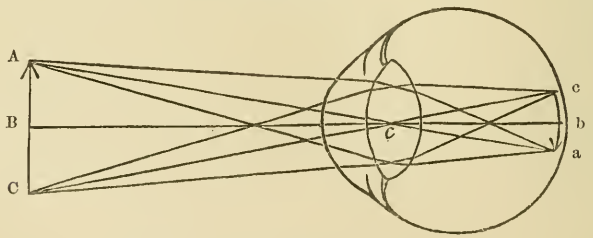

* Helmholtz's Physiologische Optik., p. 70.

eye, a distinct inverted image of it will be formed upon the retina at *a b c*. Let *B b* be the axial ray passing through the nodal point to the retina. Through this nodal point draw a straight line from *A* to *a*. This line *A a* will be a secondary optic axis, and all the rays emanating from *A* will be focused upon the retina at *a*. The straight line *C c*, passing through the nodal point, will be another secondary optic axis, and all the rays from *C* will be united upon the retina at *c*. Hence *a b c* will be the inverted diminished image of *A B C*.

Now the question, whether or not the rays from the object will be brought to a focus upon the retina, and the latter thus receive a clearly-defined image, will depend upon the situation of the object, and the distance for which the dioptric system of the eye is accommodated. The same principles as were laid down with respect to biconvex lenses apply to this case. Thus, if an eye is adjusted for parallel rays, these will be brought to a focus upon the retina. If the object is now brought nearer to the eye, so that its rays become divergent, they will no longer be united upon the retina, but behind it. The eye will consequently not receive a clearly-defined image, but the latter will be blurred and indistinct, on account of the "circles of diffusion" formed upon the retina. As the focus of the rays lies behind the retina, each luminous point from the object is no longer presented by a point upon the retina, but by a circle (the section of each conical pencil of rays), and as these circles overlap each other, the image is rendered indistinct. These are called circles of diffusion, and take the form of the pupil, consequently their size diminishes with that of the pupil, and *vice versâ*.

For the more exact calculation of the passage of rays of light through the eye, Listing constructed a diagrammatic eye (Fig. 63) having six cardinal points, corresponding to those of optical lenses and situated on the optic axis. 1. The focus *F'* (Fig. 63) situated upon the retina, in which rays falling parallel upon the cornea would be

Fig. 63.

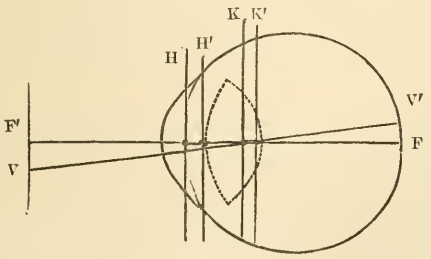

united. 2. The anterior focus *F''*, at which rays coming from the retina, and whose course is parallel in the vitreous humour, would be

brought to a focus. 3. The two "principal points" *H H'* which lie on the optic axis in the anterior chamber close behind the cornea (in Fig. 63 these two points lie somewhat too far from the cornea). 4. The two "nodal points" *K K'*, in which the lines of direction cut each other, and which near the posterior surface of the lens.

On account of the extremely small distance (less than $\frac{1}{4}$ of a millimetre) between the two principal points and the two nodal points, this diagrammatic eye may be simplified, and these four cardinal points be reduced to two, viz., a principal point situated in the anterior chamber, and a nodal point, situated somewhat in front of the posterior surface of the lens. The two focal points remain the same. For the method of calculating the course of the rays of light according to the cardinal points, I must refer the reader to Helmholtz's Physiologische Optik, and Donders' work on the Anomalies of Refraction and Accommodation.

A glance at Fig. 63 will also explain the relative positions of the optic axis (*F F'*) and of the visual line (*V V'*). The latter is an imaginary line drawn from the yellow spot to the object point. They were formerly supposed to be identical, but Helmholtz has found that this is not the case, but that in front of the eye the visual line lies inwards and generally somewhat upwards of the optic axis, its posterior (retinal) extremity consequently lying to the outer side of the optic axis and slightly below it. Thus in Fig. 63 (which represents a horizontal section of the diagrammatic eye, the upper side of the figure being the temporal, the lower the nasal side) *V V'* is the visual line and *F' F'* the optic axis. At the cornea, the former lies to the inner side, at the retina, to the outer side of the optic axis. At the nodal point *K* they cross each other.

In the normal or emmetropic eye the visual line impinges upon the cornea slightly to the inner side of the optic axis, forming with it an angle of about 5°. But Donders has shown that in the hypermetropic eye it lies still more to the inner side, so as to form an angle of 8° or 9°, whereas in myopia the visual line may correspond to the optic axis, or even lie to the outer side of it. These differences in the relation between the optic axis and visual line often give rise to an apparent strabismus.

The Visual Angle.—The apparent size of an object depends upon the size of its retinal image. If, for instance, the eye is adjusted for the object *A B* (Fig. 64) and the lines of direction, *A A'* and *B B'*, are drawn through the nodal point *k*, the angle *A k B* will be the visual angle under which the object is seen, and this angle will equal the angle *A' k B'*. The visual angle stands in direct relation to the size of the object, for the larger the latter is, the greater will be the visual angle, and consequently the image, and *vice versâ*. Moreover, the visual angle will

also increase in size according to the proximity of the object, and diminish as the latter is further removed from the eye. If, however,

Fig. 64.

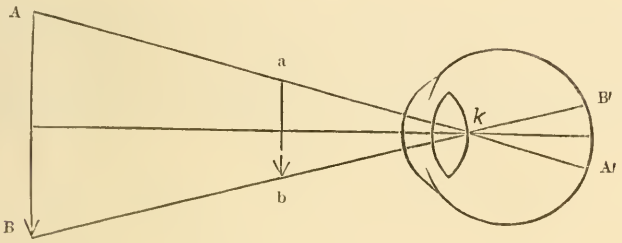

the size of the object increases in due proportion with its distance, it will be seen under the same visual angle. Thus *A B* (Fig. 64) and *a b* are seen under the same visual angle, although the former is considerably further from the eye than *a b*. From this it will be easily understood, that the mere fact of a patient being able to read the smallest print does not exclude a certain degree of amblyopia. In deciding upon this point, we must always take into consideration the distance at which he can read it, and the state of refraction and accommodation.

The smallest visual angle under which an object can be distinctly seen by the eye is one of 5°. Hence this has been taken as the standard for determining the acuteness of vision, and the test types of Snellen and Giraud Teulon have been devised upon this principle, as has been already stated (p. 4), each type being seen under an angle of 5° at the distance in feet corresponding to its number. Thus No. 1 is seen at an angle of 5 minutes at 1 foot, No. 2 at 2 feet, etc.

We have now to turn our attention to the nearer consideration of the subject of refraction and accommodation.

By the term "accommodation" is meant the power which every normal eye possesses of adjusting itself almost imperceptibly and unconsciously for different distances. At one moment, looking at something but a few inches from the eye, at the next, regarding some far distant object, or taking in at a glance the vast expanse of miles of scenery.

In a normal eye the whole apparatus of accommodation is so beautifully balanced, and its functions are performed with such ease and accuracy, that, although in reality a voluntary act, its duties are from early childhood fulfilled intuitively, unconsciously. No wonder, then, that this power of adjustment of the eye to different distances has been a favourite study with some of the most eminent physiologists and natural philosophers.

That such a power is essentially necessary will become at once apparent by a consideration of the following fact, and a glance at Fig. 65.

It has been already stated that the emmetropic eye in a state of rest is adjusted for parallel rays *a a*, so that these are brought to a focus upon the retina *b*, without any effort of the accommodation. But if the object is now brought to *c* (12″* from the eye) the rays will be very divergent, and will be focused behind the retina at *d*, unless the

Fig. 65.

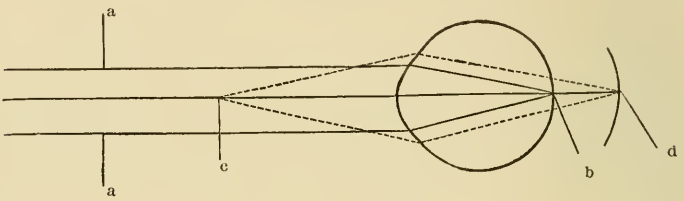

eye can increase its power of refraction sufficiently to unite them upon the retina. If not, circles of diffusion will be formed upon the latter, and the object consequently appear blurred and indistinct. If the accommodation of the eye is paralysed, rays from the object *c*, 12″ in front of the eye, would be brought to a focus upon the retina by the aid of a bi-convex lens of 12 inches focus, which would render the rays parallel and thus enable the eye to focus them upon the retina.

It is very necessary carefully to distinguish between the meaning of the terms refraction and accommodation, as they signify two perfectly different things. By refraction is understood, the passive power which every eye possesses, when in a state of rest,—*i.e.*, adjusted for its far point—of bringing certain rays to a focus upon the retina without any active effort or participation of the muscular apparatus of accommodation. This power of refraction is due to the form of the eye and its different refracting media.

We have just seen (Fig. 65) that the state of refraction of the normal eye is such that, when it is in a state of rest, parallel rays are brought to a focus upon the retina without any effort of the accommodation. Its furthest point of distinct vision lies at an infinite distance. Donders terms this condition emmetropia. He says,† "the refraction of the media of the eye at rest can be called normal in reference to the situa-

* I may remind the reader of the signification of the following expressions: *A*, means range of accommodation; *r*, far point; *p*, near point; ∞ (= 0), infinite distance; ′, foot; ″, inch; ‴, line.

† Donders "On the Anomalies of Accommodation and Refraction of the Eye," p. 81. New Sydenham Society, 1864.

tion of the retina, only when parallel incident rays unite on the layer of rods and bulbs. Then, in fact, the limit lies precisely at the measure; then there exists emmetropia (from ἔμμετρος, modum tenens, and ὤψ, oculus). Such an eye we term emmetropic.

"This name expresses perfectly what we mean. The eye cannot be called a *normal* eye, for it may very easily be abnormal or morbid, and nevertheless it may be emmetropic. Neither is the expression *normally constructed eye* quite correct, for the structure of an emmetropic eye may, in many respects, be abnormal, and emmetropia may exist with difference of structure. Hence the word emmetropia appears alone to express with precision and accuracy the condition alluded to."

The state of refraction may deviate in two ways from the emmetropic condition.

1. The principal focus of the eye, when adjusted for its far point, lies in front of the retina (Fig. 66), so that parallel rays are not brought to a focus upon the latter, but in front of it *f*, and circles of diffusion, *b b*, will be formed, only sufficiently divergent rays being united upon the retina. This condition is termed myopia; also brachymetropia (βραχὺς

Fig. 66.

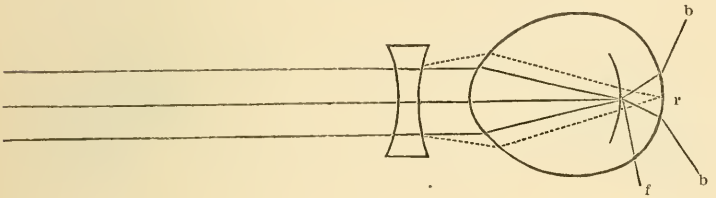

brevis, μέτρον, modus, ὤψ, oculus, the limit lies within the measure), and depends upon the eyeball being too long, or the state of refraction too high. A suitable concave lens will be required to unite the parallel rays upon the retina (Fig. 66).

2. The principal focus may lie behind the retina, so that when the eye is in a state of rest, parallel rays are brought to a focus behind the retina (*r*, Fig. 67) at the point *f*. Circles of diffusion *b b* are formed, and the

Fig. 67.

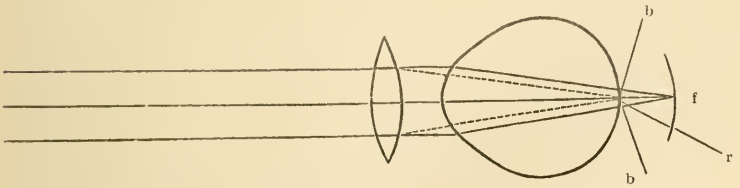

object looks indistinct. This condition is termed hypermetropia (*ὑπὲρ*, super, *μέτρον*, modus, *ὤψ*, oculus, the limit lies beyond the measure). To remedy this indistinctness of the image, the eye undergoes a change in its accommodation, so as to increase its power of refraction, and render the parallel rays sufficiently convergent to be united upon the retina. The same effect may be produced by placing a suitable convex lens before the eye.

In order to express that the eye is not emmetropic, Donders proposes the term *ametropia* (from *ἄμετρος*, extra modum, and *ὤψ*, oculus); and he observes that brachymetropia and hypermetropia are both, therefore, referrible to it. Formerly presbyopia and myopia were supposed to be opposite conditions. This is, however, erroneous. In myopia there is an abnormal position of the far point, whereas in presbyopia the position of the far point is normal, but that of the near point is changed, being removed further from the eye. Indeed presbyopia and myopia may co-exist. Presbyopia is not, therefore, an anomaly of refraction, but a diminution in the range of accommodation.

It has long been a keenly debated question in what the changes of accommodation of the eye consist, and various opinions have been advanced. Some have thought that the cornea undergoes some alteration during accommodation for near objects, so that its power of refraction is increased, and the eye enabled to adjust itself for reading, writing, &c.; but apart from other reasons against this theory, Helmholtz has shown, with his ophthalmometer, that there is no alteration in the curvature of the cornea during accommodation. Others have supposed that the muscles of the eyeball play an important part in bringing about, in conjunction with the ciliary muscle, the adjustment for near objects. But that this is not the case has been incontrovertibly proved by a case of Von Graefe's, in which all the recti and obliqui muscles of both eyes were paralysed, so that the eyeballs were completely immoveable, and yet the power of accommodation was perfect.

It has at length, however, been definitely settled, chiefly by the experiments of Cramer and Helmholtz (conducted independently of each other), that the necessary change in the refraction of the eye during accommodation is due to an alteration in the form of the crystalline lens. Helmholtz found, by means of his ophthalmometer, that the lens did not change its position during accommodation for near objects, but that this was brought about by a change in the curvature of the anterior and posterior surfaces of the lens, which become more convex (the lens itself thicker from before backwards), so that the lens acquires a higher power of refraction, and consequently a less focal distance, by which means rays from even very near objects are brought to a focus upon the retina. He found, with the ophthalmometer, that

the eye undergoes the following changes during accommodation for near objects :—

1. The pupil diminishes in size. 2. The pupillary edge of the iris moves forwards. 3. The peripheral portion of iris moves backwards. 4. The anterior surface of the lens becomes more convex (arched), and its vertex moves forwards. 5. The posterior surface of the lens also becomes slightly more arched, but does not perceptibly change its position. The lens, therefore, becomes thicker in the centre.*

As the volume of the lens must remain the same, he thinks that we may, moreover, assume that the transverse diameter of the lens becomes diminished. He finds, from calculation, that these changes in the lens are quite sufficient for all accommodative purposes.†

Fig. 68 illustrates the changes which the eye undergoes during accommodation. The anterior portion of the eye is divided into two

Fig. 68.

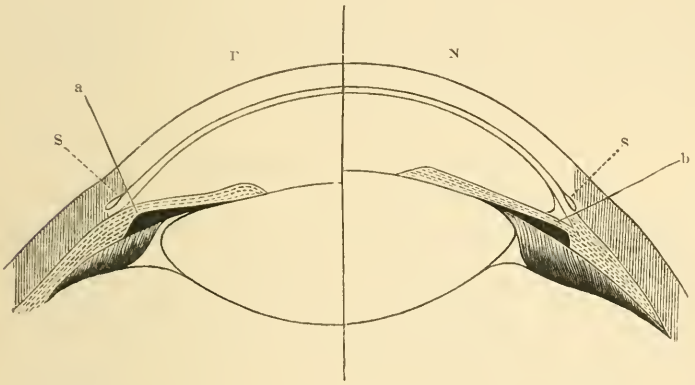

equal parts. The one half, F, shows the position of the parts when the eye is adjusted for distance, the other, N, when it is accommodated for near objects. When the eye is in a state of rest, the iris forms a curve

* Otto Becker has found that in albinotic eyes the space between the ciliary processes and the edge of the lens, becomes increased in size during accommodation for near objects. He thinks it probable that the volume of the ciliary processes varies in the different conditions of the accommodation, and supposes that this is due to the difference in the blood supply to the iris, which he thinks varies with the dilatation and contraction of the pupil.

† It was found, with the ophthalmometer, that the position of the reflection images of a candle, produced by the cornea and the anterior and posterior surfaces of the lens, underwent a change during accommodation for near objects. Whilst the reflex image from the cornea remained unchanged, that from the anterior surface of the lens approached the corneal image and diminished in size; the image from the posterior surface of the lens also diminished very slightly in size, but underwent no appreciable change of position.

(*a*) in the vicinity of Schlemm's canal (*s*); but when accommodated for near objects, the fibres of the iris suffer contraction, the periphery of the iris becomes straightened (*b*), and the anterior chamber lengthened, so that its diminution in depth is compensated for by the advance of the anterior surface of the lens.

The question now arises in what manner is this change in the form of the lens produced? There can be no doubt now that it is entirely due to the action of the ciliary muscle. Cramer, Donders, Helmholtz, Müller, as well as many other observers, considered that whilst the ciliary muscle played the most important part in the mechanism of the accommodation, it was materially assisted by the iris. Indeed it was impossible to determine with accuracy, even after the most careful dissections and most elaborate investigations, the relative amount of importance of the iris and ciliary muscle. This question has now, however, been definitely set at rest by a case which occurred in Von Graefe's clinique, in which, together with a total absence of the iris (the latter was removed after an accident) the power of accommodation remained perfect. Moreover, on the application of a strong solution of atropine it became completely paralysed.

2.—NEGATIVE ACCOMMODATION.

Some ophthalmologists of eminence, more especially Von Graefe and Weber, have thought that when the emmetropic eye is in a state of rest, it is not quite adjusted for its furthest point of distinct vision, but can become so by a slight alteration in its accommodation, which may be called the *negative* accommodation, in contradistinction to the *positive* which enables it to adjust itself for near objects. Von Graefe has thought that, by the aid chiefly of the external muscles of the eyeball which exert a slight pressure upon the eye, and thus somewhat flatten the cornea, the refraction of the eye is slightly diminished, and the far point removed still further from the eye, than when the eye is in a state of absolute rest. Henke,* however, thinks that both the positive and the negative accommodation are produced by the action of the ciliary muscle. The former being due to the action of its circular fibres, the latter to that of its radial fibres.

The chief argument against the theory that the eye accommodates itself actively for distant objects is furnished by the action of a strong solution of atropine, which completely paralyses the power of accommodation, but does not interfere with the distant vision of an emmetropic eye, and does not change the position of its far point.

* "A. f. O.," vi, 2, 53.

3.—THE RANGE OF ACCOMMODATION.

When the eye has assumed its highest state of refraction, it is accommodated for its nearest point of distinct vision; when its state of refraction is, on the other hand, relaxed to the utmost, it is adjusted for its furthest point.

But as the power of the ciliary muscle is limited, the accommodation for near objects must also be limited, and the near point cannot be approximated closer than a certain distance to the eye. In the youthful emmetropic eye it lies at about $3\frac{1}{2}$ to 4 inches from the eye, but recedes further and further with advancing age. The furthest point of distinct vision in the emmetropic eye lies at an infinite distance. The furthest point of distinct vision is expressed by the letter r (punctum remotissimum), the nearest point by p (punctum proximum). The distance between these two is called the range of accommodation. The extent of this range varies, of course, according to the strength and efficiency of the ciliary muscle, the elasticity of the lens, and the age of the patient. The distance of p from the eye (measured from the nodal point) is expressed by P, the distance of r from the eye by R. Now the range of accommodation can be easily found if we assume it to equal the focal length of a lens which would give to the rays emanating from an object placed at the nearest point (p) a direction as if they came from the furthest point (r). Let us suppose that the eye is emmetropic and accommodated for an object placed at its far point (parallel rays), if the object is now moved up to 5″ from the eye, and the latter does not exert its power of accommodation, the rays from the object will be brought to a focus behind the retina. In order to unite them upon the latter, a bi-convex lens must be placed before the eye, which shall render the rays coming from the object (placed at 5″) parallel, *i.e.*, give them the same direction as they had when the object was situated at an infinite distance. A 5-inch lens would be required for this purpose, for the rays from an object situated at its anterior focal length would issue parallel from the lens. If we now suppose this auxiliary lens placed within the eye, it represents the accommodation of the eye, and its power the range of accommodation, the latter would, therefore, in this case $= \frac{1}{5}$. The range of accommodation $\frac{1}{A}$ may be found by the formula $\frac{1}{A} = \frac{1}{P} - \frac{1}{R}$.

Let us illustrate this by a few examples :—

1. If the furthest point lies at an infinite distance, $R = \infty$, the nearest point at 6″ $P = 6''$, the range of accommodation will be

$\frac{1}{6}$, for $\frac{1}{6} - \frac{1}{\infty} = \frac{1}{6}$. The range of accommodation is here represented by an auxiliary lens of 6 inches focus.

2. If in a myopic eye, the far point lies at 8″ and the near point at 4″ from the eye, the range of accommodation will be $\frac{1}{8}$ for $\frac{1}{4} - \frac{1}{8} = \frac{1}{8}$.

3. If a presbyopic eye has its far point at an infinite distance, and its near point at 10″, the range of accommodation will be $\frac{1}{10}$ for $\frac{1}{10} - \frac{1}{\infty} = \frac{1}{10}$.

The following is also a very good method for testing the range of accommodation, and for quickly discovering whether the eye is emmetropic, myopic, or hypermetropic:—

A convex lens of 6″ or 10″ focus is placed before the eye.* With this lens the patient then reads No. 1 of Snellen, and his far and near point are noted. The far (r') and near point (p') thus found, stand in such relation to his real far (r) and near point (p), that the rays coming from r' are refracted by the lens as if they came from r, those from p' being also refracted as if they emanated from p. With convex 6, r' (in the normal eye) lies at 6″ from the eye, for rays from an object at 6″ distance falling on this lens, would be rendered parallel by it, and would, consequently, impinge upon the eye as if they came from an infinite distance (the normal far point). The near point (p') would lie at about $2\frac{2}{3}$″. This varies, however, with the age of the patient.

The range of accommodation is, therefore, easily found by the formula $\frac{1}{A} = \frac{1}{P} - \frac{1}{R}$. The lens and its distance from the eye (about $\frac{1}{2}$″) are omitted in the calculation.

If (with convex 6) the far point (r') lies at 6″, the near point (p') at 3″, $\frac{1}{A} = \frac{1}{3} - \frac{1}{6} = \frac{1}{6}$.

Let us illustrate this proceeding by the following examples:—

I. *Myopic eye.* We find that with convex 6 $r' = 5''$, $p' = 3''$. The eye is consequently myopic, for it is not adjusted for the normal far point (6″), but for a nearer one, the rays from which impinge in a divergent direction upon the eye:—$\frac{1}{A} = \frac{1}{3} - \frac{1}{5} = \frac{1}{7\frac{1}{2}}$.

* The lens must be strong, in order that the patient may really command his far point, and that the latter may be approximated so much that the minimum of the angle of distinction no longer exerts any influence, and amblyopia is therefore excluded.

Now, what glasses will this patient require for infinite distance? By means of our strong convex lens we have changed this eye into a very myopic one, in fact, into a myopia of $\frac{1}{5}$, for we should have to place a concave glass of 5″ focus before convex 6, in order to enable it to see at a distance; for this concave glass would render parallel rays so divergent as if they came from 5″ distance. In order to find the proper concave glass for distance, we deduct concave 5 from convex 6. Hence the proper concave glass will be No. 30 for $\frac{1}{6} - \frac{1}{5} = -\frac{1}{30}$.

II. *Hypermetropic eye.* With convex 6, $r' = 8$, $p' = 3''$. The eye is, therefore, hypermetropic, for its far point lies beyond the normal far point (6″).

Its range of accommodation $= \frac{1}{4\frac{4}{5}}$ for $\frac{1}{A} = \frac{1}{3} - \frac{1}{8} = \frac{1}{4\frac{4}{5}}$.

Above we have only spoken of the *absolute* range of accommodation which exists when each eye is tried separately. Donders* has, however, pointed out that we must distinguish two other kinds of ranges, viz., the *binocular* and the *relative*. The *binocular* comprises the accommodation from the furthest point r_2 to the nearest point p_2, when both eyes are tried together. The formula is $\frac{1}{A_2} = \frac{1}{P_2} - \frac{1}{R_2}$.

Although a certain connection exists between the accommodation and the convergence of the visual lines, yet this connection is not absolute and definite, for we find that the position of the visual lines may be changed, yet the accommodation remain the same; for if a prism of moderate strength be placed with its base outwards before one eye, the convergence of the visual lines will be greatly increased to overcome the diplopia, and yet the object can be distinctly seen at the same distance with both eyes. Again, the accommodation may be altered, and yet the state of convergence remain the same, for if we place weak concave or convex lenses before the eyes, an object can still be distinctly seen at a definite distance. This proves that the accommodation may be modified without any change of the convergence of the visual lines. These experiments show that there exists a certain independence between the convergence and the accommodation, and the range of accommodation over which we have control at a given convergence of the visual lines is termed the *relative* range, and is found by the formula $\frac{1}{A_1} = \frac{1}{P_1} - \frac{1}{R_1}$. It consists, moreover, of two parts, the *positive* and the *negative*. The positive being the part which is disposable for a distance closer than the point of convergence, whereas the negative is the portion which is required to see an object lying

* Op. cit., 110. Full explanations, with explanatory diagrams of this subject, will be found in Donders' work.

beyond the point of convergence of the visual lines. Now the relation between these two parts of the relative range of accommodation is of much practical importance, for it is found that, in order that the eyes may be employed comfortably for some length of time at near objects (reading, etc.), it is absolutely necessary that the positive part of the accommodation should bear a certain proportion to the negative (it should at the very least be equal to $\frac{1}{2}$).

The best objects for testing the range of accommodation are Snellen's test types or Von Graefe's wire optometer. But as the latter requires some exactitude and intelligence on the part of the patient, I find it more practical, especially with hospital patients, to use the test types. If whilst they are reading No. 1 we move the type a few times alternately nearer to and further from the eye, the nearest and furthest point of distinct vision can be readily ascertained. Von Graefe's optometer consists of a small square steel frame, across which a number of delicate, parallel, vertical wires are stretched. This frame may be attached to a brass rod (graduated in inches and feet) upon which it is moveable; or it may be fastened to a graduated tape. One end of the rod, or the bobbin of the tape is placed against the forehead of the patient, and the frame moved to the nearest point at which the individual wires still look clearly and sharply defined; the distance of this point from the eye is read off from the graduated scale, and put down as the near point (p). The frame is then removed to the greatest distance at which the individual wires still appear sharply defined, and this is noted as the far point (r). The distance between p and r gives the range of accommodation. The wires only appear sharply defined when the eye accommodates itself perfectly for them, directly there is the slightest deviation from this perfect accommodation (the frame being too far from or too near to the eye), the wires seem indistinct, thickened, or as if surrounded by a halo; or coloured double images of them may even appear in the transparent intervals. With the test types the examination is still easier, the nearest point at which No. 1 (Snellen) can be distinctly and comfortably read is measured and noted as the near point, and then the furthest point (in an emmetropic eye No. I of Snellen should be read up to 1′, No. xx up to 20′) is measured and noted.

4.—MYOPIA.

It has been already shown that in myopia parallel rays (emanating from an object at an infinite distance) are brought to a focus in front of the retina, and that only sufficiently divergent rays are united upon the latter. This is either due to the antero-posterior axis of the eyeball being too long, or to the refracting power of the eye being too

high. In order somewhat to improve their sight for distant objects, short-sighted persons nip their eyelids slightly together. They in this way diminish the size of the circles of diffusion by narrowing the palpebral aperture, and also render the eye slightly less myopic by the pressure which is thus exerted upon the eyeball.

The anterior chamber is generally somewhat deeper, and the pupil somewhat larger in the myopic than in the emmetropic eye. If the myopia is considerable in degree, the eyeball appears abnormally large and prominent, the lids are widely apart, and the lateral movements of the eye somewhat curtailed. The increase in the length of the eyeball, and the squarely ovoid shape of its posterior portion can be easily recognised when the eye is turned far inwards towards the nose, the little hollow which exists in the emmetropic eye between the outer canthus and the globe having disappeared.

Myopia is frequently congenital, and often hereditary, and its existence may also be sometimes traced back through several generations, increasing perhaps somewhat in degree in each successive generation. It may also occur in several members of the same family.

The most frequent cause of myopia is an abnormal increase in the length of the eyeball in its antero-posterior axis. This extension occurs chiefly at the posterior portion of the globe, and may give rise to a more or less considerable ovoid bulging (posterior staphyloma), which is accompanied by thinning and atrophy of the choroid and sclerotic (vide the article on Sclerotico-Choroiditis Posterior, p. 427). But even if this should not be present, the ophthalmoscope often reveals a hyperæmic and congested condition of the optic nerve and retina, especially if the eyes have been much overworked by artificial light.

It is also supposed by some, that long-continued work at near objects may produce myopia. For persons thus employed, continually accommodate for a very near point, their crystalline lens has, therefore, constantly to assume a more convex form, and after a time, it may not be able quite to regain its original form, even when the necessity for adjusting itself for near objects no longer exists. The eye has in fact become somewhat myopic.

The production and increase of myopia by continuous use of the eyes at near objects, appear to find their explanation chiefly in the fact that the inner tunics of the eyeball become congested. The near approach of the object necessitates a strong convergence of the optic axes, which causes an accumulation of blood in, and congestion of, the inner tunics of the eyeball, these conditions being increased still more by the stooping position generally indulged in during such employment. We can easily understand that this congestion and augmentation in the pressure of the ocular fluids must, if long continued, necessarily lead

to an extension of the tunics at the posterior pole, and thus give rise to posterior staphyloma.

The seeds of short-sightedness are frequently sown in childhood, either through a premature over-exertion of the eyes at near objects, or through some affection of the refractive media (the cornea or lens). The cornea may, for instance, be clouded, and then the patient often brings the object very close to the eye, in order to obtain larger and more distinct retinal images, and thus myopia may be soon induced. The same thing may occur when the lens is somewhat opaque; thus it is well known that lamellar cataract frequently becomes complicated with short sight.

There can be no doubt that the degree of myopia is often greatly increased during childhood by long continued study, more especially by insufficient illumination and a faulty construction of the tables or desks at which the pupils read and write. An insufficient illumination necessitates a close approximation of the object, which gives rise to straining of the accommodation and congestion of the eyes. A faulty construction of the tables, or of the distance between the latter and the seats, is also injurious by forcing the children to stoop. An interesting and valuable monograph has been written by Dr. Cohn* upon this subject. He examined the eyes of 10,060 school children, and could distinctly trace the increase in the proportion of the myopia according to the construction of the desks and the lighting of the school-rooms.

It was formerly supposed that increased convexity of the cornea was the cause of myopia, but this is erroneous, for Donders has found that the cornea is as a rule less convex in myopic persons than in the emmetropic. Increase of the curvature of the cornea (as in conical cornea) may, however, give rise to myopia. We sometimes also find that persons suffering from incipient cataract become somewhat myopic, and see better at a distance with concave glasses. The real explanation of this fact is still uncertain, but, it may perhaps be due to a slight swelling (?) of the lens, and a consequent increase in its power of refraction.

The diagnosis of myopia is generally a matter of no difficulty. The far point of distinct vision is more or less approximated to the eye, in consequence of which distant objects cannot be clearly distinguished, and a suitable concave lens is required to render them distinctly perceptible. We must be upon our guard, however, not at once to pronounce a person short-sighted because he holds small objects (such as small print) very close to the eye, or because he cannot see well at a distance, for we shall hereafter point out that this may also occur in hypermetropia, in which case convex and not concave glasses are required to remedy this defect.

* Dr. Cohn, Untersuchung der Augen von 10,060 Schulkindern. Leipsic, 1867.

Together with the myopia there is frequently present more or less amblyopia or weakness of sight. This is especially the case if there is a considerable degree of sclerotico-choroiditis posterior, and appears to be chiefly due to the stretching of the inner tunics of the eye, more especially of the light conducting elements of the retina. The impairment of sight may also be due to opacities in the vitreous humour or the lens. Myopic eyes are often very irritable, so that prolonged use in reading or writing causes them to become red, hot, and very painful. This may be partly due to irritability and congestion of the inner tunics, or it may be caused by a weakness of the internal recti muscles, which are not sufficiently strong to maintain the requisite degree of convergence. If this insufficiency is developed to a considerable degree, it gives rise to marked symptoms of asthenopia and fatigue of the eyes (vide the article on Muscular Asthenopia). We may easily distinguish simple myopia from that complicated with amblyopia, by the fact that the former can be completely corrected by suitable concave glasses. The less the concave glasses correct the myopia, the greater is the degree of the co-existing amblyopia, and *vice versâ*.

Ophthalmoscopic diagnosis of Myopia.—We may also recognise the existence of myopia, and ascertain its approximative degree, by means of the ophthalmoscope, and this will often be found very useful in practice, particularly when the patient's statements are not very trustworthy. We can diagnose the existence of myopia by the following appearances:—

I. If we examine a highly myopic eye in the erect image (that is merely with the mirror, without any convex lens before it), we are at once struck by the fact, that we can see the details of the fundus at some distance from the eye. If we regard one of the retinal vessels or the optic disc, and move our head slightly to one side, we notice that the image moves *in the contrary direction;* if we move to the right it moves to the left, and *vice versâ*, so that we obtain a reverse image of the background of the eye.

Fig. 69.

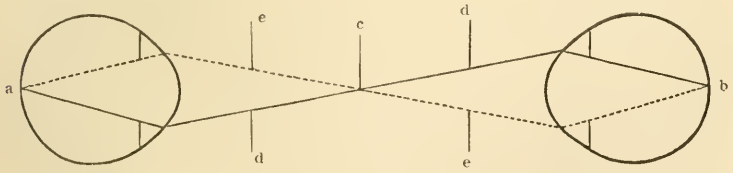

Fig. 69 will at once explain the reason of this. Let *a* be a very short-sighted eye ($m = \frac{1}{4}$), and *b* the eye of the observer: *a* being in a state of rest is adjusted for its far point (*c*), which lies 4″ in front of the eye. The rays from the fundus, therefore, pass out of the eye in a

strongly convergent direction, and meet at *c*, and, crossing there, fall in a divergent direction upon the eye of the observer. If the latter be myopic (accommodated for divergent rays when his eye is in a state of rest), they may be united upon his retina (*b*) without the aid of any correcting lens behind the ophthalmoscope. But if his eye is emmetropic he will, if adjusted for his far point, require a suitable convex lens behind the mirror, in order to render the divergent rays parallel. If he, however, accommodates himself for a sufficiently near point, he will be able to unite the divergent rays upon his retina without any correcting lens. The reversed image of the eye represented in Fig. 69 (the myopia of which $= \frac{1}{4}$) will be seen at a distance of about 7″—8″, because as the rays from it cross at *c*, the upper ray, *e*, becomes the lower ray after they have crossed, and the lower ray, *d*, becomes the upper.

II. In order to examine a myopic eye in the erect image, it will be necessary to place a suitable concave lens behind the mirror, so as to obtain a distinct image of the fundus; the greater the myopia the stronger must this concave glass be, and the nearer must the observer approach to the eye. The strength of this correcting concave lens will also enable us approximately to estimate the degree of the myopia,* which will be always somewhat less than the strength of the correcting lens. The field of vision will appear smaller, and the image nearer the eye of the observer, than in the emmetropic eye. The image is also less bright in colour and less illuminated, but apparently larger, for we cannot, as in the emmetropic eye (the size of the pupil being equal) overlook the whole expanse of the optic disc at a glance, but only a portion of it. In the indirect mode of examination, the image of the disc will be less than that of the emmetropic eye, on account of its being formed nearer to the object lens.

Myopia may run a very variable course. In some cases its progress is marked and rapid, in others slow and insidious; in the most favourable cases it remains stationary at the adult age. It is generally, however, somewhat progressive, especially between the ages of 15 and 25, and often markedly so in hereditary myopia, or if the patients employ their eyes a great deal in reading, sewing, etc. A moderate degree of stationary or but slowly progressive myopia causes but little annoyance to the patient; but it is very different if its degree is very considerable and its progress marked and rapid, for in the latter case it is almost always accompanied by symptoms of irritation and inflammation of the inner tunics of the eyeball, giving rise to redness, heat, and ciliary neuralgia during prolonged work at near objects.

* For a very full and valuable explanation of the determination of the state of refraction by the aid of the ophthalmoscope, I must refer the reader to Mauthner's Lehrbuch der Ophthalmoscopie.

It is of consequence, both in the prognosis and treatment of myopia, carefully to watch its progress, and accurately to ascertain and note the degree of myopia at the commencement, so that we may hereafter be able to determine whether the disease has remained stationary or progressed, and in the latter case, to know the extent and rate of such progress.

The popular idea that myopia diminishes with old age is not quite correct, although it is true that distant vision is somewhat improved by the diminution in the size of the pupil. Moreover the senile changes (sclerosis) in the lens may slightly diminish the myopia.

With regard to the *prognosis* of short sight, it may be stated that there is nothing to be feared from a slight stationary myopia; but it is very different when the latter is high in degree, progressive, and associated with considerable sclerotico-choroiditis posterior, for then it is always a source of danger to the eye. There is a popular fallacy that short-sighted eyes are particularly strong, and even some medical men participate in it. But this is quite erroneous, indeed a myopic eye must be looked upon as unsound, more especially if the disease is extensive and progressive. In such cases care must, therefore, be taken that the patient avoids all employment or amusement that may hasten the progress of the myopia, or give rise to irritation and straining of the eye.

It is of much consequence in myopia that the spectacles should be selected with accuracy and care, for if they are unsuitable, more especially if they are too strong, they may prove very injurious to the eye. The proper strength is rapidly and easily found in the following manner:—

The degree of the myopia must in the first place be ascertained with exactitude, by trying the furthest distance at which the patient can read No. 1. If he can do so up to 10″ from the eye, his far point (r) lies at 10″, and his myopia $= \frac{1}{10}$; for a concave lens of 10″ focus would enable him to see at an infinite distance, as it would give to parallel rays a divergence as if they came from a point 10″ in front of the lens (the patient's far point). The position of r, therefore, always affords us a clue to the number of the concave lens required, but although No. 10 would be theoretically the proper glass, we find practically that it would be somewhat too strong. The reason of this is, that the convergence of the optic axes at 10″ prevents the eye from exactly accommodating itself for its far point, the latter being only attainable when we look at distant objects with parallel optic axes. Hence concave 11 or 12 would be the glass really suitable. Whether a given lens is accurately suited to the patient's sight, can be easily determined in the following manner:—Let us return to the case above referred to of a myopia $= \frac{1}{10}$. With concave 10 the patient is able to read No. xx of Snellen at 20′, hence his V = 1. In order to determine whether

No. 10 is exactly the right glass, we alternately place before it weak concave and convex glasses and try their effect. If weak concave glasses improve the sight, the original lens (No. 10) is too weak; if, on the other hand, weak convex glasses improve it, it is too strong. If neither concave nor convex glasses render any improvement, the original lens suits exactly. The proper glass can be easily found by a very simple calculation; for if the myopia $= \frac{1}{10}$, and convex 50 improves the sight still more (convex 40 making it worse), the original glass is somewhat too strong, and we must deduct $\frac{1}{50}$ from it. The proper glass will be $\frac{1}{12\frac{1}{2}}$, for $\frac{1}{10} - \frac{1}{50} = \frac{1}{12\frac{1}{2}}$. We try concave 13 and find that neither concave nor convex glasses render any improvement.

If the original lens ($\frac{1}{10}$) was most improved by the addition of concave 50, it was too weak, and a concave lens of about 9 inches focus will be required for $\frac{1}{10} + \frac{1}{50} = \frac{1}{8\frac{1}{3}}$.

As a general rule, the weakest glass which neutralizes the myopia may be given.

If a myope desires to have spectacles to enable him to see at a distance of about 2 feet (for reading music, etc.), the proper glasses can be easily found by the following calculation:—If his myopia $= \frac{1}{12}$, and he wishes to see distinctly at 24″ the formula will be $-\frac{1}{12} + \frac{1}{24} = -\frac{1}{24}$, and concave 24 will be the proper glass.

The degree of the patient's range of accommodation materially influences the choice of spectacles, and the question as to whether or not he may be allowed their use for reading, writing, etc.

The range of accommodation may be tested in the manner already described, by finding the nearest and furthest point at which No. 1 can be read with ease, and then deducting the latter from the former according to the formula $\frac{1}{A} = \frac{1}{P} - \frac{1}{R}$.

The following plan, recommended by Donders, is however still better, as it allows the patient really to accommodate for his far point. The myopia having been neutralized by the proper concave glasses, so that the patient can read No. xx at 20′, the position of his near point (with these glasses) is now found, if it lies at 5″, his range of accommodation $= \frac{1}{5}$, for as $r = \infty$, and $p\ 5''$, $\frac{1}{A} = \frac{1}{5} - \frac{1}{\infty} = \frac{1}{5}$.

In determining the degree of myopia, each eye should always be tested separately, for the degree generally varies somewhat (often considerably) in the two eyes. The question as to what glasses should be given when there is any marked difference in the two eyes, either in

the degree of myopia, or in the refraction itself (the one eye being perhaps myopic, the other hypermetropic) will be considered hereafter.

There is no harm in permitting myopic persons to wear such glasses for distance, as just neutralize their myopia, especially if the degree of short sight is but moderate. If the patient is young, the myopia slight, and his range of accommodation good, he may even be permitted to wear these glasses in reading and writing, as in such cases the myopia shows but little tendency to increase. But if the latter is considerable, the range of accommodation diminished, and the acuteness of vision impaired, the myopia should not be quite neutralized. The patient may, however, use a binocular concave eye-glass before his spectacles when he desires to see distant objects very distinctly.*

For the purpose of reading music, I think it best to give patients spectacles suited for a distance of 2′—3′, for if the myopia is considerable, and they use glasses which completely neutralize it for distance, the size of the music is inconveniently diminished, and thus becomes somewhat indistinct and difficult to decipher.

We now come to the question whether myopic persons should wear glasses in reading, sewing, writing, etc., and the answer to this must depend upon several circumstances.

Where the myopia is but slight in degree (less than $\frac{1}{14}$), they may be dispensed with—or, if the employment is not continued for any length of time, the distance glasses may even be worn, but the type must be held at a greater distance, otherwise the eye becomes fatigued, and the accommodation strained. Indeed, I find that it is less trying and more comfortable for such patients to read without their glasses.

If the myopia is considerable in degree, so that the print has to be held very close to the eye, glasses should be prescribed which will remove the far point to about 14″—16″, for this will prevent the necessity of stooping, which causes an increased flow of blood to the eye, and an increase in the tension of the intra-ocular fluids. This congestion of the eye greatly tends to promote the development of sclerotico-choroiditis posterior, intra-ocular hæmorrhage, and detachment of the retina, which are so apt to occur in very short-sighted persons. For these reasons, we should direct myopes to read with their heads well thrown back, and to write at a sloping desk. Strict injunctions must also be given against the habit of reading in the recumbent position, either in bed or on a couch, as this produces great congestion of the eyes.

But the strong convergence of the optic axes which takes place

* In very high degrees of myopia, I have found Steinheil's glass-cone very useful for distant objects, as it acts like a Galilean telescope. It consists of a small cone of solid glass, the base of which is convex, and the opposite surface concave. It is about one inch in length, and can be readily carried in the waistcoat pocket.

when the object has to be held close to the eye, is also a source of great danger, for it is always accompanied by an increased tension of the eyeball and of the accommodation. The latter is an associated action, not arising from the mechanism of the convergence, but existing within the eye itself, and may, consequently, easily give rise to an increase of the myopia. But besides this, the pressure of the muscles upon the eyeball is greater when the optic axes are convergent than when they are parallel, and this increase of pressure must tend to give rise to the development of posterior staphyloma, and to hasten its progress. The increase in the tension of the eyeball is particularly marked when the internal recti muscles are weak, and thus render the convergence of the optic axes more difficult.

Now if we afford such very short-sighted persons the use of glasses which enable them to read and write at a distance of 14 or 16 inches from the eye, we do away with the necessity of a considerable convergence of the optic axes, the stooping position, and the evils to which these give rise.

But the patient must be warned not to bring the type close to him when the eyes become a little tired, for this would strain and fatigue the accommodation; but the book should then be laid aside for a few minutes, and the eyes rested.

Spectacles may also be used for near objects in those cases in which the myopia is accompanied by muscular asthenopia (depending upon an insufficiency or weakness of the internal recti muscles), which manifests itself as soon as the patient has worked at near objects for a short time.

Whilst the use of spectacles for near objects may be permitted with advantage in the above forms of myopia, it must be forbidden if the range of accommodation is very limited, and if the patients suffer from such a degree of amblyopia (generally depending upon sclerotico-choroiditis posterior), that they are unable to read No. 2 or 3 of Snellen's types. The glasses will diminish the size of the letters, and, in order to see them under a larger visual angle, the patient will bring the object very close to the eye, which will cause the accommodation to be greatly strained, the intra-ocular tension to be increased, and serious mischief will but too surely ensue. Spectacles should not, therefore, be permitted for near objects when marked amblyopia exists.

If the myopia is very considerable, we generally find that only one eye is employed for near objects; the convergence of the optic axes being therefore annulled. Donders says with reference to this point, "This appears to me to be often a desirable condition: in strong myopia binocular vision loses its value, and the tension which would be required for it cannot be otherwise than injurious. Now, in such cases, for reading no spectacles are given; in the first place, because the acute-

ness of vision has usually somewhat decreased, and the diminution of concave glasses is now troublesome; in the second place, because, with the retrocession of *r*, injurious efforts at convergence and at binocular vision might be excited. In any case the spectacles should be so weak as to avoid these results."

5.—PRESBYOPIA.

The first symptom of presbyopia is that small objects (small type, fine needlework, etc.) cannot be seen with such ease or at so short a distance as before. In order to see minute objects more distinctly, the patient is obliged to remove them further from the eye, or even to seek a bright light, so as to diminish the circles of diffusion upon the retina by narrowing the size of the pupil. But as the retinal images of these fine objects are very small, on account of the distance at which they are held, he will soon experience a commensurate difficulty in clearly distinguishing them, the print, for instance, will get indistinct and confused, and the eyes become fatigued and painful.

In simple presbyopia, the far point is at a normal distance from the eye, parallel rays are united upon the retina, and neither concave nor convex glasses (even after the instillation of atropine) at all improve distant vision. The eye is neither myopic nor hypermetropic. There is in fact no anomaly of refraction, but only a narrowing of the range of accommodation; the near point is removed too far from the eye, and hence the difficulty of accurately distinguishing small objects.

Amblyopia sometimes co-exists with presbyopia, and may even be mistaken for it, as the amblyopic patient likewise cannot see very small objects distinctly, and convex glasses also improve his sight. But in simple presbyopia (uncomplicated with amblyopia) we should be able to restore the normal acuity of vision and range of accommodation by the proper convex glass. With its aid, the patient should be able to read No 1 at 8″; hence if he can only decipher No. 2 or No. 4, or is obliged to hold the print closer, he is also amblyopic.

Donders has found that in the emmetropic eye the near point gradually recedes, even from an early age, further and further from the eye. This recession commences about the age of 10, and progresses regularly with increasing years. At 40 it lies at about 8″, at 50, at 11″—12,″ and so on. In the emmetropic eye, no inconvenience is generally experienced from this recession till about the age of 40 or 45. This change in the position of the near point is met with in all eyes,—the emmetropic, hypermetropic, and myopic.

But the far point also begins in the normal eye to recede somewhat about the age of 50, so that the eye then becomes slightly hypermetropic (distant vision being improved by convex glasses). At 70 or 80

years of age, the hypermetropia may $= \frac{1}{24}$, *i.e.*, the patient can see distinctly at a distance with a convex glass of 24″ focus. This hypermetropia, which is at first only acquired, may afterwards become absolute; so that the patient is not only unable to accommodate for divergent, but even for parallel rays.

The recession of the near point from the eye, and the consequent narrowing of the range of accommodation, are far more due to a change in those parts within the eye which are passively changed during the act of accommodation, than to an alteration in those which through their activity bring about the latter. For the ciliary muscle, the active agent of accommodation, is generally normal, although it may, later in life, undergo senile changes. Whereas, the passively changed organ of accommodation, the crystalline lens, gradually becomes more and more firm with advancing years, and in consequence of this increased firmness, the same amount of muscular action cannot produce the same change in the form of the lens as heretofore.

At first, of course, no inconvenience is experienced from this gradual recession of the near point; we do not, in fact, notice it until the distance is so considerable that we cannot easily distinguish small objects. When are we, then, to consider an eye presbyopic? Donders thinks this should be done as soon as the near point has receded further than 8″ from the eye; for as soon as this is the case, patients generally begin to complain that continued work at small objects has become irksome and fatiguing. We, however, sometimes meet with persons with very strong sight, who can read and write for hours without experiencing any inconvenience, even although their near point may be 11″—12″ from the eye. But these cases are exceptional. Let us, therefore, with Donders, consider presbyopia to begin when the near point is removed further than 8″ from the eye.

The degree of presbyopia (Pr) may be easily found if we decide upon a definite distance (*e.g.*, 8″) as the commencement of presbyopia, for we have then simply to deduct the presbyopic near point (p′) from this. Thus if p′ lies at 16″ the presbyopia $= \frac{1}{16}$, for $\frac{1}{8} - \frac{1}{16} = \frac{1}{16}$. Hence convex 16 will neutralize the presbyopia and bring the near point again to 8″.

It will perhaps have already struck the reader, that if presbyopia is assumed to commence when the near point has receded further than 8″ from the eye, not only the emmetropic, but also the myopic and hypermetropic, eye may suffer from presbyopia; for if a person has a myopia $= \frac{1}{16}$, and his near point lies at 12″, he is also presbyopic. This cannot, of course, occur when the myopia is higher in degree than $\frac{1}{8}$. In hypermetropia the same thing may take place, for if, with the convex glass which neutralizes the hypermetropia, the near point lies at 12″, there is also presbyopia.

The range of accommodation is found by the formula $\frac{1}{A} = \frac{1}{P} - \frac{1}{R}$.

If p = 10″, and r = ∞ $\frac{1}{A} = \frac{1}{10}$, for $\frac{1}{10} - \frac{1}{\infty} = \frac{1}{10}$.

There can be no question as to the advisability and necessity of permitting far-sighted persons the use of spectacles. They should be furnished with them as soon as they are in the slightest degree annoyed or inconvenienced by the presbyopia. Some medical men think that presbyopic patients should do without spectacles as long as possible, for fear that the eye should, even at an early period, get so used to them as to find them indispensable.

This is, however, an error, for if such persons are permitted to work without glasses, we observe that the presbyopia soon rapidly increases.

The proper strength of the glasses may be readily calculated. If p (the near point) lies 16″ from the eye, Pr = $\frac{1}{8} - \frac{1}{16} = \frac{1}{16}$. A convex glass of 16″ focus will bring the near point back again to 8″ from the eye. We must generally, however, give somewhat weaker glasses, because, on account of the greater convergence of the optic axes, the near point will through these glasses (convex 16) be in reality brought nearer than 8″. Late in life, when there is some diminution in the acuteness of vision, the near point may sometimes be brought even to 6″ or 7″, and it should be approximated the closer the greater the range of accommodation.

If no hypermetropia exists, the weakest glasses with which No. 1 of Snellen can be distinctly and easily read at about 12″ distance, may generally be given. But I have often found that if the person is much employed in reading and writing, and has always been accustomed to hold his book at a considerable distance, he will be at first much inconvenienced if his near point is brought to 10″ or 12″. We shall, therefore, have to give him glasses which will bring it only to about 16″. With these he will be able to work with ease for a considerable length of time. They may afterwards be gradually changed for rather stronger ones.

In choosing spectacles for far-sighted persons, we must also be particularly guided by the range of their power of accommodation. If this is good, we may give them glasses which bring their near point to 8″, but if it is much diminished weaker glasses should be chosen, so that it may lie at 10″—12″ from the eye.

6.—HYPERMETROPIA.

It has already been stated (p. 499) that in hypermetropia the refractive power of the eye is so low, or its optic axis so short, that

when the eye is in a state of rest parallel rays are not united upon the retina, but behind it, and only convergent rays are brought to a focus upon the latter. We must, therefore, give to parallel rays, emanating from distant objects, a convergent direction by means of a convex glass, and the reader will now comprehend how it is that a hypermetropic eye requires convex glasses for seeing distant objects. The patient may require perhaps even a stronger pair for near objects. The consequence of this low refractive power of the eye is, that whereas the normal eye unites parallel rays upon its retina without any accommodative effort, the hypermetropic eye has already, in order to do so, to exert its accommodation more or less considerably, according to the amount of hypermetropia. This exertion increases, of course, in direct ratio with the proximity of the object. If the degree of hypermetropia is moderate, and the power of accommodation good, no particular annoyance is perhaps experienced, even in reading or writing. But in *absolute* hypermetropia, the patient will not be able to see well at any point.

It will be found that hypermetropia generally depends upon a peculiar construction of the eye. It is smaller and flatter than the emmetropic eye, and although all its dimensions are less than in the latter, this is more particularly and markedly the case in the antero-posterior axis. The eye does not appear to fill out the palpebral aperture properly, but a little space may be observed between the outer canthus and the eyeball. Upon directing the eye to be turned very much inwards, it will also be seen that the posterior portion of the eyeball is flatter and more compressed than in the emmetropic eye. Donders considers that the hypermetropic is generally an imperfectly developed eye, that the expansion of the retina is less, and that there is a smaller optic nerve with a less number of fibres. He thinks, moreover, that in hypermetropia there often exists a typical form of face, chiefly dependent upon the shallowness of the orbit, which lends a peculiar flatness to the physiognomy. The hypermetropic construction of the eyeball is congenital, and often hereditary.

The ophthalmoscope also enables us to diagnose a hypermetropic eye, but in this case just the reverse obtains to what was seen in the myopic eye (page 509).

I. The fundus may also in this case be seen in the erect image at a considerable distance, but we obtain an erect image of it (and not as in myopia a reverse image), for if we regard the optic nerve, or one of the retinal vessels, and move our head to one side, we find that the image *moves in the same direction.* For an explanation of this let us glance at Fig. 70.

Let *a* be the hypermetropic eye, *b* the eye of the observer; *a* is adjusted for its far point (convergent rays), and the rays reflected from

its back-ground will, consequently, emanate from it in a divergent direction, as if they came from a point behind the retina, and they must,

Fig. 70.

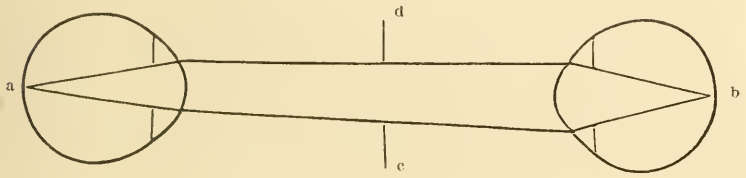

therefore, also fall in a divergent direction upon the eye of the observer. If the latter is myopic (adjusted for divergent rays), the rays will be united upon his retina without the aid of any correcting lens behind the ophthalmoscope. But if his eye is emmetropic (adjusted, when in a state of rest, for parallel rays), he will either have to place a convex lens behind the mirror, or have to accommodate for a nearer point. The strongest convex lens with which the details of the fundus can still be seen in the erect image, affords us a relative estimate of the degree of existing hypermetropia.

The image of the observed eye will be erect, for *c* and *d* retain their relative positions.

II. On going closer, but still examining in the erect image, the field of vision appears much enlarged, and the image removed further from the eye, its size is considerably diminished, whereas the intensity of its light and colour is much increased. If the hypermetropia is high in degree, we can overlook at a glance not only the whole optic entrance, but also a considerable portion of the fundus around it. In the indirect mode of examination, the size of the optic disc will appear much larger than in the emmetropic eye, which is due to its image being formed further from the object lens. If our eye is emmetropic, we must, in order to gain a distinct image, either place a strong convex lens behind the mirror, or else we must accommodate for a nearer point.

The ophthalmoscopic diagnosis of hypermetropia is frequently of much service, especially in young children affected with strabismus, the state of whose refraction we wish to ascertain, but who are too young to read. Again, in spasm of the ciliary muscle dependent upon hypermetropia, the latter may be so completely masked that the patient can only see at a distance with slightly concave glasses, and not at all with convex ones. We hence, perhaps, believe it to be a case of myopia, but on ophthalmoscopic examination we find that the refraction is markedly hypermetropic. In such cases the patient should, however, look at some distant object, or into vacant space, so that his accommodation may be quite relaxed. We may notice in such patients how the ophthal-

moscopic appearances vary when the accommodation is relaxed, and when it is called into action by their regarding some near object.

We must distinguish various forms of hypermetropia, and in our classification of these we shall follow Donders' system, which is the most practical.

We may, in the first place, divide hypermetropia into two primary classes, the original and the acquired.

Owing to the senile changes in the lens which appear with advancing age, the far point begins to recede somewhat from the eye at the age of 40 or 45. At 60, the eye is generally already so hypermetropic that distant vision is markedly improved by convex glasses. At 70 or 80 years the hypermetropia often $= \frac{1}{24}$. This is termed acquired hypermetropia. The latter will, of course, be very considerable when the crystalline lens is absent (as after extraction of cataract).

Original hypermetropia may be divided into the manifest (Hm) and latent (Hl) form.

In order to determine the presence of hypermetropia, the patient is directed to read No. xx (Snellen) at 20′. Let us suppose that he can do so with ease; we then find the strongest convex glass with which he can still see the same number clearly and distinctly, and this gives us the degree of manifest hypermetropia. If convex 20 is the lens (convex 18 making the sight worse) Hm $= \frac{1}{20}$. Each eye should be tried separately, as the degree of hypermetropia may vary. The range of accommodation with this glass is then tried.

But although convex 20 may be the strongest glass with which he can see at a distance, the degree of hypermetropia may in reality be very much higher than $\frac{1}{20}$. The fact being, that the patient has been so accustomed to exert his accommodation (even when regarding distant objects), that he cannot relax it all at once, even when there is no occasion for it, the malconstruction of the eye being compensated for by a convex lens. To find the real degree of hypermetropia, we must, therefore, paralyse his accommodation by a strong solution of atropine (gr. iv ad ℥j). This should be allowed to act for two or three hours. At the end of this time we again examine the patient, and now, perhaps, find that he cannot see No. xx at all at 20′ without glasses, or even with convex 20. To do so distinctly he, perhaps, requires convex 8; and this difference in the power of the glasses required before and after the paralysis of the ciliary muscle, shows us to what an extent he exerted his accommodation before the application of the atropine. But this great difference only exists in young persons, with a good range of accommodation. The atropine should be only applied to one eye at a time; its effect goes off in about six or seven days. But as its effect proves very disagreeable and confusing to the sight, it should only be applied in those cases in which it is of importance to know

precisely the degree of latent hypermetropia. Its action may, if necessary, be neutralized by the extract of Calabar bean, which will however have to be repeated several times, as its effect is much more transitory.

A slight degree of hypermetropia is often unnoticed until the age of 25 or 30, when symptoms of asthenopia show themselves if the patient is obliged to work much at near objects. If we try the sight for distance, we find that he can read No. xx at 20′, and also with a weak convex glass (30 or 40). Or, perhaps, if only momentarily held before the eye it makes the sight worse, as the patient cannot at once relax his accommodation, but after looking through it for a few minutes he sees better. To make sure of the degree of H, the accommodation must be paralysed with atropine.

Donders divides manifest hypermetropia into three classes, the *facultative*, the *relative*, and the *absolute*.

In *facultative* hypermetropia the patient can see well (with parallel optic axes) at an infinite distance, with or without convex glasses. He can also see to read small print with ease without glasses, so that he experiences no fatigue during work. Presbyopia, however, sets in unusually early, and then symptoms of asthenopia supervene.

In *relative* hypermetropia, the eye may also be able to accommodate itself either for parallel or for divergent rays, and see well both at a distance and near at hand, but it can only do so by converging the optic axes for a nearer point than that at which the object is situated; by acquiring, in fact, a periodic convergent squint. It is not of very frequent occurrence in childhood, but is more often met with after the age of puberty and in early manhood. The sight is always more or less affected, and the patient has a difficulty in finding the exact distance at which he can see best.

In *absolute hypermetropia* vision is indistinct, both for infinite distance and for near objects; for the patient cannot unite the rays upon the retina even with the strongest effort of accommodation, or with the strongest convergence of the optic axes. The focus of both divergent and parallel rays remains situated behind the retina. It is not often met with in youthful individuals, as they generally possess a sufficiently strong power of accommodation to overcome it. In a superficial examination, such a patient might be mistaken for a person suffering from myopia with amblyopia, for he will not be able to see distinctly at a distance without glasses, which may be erroneously attributed to myopia, nor will he be able to read very fine print, and this may be supposed to be due to amblyopia.

If the hypermetropia is considerable in degree, the patients often see better when the print is held very close to the eye, than when it is 10″ or 12″ off. This is partly due to the diminution in the size of the circles of diffusion, on account of the contraction of the pupil. More-

over, the circles of diffusion increase comparatively less in magnitude than the size of the retinal image, as the object is approximated (Graefe).

A hypermetropic eye may at a certain age become presbyopic. If with the glasses which neutralize the hypermetropia, the near point lies at 12″ to 14″, presbyopia co-exists, and a stronger pair of glasses will be required for reading.

The range of accommodation is best found by neutralizing the patient's hypermetropia by means of the proper convex lens, and then finding where his near point lies with this glass.

In high degrees of hypermetropia the acuteness of vision is generally somewhat diminished. This, according to Donders, is partly due to the structure of the eye, for as the nodal point lies far back, the retinal images will be correspondingly small; hence convex glasses improve the sight, by advancing the nodal point, and increasing the size of the retinal image. It may also be due to astigmatism, or to the smaller number of nerve fibres in the optic nerve and retina.

Hypermetropia is a very frequent cause of asthenopia (seu hebetudo visus, impaired vision, muscular asthenopia, etc); this condition being distinguished by the following symptoms:—The patient cannot look at near objects (in reading, writing, sewing, etc.), for any length of time without the eyes becoming fatigued. The print becomes indistinct, the letters run into one another, there is pain in and around the eye, and the latter may become red and watery, and feel hot and uncomfortable; yet the eye looks quite healthy, the refracting media are clear, vision is good, the convergence of the optic axes perfect, and the mobility of the eye unimpaired. Neither does the ophthalmoscope reveal anything abnormal, except perhaps slight hyperæmia of the optic nerve and retina. The symptoms of asthenopia quickly vanish when the work is laid aside, to reappear however when it is resumed. It was indeed a great boon when Donders discovered that most of these cases of asthenopia depended upon hypermetropia, and could be cured by the proper use of spectacles. If we wish permanently to cure such cases, we must afford the patient the aid of glasses, and thus prevent all undue straining of the accommodation.

This accommodative form of asthenopia must be distinguished from the muscular, which depends upon weakness of the internal recti muscles, and from the retinal asthenopia. The latter is generally due to hyperæsthesia and irritability of the retina, accompanied by hyperæmia of the optic nerve and retina. It mostly occurs in feeble, nervous, and excitable persons, especially females.

Let us now consider how hypermetropic persons are to be suited with glasses.

Theoretically, it would appear right to neutralize the hypermetropia by a convex lens, and thus change the eye into an emmetropic one; this

lens forming, so to speak, an integral part of the eye. But in practice we find that this does not answer.

In facultative hypermetropia, there will be no occasion to prescribe glasses for distance, as the patient can see well without them. Moreover, there is the disadvantage, that after convex spectacles have been worn for some time for distance, the power of seeing distinctly without them is lost, which is of course very inconvenient. For this reason they should never be ordered, except in cases of absolute or relative hypermetropia of a considerable degree. If there are symptoms of asthenopia, glasses should be given for reading, etc., which are somewhat stronger than those which correct the manifest hypermetropia. If these are found too strong and trying to the eye, they must be exchanged for weaker ones, and the strength be gradually increased until the asthenopia has disappeared.

In relative and absolute hypermetropia spectacles should also be worn for distance, as we find that in such instances distant vision is not distinct. In such cases, I generally commence with the glasses which neutralize the manifest hypermetropia, and in young persons order them to be worn both for near and distant objects. If they prove too strong for distance, a weaker pair must be prescribed, and their strength gradually increased. If they do not relieve the asthenopia, or if presbyopia coexists, a stronger pair must be given for reading, writing, and sewing.

In using the spectacles for reading, sewing, etc., it is always advisable to interrupt the work for a few minutes at the end of half an hour or an hour. This rests the eye, which is then able to resume the employment with renewed vigour and ease. If the asthenopia does not quite disappear under the use of glasses, we must examine the power of convergence, for together with the hypermetropia there may exist insufficiency of the internal recti muscles, and the asthenopia be partly due to this. If the accommodation has been greatly fatigued by prolonged work at near objects without the aid of glasses, or if there is spasm of the ciliary muscle, the accommodation should be placed in a condition of complete rest, by being paralysed by a strong solution of atropine; and this paralysis should be maintained for several weeks.

Donders has shown that convergent strabismus very frequently depends upon hypermetropia. A person suffering from the latter, is always obliged to accommodate more or less, in order to see with distinctness. Even at a distance, he must already accommodate in order to neutralize the hypermetropia, and the nearer the object is approximated, the more will this tension of the accommodation increase. There exists, however, a certain relation between the accommodation and the convergence of the optic axes, for with an increase of the latter there is also an increase in the power of accommodation. This assertion is proved by the fact, that if we place a

prism with its base turned outward before a hypermetropic eye, the latter will squint inwards, in order to avoid diplopia in looking at distant objects, and this convergence will enable the eye to accommodate for parallel rays (distant objects); whereas, with parallel optic axes, it before required convergent rays, *i.e.*, the rays from a distant object had to be rendered convergent by means of a convex glass, in order to be brought to a focus upon the retina. Again, if we place a concave glass before a normal eye, we change it into a hypermetropic one; parallel rays are united *behind* the retina, and it either requires an effort of accommodation or a convex glass to bring them to a focus *on* the retina. If the concave lens is but of slight power, an increased effort of accommodation,—an increase in the convexity of the crystalline lens,—will neutralize the effect of the concave lens, and overcome this artificial hypermetropia. But if the concave glass is too strong for this, the eye often overcomes its effect by squinting inwards, and thus considerably increasing its power of accommodation. Now the same thing frequently occurs in hypermetropia; for the eye squints inwards in order to increase its power of accommodation. This has been called periodic squinting. In the beginning, no deviation of the optic axes is observable as long as the person is not looking sharply at anything; but as soon as he looks intently at any object, near or distant, convergent squint shows itself. Sometimes, this only occurs when the patient is looking at near objects, the squint disappearing as soon as he regards distant objects. After a time the squint becomes permanent, particularly in those persons who work at near objects, whether in reading, writing, or sewing. We meet with it very frequently in children about the third or fourth year, when they first look attentively at things, or begin to use their eyes for any length of time for near objects. When this tendency to squint first shows itself, it may be corrected by neutralizing the hypermetropia by means of convex glasses, but will generally require an operation.

Moreover, the patient should always be warned beforehand that after the operation of strabismus, it may be necessary to wear glasses in order to prevent the recurrence of the squint.

The cause of the *apparent* divergent strabismus which is often noticed in marked cases of hypermetropia, has already been explained to be due to the considerable angle formed by the visual line and optic axis on the cornea of hypermetropic eyes; for as the visual line in the latter lies much to the inner side of the optic axis on the cornea, it will be at once evident that if the visual lines are parallel (fixed upon some distant object) the optic axes will diverge, often to a marked degree. In high degrees of myopia the reverse obtains, for as the visual line then often lies to the outer side of the optic axis, an apparent convergent squint will arise when the visual lines are parallel.

7.—ASTIGMATISM.

We have seen that the anomalies of refraction resolve themselves into two, viz., myopia and hypermetropia. But the state of refraction may vary in the different meridians of the same eye; thus, it may be emmetropic in the vertical meridian, but myopic or hypermetropic in the horizontal, or *vice versâ*. Or differences in the degree and even in the form of emmetropia may exist in the various meridians. This asymmetry has been termed astigmatism (*a*, privative, and *στιγμα*, a point), which signifies that rays emanating from a point are not re-united at a point. This peculiar defect* was first observed by Thomas Young (1793), who considered it due to some inequality in the structure of the lens, whereas Wharton Jones thought its seat was in the cornea. Donders has shown that it is of frequent occurrence, and that many cases of congenital amblyopia are due to it, and may be cured by proper cylindrical glasses.

But even in the normal eye, the cornea does not refract equally in all its meridians, for the focal distance of the dioptric system is generally shorter in the vertical meridian than in the horizontal. On this account, fine vertical lines can be seen up to a further distance than horizontal lines, but the latter can be seen closer than the vertical ones. For this experiment horizontal and vertical lines may be drawn upon a page, or Von Graefe's wire optometer may be used.

If the stripes or lines are arranged crosswise, we are unable to distinguish both the horizontal and vertical lines with equal clearness and distinctness at one and the same distance; thus, if we can see the vertical line clearly and sharply defined, we must approach the horizontal line nearer to the eye, in order to gain an equally distinct image of it, and *vice versâ*. These facts prove that the vertical meridian has a shorter focal distance than the horizontal, and for this reason horizontal lines are seen distinctly at a shorter distance than vertical ones. For as the rays which are refracted in the vertical meridian are united in a point sooner than those in the horizontal plane, these latter give rise to circles of diffusion upon the retina in the form of small horizontal lines which do not confuse the images of horizontal lines, but interfere with those of vertical lines.

As it is of much consequence in the study of astigmatism that the reader should thoroughly understand these preliminary facts, I give the following extract and explanatory woodcuts from Donders' work. After speaking of the fact that a vertical stripe can be seen further off and a horizontal stripe at a closer distance he continues:—"These

* For a most interesting historical account of this subject, see Donders' work, p. 539.

experiments prove that the points of the refracting meridians are not symmetrically arranged around one axis. The asymmetry is of such a nature that the focal distance is shorter in the vertical meridian than in the horizontal. In order, namely, to see a vertical stripe acutely, the rays, which in a horizontal plane diverge from each point of the line, must be brought to a focus upon the retina; it is not necessary that those diverging in a vertical plane should also previously converge into one point, as the diffusion-images still existing in a vertical direction cover one another on the vertical stripe. On the other hand, in order to see a horizontal stripe acutely, it is necessary only that the rays of light diverging in a vertical plane should unite in one point upon the retina. Now horizontal lines are acutely seen, as I have remarked, at a shorter distance than vertical ones, consequently rays situated in a vertical plane, which are refracted in the vertical meridian of the eye, are more speedily brought to a focus than those of equal divergence situated in a horizontal plane; and the vertical meridian, therefore, has a shorter focal distance than the horizontal.

"The correctness of this view appears further from the form of the diffusion-images of a point of light. In accurate accommodation the diffusion-spot is very small, and nearly round, while a nearer point appears extended in breadth, and a more remote one seems to be extended in height. The signification of this phenomenon must be clearly understood, and appears, therefore, to demand more particular explanation.

"Let us suppose the total deviation of light in the eye to be produced by a single convex refracting surface, with the shortest radius of curvature in the vertical, and the longest in the horizontal meridian. These two are then the principal meridians. Through a central round opening (Fig. 71, *v v h h*) let a cone of rays, proceeding from a point situated in the prolongation of the axis of vision, fall upon this surface; of this cone let us consider only the rays situated in the vertical plane *v v*, and the rays situated in the horizontal plane *h h*, whereof respectively the points *v v* and *h h* are the most external. After the refraction, both approach the visual axis (which perpendicular to the plane of the drawing passes through *a*), *v v* does so, however, more rapidly than *h h*. Before union they therefore lie in the ellipse *A*, as in Fig. 72, and where *v v* meet in one point *B*, *h h* have not yet come to a focus. Thereupon we now find in succession *v v* already intersected, *h h* approached to one another, *C*, *D*, *E*; further, *h h* united in one point, and *v v* after intersection more widely separated, *F*; finally, both intersected, *G*. The focus of *v v* therefore lies most anteriorly, that of *h h*

Fig. 71.

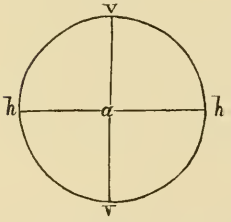

most posteriorly in the axis. The space between the two points, where rays of different meridians intersect, may be called the focal interval (*intervalle focale*, or Brennstrecke of Sturm). From the above figures,

Fig. 72.

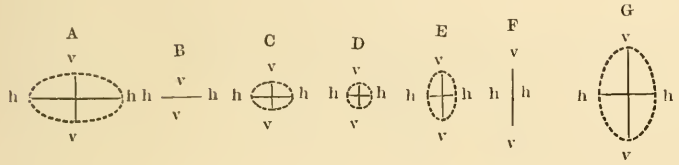

it is now evident what successive forms the section of the cone of light will exhibit. In the middle of the focal interval *D*, it will be nearly round, and anteriorly through oblate ellipses, *C*, with increasing eccentricity, it will pass into a horizontal line *B*; posteriorly through prolate ellipses, *E*, it will come to form a vertical line *F*, while before the focal interval a larger oblate ellipse, *A*, and behind it a larger prolate ellipse, *G*, will be found."

The position of these figures with regard to the focal interval is shown in Fig. 73. In the cone of light emanating from *L*, are depicted the rays which impinge upon the vertical meridian *V V* and upon the horizontal meridian *H H*. The former are united in *o*, the latter in *m*, so that *o m* is the focal interval.

Fig. 73.

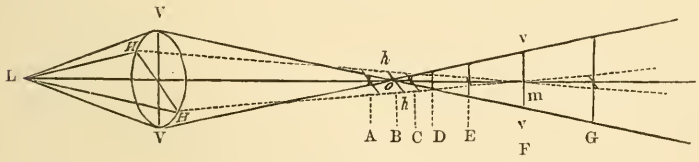

After Schirmer.

In Fig. 73, the letters *A*, *B*, *C*, *D*, *E*, *F*, and *G* correspond to the same letters in Fig. 72. The rays which lie in the plane of the vertical meridian *V V* (in Fig. 73), are brought to a focus at *o*, where the rays which lie in the plane of the horizontal meridian *H*, *H*, are not yet united, but form the horizontal line *h h* (the *anterior* focal line). The rays *H H* are united further back at *m*, where the vertical rays form the vertical line *v v* (the *posterior* focal line). The distance between these two focal lines forms the focal interval. The anterior focal line *h h*, corresponds to the position of the meridian of the lowest refractive

power, whereas the posterior focal line *v v*, to that of the meridian of highest refraction. Generally the astigmatic patient endeavours unconsciously so to regulate his accommodation that the middle portion of the focal interval falls upon the retina; in this way only a small round circle of diffusion *D* (Fig. 72), is formed, and the object is more distinctly seen than it would be at the anterior or posterior extremity of the focal interval. In case that the anterior extremity of the focal interval (and if this is the focus of the vertical meridian) falls upon the retina, a circular flame appears as a horizontal luminous line. The reverse will of course occur if the posterior extremity of the focal line (if this corresponds to the focus of the horizontal meridian) falls upon the retina, for then the flame will appear as a vertical, luminous line. Hence, horizontal and vertical stripes will be sharply and distinctly seen when the diffusion-images of all the points of the stripe form respectively horizontal and vertical lines, which cover one another in the stripe; and this will be the case when the beginning and the end of the focal interval correspond respectively to the percipient surface of the retina (Donders).

Although we have hitherto assumed that the principal axes of curvature corresponded with the vertical and horizontal meridians, it must be mentioned that they may deviate considerably from these. Also, that instead of the minimum of curvature corresponding with the horizontal meridian, and the maximum with the vertical, the reverse may even obtain, and the maximum curvature coincide with the horizontal meridian.

The aberration which is due to a difference in the focal distance of the two principal meridians, is called *regular* astigmatism, and depends upon the curvature of the cornea. Whereas the aberration which is due to a difference in the refraction in one and the same meridian, is called *irregular* astigmatism, and is generally caused by a peculiarity in the structure of the crystalline lens, and cannot be corrected by cylindrical lenses. It often gives rise to monocular polyopia. The two forms sometimes co-exist. The degree of regular astigmatism met with in normal eyes is generally too slight to cause any impairment of vision; but when it is more considerable, the sight is indistinct. This amblyopia is due to circles of diffusion being formed upon the retina, which cross and overlap each other. The greater the difference in the refraction of the principal meridians, the more considerable will be the circles of diffusion and consequent indistinctness of vision. If the astigmatism is at all high in degree, the acuteness of vision is much impaired, both for near and distant objects. If the eye is myopic or hypermetropic, we find that we cannot with any spherical lens produce a very decided improvement, or raise the acuteness of vision to the normal standard.

The diagnosis of astigmatism may generally be made without much difficulty; but it is necessary to follow a settled line of examination, otherwise the beginner will fall into great confusion, and waste a large amount of time. Numerous modes of discovering the presence of astigmatism, and of estimating its degree are in use; but the following are the simplest and most practical.

In the first place, we must carefully examine the acuteness of vision, and ascertain which number of Snellen's types the patient can see at a distance of 20′. If the acuteness of vision is below the normal standard (if he cannot read No. xx), we must try whether it can be raised to this by concave or convex spherical lenses. If we fail in doing so, we must suspect the presence of astigmatism, and next proceed to determine the situation of the two principal meridians (*i.e.*, the maximum and minimum of curvature). This may be done by directing the patient to look at a small, distant point of light (varying from two to four millimètres in diameter, and seen through a small opening in a large black screen). The patient should be placed at a distance of from 12 to 16 feet, and directed to look at the luminous point. The latter will not appear round if the eye is astigmatic, but will be elongated in a certain direction, according to the fact whether the light is nearer or further off than the point for which the eye is accommodated. Thus, if the maximum of curvature coincides with the vertical meridian, the luminous line will be horizontal if the eye is accommodated for a further point, and vertical if it is adjusted for a nearer point. Weak concave and convex lenses are then placed alternately before the eye (the latter being thus changed into a myopic or hypermetropic one), and the anterior and posterior focal line brought alternately upon the retina. The direction of this line will depend of course upon the direction of the principal meridian.

A better test object is, however, formed by a series of straight lines, which cross each other in the centre of a circle. For this purpose, I have found Dr. Green's* test objects the best, and use them in preference to any others. He employs three figures, which can be arranged in such a manner as to amplify and check the results obtained. I have, however, found that one of the diagrams (Fig. 74) is sufficient. It consists of a circle, traversed by a set of twelve triple lines, corresponding to the figures on a watch dial; the figures being placed at the extremity of the sets of lines, as in Javal's optometer (Fig. 75). Each line is equal in thickness to the lines

Fig. 74.

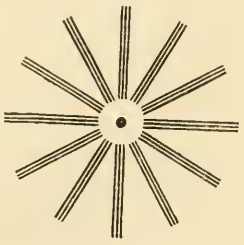

* Vide Dr. Green's paper on "The Detection and Measurement of Astigmatism," in the American Journal of Medical Sciences, January, 1867.

employed by Snellen in the construction of No. xx of his test types, and is designed to be distinctly seen at a distance of about 20′. The circle is about $12\frac{1}{2}''$ in diameter.

This test circle is to be placed at a distance of 20′, and if the patient can see all the lines distinctly and sharply defined (any existing myopia or hypermetropia being corrected by suitable spherical lenses), he is not astigmatic. But if only the line in one meridian appears clear and sharply defined, whilst the others are indistinct, the presence of astigmatism is proved, and the direction of the distinct line corresponds to the meridian of the highest refraction. If we now wish to discover the degree and nature of the astigmatism, and are only supplied with spherical lenses, we try the weakest concave or the strongest convex lens which, placed in a stenopaic apparatus,* enables the patient to see all the radiating lines with equal distinctness. If a concave lens is required, it is a case of myopic astigmatism, whereas, it is hypermetropic, if a convex lens is required.

If we possess a trial case of cylindrical lenses, the weakest concave or strongest convex cylindrical glass should be found which renders all the radiating lines quite distinct and clearly defined. When we have found the lens which corrects the astigmatism, the patient's sight should next be tried with Snellen's test types, in order that we may accurately ascertain the degree of improvement of sight produced by it. In cases of hypermetropia, the effort of accommodation often conceals a considerable portion of the astigmatism, and may thus greatly mislead us as to its actual degree. The examination is therefore greatly facilitated, if the accommodation is first paralysed by atropine.

In the above modes of examination each eye is to be tried separately.

Javal has devised the following ingenious instrument for the rapid determination and correction of astigmatism.† It is in the form of a stereoscope mounted upon a stand, and is supplied with convex spherical lenses of about 5″ focus. In high degrees of hypermetropia a lens of 3″ should be employed, whereas, in high degrees of myopia we may omit the convex lenses, or substitute concave ones. Two circles are drawn side by side upon a piece of card board, just as in a stereoscopic plate, being at such a distance from each other, that the centre of each circle corresponds to the distance between the two eyes. In

* The stenopaic apparatus employed for this purpose, consists of a small cylinder open at one end, so as to fit closely to the eye, the other end being furnished with a small slit, which can be readily narrowed and widened. The effect of this slit (which should be set to a width of about $1\frac{1}{2}$ or 2 millimètres), is of course to admit only rays in a certain direction, excluding all the others. The box of the cylinder should be made to unscrew, in order that spherical lenses may be placed in it.

† "Kl. Monatsbl.," 1865, 336. This optometer of Javal's is made by Nachet, 17, Rue St. Séverin, Paris.

the one figure (Fig. 75) are drawn a series of radiating lines, and at their extremity are placed the figures I to XII, arranged like the figures on a watch dial. If the visual lines are parallel, the two circles are fused into one image, in the centre of which lie the radiating stripes,

Fig. 75.

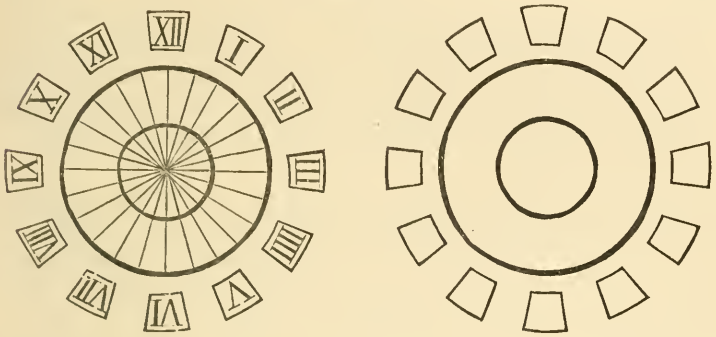

and at the circumference the figures. On account of the parallelism of the eyes, the latter are accommodated for their far point. By means of a screw, the circles are now removed further and further from the eyes, until all the radiating lines, except one, become indistinct. The direction of this one is easily identified by the figures, and its direction corresponds to the diameter of the highest refraction. Behind the ocular lens of the one eye is arranged, upon a pivot, a series of concave cylindrical lenses, so that they can be rapidly rotated in front of the eye, until the lens is found which corrects the astigmatism and indicates its degree. These lenses are arranged in such a manner, that they can be used singly or together, thus allowing of most varied combinations. After the degree of astigmatism has been determined, the state of the refraction of the eye must be ascertained, and the same apparatus may be used for this purpose. After the examination of the one eye has been finished, that of the other should be proceeded with, the series of cylindrical lenses being turned over to the other side. The principal objection to this instrument is, that on account of the patient being conscious of the close proximity of the object, he does not relax his accommodation completely, and is hence not in reality accommodated for his far point, and we may therefore fall into error as to the degree of his astigmatism. This error is to a great extent avoided if we test him with the radiating lines at a distance, and completely so, if in a case of hypermetropia the accommodation is paralysed.

Donders has distinguished three forms of astigmatism, viz.: I. Simple astigmatism; II. Compound astigmatism; III. Mixed astigmatism.

I. Simple Astigmatism.—The state of refraction of the one principal meridian is emmetropic, whereas, that of the other is either myopic or hypermetropic. If we, in such a case, turn the slit of the stenopaic apparatus in the direction of the normal meridian, the acuteness of vision will be perfect, whereas, a certain concave or convex spherical lens will be required if the slit is turned in the direction of the other meridian.

Simple astigmatism is divided into :—1. Simple myopic astigmatism (Am), in which myopia exists in the one principal meridian, and emmetropia in the other. 2. Simple Hypermetropic Astigmatism (Ah). —In this there is hypermetropia in the one principal meridian, and emmetropia in the other.

II. Compound Astigmatism.—In this form, myopia or hypermetropia exists in both principal meridians, but it varies in degree. If the stenopaic slit be used in such cases, it will be found that a different concave or convex lens will be required in each of the principal meridians, in order to render the acuteness of vision normal.

We must here also distinguish two forms :—1. Compound Myopic Astigmatism (M + Am).—Myopia exists in both principal meridians. 2. Compound Hypermetropic Astigmatism (H + Ah).—Hypermetropia exists in both principal meridians.

III. Mixed Astigmatism.—This is a rare form, in which the one principal meridian is myopic, the other hypermetropic. We must here also distinguish :—1. Mixed astigmatism, with predominant myopia (Amh). 2. Mixed astigmatism, with predominant hypermetropia (Ahm).

Knapp and Schweigger have pointed out that the ophthalmoscope also furnishes us with a valuable and easy diagnostic symptom of regular astigmatism. On examining in the direct method an eye affected with astigmatism, it will be found that the optic disc, instead of being round, appears elongated in one direction, and that the latter corresponds exactly to the meridian of greatest curvature. For as the focal distance is shorter in this meridian than in the other, the image must also be more magnified in this direction. If we now examine the same eye in the inverted image, the optic disc will appear elongated in the opposite direction; thus, if in the erect image the disc appears oval in the vertical direction, in the inverted, it will appear oval in the horizontal direction, and this at once proves the existence of regular astigmatism, and shows also that the vertical meridian is of greater curvature, and, consequently, has a less focal distance, than the horizontal. The comparative examination in the erect and inverted image therefore furnishes us with a most valuable aid to diagnosis, which will often spare us the necessity of a long and intricate subjective examination.

In examining, in the erect image, an eye affected with hypermetropic

astigmatism, it will also be found that in order to see with equal distinctness the vessels running in different directions, the state of accommodation of the observer's eye has to undergo a change.

Mr. Bowman "has been sometimes led to the discovery of regular astigmatism of the cornea, and the direction of the chief meridians by using the mirror of the ophthalmoscope much in the same way as for slight degrees of conical cornea. The observation is more easy if the optic disc is in the line of sight and the pupil large. The mirror is to be held at two feet distance, and its inclination rapidly varied, so as to throw the light on the eye at small angles to the perpendicular, and from opposite sides in succession, in successive meridians. The area of the pupil then exhibits a somewhat linear shadow in some meridians rather than in others." *

Astigmatism is generally congenital and often hereditary; it may, however, also be acquired. The congenital astigmatism is mostly regular and dependent upon asymmetry of the cornea. In the majority of cases it is present in both eyes, although perhaps in varying degree. Donders has found that abnormal astigmatism occurs far more frequently in hypermetropic eyes than others; indeed, he even thinks that out of six hypermetropic eyes one suffers from abnormal astigmatism. The amblyopia which often exists in hypermetropia, and which cannot be remedied by spherical convex lenses, is mostly due to astigmatism. We often find that persons unconsciously correct a certain amount of astigmatism by holding their head on one side, and thus looking slantingly through their spectacles.

Acquired astigmatism is mostly caused by inflammatory changes in the cornea, which lead to consecutive flattening of the cornea, and leave behind them opacities and cicatrices; it may also be caused by irregularity in the apposition of the edges of the incision after the operation of extraction of cataract. We occasionally find that if iridectomy, or iridodesis, is performed in cases of opacity of the cornea, a considerable degree of amblyopia persists after the operation, although the pupil is now brought opposite to a transparent portion of the cornea. On examination, we then find that in many of these cases this weakness of sight is due to astigmatism, and that vision is greatly improved by a cylindrical lens. Acquired astigmatism may also be caused by dislocation of the crystalline lens, more particularly if it is obliquely displaced in the area of the pupil.

The best examples of pure regular astigmatism are furnished by successful cataract operations, for then any irregular astigmatism which may have been caused by the lens will, of course, have been removed.

The disturbance of vision produced by even a slight degree of astigmatism is often very great and annoying, as the form and shape of

* Donders, p. 490.

minute objects (such as small letters) are so changed, that they cannot be seen with distinctness, but look blurred and confused. This is due to the fact that certain portions of a letter are yet quite distinct, whilst others are faint or unapparent. Thus the vertical lines of the letter H may appear quite dark and clear, whilst the horizontal connecting line is almost invisible. This also gives a peculiar tremulousness and uncertainty to the outline of the object. On account of the co-existence of irregular astigmatism, the patient may also be affected with monocular diplopia or polyopia.

Regular astigmatism may be remedied by the use of cylindrical lenses, which enable us to correct the anomaly of refraction in each of the principal meridians.

A cylindrical lens is the segment of a cylinder, and refracts those rays of light the strongest which strike it in a plane at right angles to the axis of cylindrical curvature; whereas the rays which pass through its axis suffer no deviation at all. In this, therefore, the cylindrical lens differs from the spherical, which refracts the rays in all planes of the segment.

Now, if in a case of simple astigmatism the one principal meridian is normal, so that rays passing through it are united exactly upon the retina, and the other principal meridian is myopic or hypermetropic, and the rays passing through it are brought to a focus before or behind the retina, we should correct this anomaly of refraction by means of a cylindrical lens whose axis corresponds to the normal meridian. The effect of this would be that the rays which pass through its axis would undergo no refraction, whereas, those that pass in a plane at right angles to the axis would undergo the necessary refraction, and thus neutralize the anomaly which obtains in this meridian.

A convex cylindrical lens should be placed in such a direction that its axis lies in the plane of the highest refracting meridian, in order that it may give to the rays which undergo the smallest degree of deflection, such an increased amount of convergence as if they passed through the meridian of the greatest refraction.

The reverse obtains in the case of concave cylindrical lenses, for here the axis must correspond to the meridian of least refraction, so that the focal length of the meridian of greatest curvature may be increased, and made equal to that of the meridian of least refraction. A glance at Fig. 73, p. 527, will readily explain this.

I will now illustrate the choice of cylindrical lenses by some examples.

I. *Simple Astigmatism.*—The state of refraction of the one principal meridian is emmetropic, whereas, that of the other is either myopic or hypermetropic.

1. *Simple Myopic Astigmatism* (Am).—Let us suppose that there is

emmetropia in the principal horizontal meridian (the far point lying at an infinite distance, *i.e.*, R = ∞), but that in the principal vertical meridian there is myopia = $\frac{1}{8}$, then Am = $\frac{1}{8} - \frac{1}{\infty} = \frac{1}{8}$.

In order to correct this, a concave cylindrical lens of 8 inches focus will be required, its axis corresponding to the horizontal meridian, so that the rays of light may here pass without undergoing any refraction, and only those which pass at a right angle to the axis (vertically) be refracted, so as to neutralize the myopia which exists in the principal vertical meridian. To be quite accurate the lens should be slightly stronger ($7\frac{1}{2}$ inches focus), for $\frac{1}{2}$ an inch should be deducted from the strength of the concave lens, on account of the distance of the latter from the nodal point. In hypermetropia, on the other hand, this distance of about $\frac{1}{2}$ an inch must be added to the number of the convex lens. In slight degrees of myopia or hypermetropia (below $\frac{1}{15}$ or $\frac{1}{20}$) we may, however, omit this distance in the calculation.

2. *Simple Hypermetropic Astigmatism* (Ah).—In the horizontal meridian let there be hypermetropia = $\frac{1}{10}$, in the vertical emmetropia, then Ah = $\frac{1}{10} - \frac{1}{\infty} = \frac{1}{10}$ and the patient will require a convex cylindrical lens of 10 inches focus with its axis placed vertically.

II. *Compound Astigmatism.*—In this form, it will be remembered, myopia or hypermetropia exists in both the principal meridians, but it varies in degree.

It will be found very much to facilitate the understanding of these cases of compound astigmatism, if we consider the eye to be affected with simple myopia or hypermetropia, but that there exists besides, a maximum degree of this anomaly of refraction in one of the principal meridians. We have, therefore, a certain degree of myopia or hypermetropia common to the whole eye, besides a certain, special degree in one of the principal meridians.

1. *Compound Myopic Astigmatism* (M + Am).—Myopia exists in both meridians, but to a higher degree in the one than in the other.

In the principal vertical meridian let M = $\frac{1}{15}$.

In the principal horizontal meridian let M = $\frac{1}{30}$, we then have myopia = $\frac{1}{30}$ and Am = $\frac{1}{15} - \frac{1}{30} = \frac{1}{30}$ to be written as M = $\frac{1}{30}$ + Am $\frac{1}{30}$.

In such a case, a spherico-cylindrical lens is required, the one surface of which has a spherical, the other a cylindrical curvature, and its action is that of a plano-cylindrical lens combined with a plano-spherical lens, and it may be expressed by the formula for each of the refracting surfaces, united by a sign of combination.

The case which we have supposed would therefore be corrected by $-\frac{1}{30}$ s $\subset$ $-\frac{1}{30}$ c.

For the spherical and cylindrical surface would require to have a negative focal distance of 30″, and the axis of the cylindrical surface would have to be placed horizontally.

2. Compound hypermetropic astigmatism (H + Ah). Hypermetropia exists in both principal meridians, but more in the one than in the other.

In the vertical meridian let H = $\frac{1}{18}$. In the horizontal meridian let H = $\frac{1}{12}$. We have then H = $\frac{1}{18}$, and moreover Ah = $\frac{1}{12} - \frac{1}{18}$ = $\frac{1}{36}$, and we write H $\frac{1}{18}$ + Ah $\frac{1}{36}$. Hence a positive spherico-cylindrical lens will be required, and it will be corrected by $\frac{1}{18}$ s $\supset$ $\frac{1}{36}$ c. The axis of the cylindrical surface being placed vertically.

III. Mixed astigmatism. In this form, in which myopia exists in the one principal meridian, and hypermetropia in the other, we must make use of bi-cylindrical glasses. These consist of two cylindrical surfaces of curvature, the axes of which are perpendicular to one another; the one surface is concave, the other convex. In consequence of this, the effect of such lenses is to render parallel incident rays divergent in the plane of one axis, and convergent in that of the other. The axis of the concave surface must be placed in the direction of the hypermetropic meridian, and the axis of the convex surface in the direction of the myopic meridian. Their action may be expressed by the formula for each of the two planes, united by a sign of a right angle ⌐.

1. Mixed astigmatism, with predominant myopia (Amh).

In the vertical meridian let M = $\frac{1}{10}$. In the horizontal meridian let H = $\frac{1}{20}$. Therefore Amh = M $\frac{1}{10}$ + H $\frac{1}{20}$ = $\frac{1}{6\frac{2}{3}}$, and is corrected by $\frac{1}{20}$ c ⌐ $-\frac{1}{10}$ c.

The axis of the convex surface to be placed vertically, that of the concave horizontally.

2. Mixed astigmatism, with predominant hypermetropia (Ahm).

In the vertical meridian let M = $\frac{1}{18}$. In the horizontal meridian let H = $\frac{1}{12}$. Therefore Ahm = H $\frac{1}{12}$ + M $\frac{1}{18}$ = $\frac{1}{7\frac{1}{5}}$, and is corrected by $\frac{1}{12}$ c ⌐ $-\frac{1}{18}$ c.

The axis of the convex surface to be placed vertically, that of the concave surface horizontally.

These examples illustrate the method to be adopted in finding glasses to correct the astigmatism and the ametropia. But in many cases it is not advisable completely to neutralize the anomaly of refraction, both on account of the difference in the size of the retinal images which will occur if the lenses are strong, and also on account of the disturbance in the combined action of the ciliary muscle and the internal recti muscles. It is often desirable that the astigmatism should be wholly corrected, but that only a certain portion of the myopia or hypermetropia should be neutralized.

After the operation of extraction of cataract, the sight is often materially improved by cylindrical lenses, even although before the opacity of the lens, the sight had been perfectly normal. Such cases can only be explained on the supposition, that a certain degree of corneal astigmatism had been neutralized (compensated for) by some lenticular astigmatism, so that when the lens is absent, the ill-effects from the corneal astigmatism make themselves felt. This condition must of course be distinguished from the acquired astigmatism due to a faulty cicatrization of the section. In all cases of extraction, in which the sight is not as good as might be expected from the general appearance of the eye, the presence of astigmatism should be looked for, and the effect of cylindrical lenses tried.

It is of great consequence, that the axes of the surfaces of curvature of the cylindrical glasses should be situated in the principal meridians of the eye, for even a very slight deviation will give rise to considerable indistinctness of vision. In order to insure the exact adaptation of the glasses to the eye, the lenses should be set in round frames, which permit of their being readily rotated in any direction. When the proper position of the axis is found, the screw should be tightened, and the lens thus firmly fixed in the desired position. The clumsy and awkward appearance of the circular frames may be greatly diminished by making them of a smaller diameter, or by having the glasses ground down into oval ones, and then reset into oval frames. But this requires great exactitude and nicety.

Irregular astigmatism depends sometimes upon irregularities in the curvature of the cornea, such as occur from thinning of the cornea after corneitis, in conical cornea, and a faulty union of the section in extraction of cataract. Irregularities in the structure of the lens, or displacement of the latter, so that its edge lies partially in the area of the pupil, may also give rise to this form of astigmatism. On account of these irregularities in the cornea or lens, the refraction of luminous rays is much distorted, for not only do the rays in a certain diameter undergo irregular refraction, but even perhaps individual rays in the same diameter. The retina, therefore, receives a very confused and blurred image, and hence there is always a considerable impairment of

vision, the object looking crooked and distorted. Not unfrequently there is marked monocular diplopia or polyopia. Whilst this irregular astigmatism cannot be corrected by cylindrical glasses, it is often susceptible of improvement by stenopaic spectacles, which, by excluding a large portion of the irregularly refracted rays, render the image less distorted and confused.

8.—APHAKIA (ABSENCE OF THE CRYSTALLINE LENS).

This condition may be due to an operation for cataract (*e.g.*, extraction, division, or reclination), to absorption of the lens after traumatic cataract, or dislocation of the lens into the vitreous humour, etc. The state of refraction is of course greatly altered by absence of the lens. Thus, an emmetropic eye becomes strongly hypermetropic; a hypermetropic eye still more so; whereas, a myopic eye will become less short-sighted, or, if the degree of myopia was very great, it may even become emmetropic. The power of accommodation is completely absent in aphakia. This has been now incontrovertibly proved by Donders' numerous and most exact experiments.

The acuteness of vision even after the most successful operations for cataract, and with the aid of the most suitable glasses, does not usually reach the normal standard. In old persons, this is frequently due to certain senile changes which take place in all eyes, and often considerably deteriorate the sight. Another not unfrequent cause is to be found in the presence of secondary cataract, or even in the wrinkling of the transparent capsule, which may produce considerable distortion and confusion of the retinal image.

Patients who have been operated upon for cataract, require very strong convex glasses to neutralize the acquired hypermetropia. The strength of these glasses will vary according to the degree of the hypermetropia, *i.e.*, the length of the optic axis; for the shorter the latter is, the stronger will the lens require to be. Two sets of glasses will be wanted, one for distant objects, and one for reading, sewing, etc. For the former purpose, the number generally ranges from 4″ to 5″ focus, for the latter from 2″ to 2½″ focus. But as this varies considerably, different numbers must be tried until the best is found, and it must be remembered that in these lenses of high power, a slight difference may exert a very considerable effect upon the sight. In order to remedy the great spherical and chromatic aberration of light, which is produced in these lenses from the difference in their thickness at the centre and at the periphery, such spectacles are generally set in a broad horn or tortoise-shell frame, which leaves only the more central portion of the glass exposed.

9.—PARALYSIS, SPASM, AND ATONY OF THE CILIARY MUSCLE.

Diminution or loss of accommodation from paralysis or atony of the ciliary muscle is occasionally met with after severe illnesses, the whole muscular system being greatly debilitated. In such cases, it is not unfrequently mistaken for amblyopia dependent upon general debility. It is also often met with after diphtheria, and appears to depend less upon general constitutional weakness, than upon some special and peculiar cause, the exact nature of which is yet undetermined.

The symptoms of paralysis of the accommodation are very marked in emmetropic eyes. The patients find that they cannot accurately distinguish near objects, so that they are quite unable to read, write, or sew; but at a distance they can see distinctly. The far point has undergone no change of position, but the near point has receded further from the eye. If we test the sight with a convex lens of 6″ focus, we find perhaps that the near point has receded to 5″ or $5\frac{1}{2}$″ from the eye, and that the far point lies at 6″ (the focal distance of the lens), hence that the power of accommodation is almost entirely lost. The position of the near point will of course vary with the degree of paralysis; if this is but slight (paresis), the near point may be but little removed from the eye, and the disturbance of vision but inconsiderable. If there is complete paralysis, the patients cannot generally distinguish any print smaller than No. 14 or 16 of Jäger, but can easily read the finest type with strong convex lenses. The sight is much less affected in short-sighted persons, for if the myopia $= \frac{1}{12}$ or $\frac{1}{14}$, they are still able to read at their far point (12″ or 14″), as only the near point undergoes a change, and the far point lies sufficiently close to the eye to permit of small objects being seen distinctly. In hypermetropic patients it is, however, quite different, for in them both the near and distant sight is impaired, just as after the instillation of atropine. In incomplete paralysis, the symptoms often resemble those of asthenopia, and the true nature of the affection may be easily overlooked, if the range of the accommodation is not examined. Together with the paralysis of the accommodation, there is almost always paralysis of the constrictor pupillæ, and consequent dilatation of the pupil, as both muscles are supplied by the third nerve; and frequently other muscles of the eye, supplied by this nerve, are also affected. In trying the sight, attention should be paid to this dilatation of the pupil, and the consequent presence of circles of diffusion upon the retina, and the patient should be directed to read through a small stenopaic opening.

The treatment of cases of paralysis of the ciliary muscle must depend upon the cause. If the patient has been suffering from diph-

theria or any debilitating disease, tonics must be our chief remedy. In the rheumatic form (due to exposure to cold or draught) or the syphilitic, iodide and bromide of potassium are of much use, as also a suppurating blister behind the corresponding ear. I have often found the most marked and speedy benefit from the latter remedy, so that a patient, who before could only decipher letters of 14 or 16 of Jäger, was able, within 24 or 48 hours after the application of the blister, to read the finest print. I have also used the solution of the extract of Calabar bean with excellent results. I employ it of a strength sufficient to cause considerable contraction of the ciliary muscle and constrictor pupillæ, without, however, over-straining, and thus fatiguing, these muscles. I then allow the effect to pass off entirely, and after a few days' rest, the extract is re-applied, so that the muscles may be periodically stimulated. The action of the Calabar bean, and its peculiar effect upon the pupil were fully investigated in 1862, by Dr. Fraser,* in his valuable graduation thesis for the University of Edinburgh, on the "Characters, Actions, and Therapeutic uses of the Ordeal Bean of Calabar." And in 1863, Dr. Argyle Robertson discovered its effect upon the accommodation.†

On the application of a minute quantity of a strong solution (1 drop = 4 grains of the bean) to the inside of the lower eyelid, a little irritation and redness are produced, but these pass off very rapidly. Within five or ten minutes the pupil begins to contract, and at nearly the same time, the spasm of the ciliary muscle commences. The contraction of the pupil reaches its maximum degree (about 1‴ in diameter) in from 30 to 45 minutes. After two or three hours it gradually dilates again, but does not regain its normal size till after the lapse of two or three days, when it may even become larger than before. Even during its greatest contraction, the pupil is still under the influence of light.

The spasm of the accommodation commences about the same time as the contraction of the pupil, and both the near and far point become greatly approximated to the eye, which becomes, in fact, strongly myopic. The far point in the emmetropic eye may be brought to 5″ or 6″ from the eye, and the near point to 3″ or 3½″. The effect upon the accommodation passes off much sooner than that upon the pupil, for three or four hours generally suffice to restore the state of refraction and accommodation to its normal condition.

* Further investigations on the physiological action of the Calabar bean are contained in a more recent paper by Dr. Fraser, in the "Transactions of the Royal Society of Edinburgh," vol. 24.

† Shortly after this discovery of Dr. Argyle Robertson, I had the opportunity of carefully studying the effect of the Calabar bean upon a case of paralysis of the ciliary muscle; a full account of which will be found in the "Med. Times and Gazette," May 16, 1863.

That the spasm of accommodation is due to the action of the drug upon the muscles of accommodation, and not upon the iris, was incontrovertibly proved by Von Graefe,* who tried its effect in a case of complete absence of the iris, and found that the action upon the accommodation took place at about the same time, and in exactly the same manner, as in eyes in which the iris was present. This action of the Calabar bean is, therefore, exerted upon the ciliary muscle, and is completely independent of its effect upon the iris.

The effect of the Calabar bean in counteracting the action of atropine, has also been proved by many experiments. The weaker solutions of atropine are easily overcome by a strong solution of Calabar. But the complete paralysis of the accommodation by a strong solution of atropine (4 grains to the ounce) is only temporarily overcome even by a very strong solution of Calabar, 1 drop = 4 grains; the pupil becomes smaller, and the state of refraction increased, but the action of the atropine re-asserts itself in the course of a few hours. In such cases, we must repeat the application of the Calabar when necessary, until the effect of the atropine upon the accommodation has disappeared.†

Great fatigue of the ciliary muscle through over exertion at near objects, may give rise to very severe symptoms of asthenopia, and this is best treated by the use of strong convex glasses (6 to 10 inches focus), for reading, etc. After they have been used for some time, the accommodation should be gradually exercised by using weaker glasses, the distance of the object remaining the same. The accommodation may also be rested by the application of a strong solution of atropine continued for some little time.

Spasm of the ciliary muscle is of rather rare occurrence, and is especially met with in cases of hypermetropia in youthful persons, who have strained their eyes without using convex glasses; this continued tension of the accommodation producing a spasmodic contraction of the ciliary muscle. In such cases, we find that the patient is apparently suffering from myopia, requiring concave glasses for distant objects, and yet, on examining his eye with the ophthalmoscope, the refraction is found to be hypermetropic. The use of a strong solution of atropine has frequently to be continued for several days, before the ciliary muscle can be completely paralysed. This paralysis and complete rest of the accommodation must be continued for several weeks.

* "A. f. O.," ix, 3, 113.

† Instead of the extract, the more elegant preparation of the gelatine discs may be employed. But these do not answer so well when we wish to stimulate the partially paralysed muscle, as we cannot regulate the strength so exactly as in the solution.

10.—SPECTACLES.

The spectacles which are generally used for the purpose of correcting some optical defect in the eye are either spherical or cylindrical lenses, or a combination of both. The properties of such lenses have been already sufficiently explained (pp. 489 and 534) and I shall, therefore, now only add a few remarks as to the different kinds of spectacles and their construction.

From the perusal of the different anomalies of refraction and accommodation, the reader will have been sufficiently impressed with the importance of the proper and scientific selection of spectacles. I have no hesitation in saying that the empirical, haphazard plan of selection generally employed by opticians, is but too frequently attended by the worst consequences; and that eyes are often permanently injured, which might, by skilful treatment, have been preserved for years. For this reason, I must strongly urge upon medical men the necessity of not only examining the state of the eyes, and ascertaining the exact nature of the affection of refraction or accommodation, but of going even a step further than this, and determining with care and accuracy the number of the required lens. For this purpose they must possess a case of trial-glasses,* containing a complete assortment of concave and convex lenses, glasses of corresponding number being kept by the optician. Written directions as to the focal distance of the required glass, and whether it is for distance or for reading, are to be sent to the optician.

The strength of any given convex lens may be easily ascertained by finding the distance at which the image of a distant object (a candle, the bars of a window frame, etc.), is distinctly formed on a sheet of white paper or the wall. The distance of this distinct image from the lens, gives the focal length of the latter. But if we have a set of trial

* Such trial cases are made by Messrs. Paetz and Flohr, of Berlin, and contain complete sets of concave and convex lenses, prismatic and tinted glasses, and a clip spectacle frame for holding the lenses. These lenses are defined in the Prussian inches, which are almost identical with the English; whereas the French are considerably more. As the arrangement of the lenses in these trial cases is, however, made without any system, so that whilst there are very many and but slight gradations in the weaker glasses, those in the stronger are not sufficiently numerous, the difference in the refraction of the higher numbers is very great. Thus, whilst the difference in the refraction between convex 60 and 50 is only $\frac{1}{300}$, that between $3\frac{1}{4}$ and 3 is $\frac{1}{39}$. To remedy these defects, as well as to simplify the trial cases, and greatly diminish the number of lenses, Zehender has proposed a new combination scale of glasses (vide "Klin. Monats.," 1866). As a member of the International Refraction Committee, appointed by the Ophthalmological Congress in 1867, I may mention here, that it is very probable that the mètre measure will be substituted for that of inches in the determination of the strength of lenses, in order that their number may be the same in all countries.

glasses at hand, a more simple and ready mode is to find the concave lens which completely neutralizes the convex one, and this at once gives us the number of the latter.

The complete neutralization of the convex lens by the concave is known by the fact that if the two are placed in close apposition, we can read as well through them as without any glass before the eye. Another test is, that if we regard a vertical line (*e.g.*, the vertical bar of a window) through them, it remains perfectly immoveable when the glasses are moved to and fro before the eye. Whereas, the line will distinctly move if the two glasses do not neutralize one another, the more so, the greater the difference between them. If the object moves in the contrary direction to that in which the lenses are moved, it proves that the convex lens is the stronger of the two; whereas, if it moves in the same direction, the concave is the stronger. The strength of concave lenses may be tried in the same way.

Care should be taken that the spectacles fit accurately; that the glasses are on the same level, so that one is not higher than the other; that they are sufficiently close to the eyes, and that the centre of each glass is exactly opposite the centre of the pupil. The last point should be particularly observed in the selection of glasses which fit on to the nose by means of a spring (pinces nez), for we find that, on account of their oval shape, these generally are not accurately centred. If they do not fit properly, so that their centre corresponds to the centre of the pupil, they act as prisms, and give rise to diplopia or a correcting squint, and the latter may even become permanent, if their use is persisted in. Concave glasses should be quite close to the eye, otherwise they will diminish the size and distinctness of the retinal image. As the rays which impinge upon a concave lens are rendered divergent by it, it follows that the further the glass is removed from the eye, the fewer peripheral rays will enter the latter, in consequence of which the retinal image is diminished in size and intensity.* The reverse obtains in the case of convex glasses, for as they render the rays which impinge upon them more convergent, a greater number of peripheral rays will enter, the further (up to a certain point, of course) the convex glass is removed from it, the retinal image becoming at the same time larger and brighter.

Single eye glasses should not, as a rule, be permitted, as they often lead to weakness of the other eye from non-use.

Besides the spherical and cylindrical spectacles we must also consider the following kinds:—

* It has already been stated that concave glasses diminish the retinal image by moving the nodal point further back, thus diminishing the angle of vision; whereas, convex glasses enlarge the retinal image, as they move the nodal point forwards, and thus increase the size of the angle of vision.

The periscopic glasses consist of concavo-convex, and convexo-concave lenses (so called positive and negative menisci), and consequently have only a very slight spherical aberration. On this account, when the concave surface is turned towards the eye, there is less irregular refraction at the edge of the glass, so that the regularity of the images is much less impaired. In consequence of this, the observer can look more obliquely through them, as was first shown by Wollaston, who on this account termed them periscopic. Their chief disadvantages are that they reflect the light more, and are also more heavy and expensive than spherical lenses.

Spectacle glasses are sometimes required to have a different focus in the upper and lower part (*pantoscopic spectacles*). This is more especially the case if presbyopia co-exists with myopia or hypermetropia. Thus Franklin, who was presbyopic and also slightly myopic, employed glasses, the lower half of which was convex, to neutralize the presbyopia, and the upper half concave, to neutralize the myopia. In Paris such glasses are termed *verres à double foyer*, and are constructed by grinding in the upper part of the spectacle-glass, the surface which is turned from the eye, with another radius. Such spectacles must be placed at a proper height before the eyes, so that in looking at near objects the rays only fall upon the eye through the lower part, whereas, those from distant objects must only fall upon the upper part. This form of spectacle is found very useful by miniature painters, lecturers, etc.

Prismatic spectacles are sometimes employed either for the purpose of exercising and thus strengthening certain of the muscles of the eyeball, or to relieve them. The action of prisms has been already explained in the introduction (p. 10), and the use of prismatic spectacles will be found described in the article upon muscular asthenopia. The prisms are generally turned with their base inwards (to relieve the internal recti muscles), and may either be used alone or in combination with convex or concave lenses. In the latter case, they are ground in such a manner as to combine the effect of a prism with that of a spherical lens. By turning the base of the prism inwards, the rays will be deflected somewhat to the inner side of the yellow spot, the eye will consequently move slightly outwards so as to bring the rays again upon the yellow spot; there will consequently be a less convergence of the optic axes, the effect being the same as if the object were placed somewhat further off, but it is seen under the same visual angle, and divergence of the rays is also the same.

Closely allied to the prismatic glasses, are the decentred lenses of Giraud Teulon. They are constructed in such a manner, that the eccentric portions of two convex lenses are used instead of the centre, so that they may thus acquire a slightly prismatic action. Thus in convex

lenses the centre should lie a little to the inner side of the visual lines, whereas in concave glasses the reverse obtains, and the centre should lie a little to the outer side of the visual lines.

Dr. Scheffler proposes to substitute for the common spherical lenses, glasses which are cut out from the periphery of a large lens, in such a manner as to act as decentred lenses. The advantage which he claims for them is, that with them the convergence of the optic axes undergoes an alteration in harmony with the change in the accommodation, which is not the case when the common spherical lenses are used. His work "Die Theorie der Augenpfehler and der Brille," in which this subject is fully treated, is being translated into English by Mr. R. B. Carter.

Eye-protectors are found of much service to guard the eye against very bright light, dust, or cold winds. The best are the medium blue curved eye-protectors. They are curved somewhat like a watch glass, so as to fit closely, except at the temporal side, where they permit a sufficient amount of air to enter and come in contact with the eye, to maintain the evaporation of the conjunctival moisture. They are greatly to be preferred to the goggles with wire or silk sides, or the glass spectacles with large glass side pieces, for these keep the eye much too hot and close. The goggles are useful if the patient is exposed to the atmosphere very soon after a severe operation, when the eye is still inflamed and very susceptible to cold, but for all other purposes the curved glasses are to be preferred.

The sense of dazzling of which many (more especially myopic) patients complain when they are exposed to bright sun or gas light, is most effectually relieved by cobalt blue glasses. It was formerly supposed that the red rays of the solar spectrum were the most trying to the eye, and consequently green glasses (which exclude the red rays) were much in vogue. But it is now a well known fact, that it is not the red but the orange rays which are irritating to the retina, and as blue excludes the orange rays this is the proper colour for such spectacles. Moreover, the blue colour, on account of its more eccentric position in the solar spectrum, makes a less impression upon the retina. Smoke-glasses are not so good, as they more or less subdue and diminish the whole volume of light and colour, and thus render the image somewhat indistinct.

It is often very desirable to combine the blue tint with the use of convex or concave spherical lenses; in the weaker glasses this can be very effectually done, but in the higher numbers it is difficult, for the varying thickness of the glass causes a considerable difference in the tint in the centre and at the edges of the lens. In such cases, it will be well to adopt Mr. Laurence's suggestion, viz., to join a very thin piece of plain tinted glass with Canada balsam, to the back of a colourless spherical lens.

Besides the coloured eye-protectors which are used in order to diminish the bright glare of light, or to keep off the cold wind, dust, etc., there are those which are used by workmen in order to protect the eye during their work against injury from pieces of stone, chips of steel, etc. The best are those made of thick plate glass, with wire or gauze sides, for they are sufficiently strong to resist the force of any, excepting a very large projectile. The chief objections to these are their expense and their weight. To obviate these defects, Dr. Cohn* has recommended the use of spectacles made of mica instead of glass. If the mica is of good quality, it is quite as transparent as glass, but lends a faint grey tint to objects, which does not, however, in the least diminish the acuity of vision, but rather tempers the light. They are made in the shape of the large curved eye-protectors, and should fit quite close to the eye, leaving only the temporal side somewhat open. They are much lighter and cheaper than the glass spectacles, and do not break on falling down.

11.—DIFFERENCE IN THE REFRACTION OF THE TWO EYES.

Differences in the refraction of the two eyes are not of unfrequent occurrence, and generally consist in differences in the degree of the myopia or hypermetropia in the two eyes; or, again, one eye may be emmetropic, the other myopic or hypermetropic; or myopia may exist in one eye, and hypermetropia in the other. Absence of the lens (aphakia) in one eye, gives rise of course to a very great difference in the state of refraction of the two eyes. In the majority of cases, the refraction of the two eyes is very nearly alike. Sometimes, however, we find considerable differences in the degree of myopia or hypermetropia. The practical question is, what kind of glasses are we to give to such patients? It might appear proper to furnish each eye with the glass suitable to its own state of refraction, but in practice we find that this does not generally answer, for the patients, as a rule, complain that such spectacles render their vision confused and indistinct, on account of the difference in the size of the two retinal images. It is best, therefore, to furnish both eyes with the glass which suits the least ametropic (hypermetropic or myopic) eye. If it is very desirable that the patient should enjoy the greatest possible acuteness of vision, we may give two different glasses, so as completely to neutralize the difference in the state of refraction, and the patient must try whether he is able to see distinctly and comfortably with them. Sometimes a little practice will enable him to do so, and then their use may be allowed. If this is not

* Berliner Klinische. Wochenschrift, Feb. 24, 1868.

the case, we may partially neutralize the difference, and thus diminish the size of the circles of diffusion. Thus if the myopia of the one eye $= \frac{1}{14}$, and that of the other $\frac{1}{6}$, we may prescribe concave 15 for the former, and concave 9 or 10 for the latter. It has also been advised that when the sight of the two eyes (which differ considerably in the degree of their myopia) is equally good, the glass which lies midway between the two degrees of myopia should be given for both. If, for instance, the one eye requires concave 4 and the other concave 8, it would be advisable to prescribe concave 6 for both eyes. But such glasses prove unsuitable, as they suit neither eye, being too strong for the one, and too weak for the other.

If there is a difference in the refraction of the two eyes—the one being myopic, the other hypermetropic—it is also often difficult to suit them with glasses which shall neutralize each anomaly. This is owing to the difference in the size of the retinal images which will be produced, for the convex lens will enlarge, the concave lens diminish, the size of the retinal image, and this may prove a source of considerable confusion. In all cases of difference in the refraction of the two eyes, the patients should try the glasses for some little time, so as, if possible, to become accustomed to them, before we decide definitely as to the kind of glasses which we shall prescribe.

Chapter XIV.

AFFECTIONS OF THE MUSCLES OF THE EYE.*

1.—ACTIONS OF THE MUSCLES OF THE EYE.

In order properly to understand the physiological action of the different muscles of the eyeball, we must consider the eye as a sphere, the centre of which being fixed, its movements can only be rotations around a fixed axis, and hence there can be no change of locality. But for the purpose of accurately determining these rotations, it does not suffice to ascertain the change of position which *one* point upon the surface of the sphere may undergo, but we must take into consideration the position of a *second* point, which must not, however, stand in the relation of a pole to the first. If we take the centre of the cornea for the one point, and the vertical meridian (the greatest circle standing perpendicular to the equator of the eye) as the second, we shall be easily able to determine the rotations which the eye undergoes, by watching in which direction the centre of the cornea moves, and what kind of inclination the vertical meridian undergoes.

For the purpose of discovering the inclination of the vertical meridian in the different positions of the eye, Donders devised the following ingenious experiment. Having vertically suspended a coloured thread, he looked at it until its image was impressed upon his retina (this image was of course in the vertical meridian of the eye), he then moved his head in the different directions in which he desired to ascertain the inclinations of the vertical meridian, and then measured the angle which the image upon his retina formed with a line held vertically before his eye. As the position of the retinal image of course agreed with that of the vertical meridian, he was enabled in this way readily to ascertain the direction of the vertical meridian in every movement of the eyeball.

* For further information upon the diseases of the muscles of the eye, I must refer the reader to Von Graefe's articles in the "A. f. O.," vols. i and iii; and Alf. Graefe's "Motilitäts-störungen des Auges;" also to my articles in the "R. L. O. H. Rep.," vols. ii and iii; and in the "Med. Times and Gazette," 1865.

I must here point out that from habit we see objects vertical and not slanting, even although the vertical meridian should be inclined.

Based upon these experiments, Donders laid down the following rules as to the position of the vertical meridian in the different movements of the eye :—

1. In looking in the horizontal meridian-plane, straightforwards, to the right or to the left, the vertical meridian suffers no inclination, but remains vertical.

2. In looking in the vertical meridian-plane, straightforwards, upwards, or downwards, the vertical meridian also remains vertical.

3. In looking diagonally upwards to the left, the vertical meridians of both eyes are inclined* parallelly to the left (that of the left eye slanting outwards, that of the right inwards).

4. In looking diagonally downwards to the left, the vertical meridians of both eyes are inclined parallelly to the right (that of the left eye inwards, that of the right outwards).

5. In looking diagonally upwards to the right, the vertical meridians of both eyes are inclined parallelly to the right (that of the right eye outwards, that of the left inwards).

6. In looking diagonally downwards to the right, the vertical meridians of both eyes are inclined parallelly to the left (that of the right eye inwards, that of the left eye outwards).†

For the sake of simplicity, we may consider the muscles which move the eyeball as consisting of three pairs ; the two muscles of each pair acting in an antagonistic way to each other.

In order to ascertain the direction in which a muscle acts, we must draw through it a straight line which shall unite the middle of its origin with the middle of its insertion. A plane laid through this line and the turning-point of the eye, is termed the *plane of the muscle (muscle-plane)*, and a line standing perpendicular upon this plane in the turning-point, is called the *axis of turning*. Now we shall find it of the greatest importance in the paralyses of the different muscles of the eyeball, to know in which positions of the eye certain muscles act most upon the height of the cornea, and in which positions most upon the vertical meridian. We shall find that the effect upon the height of the cornea is the greater, the more the muscle-plane coincides with the vertical meridian-plane, and the more the axis of turning approaches the horizontal diameter. On the other hand, the power over the vertical meridian will be least in this position, but will increase in proportion as the eye is turned in the opposite direction, for the axis of turning then approaches more and more the position of the optic axis.

* The *upper* end of the vertical meridian line is the one always described.

† These rules have been translated from Alfred Graefe's excellent work, "Klinische Analyse der Motilitäts-störungen des Auges."

Let us now consider the action of the different muscles upon the position of the eyeball and the direction of the vertical meridian.

The superior rectus muscle arises from the portion of bone just in front of the optic foramen, and runs obliquely over the globe to be inserted into the sclerotic, about three lines from the cornea. But its course is so oblique, that the internal portion of its insertion lies almost one line nearer the cornea than its external portion. Its action is to move the eye upwards and slightly inwards, inclining the vertical meridian inwards.

The inferior rectus also arises from the optic foramen, and its tendon is inserted about three lines from the lower edge of the cornea, but somewhat (about half a line) to the inner side of a supposed vertical line drawn through the centre of the cornea. It moves the eye downwards and inwards, and inclines the vertical meridian outwards.

The superior and inferior recti exert most influence upon the height of the cornea, when the eye is turned outwards, as the muscle-plane then coincides more and more with the meridian-plane, and the axis of turning approaches the horizontal diameter. These muscles act most upon the inclination of the vertical meridian, when the eye is turned inwards, as the axis of turning then approaches more and more the optic axis.

The external rectus arises from the common tendon, and runs along the outer side of the eyeball to be inserted about three lines from the external edge of the cornea. It moves the eye directly outwards, without producing any inclination of the vertical meridian.

The internal rectus is the strongest of the ocular muscles and nearly four lines in width; it arises from the common tendon, and is inserted into the sclerotic about $2\frac{1}{2}$ lines from the inner edge of the cornea. It moves the eye directly inwards, and does not incline the vertical meridian.

The superior oblique arises just in front of the inner portion of the optic foramen, and runs along towards the inner angle of the eye, where its tendon passes through the trochlea, and then, bending outwards and backwards, it spreads out like a fan to be inserted into the upper, outer and posterior quadrant of the eyeball, by a tendon three lines in length, the convexity of which looks backwards. The action of the superior oblique is to roll the eye downwards and outwards, and to incline the vertical meridian inwards.

The inferior oblique arises from a depression in the orbital edge of the superior maxillary bone, slightly towards the outer side of the lachrymal sac, and passes along the floor of the orbit in an outward, downward, and backward direction, until it has passed beneath the inferior rectus (to which it is connected by fibro-cellular tissue), when it curves upwards and backwards, and passes to the inner side of the

external rectus, to be inserted by a short tendon close to the insertion of the superior oblique. The inferior oblique rolls the eye upwards and outwards, and inclines the vertical meridian outwards. The two oblique muscles act most upon the height of the cornea when the eye is moved inwards, as their muscle-plane then coincides more and more with the meridian-plane; whereas, they act most upon the inclination of the vertical meridian when the eye is turned outwards, for then the axis of turning approaches more and more the optic axis.

Having described the action of the individual muscles, we must now pass on to the consideration of the movements of the eye which are produced by the combined action of several muscles. In so doing, we have to consider the following eight different movements of the eye:—

1. The movement vertically upwards, in which the vertical meridian remains vertical, is brought about by the action of the superior rectus and inferior oblique. The superior rectus alone, draws the cornea upwards and inwards, and inclines the vertical meridian inwards, hence some other muscle (inferior oblique), whose action is to draw the cornea upwards and outwards and incline the vertical meridian outwards, must associate itself with the superior rectus, in order to counterbalance its action.

2. In moving the eye diagonally upwards and inwards, the vertical meridian being inclined inwards, the superior rectus is chiefly associated with the internal rectus. But as the latter has no effect upon the vertical meridian, the superior rectus would incline it too much inwards, and hence disturb its parallelism with the vertical meridian of the other eye (which is inclined outwards). Some other muscle, whose action is to incline the vertical meridian outwards, must, therefore, be called into play, in order to check the action of the superior rectus. We shall again find in the inferior oblique the muscle required; moreover, on account of its having least influence on the vertical meridian when the eye is turned upwards and inwards, it will not over-correct the action of the superior rectus, but only limit it.

3. In moving the eye diagonally upwards and outwards, the vertical meridian being inclined outwards, the superior rectus acts in conjunction with the external rectus. But as the latter has no influence on the position of the vertical meridian, and as the internal rectus turns it inwards, we must call into requisition some other muscle, which shall not only counterbalance the effect of the superior rectus upon the vertical meridian, but shall even more than correct it, and incline the latter outwards. The inferior oblique will be able to do this, for the eye is now in the position (upwards and outwards) in which the inferior oblique acts most upon the vertical meridian.

4. The movement vertically downwards, the vertical meridian remaining vertical, is produced by the combined action of the inferior

rectus and superior oblique. The action of the inferior rectus alone, would be to draw the eye downwards and inwards, and to incline the vertical meridian outwards, hence it must be associated with the superior oblique, whose action is to move the eye downwards and outwards, and to incline the vertical meridian inwards, and thus to counterbalance the inferior rectus.

5. In the movement diagonally downwards and inwards, the vertical meridian being inclined outwards, the inferior rectus is associated with the internal rectus, and the superior oblique is required to limit the effect of the inferior rectus upon the vertical meridian, and to preserve the parallelism of the meridians.

6. In the movement diagonally downwards and outwards, the vertical meridian being inclined inwards, the inferior rectus is associated with the external rectus, and the superior oblique is called into play, not only to counterbalance the effect of the inferior rectus upon the vertical meridian, but to over-correct this, and incline the latter inwards.

7. The movement directly outwards is produced by the action of the external rectus.

8. The movement directly inwards is produced by the action of the internal rectus.

The following tabular arrangement will enable the reader to remember more easily the manner in which the different movements of the eye are produced:—

Movement.	Is produced by the action of the
Upwards	Superior rectus and inferior oblique.
Downwards	Inferior rectus and superior oblique.
Inwards	Internal rectus.
Outwards	External rectus.
Upwards and inwards	Superior rectus, internal rectus, and inferior oblique.
Upwards and outwards	Superior rectus, external rectus, and inferior oblique.
Downwards and inwards	Inferior rectus, internal rectus, and superior oblique.
Downwards and outwards	Inferior rectus, external rectus, and superior oblique.

The effect of the recti muscles is to draw the eye *into* the orbit, that of the oblique muscles is to draw it out.

The nerves supplying the muscles of the eye, are the third, fourth, and sixth.

The third nerve supplies the superior, inferior, and internal rectus,

the inferior oblique, the levator palpebræ superioris, the constrictor pupillæ, and the ciliary muscle.

The fourth nerve supplies the superior oblique.

The sixth nerve supplies the external rectus.

There are two different kinds of binocular movements, viz., the associated and the accommodative. In the former, the optic axes (strictly speaking the visual lines) remain parallel, whereas, in the accommodative movements they converge towards each other, and meet in the object. When the muscles of both eyes are quite at rest, the angle formed by the visual lines of the two eyes is called the muscular mesoropter; and the convergence of the visual lines is such, that their prolongation would meet at a point varying from 8′ to 12′ in front of the eyes. I must here mention the fact, that in looking downwards there is always an increased tendency to convergence, whereas, in looking upwards there is a greater tendency to divergence. Hence a convergent squint becomes more marked when the patient looks downwards, and a divergent squint when he looks upwards.

We have now briefly to consider the symptoms, diagnosis, and treatment of the paralytic affections of the different muscles of the eye, and I shall commence with the simplest and easiest form of paralysis, viz., that of the external rectus muscle.

To prevent needless repetition, and to avoid the chance of any symptom being overlooked, it is always best to follow a certain routine in examining patients supposed to be affected with strabismus, or paralysis of one or more of the muscles of the eye. Such an examination is best begun, by directing the patient (who should hold his head quite straight and immoveable) to follow with his eyes some object, such as a pen or ruler, held at the distance of a few feet, and moved in all directions. Any abnormality in the movement of either eye will thus become at once apparent. We next cover one eye (say the right) with our hand, the patient the while keeping his eyes steadily fixed upon the object, and we then observe whether the left eye remains immoveable, or makes a movement in order to bring its optic axis to bear upon the object. In the latter case, we know at once that this eye had before deviated from the object; thus, if it moves downwards, it before stood too high, and *vice versâ*.

2.—PARALYSIS OF THE EXTERNAL RECTUS MUSCLE (OF THE LEFT EYE).

If the object (a lighted candle) is held in the horizontal meridian-plane about four or five feet in front of the patient, we find that both optic axes are steadily fixed upon it, for upon the closure of either eye

the other makes no movement. The object is then successively moved to the right of the patient, then upwards and downwards, and still both eyes follow it accurately. But when it is moved somewhat to the left side of the median line, we find that the left eye lags behind, thus giving rise to a convergent squint, which increases in proportion as the object is moved further to the left. As the paralysis of a muscle only shows itself when the eye is moved in a direction which calls into action the muscle in question, the paralysis of the left external rectus does not become manifest until the eye has to be moved in a direction to the left of the median line.

In a recent case of complete paralysis of the external rectus, it will be found that when the healthy eye is closed, and the object moved slightly into the left half of the field of vision, the left eye will attempt to follow it, not, however, in a straight, horizontal direction, but by a zig-zag, rotatory movement, brought about by the action of the superior and inferior oblique.

A third symptom is, that the secondary deviation is considerably greater than the primary.* This is a symptom of great importance in distinguishing the paralytic from the common concomitant squint. The deviation of the squinting eye is termed the *primary* deviation. Now if the healthy eye is covered, the other will move in a certain direction to adjust its optic axis upon the object, which movement will be accompanied by an associated movement of the healthy, covered eye, which thus becomes the squinting eye, and this movement of the healthy eye is termed the *secondary* deviation.

To render this more intelligible, let us presume that in our supposed case of paralysis of the left external rectus, the object is moved somewhat to the left side of the patient. At a certain point, a slight degree (say one line) of convergent squint of the left eye will appear, owing to the inability of this eye to follow the object. If we now cover the right eye with our hand, the left will make an outward movement of one line in order to direct its optic axis upon the object, but the right eye will simultaneously make an associated movement inwards of perhaps two-and-a-half to three lines. This secondary deviation (two-and-a-half to three lines) is therefore considerably greater than the primary (one line). The reason of this is easily explained. As the external rectus of the left eye is insufficiently innervated, it demands a greater impulse of the will to bring about this movement of one line, than if the innervation were normal. But this increased impulse also affects the associated, healthy, internal rectus of the right eye, and thus produces a

* To watch the position of the eye excluded from participation in the act of vision, a slip of slightly frosted glass should be placed before the one eye, instead of covering it with the hand; for whilst this prevents the patient from seeing, it does not prevent our observing the position of the eye.

greater amount of movement in this eye. Hence, it is an invariable rule in all cases of paralysis, that the secondary deviation considerably exceeds the primary, whereas, in the common concomitant squint the two are exactly equal.

The linear measurement of a squint may be made as follows :—We note a spot upon the lower eyelid, which would correspond to an imaginary vertical line drawn through the centre of the pupil of the squinting eye, when the other eye is fixed upon an object held at from 8″ to 12″ distance. The normal eye is then closed, and the squinting eye directed upon the object, and the spot on the lower lid which now corresponds to a vertical line drawn through the centre of the pupil is again noted, and the distance between the first and second spot gives the linear size of the squint. These spots may be at first marked with a dot of ink upon the lower lid, but a little practice will soon enable us quickly and accurately to estimate the distance between them. This proceeding is illustrated in Fig. 76. *A* represents the mark corresponding to the centre of the pupil when the eye is squinting, *B* the mark corresponding to the centre of the pupil when the eye is fixed upon the object. The distance between *A* and *B* gives the size of the squint.

Fig. 76.

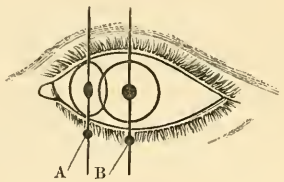

It is, however, still more convenient to employ Mr. Laurence's strabismometer (Fig. 77), which consists of an ivory plate (*P*) moulded to the conformation of the lower eyelid. Its border is graduated in such a manner, that while the centre is designated 0, Paris lines and half lines are marked off on each side of 0. The handle (*H*) is attached to the plate. The plate is applied to the border of the lower eyelid of the squinting eye, and the size of the squint can be read off with great ease and accuracy.

Fig. 77.

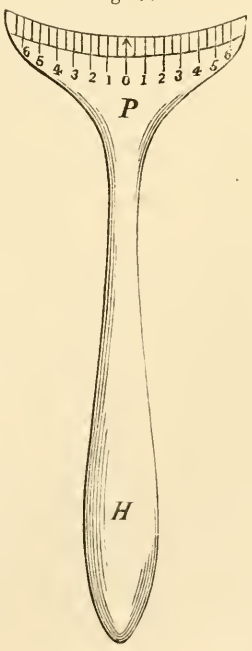

Another symptom which is at once characteristic of a paralytic affection, is the erroneous projection of the visual field. For instance, if we close the right eye and tell the patient to strike quickly with his finger (if he does it slowly he will have time to correct his mistake) at an

object held somewhat towards the left of the median line, he will miss hitting it, by going too much to the left side of it. The reason of this is, that the insufficiently innervated external rectus requires to make a contraction far exceeding the extent of the required movement, and far greater than would be necessary if the innervation were normal. In consequence of this, the patient over-estimates the amount of movement, and believes the object to lie further to the side of the affected muscle than it really does, and consequently strikes too much to the left. If the paralytic affection is not too complicated, the patients in time learn to correct these errors of projection. The dizziness which they often complain of is not necessarily due to a cerebral lesion, but is generally owing to the confusion which arises from the diplopia, etc.

The manner of examining the position of double images, and the action and uses of prismatic glasses, have been explained in the introductory chapter, p. 9.

In a case of paralysis of the external rectus, the diplopia will appear when the object is moved into the left half of the visual field, but will be absent in the right half. The distance between the double images will increase the further the object is moved to the left. The double images show only lateral differences, being parallel, of the same height, and homonymous. It is, however, an interesting fact, that although the external rectus has no *direct* influence upon the vertical meridian, it yet, by assisting in the external diagonal positions of the eyeball, helps in preserving the parallelism of the vertical meridians of the two eyes. For instance, if the patient be directed to look at an object held diagonally upwards to the left, the right eye will be moved into the necessary position by the combined action of the superior rectus, inferior oblique and the internal rectus, its vertical meridian being inclined to the left. The left eye requires, in order to be moved upwards and outwards, the combined action of the superior rectus, the inferior oblique, and the external rectus. But as the latter is paralysed, the left eye will remain almost straight, and its vertical meridian vertical (instead of being inclined towards the left), the parallelism of the vertical meridians is therefore destroyed, and they converge at the top, whilst the double images appear to the patient to diverge at the top. But as in conformity with the laws of normal vision, the image which falls in the slanting meridian of the healthy right eye appears straight to the patient, the image of the affected eye will necessarily appear slanting.

Hence, in the diagonal positions to the left, viz., upwards and outwards, and downwards and outwards, the double images will show not only a difference in inclination, but also in height. As the external rectus is engaged, together with the superior rectus and inferior oblique, in bringing about the movement of the eye diagonally upwards and outwards, its paralysis must impair this, and also affect the position of the

vertical meridian, which, instead of being parallel with that of the right eye, and inclined to the left, will be nearly vertical, and consequently the two vertical meridians will converge at the top, the double images appearing to the patient to diverge. A glance at Fig. 78 will readily explain this.

In Fig. 78, I represents the healthy right eye, whose vertical meridian *A B* is vertical, and whose horizontal meridian *C D* is horizontal, the image *a b* falls in the vertical meridian. II is the left eye affected with paralysis of the external rectus, in the position upwards

Fig. 78.

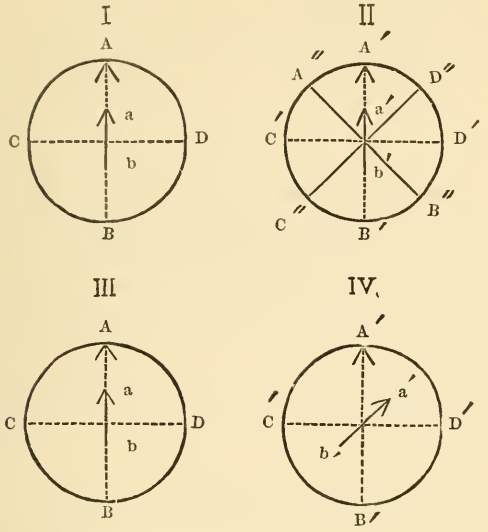

and outwards the vertical meridian *A' B'* is not parallel to that of the right eye, but converges towards it (*A'' B''*). The image *a' b'* will consequently not fall in the vertical meridian, but in the upper and outer (*A'' D''*), and the inner and lower (*C'' B''*) quadrants of the retina. The double image will, therefore, appear to patient to be turned towards the left, and to diverge at the top from that of the right eye (III and IV, *a b* and *a' b'*).

I must here again call attention to the fact that the inclinations of the vertical meridians are merely relative; so that, although in reality the image of the healthy eye may be the one which is inclined, it generally appears to the patient to be straight, and the image of the affected eye is the one which seems to be slanting, although its vertical meridian may remain vertical.

We also meet with a curious phenomenon in this movement (upwards and outwards), viz., a difference in the height of the double images, without any difference in the height of the cornea. This apparent anomaly is easily explained by a glance at Fig. 79. In I the rays from the object will fall on the yellow spot a, but in the left eye

Fig. 79.

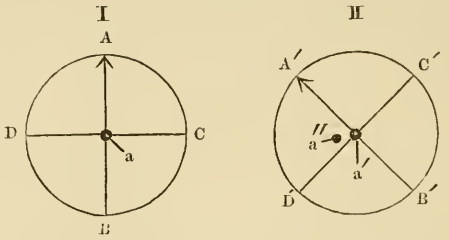

(II), on account of the convergence of the eyes and the inclination inwards of the vertical meridian (A' B'), the rays will not fall upon a', but on a'', a point in the inner and upper quadrant of the retina, and hence the double image will lie to the left side, and below the object. Whereas, in the diagonal position downwards and outwards, the double image will lie to the left and above the object, and be inclined towards the right.

The position of the head is also characteristic, for the patient carries it turned slightly to the left, in order to avoid the diplopia, by bringing all objects as much as possible into the right half of the field of vision.

The prognosis is generally favourable if the paralysis of the external rectus muscle is acute, not too considerable in extent, and not dependent upon a cerebral lesion. Such cases are often completely cured, or very greatly relieved. Sometimes, however, secondary contraction of the internal rectus of the same eye supervenes, on account of the diminished force opposed to the action of the latter muscle. In this way, a permanent convergent squint of this eye may be produced. But if the affected eye enjoys the better sight of the two, and is only suffering from a partial paralysis of the external rectus, the patient may use it, in spite of the effort required, in preference to the other, which will squint considerably inwards, and perhaps permanently so.

In paralysis of the external rectus, a prism would have to be applied with its base to the temple, so that the rays may be refracted outwards; for, on account of the convergence of the optic axis, the rays from the object will fall to the inner side of the yellow spot. Prismatic glasses may be used for two purposes: 1, simply to free the patient from the

annoyance of diplopia; 2, for the purpose of slightly exercising the paralysed muscle, and so gradually strengthening it. In the former case, we prescribe that number of prism which completely neutralizes the diplopia at a certain distance. Whereas, if we desire to exercise the affected muscle, we order a prism which only approximates the double images; this proves very confusing to the patient, and he endeavours, if possible, to fuse them into one by a voluntary exertion of the paralysed muscle. In doing this, care must be taken that the prism is not too weak; at first one should be selected which nearly fuses the double images, and then, as the muscle becomes stronger, a gradually weaker prism may be prescribed.

3.—PARALYSIS OF THE THIRD NERVE.

The third is the principal motor nerve of the eyeball; it divides in the orbit into two branches, an upper and a lower. The former supplies the superior rectus and the levator palpebræ superioris; the latter, the internal rectus, inferior rectus, inferior oblique, sphincter pupillæ, and ciliary muscle. According to Volkmann and Fäsebeck, the third also sends a small branchlet to the superior oblique and external rectus.

The paralysis of the third nerve may vary in degree and extent, and may be complete or partial. 1. All the muscles supplied by it may be more or less implicated; they may be all completely or all partially paralysed; or, again, some may be completely paralysed, whilst the rest are only partially affected. 2. One or more muscles may be completely or partially paralysed, the rest being unaffected.

Before describing the symptoms presented by the isolated paralysis of the individual muscles supplied by the third nerve, it will be well to glance at those which are caused by a paralysis of all the branches of the nerve.

Let us, therefore, suppose the existence of a complete paralysis of the third nerve of the left eye. The following would be the symptoms present in such a case:—The upper eyelid hangs down over the eye; upon lifting it and moving an object in different directions, we find that the eye fails to follow it in the upward, inward, and downward direction. It can still, however, move outwards by the action of the external rectus, and somewhat downwards and outwards by aid of the superior oblique. Generally, secondary contraction of the external rectus soon supervenes, and a marked divergent squint arises, accompanied by crossed diplopia.

If we move the object over to the right of the patient, a divergent squint arises (with crossed diplopia), which increases in proportion as

the object is moved further in this direction. Upon moving the object upwards, the right eye will follow it, but the left will lag behind, the rays from the object will therefore fall upon a portion of the retina below the yellow spot, and the double image be projected above that of the right eye. If the object is moved downwards, the reverse will of course obtain, and the image of the left eye be projected beneath that of the right.

On account of the paralysis of the branch to the sphincter pupillæ, the pupil will be somewhat dilated (about 2 or $2\frac{1}{2}$ lines in diameter), and immoveable. The paralysis of this branch may, however, precede that of general paralysis of the third nerve. Upon the application of atropine, the pupil dilates to its fullest extent. Finally, as the ciliary muscle is paralysed, the eye will have lost its power of accommodation.

If the healthy eye is closed, and the patient directed to walk straight up to a certain object, he becomes giddy and faint, and reels in his gait; which is owing to the illusion which exists in his mind between the real and imaginary position of the object. There is generally some protrusion of the eyeball, on account of the paralysis of the three recti muscles, whose office it is to pull the eye into the orbit.* There is also marked ptosis, but the latter is not so excessive as when the orbicularis pelpebrarum is also paralysed. By relaxing the orbicularis and contracting the frontalis, the upper eyelid can still be somewhat lifted. Although we but seldom meet with a complete, isolated paralysis of the individual muscles supplied by the third nerve, it will be well briefly to consider the symptoms which paralysis of these different muscles would present.

4.—PARALYSIS OF THE INTERNAL RECTUS OF THE LEFT EYE.

When an object is moved from the left to the right side, both eyes will be fixed upon it nearly up to the middle line, but when it is carried over to the right, the left eye will lag more and more behind, thus giving rise to a divergent squint. If the paralysis is complete, and the patient endeavours to move his left eye inwards, a vicarious, rotatory, zig-zag movement inwards will be produced by the action of the superior and inferior recti. As the squint is divergent, the diplopia is

* H. Müller discovered in the inferior orbital fissure a reddish grey mass, consisting of bundles of unstriped muscular fibre with elastic tendons, analogous to the orbital membrane of the mammalia. He supposed that its action is to protrude the eyeball; it is supplied by fibres from the sympathetic, and irritation of the latter in the neck has been found to cause protrusion of the eye, perhaps through the action of this muscle.

crossed, and the lateral distance between the double images will increase in proportion as the object is carried over to the right, but there will be no difference in the height and straightness of the images in looking vertically upwards or downwards. But in the diagonal positions inwards, there will not only be a difference in the height of the double images, but the one will slant considerably. In the oblique position of the object upwards and inwards, the double images will diverge at the top, that of the left eye being inclined to the right. Whereas, in the diagonal position downwards and inwards, the double images appear to converge at the top, that of the left eye being inclined towards the left.

In the diagonal positions inwards, there will also be a difference in the height of the images, even although there is no difference in the height of the cornea. The reason of this has been already explained in the description of paralysis of the external rectus muscle.

The line which divides the portion of the field in which the patient sees double from that in which single vision exists, does not run vertically from above downwards, but obliquely from left to right; lying to the left side of the vertical line above the horizontal line, and to the right side of it below the horizontal line. This is explained by the fact that the divergence is much greater when the eyes look upwards, than when they look down.

The patient's head is turned towards the right, so as to avoid diplopia, by bringing objects as much as possible into the left half of the visual field.

5.—PARALYSIS OF THE SUPERIOR RECTUS OF THE LEFT EYE.

This muscle moves the eye upwards and inwards, and inclines the vertical meridian inwards.

The inefficiency of the paralysed superior rectus will not be apparent in the movements of the eye below the horizontal diameter, but only in those above the latter. The diplopia will consequently be also only apparent in the upper half of the field. When the object is moved above the horizontal line, the left eye will lag behind, and this deviation will increase in proportion the higher the object is moved. At the same time there will also be a divergent squint, for on account of the paralysis of the superior rectus, the inferior oblique will move the eye somewhat outwards. If the right eye is covered, and the patient directed to look with the left at an object held slightly in the upper half of the visual field, the left eye will move upwards and inwards (the degree depending upon the amount of paralysis), showing that it had before deviated

downwards and outwards. The covered eye will at the same time make a considerably greater associated movement upwards and outwards. The patient in endeavouring to strike an object will aim too high. He will carry his head thrown back, so as to bring all objects, as much as possible, into the lower half of the field.

The diplopia manifests itself in the upper half of the visual field. The double images show lateral differences, are crossed, different in height, and not parallel.

As the cornea deviates downwards and outwards, the rays from an object held above the horizontal meridian line fall upon an outer and lower portion of the retina, and will consequently be projected upwards and inwards; the double image of the affected eye (*pseudo-image*) lying above and to the right of the image of the right eye.

As the action of the superior rectus upon the height of the eye increases as the latter is moved outwards (to the left), the inefficiency of the paralysed muscle in raising the cornea, will also be most evident in this direction. The difference in the height of the double images, therefore, increases as the eye is turned outwards, and diminishes as it is turned inwards. On the other hand, the inclination of the vertical meridian will be most apparent when the eye is turned inwards, and least so when it is turned outwards (to the left). On account of the paralysis of the superior rectus, the vertical meridians are not parallel, but that of the left eye is turned outwards by the unopposed action of the inferior oblique. Hence the pseudo-image would appear to converge towards the image of the right eye, but the double images are crossed, and hence they diverge at the top, the pseudo-image being inclined towards the right.*

6.—THE PARALYSIS OF THE INFERIOR RECTUS OF THE LEFT EYE.

The symptoms arising in a paralysis of this muscle are just the reverse of those in paralysis of the superior rectus. The want of movement and consequent diplopia are only apparent when the object is held below the horizontal meridian line. The pseudo-image lies *above* that of the right eye, and towards its right. The double images increase in height when the eyes are moved to the left, and in inclination when they are moved to the right. The double images are crossed and the pseudo-image inclined towards that of the right eye (*i.e.*, inclined towards the left).

* As patients often find it difficult to estimate accurately the obliquity of a small object, such as the flame of a lighted candle, it is better to use as an object, a white staff, or a roll of paper about 12 inches in length.

7.—PARALYSIS OF THE INFERIOR OBLIQUE OF THE LEFT EYE.

As it is extremely doubtful whether an isolated paralysis of this muscle ever occurs, I shall not describe the symptoms which would be presented by such an affection, but simply state that they would be just the reverse of those met with in paralysis of the superior oblique, and from a knowledge of which these symptoms could easily be constructed.

8.—PARALYSIS OF THE SUPERIOR OBLIQUE OF THE LEFT EYE, ETC.

The paralysis of the superior oblique illustrates better than that of any other of the ocular muscles, the correctness of the rules laid down as to action of the different muscles, and the nature of the diplopia presented by their paralysis. Indeed, the deviation of the optic axis is so extremely slight in cases of paralysis of the superior oblique, that it might easily escape detection, and we must, therefore, place our chief reliance upon the position of the double images to assist us in determining the diagnosis.

A person affected with paralysis of the left superior oblique would complain that objects (the floor, steps, etc.) in the lower half of the field appear double and irregular in outline. Above the horizontal median line, both optic axes are fixed upon the object and no diplopia exists. If the object is held in the horizontal median line or a very little below it, a very slight deviation of the left eye in an upward and inward direction is noticed, which becomes more and more marked the further the object is moved into the lower half of the field, more especially towards the right. If the right eye is closed, the left makes a well-marked movement downwards and outwards, and there will be an erroneous projection of the visual field in the same direction. Upon closing the healthy right eye, and testing the mobility of the left, we might at first suppose it to be unimpaired in all directions, but on closer examination we find that downwards and inwards (towards the nose) there is a distinct want of mobility. Instead of following the circular sweep of the object from below to the inner side, the optic axis makes a diagonal spring upwards and inwards. The double images are homonymous, and show a difference both in height and laterally, and the one slants. The diplopia is confined to the lower half of the visual field, and is absent in the upper. On account of the convergent squint which arises below the horizontal line, the diplopia

is homonymous, and as the left eye remains at the same time too high, its double image will appear beneath that of the right eye. The lateral difference between the double images increases the more, the further the object is moved downwards, as the convergence of the optic axes then becomes greater, on account of the unopposed action of the inferior rectus. The difference in the height of the double images increases the more, the further the object is moved over to the right, and diminishes as it is moved over to the left. This is owing to the fact, that the superior oblique exerts the greatest influence upon the height of the eyeball when the eye is moved downwards and inwards, and hence its loss of power upon the height of the cornea will also be felt the most in this direction. On the other hand, the inclination of the double images will be greatest when the object is moved over to the left, and least when it is carried over to the right. For the superior oblique exerts most influence on the position of the vertical meridian, when the eye is moved downwards and outwards. On account of the paralysis of the superior oblique, the inferior rectus will exercise unopposed sway over the vertical meridian in all the movements of the eye below the horizontal median line, and incline it outwards. The parallelism of the vertical meridians will, therefore, be destroyed, and they will diverge at the top, the double images appearing to converge. For on account of the slanting outwards of the vertical meridian of the left eye, the image from the object will not fall in the vertical meridian, but upon the upper and inner and lower and outer quadrants of the retina, and the pseudo-image will, therefore, appear to the patient to be inclined towards the right, and to converge towards the image of the right eye. A glance at Fig. 78, p. 557, will render this intelligible, it being remembered, however, that the vertical meridian is turned outwards in paralysis of the superior oblique, and inwards in that of the external rectus.

When the object is carried very far down into the lower half of the field, a curious phenomenon is observed, viz., that the pseudo-image appears above that of the right eye, even although the left cornea still remains higher than the right. This is due to the extreme inclination of the vertical meridian, which becomes so great when the eye is moved far downwards, that a dislocation of the quadrants of the retina takes place, the rays from the object falling no longer upon the inner and upper quadrant of the retina, but upon the inner and lower, and they are hence projected upwards and to the left.

The double images in paralysis of the superior oblique are not at the same distance from the patient, but that of the affected eye is considerably nearer to him. This was I believe first noticed by Dr. Michaelis. It would appear to be due to the projection of the image upon a horizontal surface below the eyes (*e.g.*, the floor of the

room), for this symptom disappears with an alteration of the surface of projection.*

The line which divides the field of single from that of double vision does not run horizontal, but obliquely downwards from the right to the left. The patient carries his head turned downwards and to the right, so as to bring the objects as much as possible into the upper and left portion of the field, as the diplopia arises sooner in the right half. Prisms must be turned with their base downwards and outwards.

After a paralysis of the superior oblique has existed for some time, secondary contraction of the inferior oblique often supervenes. The diplopia then extends into the upper half of the visual field, but here becomes crossed, the pseudo-image, however, being still beneath that of the right eye. This is due to the cornea being moved abnormally upwards and outwards, on account of the contraction of the inferior oblique. The increase in the height of the double images will augment towards the right, and diminish towards the left; the reverse obtaining with regard to the inclination of the double images.

Having considered the various symptoms presented by the paralytic affections of the different muscles of the eye, we must now turn our attention to their causes, prognosis, and treatment.

We may distinguish peripheral and cerebral causes. Amongst the former, cold and rheumatism are the most frequent. In such cases, the affection is rapidly developed, and is generally accompanied by more or less severe rheumatic pains in the corresponding side of the face and head. Very frequently there is no difficulty in tracing the cause to a cold which the patient has caught from a sudden exposure to a great change in temperature, or to a draught of cold wind. This is soon followed by pain in and around the orbit, accompanied by a slight degree of diplopia. The pathological changes in such cases generally consist in a rheumatic inflammation of the nerve sheath.

The causes may be situated in the orbit. Amongst these we must enumerate effusions of blood, all the different forms of orbital tumour, abscess of the orbit, exophthalmic goitre, etc.

The most frequent cause is, however, syphilis. According to Von Graefe about one-third of the paralytic affections of the muscles of the eye are due to it. In many cases it is, however, impossible to determine with any degree of accuracy the exact seat of the cause; we must be satisfied with the fact, that the patient has suffered from

* "Symptomenlehre der Augenmuskellähmungen," A. Von Graefe, 1867, p. 145.

syphilis, and we frequently find that a rapid recovery ensues under proper anti-syphilitic treatment.

Syphilitic nodes or exostoses may be situated in the orbit, or at the base of the brain, and cause the paralysis by direct pressure upon the nerve. Syphilitic neuromata may also produce it.

Paralysis of the ocular muscles is often due to some cause situated at the base of the skull, and this must be especially suspected if several muscles of one or of both eyes are affected, or if some other nerves (such as the facial or some branches of the fifth) are also implicated. We find that the causes situated at the base of the brain, generally produce paralysis by a direct compression of the nerves which lie at this situation. Amongst such causes, we must especially enumerate syphilitic and rheumatic ostitis and periostitis, exostoses, syphilitic tophi, tubercular deposits, effusions of blood, and tumours of various kinds. In cases of tumour or aneurism, the progress of the paralysis is generally slow, whereas, the reverse is the case in inflammatory exudations.

The cause may, however, be situated in the brain itself, and we then generally find that the patient shows some derangement of the intellectual functions. His memory fails him, and he experiences a difficulty in arranging his ideas, or in giving expression to them. These derangements are often very transitory, and may vary greatly in extent, from a slight impairment of memory to a state bordering on idiocy. Ptosis is not unfrequently a symptom of a cerebral affection, whereas lagophthalmus is only exceptionally so. Amongst the various affections within the brain which may produce paralysis of the muscles of the eye, must be mentioned softening of the brain, effusions of blood, tubercular deposits, aneurisms, impermeability of some of the cerebral blood-vessels, tumours situated within the brain, hydrocephalus, etc. The nature of the diplopia aids us to a certain extent in localising the cause of the paralysis, for in paralysis due to a cerebral lesion we observe that there is great difficulty in the fusion of the double images. It is found very difficult, or almost impossible to unite them, even with the most carefully selected prism, the patient being unable to fuse them by a voluntary effort, even although they are brought very close together.

The *prognosis* of the different kinds of paralysis varies with the cause, the degree, and the length of duration of the paralysis.

With regard to the *general* prognosis of paralytic affections of the muscles of the eye, it may be laid down as a rule that it is the more favourable, the more recent the affection. Again, a partial paralysis affords a more favourable prognosis than if it is complete, even although the latter may be of much shorter duration. The character of the diplopia is also prognostically of importance, for the double

images which only show a lateral difference and none in height, are far more easily united than when there is a difference in height. Slight cases of paralysis of the internal or external rectus may be spontaneously cured by the effort of the act of vision, which causes the fusion of the images.

The prognosis is generally very favourable in the rheumatic paralysis, especially if the patient applies soon after the outbreak of the disease. If the cause is situated within the orbit, the prognosis will principally depend upon the fact whether the cause can be removed or dispelled.

In the syphilitic form of paralysis, the prognosis leans towards the favourable side of the scale, but is greatly influenced by the seat and extent of the cause. In the central causes it is, however, much more unfavourable, although a complete cure may arise, if the primary affection is removed (as in absorption of exudations, etc.)

The *treatment* must also vary with the nature of the cause. In rheumatic paralysis, a free purge should be administered, and diaphoretics be prescribed, together with a good sized blister behind the ear. I have found the greatest benefit from the latter remedy, as also from the use of iodide of potassium internally. When the inflammatory symptoms have subsided, and the nerves are regaining some power, Faradization should be applied. In syphilitic cases, the iodide and bromide of potassium are found of the greatest service; or mercurial inunction may be employed, if necessary. Zitmann's decoction is also very serviceable, as it acts not only as an anti-syphilitic, but also as a diaphoretic. Its use, however, entails a good deal of inconvenience and discomfort.

To relieve the patient of the annoyance and confusion produced by the diplopia, the affected eye should be excluded from the visual act by a shade or a piece of frosted glass (if spectacles are used). This exclusion also obviates the tendency of the patient to carry his head turned to one side.

Prismatic glasses may likewise be employed for the purpose of fusing the double images, and their strength, and the direction in which their base is to be turned, will depend upon the muscle affected, and the degree of deviation. In paralysis of the internal rectus, the base would be turned inwards, in that of the external rectus, outwards. If the double images show both a difference sideways and in height, we may divide the prisms, placing one with its base laterally, and the other with its base turned upwards or downwards, as the case may be. Or we may divide these two prisms between the two eyes. In accordance with the fact, that the eye can readily overcome lateral differences in the double images, whereas, it cannot correct any but the very slightest difference in height, we often find that if we correct the latter by a prism, the lateral differences are at once corrected by an effort of one of

the horizontal muscles of the eye. This fact is of much importance in those cases in which we operate for the sake of curing diplopia. I have already stated, when speaking of paralysis of the external rectus, that when we desire to use prisms therapeutically, the double images should be not fused into one, but only approximated, in order that the paralysed muscle may be stimulated to an effort to unite them.

Electricity is often found of great service in the treatment of paralysis of the muscles of the eye, especially if the cause is peripheral. Generally one pole of the instrument is applied to the closed eyelid in a situation corresponding to the affected muscle, the other pole being placed on the temple or the back of the neck. I have sometimes gained very successful results with the common rotatory machine, keeping up its action for a few minutes. Hitherto, it has generally been supposed that electricity acts beneficially by a direct excitation of the paralysed motor nerves, but according to Benedikt* this is not so, for he states that its effect is due to a reflex excitation of the fifth. He found, moreover, that in most cases a curative action was only produced when the excitation was relatively weak, and when no trace of muscular contraction was produced by the electricity. The proper measure for the strength of the current is the sensitiveness of the fifth pair. If the fifth is extremely sensitive, the battery may have to be reduced to four or three of Daniell's elements; if, on the other hand, the fifth is very insensible, it may have to be raised to 12 or 15. The current should be sufficiently intense to produce a slight sensation in the parts excited, but the excitation should only continue for about half a minute at each sitting. Experience has taught Dr. Benedikt that in paralysis of the external rectus the copper pole should be applied to the forehead, and the zinc pole over the neighbourhood of the cheek bone. In mydriasis, the latter should be applied to the same place, but the copper pole to the closed eyelid. In ptosis, the copper pole may be either on the forehead, or may be applied by means of a short catheter-like reophore to the mucous membrane of the cheek, while the zinc pole is drawn over the lid. For all the other branches of the third nerve, the copper pole is applied as above. In order to act upon the internal rectus or inferior oblique, the zinc pole should be drawn over the skin of the side of the nose, near the inner angle of the eye, and, in order to act upon the inferior rectus, over the lower margin of the orbit. Benedikt found that in the greater number of cases the improvement takes place instantaneously, as shown by increased mobility of the eye, and a diminution of the field in which diplopia arises; and when this is not the case, a longer continuance and increased strength of the excitation is not indi-

* Vide a very interesting paper by Dr. Moritz Benedikt, "On Electro-Therapeutical and Physiological Researches on Paralysis of the Ocular Muscles." "A. f. O.," x, 1, translated in "Ophthalmic Review," vol. ii, p. 143.

cated. When the paralysis has been unaffected by 14 days of treatment, he has not seen any benefit arise from its longer continuance.

Paralytic affections of the muscles of the eye may run the following different courses :—1. The paralysis may be completely cured, which is most likely to occur when the affection is recent, and due to some peripheral cause. 2. The cure may be incomplete, the muscle being only partially restored to its former power. 3. The paralysis may remain complete; but this condition generally soon leads to the next (4) state, viz., to a secondary contraction of the opponent muscle. Thus in paralysis of the left external rectus, the diplopia may extend more and more into the right half of the visual field, and a decided convergent squint of the left eye be apparent, even when the object is held in the right half of the field. The opponent muscle may in time contract so much, as to drag the eye almost immoveably to its own side.

When all other remedies have failed to effect a cure, it may be necessary to have recourse to operative interference, and the nature of this will depend upon the degree of paralysis which remains behind. Thus, if only a slight degree of paralysis of the external rectus remains, so that the want of mobility outwards amounts to about 1 or $1\frac{1}{2}$ line, division of the opponent muscle (internal rectus) will be indicated. But when the immobility exceeds this degree, and amounts to two or three lines, this operation will not suffice, and we must combine with it the operation of bringing forward the insertion of the paralysed muscle (the latter operation is generally termed that of "re-adjustment"), so as to increase its power over the mobility of the eyeball. This operation should not be deferred too long, for after a time the paralysed muscle may undergo fatty degeneration, which renders it unfit for the requisite degree of contraction, even if its innervation were completely, or in great part, restored; and it also favours secondary contraction of the opponent. The method of performing the operation of re-adjustment will be considered together with that of strabismus.

9.—SPASMODIC AFFECTIONS OF THE MUSCLES OF THE EYE. NYSTAGMUS, ETC.

The symptoms of nystagmus consist in a peculiar, restless movement or oscillation of the eyeballs. This oscillation is generally horizontal, but occasionally rotatory, the eyeballs oscillating round the axis of the oblique muscles. In one instance I have seen it vertical, in an eye affected with convergent squint. This eye made a constant, vertical, upward and downward movement, which was not arrested, or even improved, by the tenotomy of the internal rectus. This is the only case of vertical oscillation with which I have ever met. The oscillation may be periodical, and its degree is often very variable at different times,

being markedly increased by any nervous excitement, and by the effort of accommodation. To remedy the indistinctness of vision produced by the unsteadiness of the eyes, the patients often make a contrary movement of the head; or they hold the print in a slanting or vertical, instead of a horizontal, position, so that the lines run vertically instead of horizontally. The reason of this is easily intelligible, for they can then see the individual lines chiefly by the aid of the superior or inferior recti, and the circles of diffusion caused by the oscillation of the eye will then extend the latter vertically, instead of horizontally; the length of the letters will consequently be considerably more increased than their breadth, which is less confusing to the sight, as their lateral separation will be preserved. Whereas, when they are extended horizontally, one letter runs into the other, its outline is blurred and confused, and the power of distinction much impaired.

Although there may be considerable oscillation of the eyeballs, the movements of the eyes are unaffected and perfect in all directions, and the two eyes may act perfectly together, but binocular vision is often disturbed, and the sight of the two eyes frequently very different. The oscillation sometimes diminishes greatly, or is even arrested when the eyes are moved very far outwards or inwards, or in one of the diagonal positions downwards (Böhm).*

Nystagmus generally appears in early infancy, and is especially met with in cases in which a considerable degree of exertion of the ocular muscles is required for distinct vision; the object having, perhaps, to be held very close to the eye, either on account of some anomaly of the refraction, or some opacity in the refracting media. Thus the affection is often met with in infants together with opacities of the cornea or of the lens, in cases of strabismus, in albinos, etc.

The disease may diminish, or even disappear, as the patient grows older, but it generally remains permanent, varying, perhaps, somewhat with the state of health; any debility or nervous excitement increasing its intensity. If strabismus co-exists, this should be cured by an operation, and in some cases the nystagmus is also considerably diminished by the tenotomy. In others it must, however, be confessed, that either no benefit, or only a very temporary one, results. Hence I do not consider it advisable to perform tenotomy of any of the ocular muscles for the chance of curing the nystagmus, except there is also strabismus. Any anomaly of refraction should be corrected by suitable lenses, and benefit is sometimes experienced from the use of blue eye-protectors, to diminish the intensity and glare of the light.

Spasmodic affections of the ocular muscles are extremely rare. Clonic spasms are sometimes met with in children affected with chorea or basilar meningitis; also in cases of lead poisoning, and in some of

* Böhm, Der Nystagmus.

the affections of the brain and spinal cord. Tonic spasms of the ocular muscles are occasionally observed in epilepsy.

Spasm of the orbicularis palpebrarum is described in the article upon the diseases of the eyelids.

10.—STRABISMUS.

We have now to turn our attention to the consideration of the various forms of squint and their treatment. The surgeon should thoroughly master the theoretical portion of this subject before he attempts to operate for the cure of this affection; for although the operation for squint is not *per se* a difficult one, we yet meet with many cases which require very great exactitude and nicety, not only in the preliminary examination, but also in the mode of operation. Still more difficult and intricate are those cases, in which we operate less for the cure of the deformity, which is, perhaps, hardly observable, than for the purpose of freeing the patient from the great and constant annoyance of the diplopia. These demand a thorough knowledge of the individual actions of the muscles of the eyeball, an intimate acquaintance with the various forms of diplopia, and considerable manual dexterity in the performance of the operation, the extent and character of which should be accurately determined upon beforehand. These cases, indeed, often form some of the most difficult problems in ophthalmic surgery, and can be only successfully treated by those who have mastered the theory of this and kindred subjects. A want of such knowledge brought the operation for squint into almost complete disrepute, and we are chiefly indebted to Von Graefe for having extricated it from the obloquy with which it had, not undeservedly, been visited, and for having rendered it one of the most successful operations in surgery. He has achieved this success not so much by improving the mode of operation, as by his elaborate researches into the physiology and symptomatology of the various forms of squint, which have enabled him to lay down exact data for their successful treatment.

Symptomatically we mean by the term squint, an inability to bring both visual lines to bear simultaneously upon one point, the one always deviating in a certain direction from the object. If the squinting eye deviates inwards, it is called convergent squint, if outwards, divergent squint; if it squints upwards, strabismus sursumvergens, if downwards, strabismus deorsumvergens.

The name strabismus was formerly indiscriminately applied to all abnormal deviations of the visual lines, whatever their cause; whether they were due to paralysis or spasm of one or more of the muscles of the eyeball, or whether some tumour, etc., of the orbit prevented the free movement of the eye in certain directions.

We now, however, limit the term strabismus (or strabismus concomitans of Von Graefe, a name we shall adopt) to that group of cases which presents the following well-defined and constant symptoms:—

1. The visual line of one eye being fixed upon an object, that of the other always deviates from the latter at a certain angle, and in a certain direction. In convergent squint it deviates to the inner, in divergent squint to the outer side of the object. In order to determine which is the squinting eye, the patient should be directed to look steadily at an object (a lighted candle or our uplifted finger) held in the horizontal median line, at the distance of a few feet. Then, alternately covering each eye with our hand, we note whether the uncovered eye remains steadily fixed upon the object, or has to change its position before it can bring its optic axis to bear upon it. In the former case, it is the one generally used for fixation, in the latter, it deviates from the object. We may, however, fail to detect the deviation in this manner, if it is so very slight as to be almost objectively inappreciable, in which case we must call the diplopia to our aid, as it enables us to detect the most minute deviations of the optic axes. But the concomitant squint is generally very evident.

If we cover the healthy eye with our hand, the other will move in a certain direction in order to fix the object (in convergent squint it will move outwards, in divergent inwards), the healthy, covered eye making at the same time an *associated* movement (which has been designated the *secondary* deviation), becoming now, in fact, the squinting eye.

I have already (p. 555) explained the method of measuring the linear extent of the deviation with Laurence's strabismometer. I need only add that the degree of strabismus should be tested both for near and distant objects, as it is often far more considerable during a strong effort of accommodation, as in reading small type, than when the eye is looking at a distant object.

We sometimes find that there is not only a lateral deviation, but also a slight difference in the height of the two eyes. It is important in such a case, to determine whether (in a case of convergent squint) this is due to the upper fibres of the internal rectus being more contracted than the middle or lower fibres, or whether it is owing to the superior rectus being also affected, for upon this will hinge the question of operating upon more than one muscle.

The associated movement, which the healthy eye makes when it is covered and the squinting eye fixes the object, will enable us to determine this, for if the internal rectus is alone at fault, the associated movement of the healthy eye will be only lateral, without any deviation in height; whereas, if the superior rectus is also implicated, the healthy eye will make not only an inward, but also a downward movement, corresponding to the outward and downward movement of the other

eye. In the former case, we shall almost always succeed in curing the inward and slightly upward deviation by a tenotomy of the internal rectus alone, more particularly if we freely divide the upper portion of the tendon. In the latter case, we shall have not only to operate upon the internal, but also upon the superior rectus.

2. The primary and secondary deviations are quite equal in extent. The meaning of these terms has been already fully explained at page 554. Let us suppose that the left eye squints inwards to the extent of two lines. Now, if the right is covered, the left will have to move outwards to the extent of two lines in order to fix the object, and the covered eye will make at the same time an associated movement inwards of two lines, this secondary deviation being, therefore, exactly equal to the primary.

3. The extent of movement of the two eyes is quite normal and equal, the arc of mobility being exactly of the same extent in both eyes, and only a little shifted towards the side of the shortened muscle. Thus, in a convergent squint it is shifted slightly inwards, but what is gained in this direction is lost in the movement outwards. This increase in the mobility towards the side of the shortened muscle, is, however, very slight when compared with the degree of the squint. On account of this complete accompaniment of the squinting eye in all the movements of the healthy one, it has been called strabismus concomitans. If we hold an object in the horizontal median line, and then move it to the right and left, the optic axis of the squinting eye will exactly accompany that of the healthy eye in all its movements, deviating from it, however, always at the same angle, except, indeed, at the extreme portions of the field of vision.

In order to note accurately, and to keep an easy and diagrammatic record of the extreme lateral movements of each eye inwards and outwards, Mr. Bowman has for some time adopted the following simple and practical method:—He notes the extreme range inwards, by marking the position of the pupil on extreme inversion, compared with that of the lower punctum; and the extreme range outwards, by marking the position of the outer edge of the cornea, on extreme eversion, compared with that of the external canthus.

The following figures illustrate this method, the patient being supposed to face the observer:—

Fig. 80 shows *R*, the right outer canthus, and *L* the left outer canthus, crossed by a vertical line *a*, or *b*, or *c*, which indicates by its position the extent to which the outer edge of the cornea approaches the canthus, or even goes beyond it, on *extreme eversion* of the eye. And Fig. 81, in like manner, exhibits for *R* the right eye, and for *L* the left eye, the position which the pupil, O, takes with regard to the punctum, •, when the eye is moved *inwards* to the extreme degree. It may fail

to reach it, as at *a a*, or be over it, as at *b b*, or pass more or less inwards beyond it, as at *c c*.

Fig. 80.

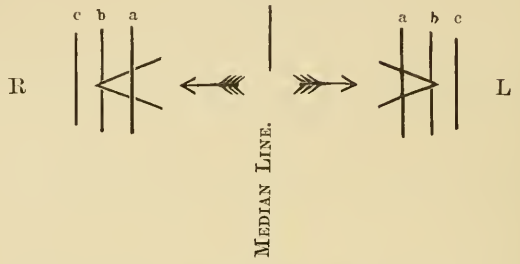

Fig. 81.

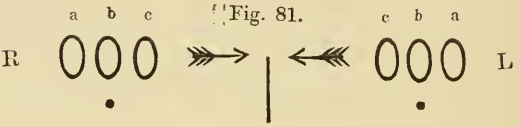

In taking the relation of the pupil to the punctum if the eye is much inverted, the observer should, as it were, face the pupil in its inverted position, otherwise the interval between it and the punctum is not so correctly estimated. Or the parts may be viewed from above, the surgeon raising the upper lid, and standing behind the patient, who sits on a chair. But a little practice soon renders this unnecessary.

If the outer edge of the cornea, in extreme eversion, passes under cover of the canthus, its actual position can be readily enough marked by noting how much of the iris is covered from view.

A diagrammatic record should be kept of the range of mobility, in order that we may hereafter be able to estimate the effect of the operation upon the lateral movements of the eye.

The accommodative movements of the eye should also be accurately tested, for they are extremely important, as will be shown hereafter, in determining the mode and extent of the operation. On bringing the object nearer and nearer to the eyes, the optic axis of the healthy eye will remain fixed upon it, converging the more the nearer the object is approximated: the position of the squinting eye (convergent strabismus) may, at the same time, undergo the following changes:—

1. It may retain its original position, sustaining only a few oscillating, irregular, lateral movements.

2. It may remain completely stationary, so that the angle of squinting will diminish the more, the nearer the object is brought, until, at a certain point (if the squint be not excessive), its optic axis will also be fixed upon the object, and there will no longer be any squint. If, how-

ever, the object is approximated still closer, a divergent squint will arise; for, whilst the healthy eye converges still more, the other retains its position, and now deviates (passively) outwards.

3. It retains its position up to a certain point, and then, as the healthy eye moves inwards to follow the object, it makes an *associated* movement outwards.

4. It deviates suddenly and spasmodically inwards, when the object is approximated very closely.

Concomitant squint may be either monolateral or alternating. In the former case, the squint is always confined (when both eyes are open) to one and the same eye. If the healthy eye be covered, the other will move in order to fix the object, but directly the former is again uncovered, it will at once resume its squinting position. In alternating squint it is different, for sometimes the one eye deviates, sometimes the other. If we, in this case, cover the healthy eye, the other will make a movement in order to adjust its optic axis upon the object, and will retain its position when we uncover the sound eye. The latter has now, in fact, become the squinting one. If we, then, cover the other, the squint will alternate again. It appears almost, or quite, immaterial to the patient which eye he uses. In such cases, there is generally no difference in the sight of the two eyes; whereas, in monolateral strabismus the vision of the squinting eye is almost always affected, on account of the suppression of the double image, sometimes, indeed, very considerably.

The active negation of the double image by the brain, soon leads to a more or less considerable deterioration in the sight of this eye. We occasionally find, however, that the vision of the squinting eye remains good, although the strabismus is not alternating. Indeed, I have seen cases (exceptional I grant) in which the patients could read the very finest print with it, never having, as far as they could remember, suffered from diplopia. Here binocular vision had most likely never existed, and hence the absence of diplopia and the call for the suppression of the double image.

It was at one time proposed to cure squint by closing the healthy eye, and thus necessitating the fixation of the other upon the object. The error of such treatment is, however, self-evident, as the squint is merely transferred to the excluded eye; for just the same thing occurs, as when we place our hand over the healthy eye, in order to estimate the primary and secondary deviation. The vision of the squinting eye is exercised, but the disease remains uncured. But this proceeding often proves very valuable in practice, for by it we may render a monolateral squint alternating, and preserve the sight of both eyes. If, for instance, a child squints (seeing perfectly with both eyes), and the operation has to be postponed for some reason, we may preserve

the sight of the squinting eye by the periodical exclusion of the other. In this way, we may not only maintain the alternating character of the strabismus, and the sight of both eyes, but we may even change a monolateral into an alternating squint.

The question as to whether binocular vision exists or not in a case of strabismus, is of much importance in the prognosis. For if it does not exist, we cannot expect a perfect, but only an approximative, cure, for there will not be any diplopia, and the perfect cure of squint depends upon the fusion of the double images. Hence, the presence of binocular vision should always be ascertained before the prognosis of a strabismus operation is made. Its presence is of course proved at once by the existence of binocular diplopia. The sight of each eye may be good, and there may be no deviation of the optic axes when both are open, and yet both may not be used at the same time. The existence of binocular vision is easily proved by the aid of prisms. Each eye should, however, be first examined separately, and its acuity of vision, range of accommodation, and state of refraction be accurately ascertained; notice being also taken as to whether the visual line is adjusted upon the object, or whether the eye "fixes" the latter with an eccentric portion of the retina, and not with the yellow spot. In the former case it is termed "central," in the latter "eccentric fixation." The patient is next directed to look with both eyes at a lighted candle situated at a distance of 4 or 6 feet, and a prism, with its base outwards, is then placed before one eye (let us suppose the left). One of the following three things will then occur:—1, diplopia; 2, a *corrective squint* if the prism is not too strong, for the left eye will endeavour to overcome the annoyance of the diplopia by squinting inwards, and thus fusing the double images; 3, the prism may have no effect, producing neither diplopia, nor a corrective squint. This proves the absence of binocular vision, and that the prism has been held before the eye which is not used. For if we place it (still with its base outwards) before the other eye, this will move inwards in order to bring the deflected rays again upon the yellow spot, this being accompanied by an associated movement outwards of the eye which is excluded from binocular vision.

Binocular vision is frequently only lost in certain portions of the retina, more especially in those which, though not identical with, are constantly excited simultaneously with the central portion of the retina of the other eye.

Thus in convergent squint we find that, in the squinting eye, the portion of the retina which lies internal to the yellow spot is the first to suffer a loss of binocular vision, for it is directed towards the object, and is therefore (though not identical with it) constantly excited simultaneously with the central portion of the retina of the other eye,

which is fixed upon the object. The reverse occurs in divergent squint, for there the external portion of the retina is the first to fail. At first, this loss of binocular vision only extends horizontally, so that if we turn a prism with its base upwards or downwards (or place it even in a diagonal position), we at once produce double images, which show not only a difference in height, but also, if there is any squint, a lateral difference. We may thus determine with the greatest nicety, which part of the retina has lost the power of binocular vision. Sometimes it extends over the whole retina, so that we fail to produce diplopia even with the strongest prisms turned in any direction; in other cases, this loss of binocular vision is tolerably circumscribed, being confined to a very small portion of the retina. In convergent strabismus, for instance, only a small portion of the retina internal to the yellow spot may have suffered: so that on placing a prism, with its base towards the nose, before this eye, and deflecting the rays still more inwards, double images are at once produced, although the deflected rays now impinge upon a more eccentric, and naturally less sensitive portion of the retina. Occasionally, we may in such a case also produce diplopia, if we, by means of a prism, bring the rays nearer to the macula lutea. Thus, a sudden alteration of the position of the optic axis of the affected eye, may at once give rise to diplopia; as, for instance, after the operation for squint, or in cases of paralysis or spasm of the other muscles of the eyeball.

Von Graefe has found that binocular vision is absent in about 90 per cent. of cases of concomitant squint; that we can produce diplopia by prisms in about 25 per cent.; and that after the operation, binocular vision is found to exist in about 50 per cent. The reason why binocular vision is so frequently absent in concomitant squint is, that on account of the annoyance and confusion produced by the diplopia, the patient soon acquires the habit of mentally suppressing the retinal image of the squinting eye. This active suppression of the pseudo-image is mostly accompanied by considerable amblyopia, and the latter is especially apt to increase very rapidly in children, so that, perhaps, within a few months after the first appearance of the squint, the child may hardly be able to decipher large letters (No. 16 or 20 of Jäger) with the squinting eye. This being so, the operation should never be unnecessarily deferred. The question is often debated, as to whether a child of two or three years of age should be operated upon for squint, or whether it is not better to postpone the operation until it is much older. My opinion is very strongly opposed to the latter practice, and is urgently in favour of the operation being performed as soon as possible, whilst binocular vision still exists, and the sight of the squinting eye is good. If it is, however, absolutely necessary to postpone the operation, the vision of the squinting eye should be

very frequently practised, and each eye alternately used for reading, etc.

The amblyopia due to the suppression of the retinal image is often greatly improved by the operation, and especially by practising the sight afterwards with a strong convex lens, or by Von Graefe's arrangement of two lenses placed in a short tube (p. 408). The improvement produced by the operation varies with the degree of amblyopia, and is greatest when the patient can still read moderate sized print (from No. 4 to 14 Jäger), when the sight is improved by convex glasses, and when the fixation is central and the visual field good.

The sudden and very marked improvement of sight which occasionally takes place directly after the division of the tendon, is probably due to the relief of the compression exercised by the contracted muscle upon the sclerotic, and through it upon the retina. It is difficult otherwise to explain this very sudden and striking improvement of vision.

We must now briefly consider the different forms of strabismus, and the various causes that may give rise to them. Before doing so, I must, however, again call attention to the fact that we occasionally meet with cases of *apparent* strabismus. In such there is an undoubted and well marked deviation (either convergent or divergent) of the optic axes, and yet both eyes are steadily fixed upon the object, and neither moves in the slightest degree when the other is closed. Hence the squint is not real, but only apparent. Donders has called particular attention to this fact, and has furnished us with the explanation.

I have already mentioned (p. 494) that according to Helmholtz, the optic axis and the visual line (an imaginary line drawn from the yellow spot to the object-point) do not correspond, but that the latter impinges upon the cornea slightly to the inner side of the optic axis, forming with it an angle of about 5°. It will, therefore, be at once apparent, that if the visual lines are parallel, the optic axes must necessarily be slightly divergent, and such is, indeed, the case in the normal eye, but this divergence is so very slight, and we are so accustomed to it, that it escapes our observation. In some cases, the visual line may change its position with respect to the optic axis, and if this deviation be at all considerable, an apparent squint will arise. In myopia, for instance, the visual line, instead of lying to the inner side of the optic axis, may correspond to the latter, or even lie to the outer side of it; and, in the latter case, there will, consequently, be an apparent convergent squint; for whilst the visual lines meet in the object-point, the optic axes must necessarily cross on this side of it. In hypermetropic eyes the reverse may obtain; the visual line may lie more than normally to the inner side of the optic axis, forming with it, perhaps, if the hypermetropia be excessive, an angle of 8° or even 9°, instead of one of 5°. If such eyes look at a distant object, they will appear to be

affected with a divergent squint, for whilst the visual lines are fixed upon the object, the optic axes will diverge from it. This explanation of Donders' is not only exceedingly interesting, but is also of much use to us in practice, for it will guard us against an erroneous diagnosis and treatment of such cases*. Some of the cases of so called incongruence of the retinæ were probably really cases of apparent strabismus.

(1.) CONVERGENT STRABISMUS.

Convergent squint is in the vast majority of cases due to hypermetropia. According to Donders,† the latter is present in about 75 per cent. of the cases of convergent strabismus. Wecker places it even at a higher figure (85 per cent.). The presence of hypermetropia is often overlooked, because it is either latent, or because the patients are very young and do not know how to read. The ophthalmoscope would, however, in such cases, at once enable us to detect the true state of refraction.

It will be remembered that we understand by the term "hypermetropia," that condition of the eye in which its refracting power is too low, or the optic axis (antero-posterior axis) too short, so that rays which impinge parallel upon the eye (emanating from distant objects) are not brought to a focus upon the retina, when the eye is in a state of rest, as occurs in the normal eye, but more or less behind it, according to the amount of hypermetropia present. The effect of this low refractive condition is, that, whilst the normal eye unites rays from distant objects upon the retina without any accommodative effort, the hypermetropic eye has already, in order so to do, to exert its power of accommodation more or less considerably. This exertion must increase, of course, in direct ratio with the approximation of the object to the eye; for if the accommodation has already to be brought into play to unite parallel rays upon the retina, how much more must this be the case when the object is closely approximated, and the rays from it impinge in a very divergent direction upon the eye. Now, in order to increase the power of accommodation, one eye often squints inwards, for the following reason:—Because together with the increase in the convergence of the optic axes, there is also an increase in the power of accommodation. We can easily prove the truth of this statement, by placing a prism (with its base outwards) before a hypermetropic eye; for the latter, in

* Although the visual line and the optic axis do not correspond, I shall yet generally use the term "optic axis" in speaking of the deviation of the eyes in squint, so as to prevent the confusion which would arise if different terms were employed.

† Vide Donders' article on "The Pathogeny of Squint," "A. f. O.," ix, 1, 99; also an able translation of this by Dr. Wright, of Dublin.

looking at distant objects, will then squint inwards, in order to avoid diplopia, and this convergence of the optic axes will now enable it to unite parallel rays (from distant objects) upon the retina, whereas, when its optic axes were parallel, it could only unite convergent rays. Again, on placing a concave lens before a normal eye, we change it into a hypermetropic one, for parallel rays are now united behind the retina, and it will require either a convex glass or an effort of the accommodation, to bring these rays once more to a focus on the retina. If this concave glass be but weak, an increased effort of the accommodation will neutralize its effect, and overcome this artificial hypermetropia. If, however, the concave lens be too strong for this, the eye often overcomes its effect by squinting inwards, and thus increasing its power of accommodation. This shows, therefore, apart from other consequences, the danger of giving a short-sighted person too strong a glass, for we may thus induce a convergent squint. Now, the same thing often occurs in hypermetropia,—the one eye squinting inwards in order to increase the power of accommodation. At first, this squint is but periodic, appearing only when the patient is intently regarding some object. As soon as he looks at any object, near or distant, the one eye moves inwards. Frequently, however, the squint only occurs when he is looking at near objects, as in reading, writing, etc. This squint has, therefore, been termed periodic squint; and hypermetropia is by far the most frequent cause of it. It is even surprising that squint is not more common amongst the hypermetropic. This form of periodic strabismus is often met with in young children, frequently showing itself first about the fourth or fifth year, when they are learning to spell, etc. In such cases, we may fail (on only cursorily glancing at the eyes) to detect the slightest squint; if we, however, direct the patient to look fixedly at something—as in reading, etc.—one eye directly squints inwards, this deviation, however, disappearing again as soon as the object is removed. Sometimes this periodic squint shows itself whenever the person is looking intently at any object, be it near or distant; in other cases, however, it only occurs when the eyes are looking at near objects, the squint disappearing as soon as they regard distant objects. The squint may, also, be frequently corrected by placing suitable convex glasses before the eyes, so as to neutralize the hypermetropia. If the latter is not neutralized by the constant use of convex lenses, the squint will generally soon become permanent, acquiring then all the symptoms of concomitant squint. As hypermetropia is often hereditary, and frequently exists in several members of the same family, and as it also often causes strabismus, the popular idea that a squint may be produced by imitation, has gained considerable credence, even in the Profession. I have often had occasion to examine such cases of squint occurring in different members of the

same family, and have almost invariably found that both patients, the supposed imitator and the imitated, have been hypermetropic; a common cause had produced the same affection.

The reason why the majority of hypermetropic persons do not squint, is evidently due to the fact, as pointed out by Donders, that they prefer to sacrifice a certain degree of distinctness and sharpness of vision in order to avoid diplopia. This is often proved by the fact, that if we cover the one eye of a hypermetropic patient with our hand, it will soon deviate inwards when the other is used for reading, etc. But it is otherwise when the images of the two eyes are very different as regards distinctness, as for instance, if the degree of hypermetropia is much greater in the one eye than in the other, or if there is some opacity in the refracting media of the one eye. In such cases, a convergent squint easily becomes developed. The same occurs if the internal recti muscles are very strong. A great difference between the position of the visual line and the optic axis (the two forming a considerable angle) seems also in hypermetropic eyes, to predispose to strabismus (Donders).

Convergent squint is most frequently met with in the moderate degrees of hypermetropia (from $\frac{1}{40}$ to $\frac{1}{10}$), being generally absent in the high degrees. This is evidently due to the fact, that when the hypermetropia is very considerable in degree, the accommodation is insufficient (even when the visual lines are abnormally converged) to produce a perfect retinal image, and the patient therefore accustoms himself to gain correct ideas from imperfect representation, rather than improve these by a maximum of effort (Donders).

Impaired vision of the one eye is a frequent cause of strabismus, as we can often notice in cases of opacity of the cornea or of the lens, or of some affection of the deeper structures of the eye; the distinctness of the retinal image of the affected eye being consequently impaired. This difference in the clearness and intensity of the retinal images of the two eyes is often very confusing and annoying to the patient, and, in order to escape from this annoyance, he involuntarily squints with the affected eye, so that the rays from the object may impinge upon a more peripheral (and, therefore, less sensitive) portion of the retina; and the image of this eye be consequently so much weakened in intensity as not to prove any longer of annoyance. The direction in which this deviation may take place, is generally determined by the relative strength of the different muscles. If one proves pre-eminently strong, the eye will squint in the direction of this muscle. The latter will contract more and more, and the squint will soon assume all the characters of concomitant strabismus. The image of the squinting eye will be gradually suppressed, and then amblyopia from non-use of the eye will be superadded to the weakness of sight caused by the

original affection (opacities in the refracting media, etc.). It must, however, be admitted, as has been pointed out by Pagenstecher, that in very many of these cases of impaired vision hypermetropia co-exists, and must, therefore, be regarded as the true cause of the squint. Donders thinks that the inflammation which causes the corneal opacity, may extend to some of the muscles, and at first bring on a spasmodic and then an organic contraction of the muscular tissues. Convergent squint may also arise as a secondary affection, after paralysis, or wounds and injuries of the opponent muscle. Marked instances of this secondary form of squint are but too often furnished by excessive operations for strabismus; the extent of the operation having either been too great for the requirements of the case, or the muscle having been divided instead of the tendon. Spasmodic contraction of the internal rectus may also produce convergent squint, but this does not, strictly speaking, belong to our present subject.

Von Graefe* has pointed out, that in rare instances myopia may be the cause of convergent squint. This occurs only in cases in which the myopia is moderate in extent, and in which the eyes are much used for very near work. After a time, the internal recti become contracted from this constant and excessive use, and cannot be relaxed when the patient looks at a distant object, the external recti being too weak to overcome the action of the internal recti. Consequently, a convergent squint arises, which is at first periodic, but may in time become permanent, and appear as soon as the patient looks at any object which is not very close to him.

This squint is not met with in cases of very considerable myopia, because in these the necessary convergence of the optic axes can generally not be maintained on account of the close proximity of the object, and therefore the patient only uses one eye. This form of strabismus mostly becomes developed in early manhood, more especially amongst students or literary men who are not in the habit of wearing glasses.

(2.) DIVERGENT STRABISMUS, ETC.

Just as hypermetropia is by far the most frequent cause of convergent squint, myopia is the most frequent cause of divergent strabismus. The latter may be constant or absolute, the one visual line always diverging from the object, and this divergence existing for all distances, so that both eyes cannot be brought to converge upon the object at any distance. The divergence, however, sometimes diminishes somewhat when near objects are regarded. This absolute divergence is especially met with in cases in which the

* "A. f. O.," x, 1, 156.

sight of one eye is greatly impaired (amaurosis, mature cataract, etc.), in paralysis of the internal rectus muscle, or in cases in which the latter has been too freely divided in an operation for convergent squint.

The principal cause why myopic eyes are so subject to divergent strabismus, is to be sought in the elongation of the antero-posterior axis of the eyeball in myopia. On account of the ellipsoidal shape of the globe, its range of mobility is diminished, and it cannot be moved so freely inwards or outwards. The outward limitation of mobility does not matter much, as it only comes into account in the extreme lateral movements of the eye, and the inconvenience arising from it can easily be remedied by a turn of the head.

We find, however, that it is very different if there is a considerable curtailment of the inward movement, as the necessary degree of convergence for a very near point can then only be maintained with great difficulty and exertion. The internal recti muscles are much strained and fatigued, symptoms of asthenopia appear, and then, to relieve these and the strong muscular effort, one eye is allowed to deviate outwards; when the work can be continued without difficulty. This is one form of periodic or relative divergent strabismus, and the same thing occurs, as Donders has pointed out, whenever the degree of myopia is so extreme, that the object has to be approximated so closely to the eye, that the visual lines cannot possibly be brought to converge upon it. Relative divergence may be due simply to the elongation of the eyeball, together with great myopia, the internal recti being healthy; or to weakness of the internal recti, without the presence of myopia; but in most instances these two causes co-exist. The tendency to divergent squint is also increased, by the small angle which the visual line forms with the optic axis in cases of myopia. We also find that divergent squint may only appear when the myopic patient is looking at any object beyond his far point, and which he does not see distinctly; or that it occurs when he is looking vacantly before him without fixedly regarding any object. On account of the indistinctness of the object, there is no effort at binocular vision, and the one eye will follow its natural muscular impulse, and deviate outwards, if the external rectus is relatively stronger than the internal. But if the patient is furnished with suitable concave glasses for distance, so that he can see the objects clearly and distinctly, the desire to maintain binocular vision will overcome the divergence; the same occurring if he is looking at any object within his range of accommodation. When one eye is blind, or there is a great difference in the refraction of the two eyes, divergent strabismus frequently occurs. For as there is no impulse to maintain binocular vision, the internal rectus gradually diminishes in strength, and the external rectus perhaps undergoes secondary con-

traction. The relative form of divergent squint dependent upon insufficiency of the internal recti, is a subject of such great importance, and one which demands such careful and special examination and treatment, that I shall treat of it separately, under the name of "muscular asthenopia."

We must now pass on to the treatment of strabismus. The nature of concomitant squint is totally different from that of the paralytic. In the latter, the innervation of one or more of the muscles of the eyeball is impaired; whereas, concomitant squint is due to a change—an increased degree of tension—in the muscle in the direction of which the squint occurs. But its innervation is normal, as is at once proved by the perfect mobility of the eyeball in this direction, and by the fact, that the secondary deviation exactly equals the primary, and does not exceed it, as in cases of paralysis. Practically, we may regard the affected muscle as shortened. We often meet with mixed forms of squint, for paralytic and spasmodic affections of the muscles of the eye may give rise to concomitant squint, leaving behind them but very slight traces of the original affection. But just as paralysis may be the cause of concomitant squint, so may the latter, if it be excessive in degree and of long standing, produce changes in the opponent muscle. Let us, for instance, suppose that there is an excessive convergent squint of the one eye: if the latter is not frequently exercised, and made to fix its optic axis upon the object either by an artificial or natural alternation, the non-use of the external rectus will gradually induce atrophy of this muscle. The internal rectus will at the same time become somewhat hypertrophied, and the mobility of the eye outwards will be considerably curtailed. These changes in the structure of the muscles are best prevented by the frequent, separate exercising of the squinting eye.

In slight cases of strabismus, it may be advantageous to exercise the weaker muscle by frequent and systematic "orthopædic" exercises; so that it may be gradually strengthened, and enabled to overcome the excessive action of its opponent in the direction in which the eye is deviated. Such exercises are, however, only indicated when the squinting eye possesses a fair degree of sight; when binocular vision exists; and when there is intolerance of diplopia, so that when the double images are brought sufficiently close together, they are fused into one by a voluntary muscular effort. These exercises may be performed by the aid of prisms, the double images being approximated so closely to each other, that they can be readily united. As the strength of the muscle increases, that of the prism must be diminished, for thus the distance between the images will be increased,

and the muscle more exerted. Javal* has introduced a very ingenious stereoscopic arrangement for these orthopædic exercises. The latter consist in the fusion of two large dots (one in each half of the stereoscope), and subsequently of letters and words, gradually diminishing in size. But both the prismatic and stereoscopic exercises demand very great patience and exactitude, and hence most patients infinitely prefer the more speedy cure by operation. But these exercises often prove very useful in perfecting the results of an operation. The sight of the squinting eye should also be often practised by itself.

Absolute concomitant squint can be cured only by an operation.

The object of the operation is to weaken the muscle in whose direction the squint occurs, so that its influence upon the movements and position of the eyeball may be diminished. This is effected by carefully dividing the tendon as closely as possible to its insertion; the muscle will then recede slightly, and acquire a new insertion somewhat further back. This recession is, however, accompanied by a certain diminution of power, for the further back the insertion lies, the less power can the muscle exercise upon the movements of the eyeball. As we wish to weaken the muscle, but at the same time to preserve as much of the lateral mobility as possible, we must carefully regulate and adapt the amount and nature of the operation to the requirements of each individual case, and we shall see, hereafter, how its effect may always be estimated to a nicety. The success depends less upon manual dexterity, than upon a thorough knowledge of the theoretical part of the subject.

After the tenotomy and retrocession of the muscle, the eyeball will incline passively to the side of the opponent to about the same extent as the muscle receded on the sclerotic. The diminution in the lateral mobility towards the side of the operated muscle, will, however, exceed the extent of this retrocession. If, for instance, the muscle has receded two lines, the loss of mobility will be from two to three lines, and this would impair the results of the operation considerably (particularly with regard to the accommodative movements) if it was not for the fact, that the mobility of the squinting eye is pathologically increased towards the side of the shortened muscle. Hence, the mobility will be in reality but slightly diminished by the operation, or it may even remain equal to that of the other eye.

The question, whether one or both eyes are to be operated upon, does not hinge upon the fact whether both eyes squint or not, but depends solely upon the extent of the strabismus. It is quite erroneous to confine the operation to one eye, merely because the squint is monolateral, and to perform the double operation only in cases of alternating strabismus.

* "Annales d'Oculistique," 1863, p. 76; also 1867, p. 5.

If the squint measures from 2 to $2\frac{1}{2}'''$ we may generally correct it by a single operation; by incising the subconjunctival tissue somewhat freely, and, by using a larger hook, we may even obtain an effect of $2\frac{1}{2}$ or $3'''$. This is particularly the case in children. If the deviation exceeds $2\frac{1}{2}$ or $3'''$ we must always divide the operation between the two eyes.

Let us suppose, for instance, that a patient is affected with a convergent squint of the right eye of about $4\frac{1}{2}'''$. To correct this by one operation, we should have to divide the tendon of the internal rectus muscle of this eye to such an extent that the muscle might recede $4\frac{1}{2}'''$. This would be, however, accompanied by a diminution in the mobility inwards of about $5\frac{1}{2}'''$; and even supposing that the pathological increase in the mobility in this direction had been previously about one line, we should still have a deficiency of about $4\frac{1}{2}'''$ after the operation. The associated movements towards the left side of the patient would, therefore, be greatly impeded; and this want of mobility inwards would make itself particularly felt during the accommodative movements, for it would prevent the proper convergence of the optic axes during reading, etc., as the optic axis of the right eye would deviate slightly outwards from the object, and this divergent squint would soon increase in extent and become permanent. In order to obviate this, we must divide the operation between the two eyes. Let us suppose that the tenotomy of the right internal rectus has corrected $2\frac{1}{2}'''$ of the deviation, there will, consequently, still remain an inward squint of this eye of about 2 lines. On covering the left eye with our hand, and telling the patient to look at the object with the right, the latter will have to make an outward movement of $2'''$, and this will be accompanied by an inward, *associated* movement of the left eye of the same extent. We must now calculate the extent of the operation which will be necessary to correct the secondary squint of the left eye, just as if the latter were primarily affected with a convergent squint of $2'''$. Let us now assume that the left internal rectus has been divided, and that we have obtained an effect of $2'''$, the eye will, consequently, incline outwards to this extent, a divergent squint of $2'''$ being in fact produced; and it will, therefore, require an extra exertion of the internal rectus to bring the optic axis of the left eye to bear again upon the object. Now, this inward movement of $2'''$ will be accompanied by an associated outward movement of the right eye to the same extent; hence, the convergent squint which had remained after the first operation will be completely corrected. If binocular vision exists, the double images will now be so very closely approximated, that a very slight muscular effort will be able to unite them permanently, and the cure of the squint will be perfect.

The operation is always to be performed in such a manner, that the

greater amount of correction is apportioned to the squinting eye, as the mobility is pathologically increased in the direction of the shortened muscle.

I shall confine my description to three operations, viz.: Von Graefe's, the subconjunctival operation of Mr. Critchett, and Liebreich's modification of Graefe's operation.

I may mention, however, that the old operation, in which the conjunctiva and subconjunctival tissue were widely incised, the capsule of Tenon lacerated, the muscle itself, and not its tendon, divided, should never be performed. Its effect is generally most unhappy, and it brought the operation for strabismus into great disrepute.

The principle of Von Graefe's operation consists in a very careful division of the tendon close to its insertion; with the smallest possible amount of laceration of the subconjunctival tissue, and the tendinous processes of the capsule of Tenon. We diminish the power of the muscle by giving it a more backward insertion; but we, at the same time, preserve its length intact. Our object is only to weaken the muscle, and not to render it more or less impotent. Before proceeding to consider this method of operating, I would, however, dwell for a moment upon the anatomical relations of the muscles of the eye with the ocular sheath. Commencing at the optic foramen and loosely embracing the optic nerve, the sheath expands, and passes on to the eyeball, which it encloses. It is loosely connected with the sclerotic by connective tissue—so loosely, indeed, as to allow of the free rotations of the globe within it. At the equator of the eyeball, it is pierced by the tendons of the oblique muscles, and, more anteriorly, by the tendons of the four recti muscles, with which it becomes blended; being finally lost on, rather than inserted into, the sclerotic, close to the cornea. The posterior portion of the sheath, up to the passage of the tendons, has been called the capsule of Bonnet; the anterior portion, from the passage of the tendons to its insertion in the sclerotic, having been designated the capsule of Tenon. On piercing the capsule, the tendons of the recti muscles become connected with it by slight cellular processes, sent forth from the capsule. These processes prevent the too great retraction of the muscle after the division of its tendon, which would be followed by a great loss of power. It is, therefore, of much consequence, that these connecting processes should not be severed by the tendon being divided too far back, or be lacerated by rude and careless manipulations with the strabismus hook. Von Graefe has, moreover, pointed out that the result may be unfavourable, even although the tendon has been divided anterior to these fibres, as the sheath of the tendon becomes thickened from the point at which it passes through the capsule, and this thickening extends nearly up to its insertion. If the tendon is, therefore, not divided sufficiently close

to its insertion, it is apt to retract within this thickened sheath, and this retraction will in many cases prevent its reunion with the sclerotic. In the old operation, the muscle was divided far back, frequently even posterior to its passage through the capsule, and it was consequently often rendered so powerless, that the eyeball could not be moved in this direction; its opponent acquired a corresponding preponderance of power, giving but too frequently rise to a secondary squint in the opposite direction. Hence the popular dread of the operation, "lest the eye should go the other way." But such an unfortunate result is not to be feared if the surgeon performs the operation with care and circumspection, and is thoroughly conversant with the theoretical part of the subject. It is an important rule never to do too much, for nothing is so difficult as to retrace one's steps and to patch up a fault which has been committed. It is far easier subsequently to increase the effect of the operation, than to diminish it. I know of no surgical operation which is so safe and so sure in its cure as that for strabismus, when properly performed. Let us now pass on to the description of Von Graefe's operation.

As it is sometimes very painful, the patient should be placed under the influence of chloroform. The eyelids are to be kept apart by the spring speculum, or, if this proves not sufficiently strong, by the broad silver elevators. An assistant should evert the eye with a pair of forceps (I am supposing that the internal rectus of the right eye is to be operated on), taking care to do so in the horizontal direction, without rotating the eyeball on its axis; otherwise, the horizontal position of the internal rectus will be changed. The operator should then seize, with a pair of finely-pointed forceps, a small, but deep fold of the conjunctiva and subconjunctival tissue, close to the edge of the cornea, and about midway between the centre and lower edge of the insertion of the internal rectus. He next snips this fold with the scissors (which should be bent on the flat, and blunt pointed), and, burrowing beneath the subconjunctival tissue in a downward and inward direction, makes a funnel-shaped opening beneath the subconjunctival tissue, this being, however, done very carefully, so as not to divide it to too great an extent. If the subconjunctival tissue is thick and strong, it will be better first to take up a small fold of the conjunctiva only, to open this, and then, seizing the subconjunctival tissue, to divide the latter. The squint-hook (which should be bent at a right angle, and have a slightly bulbous point, vide Fig. 82) is then to be passed through the opening to the lower edge of the tendon. Its point being pressed somewhat firmly against the sclerotic, the hook is to be turned on the point and slid upwards beneath the tendon, as close to its insertion as possible,

Fig. 82.

and the whole expanse of the tendon caught up. The operator must be careful not to direct the point of the hook upwards and outwards, otherwise it may perforate the fibres of the tendon, and only a portion of the latter be caught up; the direction of the point should, therefore, be rather upwards and inwards. When the tendon has been secured on the hook, the conjunctiva which covers its upper portion may be gently pushed off with the points of the scissors, so as to expose the tendon, which is then to be carefully snipped through with the scissors as closely as possible to its insertion. When it has been completely cut through, the conjunctiva is to be slightly elevated on the point of the hook, and a smaller hook passed upwards and downwards to ascertain whether the lateral expansions of the tendon have been divided. Should a few fibres remain, they must be divided, and the surgeon should again ascertain whether any others are still present. He should never omit to satisfy himself upon this point, for sometimes the lateral expansions are considerable, the tendon spreading out like a fan, and although a few fibres only might remain undivided, they would suffice to spoil the effect of the operation.

I have lately adopted a slight modification of Von Graefe's operation, and perform it more subconjunctivally. I use a pair of straight blunt-pointed scissors, and, instead of pushing off the conjunctiva from the hook so as to expose the tendon caught up by the latter, I divide the tendon subconjunctivally, quite close to its insertion. In this way, the advantages of Graefe's and the subconjunctival operation are combined. On account of the smaller size of the hook, and the situation of the incision (which is between the centre and lower edge of the tendon), the subconjunctival tissue is stretched and incised to a much less extent than in the subconjunctival operation. Again, the position and direction of the conjunctival wound are such that a suture can be at once applied, if necessary; whereas, in the subconjunctival operation the incision would have to be considerably enlarged upwards, before any effect could be produced by a suture upon the two cut edges of the tendon. But where the degree of strabismus is so considerable that it is certain no suture will be required, the subconjunctival operation may be employed; and also if we have no assistant at hand to roll the eye in the opposite direction.

If it is found, on the first introduction of the hook, that this slides up to the edge of the cornea without having caught up the tendon, it is certain that we have either not divided the subconjunctival tissue at all, or that the hook has been passed between it and the conjunctiva. If the former is the case, we must open the subconjunctival tissue, and then, on re-introducing the hook, we shall have no difficulty in finding the tendon. The opening in the conjunctiva and subconjunctival tissue should be but small, and the excursions with the hook limited, other-

wise, the subconjunctival tissue and the lateral processes of the capsule of Tenon will be extensively lacerated, which may be followed by too great a recession of the muscle.

The after-treatment is very simple. The eye, after having been well washed and cleansed of any blood coagula, is to be kept constantly moist with cold water dressing during the day of operation, so as to prevent any extensive effusion of blood under the conjunctiva. No button of granulations will form on the stump of the tendon, if the latter has been divided close to its insertion, and if the opening in the conjunctiva has been made near the upper or lower edge of the tendon, so as not to leave the latter exposed.

The effect upon the squint which follows immediately upon the operation, will not be the permanent one. We may, indeed, distinguish three stages in the effect produced by the operation :—1st. The period immediately following the operation ; 2nd. After three or four days have elapsed ; 3rd. After the interval of a few months,—this being the permanent effect. During the first stage, the effect will be considerable, for the eye can now only be moved in the direction of the divided muscle by the indirect connexion of the latter with the sclerotic by the lateral processes of the capsule of Tenon. As soon as the divided end of the tendon becomes reunited with the sclerotic, which generally occurs within three or four days, the effect will diminish, for the muscle now again exerts a direct influence upon the eyeball. This is the second stage. But we find that a further alteration in the position generally shows itself a few weeks or months after the operation, the effect being then again somewhat increased. This is due to the action of the opponent muscle, which, on account of its antagonist having been weakened, can now exert a greater influence upon the position of the eyeball.

A clue to the permanent result of the operation is furnished by the position of the operated eye during the accommodative movements of the eyes, when they are directed upon some near object. It is, therefore, of great consequence always to test the position of the eyes during accommodation immediately after the operation, as soon as the effect of the chloroform has gone off. We have already seen that the position of the squinting eye (convergent strabismus) may vary when the object is approximated closely to the eyes ; for whilst the optic axis of the healthy eye remains fixed upon the object, converging the more the nearer the latter is brought, the position of the squinting eye may undergo the following changes :—1st. It may retain its original position, sustaining only a few oscillating, irregular, lateral movements. 2nd. It may remain completely stationary, so that the angle of squinting will diminish the more the nearer the object is brought, until, at a certain point (if the squint be not excessive), its optic axis will also be fixed

upon the object, and there will no longer be any squint. If, however, the object is approximated still closer, a divergent squint will arise; for whilst the healthy eye converges still more, the other retains its position, and now deviates (passively) outwards. 3rd. It retains its position up to a certain point, and then, as the healthy eye moves inwards to follow the object, it makes an associated movement outwards. 4th. It deviates suddenly and spasmodically inwards when the object is very closely approximated.

We should, therefore, soon after the operation, when the effect of the chloroform has passed off, ascertain whether both optic axes can be steadily fixed upon the object, when it is brought to a distance of from four to six inches from the eyes (their state of refraction being normal). If the eyes are very short-sighted, the distance should be still less. The final result of the operation may be predicted from the position which the operated eye now assumes. If it remains stationary when the object is brought up to within eight inches from the eyes, so that a passive divergence will arise on its being approximated still closer, we must expect a certain amount of divergence in the course of a few months. But this will be still more the case, if the eye, instead of simply remaining stationary, makes an associated movement outwards. It is necessary to test this at short distances (four or six inches), for the eye might be able momentarily to fix its optic axis upon the object, although quite incapable of maintaining this position for any length of time. In both the above cases, the effect of the operation is to be diminished by a conjunctival suture, and particularly so in the latter instance. The effect of the suture will vary with its position, and with the amount of the conjunctiva embraced in it. Its effect will be considerable if it be inserted in a diagonal direction from downwards and inwards to upwards and outwards, so that the inner and outer lips of the wound are united. By giving it this direction, we also prevent any sinking of the caruncle. The suture diminishes the effect of the operation by re-advancing the tendon, which is closely connected with the conjunctiva and subconjunctival tissue; the divided ends, consequently, will be more closely approximated, and the retraction of the muscle diminished. The suture may remain in for from 24 to 36 hours.

The fourth position which the operated eye may assume during accommodation, viz., making a sudden spasmodic movement inwards, must make us fear that there will be a relapse—that in the course of a few months the inward squint will again show itself; for this convergent squint, which at first only showed itself during accommodation for near objects, will gradually extend also to greater distances. In such cases, the operation is said to have been only of temporary benefit; we should therefore, at once intimate to the friends of the patient that the squint may return, and necessitate another operation.

The extent of the operation must be regulated according to the degree of the squint.

In very slight degrees of strabismus (1 to $1\frac{1}{2}'''$) a partial tenotomy was formerly often practised, the tendon not being completely divided, but a few of the upper or lower fibres (as the case might be) being left standing. But this does not answer, as the power of the muscle is but slightly, if at all, impaired. In such cases, we should, therefore, make a complete tenotomy and, if necessary, insert a suture. The conjunctival opening should be small and the hook but of moderate size. The accommodative movements must be accurately tested immediately after the operation; for, if there is the slightest tendency to divergence when the object is brought up to 8 or 6 inches from the eye, a suture should be inserted. In a squint of 2 or $2\frac{1}{2}$ lines, the cellular tissue may be somewhat more freely incised, and a larger hook employed. In children, we find that the effect is generally more considerable, for the muscle is not hypertrophied and the surrounding cellular tissue is very elastic; we may, therefore, in them easily attain an effect of $2\frac{1}{2}$ or 3 lines by a single operation.

If the squint exceeds $2\frac{1}{2}$ or 3 lines, we must always operate upon both eyes. We should perform a free tenotomy in the squinting eye and a very careful one in the other, greatly limiting the effect in the latter by a suture. In this we must be guided by the amount of squint left after the affected eye has been operated upon. As a general rule, I do not think it advisable to operate upon both eyes at the same time, except the squint is very considerable, exceeding $4\frac{1}{2}$ or 5 lines. For if both muscles have been divided at the same time, we cannot accurately test the accommodative movements directly after the operation, and we thus lose the only clue to the permanent effect. It is, therefore, far safer to operate first upon the affected eye, and then, after a few days have elapsed, and the divided tendon has again reunited with the sclerotic, to ascertain how much of the squint is still left. The amount still remaining will guide us as to the extent of the operation necessary upon the healthy eye. If, after having operated upon the latter, we find that the effect somewhat exceeds our wishes, we can always diminish it by a suture. It certainly is far more brilliant to operate upon both eyes at the same time, and thus rid the patient at once of the squint, but then we run the risk of the unpleasant contingency of the eye subsequently "going the other way." It should always be remembered that the cure is to be permanent, and not temporary. In some exceptional cases, however, the risk must be run—if for instance, the time of the patient is limited, or a second visit impossible. If the squint exceeds five lines, we may, particularly in adults, operate safely upon both eyes at the same time. It may be occasionally necessary to operate not only upon both eyes, but even to repeat the operation upon the squinting eye, before we can cure the affection. This generally occurs only in cases of

excessive squint, or if the strabismus has existed for a long time, and the muscle has become hypertrophied. This second operation upon the affected eye requires considerable care, for the effect of the correction will exceed the extent of the retraction, as the influence of the muscle upon the eyeball diminishes in proportion to the backward position of its insertion.

In severe cases, it is still better to operate first upon the squinting eye, and to increase the effect as much as possible by making the patient look over to the opposite side for some days after the operation, so that the cut edges of the tendon may be stretched apart, and widely separated. The effect of this will be, that the union will take place further back than would have occurred if the eye had maintained a median position. If the internal rectus of the right eye has been divided, and we desire to increase the effect of the operation, the patient should be directed to look, as far as possible, towards his right side. The easiest way of attaining this is, by making the patient wear spectacles, the left half of each glass being covered with a piece of court plaister, for he will in this way be obliged to look to the right. They should be worn during the first three or four days after the operation. Or two pieces of card may be fixed over the left half of the eyes, by means of a tape passing over the forehead. By this means, we shall obtain a very considerable effect by the operation, and the amount of squint still remaining, must then be treated by an operation upon the other eye.

Von Graefe points out the fact that, occasionally, though rarely, we meet with cases in which the operation is followed by no effect, either upon the position or mobility of the eyeball, and yet no lateral fibres of the tendon have remained undivided. In such cases, there is a second connexion of the muscle with the sclerotic further back, near the equator; in one instance, indeed, he found it even posterior to the equator.

If the operation for squint be carefully performed, there is no fear of any but the slightest sinking of the caruncle. A little sinking will occasionally occur, whatever mode of operation be employed; indeed, I know of no method which can guarantee a *perfect* immunity from it. Von Graefe thinks that the sinking does not depend so much upon the gaping of the conjunctival wound and retraction of its inner lip, as upon the cicatrization of the connective tissue situated between the muscle and conjunctiva, by which the moveable caruncle is retracted. The further back this cicatrization extends, the more will the caruncle sink. Hence, the danger of incising the tendon too freely, and of any considerable sweeping about with the hook, and consequent extensive laceration of the subconjunctival tissue.

Mr. Critchett's subconjunctival operation is to be performed as follows:—The patient having been placed under the influence of chlo-

roform, and the eyelids kept apart by the stop speculum, he seizes a small fold of the conjunctiva and subconjunctival tissue at the lower edge of the insertion of the rectus muscle, and with a pair of blunt pointed straight scissors, makes a small incision at this point through these structures. The lower edge of the tendon, close to its insertion, is now exposed. A blunt hook (Fig. 83) is next to be passed through the opening in the subconjunctival tissue beneath the tendon, so as to catch up the latter, and render it tense. The points of the scissors (but slightly opened) are then to be introduced into the aperture, and one point passed along the hook behind the tendon, the other in front of the tendon between it and the conjunctiva, and the tendon is then to be divided close to its insertion by successive snips of the scissors. A small counter puncture may be made at the upper edge of the tendon to permit of the escape of any effused blood, and thus prevent its diffusion beneath the conjunctiva (Bowman).

Fig. 83.



Dr. Liebreich* has lately introduced a modification of the operation of strabismus, based upon a different view of the anatomical relations of the conjunctiva, subconjunctival tissue, and the capsule of Tenon to the muscles of the eye. He considers the capsule of Tenon as divided into two portions—an anterior and a posterior—the division being formed at the point where the recti muscles pierce it from without inwards; the capsule being at this point so closely connected with the muscles, as to render any displacement between the two impossible. The posterior half of the capsule, with its smooth, firm, inner surface, forms a cup, in which the eyeball moves freely as the head of a joint in the socket. The close connection between the muscles and the posterior half of the capsule is increased by sheath-like processes, which run backwards from the outer surface of the capsule towards the orbit, and which are, for a certain distance, closely connected with the muscles. But there are no sheath-like processes between the inner portion of the posterior capsule and the sclerotic. The anterior half of the capsule of Tenon adheres to the upper surface of the muscle, and is intimately connected with it. But Liebreich denies the presence of sheath-like processes derived from the capsule, where they pierce the latter, and accompanying the muscles as far as their insertion. He states, moreover, "That the caruncle, together with the semilunar fold rest upon a band-like ligament, which passes from the capsule of Tenon towards the edge of the orbit. Now when the internal rectus is contracted, and the eye rolled inwards, this band is rendered tense;

* "A. f. O.," xii, 2, 298; also "British Medical Journal," Dec. 15, 1866.

and the caruncle, which is fixed to it, is consequently drawn in towards the inner edge of the orbit. But the outer edge of the caruncle, together with the semilunar fold, and an adjoining portion of conjunctiva are drawn backwards into a furrow." This intimate connection between the muscle, capsule, and caruncle, is the reason of the sinking of the caruncle and semilunar fold, which is occasionally observed, after an extensive division of the internal rectus. To obviate these disadvantages, and yet to obtain a considerable effect, Liebreich operates in the following manner:—

"If the internal rectus is to be divided, I raise with a pair of forceps a fold of conjunctiva at the lower edge of the insertion of the muscle; and, incising this with scissors, enter the points of the latter at the opening between the conjunctiva and the capsule of Tenon. I then carefully separate these two tissues from each other as far as the semilunar fold, also separating the latter, as well as the caruncle, from the parts lying behind. When this portion of the capsule, which is of such importance in the tenotomy, has been completely separated from the conjunctiva, I divide the insertion of the tendon from the sclerotic in the usual manner, and extend the vertical cut, which is made simultaneously with the tenotomy, upwards and downwards—the more so if a very considerable effect is desired. The wound in the conjunctiva is then closed with a suture.

"The same mode of operating is to be pursued in dividing the external rectus; and the separation of the conjunctiva is to be continued as far as that portion of the external angle which is drawn sharply back when the eye is turned outwards.

"The following are the advantages of my proceeding:—

"1. It affords the operator a greater scope in apportioning and dividing the effect of the operation between the two eyes.

"2. The sinking back of the caruncle is avoided, as well as every trace of a cicatrix, which not unfrequently occurs in the common tenotomy.

"3. There is no need for more than two operations on the same individual, and therefore of more than one on the same eye."

I have performed Liebreich's operation in numerous instances with much success, and should prefer it to any other in those cases in which it was desirable to gain a very considerable effect, and yet confine the operation to one eye. For I have not found that we are able by any other operation to obtain so considerable an effect with so slight a loss of mobility, and so very little (if any) sinking of the caruncle; yet the inadmissibility of chloroform and the insertion of the sutures have prevented my practising this operation extensively. If chloroform is given, we cannot estimate with exactitude the degree of effect which we are producing by the free incisions in the capsule; and but few

patients are willing to submit to a rather lengthened and painful operation, unless chloroform is administered. The removal of the sutures a day or two after the operation is frequently attended with a good deal of difficulty in children and nervous hysterical women, for although the proceeding is quite painless, yet it is often regarded by the patient and his friends as a second operation. Where it is absolutely necessary for the success of the operation to insert a suture, I never hesitate to do so, but in Graefe's operation this is the exception, whereas, in Liebreich's it is the rule.

I must now describe the method in which certain special forms of strabismus should be treated. The question sometimes arises, whether the periodic squint which is caused by hypermetropia should be operated on, or whether it is to be corrected by the use of suitable convex glasses. If it is but slight in extent, glasses may suffice, but if it is considerable, and the internal rectus is very strong, tenotomy should be performed; for by dividing the internal rectus, we diminish its power, and a greater exertion of this muscle will consequently be demanded, in order to bring the optic axis to bear again upon the object. This extra exertion will be accompanied by an increased power of accommodation, as was the case before, when the eye squinted. But we shall now have an increased power of accommodation with a normal position of the optic axes.

On examining such cases of periodic squint with prisms, we generally find that the internal recti muscles are abnormally strong, this preponderance in strength extending throughout the whole field of vision, so that the correct position of the optic axes, which may occur when convex glasses are interposed, is frequently forced. A carefully performed tenotomy of the internal rectus muscle is, consequently, productive of very favourable results. By advising an operation for this form of periodic squint, I do not propose to set aside the use of convex glasses for the treatment of the hypermetropia; I only think it beneficial to balance the strength of the muscles of the eyeball, and to restore their normal equilibrium, for this will be accompanied by increased facility and comfort in the use of the eyes, particularly for prolonged work at near objects. Whether or not both eyes will require to be operated on, will depend upon the amount of the squint, and the relative strength of the internal recti muscles.

I believe that the best treatment for this form of periodic squint consists in a careful tenotomy of the internal rectus, with subsequent neutralization of the hypermetropia by means of convex glasses. In some cases, the question may, however, arise, whether, by operating upon the periodic squint, we may not only free the patient from the deformity, but also obviate the necessity for spectacles; for, after the

operation, the increased exertion of the accommodation in reading, etc., will be unaccompanied by a squint. This question arises chiefly with ladies, who desire not only to be freed from the squint, but also from the necessity of wearing spectacles.

The periodic squint which occurs in the short-sighted, generally only shows itself when the object is removed beyond the range of accommodation. As this squint disappears as soon as the myopia is neutralized by the proper concave glasses, it might appear unnecessary to have recourse to an operation, but we yet find that this greatly facilitates the continued use of the eyes for near objects. On excluding the affected eye from the act of vision by shading it with our hand, we observe that it then moves inwards, even although the object is held within its range of accommodation; its fixation was, therefore, forced. On testing such cases with prismatic glasses, the internal rectus muscle is generally found to be abnormally strong. It is, therefore, necessary to weaken it, and thus restore the equilibrium, so that the strength of the different muscles of the eyeball may be evenly balanced. But great care must be taken that we do not produce too great an effect, and render convergence of the optic axes for near objects impossible. Hence the power of convergence for a very near point (3″ to 4″) must always be carefully and accurately tested, and if it is found that it is only produced with difficulty, the effect of the operation must be at once diminished by a conjunctival suture. In order that we may not be misled by the temporary insufficiency of the divided muscle, which afterwards partly disappears again, Von Graefe recommends that the point of fixation (both for near and distant objects) should not lie in the median line, but towards the temporal side of the operated eye. For in this position, the temporary insufficiency of the internal rectus will come less into play, and the temporary result will correspond more closely to the permanent.

In slight cases of this form of periodic squint, it may suffice to give the patient concave glasses, so that he may be able to hold the object (book, etc.) at a greater distance. Or, again, we may combine the concave glasses with abducting prisms.

Operation for the cure of Diplopia.—We are sometimes called upon to operate for the cure of diplopia, the deviation of the optic axis being, at the same time, perhaps, hardly perceptible. These form the most difficult and intricate cases, for here less depends upon mere manual dexterity than upon a complete mastery of the theoretical portion of the subject, and a thorough knowledge of the actions of the muscles of the eyeball, and their effect upon the position of the vertical meridian, etc. Having already explained these subjects, I shall only mention the chief points to be considered in the treatment. We must, in the first place, ascertain in what directions prisms have to be turned

in order to fuse the double images, and whether any active tendency exists to unite the images if they are closely approximated. We find that certain kinds of double images are far more difficult to unite than others. It is quite impossible to fuse images which are of a different height, except, indeed, this difference be of the very slightest, equalling a prism of 1°. Crossed double images again, are far more difficult to unite than homonymous. If the double images show a difference in height, we must first endeavour to remedy this by an operation, and then, when this is cured, the patient may be able to fuse them if they are sufficiently close to each other. Should they be crossed, we must change them into homonymous, and approximate them closely to each other, so that they may be easily united.

Secondary Strabismus after Paralysis of the Opponent Muscle.—Our treatment must vary with the amount of immobility in the direction of the paralysed muscle. Let us assume that, after a paralysis of the abductor, the immobility outwards amounts to from 1 to 1½ line, but that there is no deviation inwards, so that the diplopia only extends up to the middle line, or but slightly into the opposite half of the field of vision. In such cases, a simple tenotomy of the internal rectus will generally suffice. If the immobility exceeds 1 or 1½ line, ranging between this and 2 or 2½ lines, a simple tenotomy will not suffice, and we must then bring forward the insertion of the paralysed muscle (operation of "re-adjustment"), and combine with this a tenotomy of the opponent and a suture. If the want of mobility in the direction of the paralysed muscle exceeds 2½ lines, we must bring forward the paralysed muscle, and, at the same time, divide its opponent. Our object in bringing forward the insertion of the paralysed muscle is to afford it an increased amount of power over the eyeball; for, the more anterior its insertion, the greater its power.

The operation of re-adjustment, together with the tenotomy of the opponent muscle, may be performed either according to Von Graefe's, Critchett's, or Liebreich's method.

Von Graefe's mode of operating is as follows:—The lids being kept apart by the speculum, the insertion of the paralysed internal rectus is to be divided just as in the operation for squint, but its connection with the sclerotic is to be more freely severed, and the connective tissue on each side of the muscle more largely incised. The conjunctival wound, though larger than in an ordinary tenotomy, should not be too considerable. We must carefully sever the conjunctiva from the superficial portion of the muscle. Although the latter will still adhere to the lateral expansions of the capsule of Tenon, it will be freely moveable upon the sclerotic, so that the free end of the tendon can be brought up to, or even beyond, the edge of the cornea. In order to retain it in this position, the eye must be turned inwards as far as

possible, and be immoveably kept in this position until the tendon has reunited with the sclerotic at the desired point. We need not fear any ill-effect to the cornea, for its epithelial layer prevents any union between it and the tendon. We must next pass on to the tenotomy of the abductor. A large squint-hook having been passed beneath the tendon, we take a silk thread, carrying a curved needle at each end, and thrust one needle from without inwards through the lower third of the tendon, so as to bring it out below the lower edge; the other needle is then to be passed in the same way through the upper third of the tendon. The free ends of the thread are then to be tied, so that the suture, which is situated betweenthe insertion of the muscle and the hook, will include the two external thirds of the tendon. The tendon is next to be completely divided behind the suture, so that the latter is left firmly attached to the stump. The eye is then to be rolled inwards as far as possible, and is to be maintained in this position by the threads, which should be fastened firmly to the bridge of the nose by strips of plaister. In order to maintain perfect immobility of the eyes, I generally bandage up the healthy eye. Cold water dressings are to be constantly applied so as to subdue any inflammatory symptoms. The threads should be left in for from twenty to thirty hours.

The following is Mr. Critchett's mode of operating:—All the parts covering the inner side of the globe are to be dissected off from the sclerotic (in cases in which a former operation for convergent squint has been followed by secondary divergent strabismus), including conjunctiva, subconjunctival fascia, old cicatrix and muscle, with the condensed tissue around it. He next divides the external rectus, and finally passes sutures through the flap which has been raised at the inner side of the eye, first excising a portion of conjunctiva, and stitches this to the small portion of conjunctiva left standing at the inner edge of the cornea. In this way, the whole muscular layer of the internal rectus is brought forward. I have found this operation very successful in several instances, and prefer it to Von Graefe's on account of the greater ease and certainty with which the tendon of the muscle, whose insertion we have brought forward, is kept in its new situation.

Secondary Strabismus following tenotomy of the opponent, should be treated in the same way as that consequent upon paralysis of the opponent muscle; the prognosis is, however, more favourable than in the latter case.

Dr. Liebreich has favoured me with the following communication respecting his method of performing the operation of re-adjustment. He says, "The same anatomical considerations which led me to devise a modification of the operation of tenotomy, have caused me to modify the operation of bringing forward the insertion of the muscle. It appeared to me to be especially desirable to obviate the necessity of

excising a portion of conjunctiva, from which I have observed considerable disadvantages accrue. I, therefore, operate in the following manner:—After having made a broad vertical incision in the conjunctiva in the region of the insertion of the muscle, or, still better, slightly behind it, I carefully dissect the conjunctiva from the subjacent parts, not only towards the periphery, but also close up to the cornea. I next divide the tendon, and prolong the incision in the capsule of Tenon upwards and downwards. The muscle and the portion of capsule pertaining to it having been thus rendered freely moveable, I next pass at least two sutures (the thread carrying a needle at each end) through the conjunctiva, close to the edge of the cornea, and through the conjointly-seized edge of the tendon and capsule of Tenon. In tying these sutures, both the muscle and the capsule of Tenon are brought up quite close to the margin of the cornea, and retained in this position, remaining, however, covered by conjunctiva. The wound in the conjunctiva is to be closed by the common sutures."

11.—MUSCULAR ASTHENOPIA (INSUFFICIENCY OF THE INTERNAL RECTI MUSCLES).

This affection is of common occurrence, and is characterised by very marked symptoms of asthenopia, which sometimes prove so irksome and harassing to the patient as to incapacitate him from reading, etc. Such patients complain that after they have been working or reading for a certain length of time, the eyes become hot and uncomfortable, the print grows dim, the letters become confused and run into, or overlap, each other. This is generally preceded by a feeling of tension and weight in the eyes and over the brow, and some patients distinctly feel how the one eye becomes unsteady and wavering in its fixation, and then moves gradually outwards. They often also anticipate these symptoms by closing one eye. After resting for a short time, reading may be resumed, to be, however, again interrupted by the same train of symptoms. On examining the eyes, we find that they look normal, that the acuity of vision and range of accommodation are good, but that there is, as a rule, a considerable degree of myopia. If we direct the patient to look steadily with both eyes at an object (a pencil, or our finger), and gradually approximate this to the eye, we find that when the object is brought to about 6″ from the patient, the one eye becomes unsteady and wavering in its fixation, and then either gradually and slowly, or suddenly and spasmodically, deviates outwards. The same deviation occurs (even perhaps if the object is some feet distant) when we cover one eye with our hand or a slip of ground glass, so as to exclude it from participation in binocular vision. Such a deviation will likewise

manifest itself, if a prism is held with its base upwards or downwards so as to produce diplopia, for the double images cannot be fused into one, as the eyes are unable to unite double images which show any, but the very slightest, difference in height. This is a much more delicate test than that of covering one eye with our hand, for it will enable us to detect degrees of deviation of the optic axes, which are too slight to be appreciated by the eye.

We find that the normal eye is generally able to overcome a prism of from 20° to 30° with its base turned outwards, and one of 6° or 8° with its base turned inwards. This is owing to the fact that the internal rectus is much stronger and more exercised than the external. But very few persons can overcome more than a prism of 1° with its base turned upwards or downwards. In consequence of this, diplopia will, therefore, be produced, the visual impulse will be annulled, and the eye yield to the preponderating influence of the strongest muscle. In the normal eye the muscles are equally balanced, and the double images will only show a difference in height, standing straight one above the other. But if either the internal or external rectus considerably exceeds the normal standard of strength, the double images will not only show a difference in height, but also a lateral difference. If the internal rectus is insufficient, the eye will move outwards when a prism is held with its base upwards or downwards, and there will, consequently, be not only a difference in the height of the double images, but they will also be crossed, on account of the divergent squint. We may then easily express the degree of insufficiency by the degree of the prism (base turned inwards) which is required to bring the double images one above the other. This mode of examination is particularly recommended by Von Graefe, who employs the following plan. A dot is drawn on a piece of paper, and is bisected by a fine vertical line (Fig. 84). This paper is placed at the usual distance of reading or writing, and the patient is directed to regard the dot with both eyes. A prism of 14° (with it base upwards) is then to be placed in front of one eye. This will at once produce diplopia, and the image of the eye before which the prism is held will be beneath that of the other eye. If the eyes are normal, the double images will only show a difference in height, but not any lateral difference, they will lie straight above one another. But if the internal rectus is insufficient, the eye moves outwards, and consequently the double images will not only show a difference in height, but also a lateral difference, and they will be crossed. We next try what prism (with its base inwards) is required to neutralize the effect of this deviation, and bring the images straight above each other. In order to ascertain whether the images

Fig. 84.

are crossed or homonymous, we place a slip of red glass before the other eye, and this will enable us at once to distinguish which image belongs to the left, and which to the right eye. After the presence and degree of insufficiency have been thus determined, we should proceed to test the relative strength of the internal and external rectus of each eye, by ascertaining the strongest prism which they are able to overcome. The best object to be used for this purpose is a lighted candle, or a roll of paper, which is to be held at a distance of from 6 to 10 feet. We then place prisms of various strength before one eye, turning the base first outwards, in order to find the strongest prism with which the patient sees single, and this gives us the strength of the internal rectus. The external rectus of the same eye is next to be tried; and then the other eye should be examined in the same manner. Insufficiency of the internal recti is most frequently met with in cases of considerable myopia. The reason of this can be readily understood, if we remember that a person with a myopia of $\frac{1}{6}$ would have to hold any small object (a book, etc.) at a distance of about 5″. This, however, necessitates a considerable degree of convergence of the visual lines, and great exertion of the internal recti muscles. After a time the latter become fatigued, symptoms of asthenopia arise, and if the work is persisted in, one eye deviates outwards. But a temporary insufficiency of the internal recti may also be produced by severe constitutional diseases, which greatly weaken the system (such as fevers, diphtheria, etc.), but it disappears when the patient has regained his strength. It may also co-exist with hypermetropia, and its presence should always be suspected, if the symptoms of asthenopia persist in spite of the use of convex lenses.

The disease may be treated in various ways, according as our purpose is merely to alleviate the asthenopia, or to cure it. It may be alleviated by the use of concave glasses for reading and working, so that the patient can hold the object at a distance of 12″ or 14,″ and thus require a much less degree of convergence. Moreover, the use of prisms with their base turned inwards will relieve the internal recti, but the fear is that, from want of sufficient exercise, those muscles should, after a time, become still weaker. This mode of using prisms is only indicated in the slighter cases of insufficiency, or if there is only a very limited power of abduction for distance, so that there is a risk of producing convergent squint by a tenotomy of the external rectus. These prisms may often be advantageously combined with concave glasses.

Again, the internal recti may be strengthened by frequent exercises with prisms (whose base is turned outwards). The object (a lighted candle, white wand, etc.) is to be placed at a distance of 6 or 8 feet, and a prism, with its base outwards, should be held before one eye. Crossed diplopia will be produced, and in order to overcome this the

patient will voluntarily squint inwards. The strength of the prisms may be gradually increased, but should not be too strong at first, otherwise the internal rectus will be weakened by over-exertion. If the patient is short-sighted, he should wear concave glasses when he is looking at the object. This plan of treatment, however, requires much patience and accuracy, and generally soon proves irksome to the patient.

The best mode of treatment consists in the division of the external rectus, for we thus indirectly strengthen the internal rectus which will have a less resistance to overcome. In a myopia of $\frac{1}{7}$, our chief object must be to enable the patient to converge easily, and for some time, for a distance of about $4\frac{1}{2}''$, as he will hold the print, or his work at about $5\frac{1}{2}''$ or $6''$.

Even if a slight convergent squint is produced for distance, it is of little consequence, as this may be readily neutralized by an effort of the external rectus. The amount of convergence which may be allowed for distance, must depend entirely upon the relative strength of the internal and external recti, and their power should therefore be carefully tested with prisms before any operation is undertaken. Thus, if in a myopia of $\frac{1}{7}$, the internal rectus could, before the operation, only overcome a prism of 4° or 5°, but the external rectus one of 14° or 16°, it would be perfectly safe to permit a convergence of $\frac{1}{2}'''$ or $1'''$ for distance, more particularly if the excluded eye had, before the operation, deviated outwards $\frac{3}{4}'''$ or $1'''$ when covered. In such a case, even after its division, the external rectus would remain sufficiently strong to rectify the convergent squint. The following considerations must guide us as to the extent of the tenotomy:—1. The degree of the myopia, and the consequent distance for which the optic axes must converge in reading, etc. 2. The strength of the prisms which can be overcome by the internal and external recti. The strength of the prism which can be overcome for distance by the external recti gives us a clue as to the extent of the tenotomy, for we may correct with safety the deviation outwards which corresponds to the strength of these prisms. Von Graefe has found that the primary effect of the operation may even exceed this by $\frac{2}{3}'''$ or $\frac{3}{4}'''$, so that, at a distance, homonymous double images arise in the middle line, which require a prism of 10° to unite them. As long as this is not exceeded, we need not fear that the homonymous diplopia will remain permanently. In order not to be misled by the temporary insufficiency of the external rectus, it is better not to hold the object in the median line, but 15° or 20° to the nasal side of the operated eye (Graefe). 3. The degree of deviation outwards (in looking at distant objects), which occurs when the affected eye is covered. The less this divergence is, the more careful must we be with the tenotomy. If the degree of insufficiency

exceeds the prism which the eye can overcome at a distance by abduction, we must only partially correct the insufficiency, and limit the effect of the operation by a conjunctival suture. We may also assist the effect of the operation by using prismatic glasses with the base inwards, for reading, etc. Where the power of abduction is extremely slight, and the insufficiency at a distance almost nil, tenotomy is contra-indicated, for it would be sure to be followed by a convergent squint and consequent diplopia for distance. In such cases, the asthenopia must be alleviated by prismatic glasses. 4. The mode of deviation when the object is approximated to the eye. This test is, however, less accurate than the preceding ones. Von Graefe thinks that a considerable correction is indicated, if the eye moves suddenly and spasmodically outwards at the moment when the insufficiency of the internal recti shows itself; whereas, we must be more guarded in the extent of the operation, if, as the object is brought gradually nearer to the eyes, the one moves outwards in about the same ratio as the other moves inwards, making an associated movement with this. Still more cautious must we be, if the affected eye remains stationary at a certain point, without apparently deviating any further outwards.

If both external recti are much weaker than normal, and if the deviation under the covered hand exceeds $1\frac{1}{2}'''$ or $2'''$, a double operation will be necessary. This, however, should never be done at one sitting. We should first divide the external rectus of the eye most affected, and then, after a few days, when the final result of the operation is apparent, the other eye must be carefully and accurately examined, in order to ascertain to what degree the insufficiency still remains, and to what extent the operation is indicated. It is always safest at the second operation to divide the abductor very carefully and very close to its insertion, and then to test the accommodative movements of the eyes, the amount of convergence at a distance, and the prism required to overcome the homonymous diplopia, and if the convergence at all exceeds our wishes, to insert a conjunctival suture.

Chapter XV.

DISEASES OF THE LACHRYMAL APPARATUS.

1.—DISEASES OF THE LACHRYMAL GLAND.

Inflammation of the lachrymal gland (Dacryo-adenitis) is generally chronic in character, and gives rise to a more or less considerable, firm, nodulated, immoveable swelling at the upper and outer margin of the orbit. The upper portion of the tumour disappears beneath the edge of the orbit, but can be readily followed if the tip of the little finger is inserted beneath the upper and outer orbital ridge. The skin is moveable over the tumour, and the upper eyelid is somewhat reddened and puffy, sometimes, indeed, the redness and swelling may be very considerable, so that the upper eyelid hangs down in a thick, massive fold over the lower. The conjunctiva is somewhat injected and swollen, especially at the retro-tarsal fold, and there may also be considerable chemosis. As a rule, the swelling is but slightly painful, either spontaneously, or to the touch; but if the inflammation is very acute, the pain may be severe, and extend to the corresponding side of the face and head. If the swelling acquires any considerable size, the eyeball will be displaced downwards and inwards, and its movements be impaired in the opposite direction. The inflammation generally runs a very chronic and protracted course, the swelling either gradually undergoing absorption, or chronic suppuration occurring. But if the tumour is so large as to displace the eyeball, or to impair its mobility, it will be necessary to remove it. Sometimes both lachrymal glands* become simultaneously inflamed, giving rise to a symmetrical swelling at the upper and outer edge of each orbit. In rarer instances, the inflammation assumes an acute and sthenic character, there being great heat, redness, and swelling of the part, with perhaps a rapid formation of pus, so that the disease assumes all the appearances of an acute abscess. The latter points, the skin gives way, and there is an escape of pus, which may continue to ooze out for some length of time; subsequently the

* Vide Haynes Walton, "Med. Times and Gazette," 1854, p. 317; and Horner, "Kl. Monatsbl.," 1866, p. 257.

opening closes, the inflammatory products become absorbed, and the swelling gradually disappears. Sometimes, however, the aperture remains patent, and a minute fistulous opening is established, through which the tears ooze forth. The fistula may also occur in chronic suppuration of the gland, being situated either on the external skin or on the conjunctival surface. Such fistulæ prove extremely obstinate and intractable in the treatment, and if the aperture should become accidentally stopped up, severe inflammatory symptoms may supervene. Inflammation of the lachrymal gland may be due to cold, or to a traumatic origin. It may also supervene upon chronic inflammation of the conjunctiva or cornea. Von Graefe mentions cases in which chronic swelling and congestion of the gland were produced by the protracted use of a compress bandage, the retention of the tears in the gland probably exciting irritation.

In chronic dacryo-adenitis we may endeavour to produce absorption of the inflammatory products by the local application of ointments containing iodide of potassium, iodine, or mercury; or by painting tincture of iodine over the part. In the acute form, hot cataplasms and leeches should be applied, and if suppuration threatens, a free incision should be made into the swelling. The same is to be done if pus is formed in chronic cases.

Simple hypertrophy of the lachrymal gland is a rare affection, and may occasionally be somewhat difficult to diagnose with certainty. It may ensue upon repeated inflammatory attacks, or occur spontaneously, and is most frequently met with in children; indeed it may even be congenital. This condition is particularly characterised by the extreme slowness with which the swelling increases in size, and the absence of all redness, pain, or other inflammatory symptoms. The tumour is circumscribed, more or less firm, elastic, and nodulated, and may in time acquire so considerable a size, as to displace the eyeball and curtail its movements. Attempts should be made to disperse it by the application of iodine, mercurial ointment, etc.; but these remedies generally prove unavailing and recourse must be had to operative interference.

Cysts of the lachrymal gland* (Dacryops) are of very rare occurrence, and present the appearance of a little tumour, varying in size from a small bean to a hazel nut, in the upper and outer portion of the upper eyelid, and extending back beneath the edge of the orbit. If at all considerable in size, it is at once observable to the eye, and readily so to the touch. On everting the lid, there is noticed, close beneath the conjunctiva, a bluish-pink, semi-transparent, elastic, and somewhat

* Vide a very interesting paper on this subject by Mr. Hulke, "R. L. O. H. Rep.," 1, 285.

fluctuating swelling, consisting, perhaps, of several nodulated segments of varying size. It springs still more into view, if the lid is retracted and pressed in a downward direction. The swelling, moreover, increases suddenly and markedly in size if the patient cries, or the secretion of tears is stimulated by the application of some irritant to the conjunctiva. The cyst is generally due to the stoppage of one or more of the excretory ducts of the gland, so that the tears are retained, and distend the portion of the duct and gland above the point at which the obstruction is situated. The duct is sometimes, however, patent, so that the tears may slowly ooze out, and the cyst be emptied by pressure.* According to Schmidt,† the disease is sometimes congenital. The best mode of treatment is to establish an artificial opening on the inside of the conjunctiva, so that a free exit may be afforded for the escape of the tears. For if an attempt is made to remove the cyst entire, we shall generally fail, as its wall is very delicate, and the tumour is very apt to recur. Moreover, there is much fear of leaving a small, fistulous opening, which may prove extremely obstinate and intractable in the treatment. Wecker has, however, lately recorded a successful case of removal of a dacryops.‡ An artificial opening of sufficient size may be gained by simply making a linear incision of from $1\frac{1}{2}'''$ to $2'''$ in extent, and keeping it patent by passing a probe every day along its edges, until the latter have become cicatrized. Or again, Von Graefe's§ plan may be adopted, of passing a fine, threaded, curved needle through the aperture of the duct (if this is patent) and carrying it along the anterior wall of the cyst to a distance of about $2'''$, at which point it is to be again brought out, so that a bridge of the anterior cyst wall of about $2'''$ in extent is included within the thread, which is to be tied in a loose loop. The intermediate bridge may either be allowed to slough through, or may be divided at the end of a few days, and thus an artificial opening will be established, through which the lachrymal secretion can flow off.

Fistula of the lachrymal gland is occasionally observed, and may ensue upon dacryops, or an acute or chronic abscess, or be due to a traumatic origin, supervening upon some injury of the gland, or some operation, as for instance the opening or removal of a cyst. The fistulous opening is generally extremely minute, only admitting perhaps the point of a very fine bristle. Through this little aperture the tears ooze slowly forth, and their quantity increases with the augmentation of the secretion of the lachrymal gland during any mental excitement, or irritation of the eye from dust or wind, astringent applications, etc. The affection often proves somewhat obstinate and intract-

* Vide Von Graefe, "A. f. O.," vii, 2, 1.

† Lehre von den Augenkrankheiten, 1817.

‡ "Kl. Monatsbl.," 1867, p. 34.

§ "A. f. O.," vii, 2, 2.

able. The edges of the fistulous opening may be touched with a fine point of nitrate of silver, after the edges have perhaps been first pared; or the obliteration may be attempted by the galvano-caustic apparatus. Again, we may succeed in occluding it by freshening the edges of the aperture, and then closing it with a fine suture. Sometimes, however, severe inflammatory symptoms, followed by the formation of pus, ensue upon the healing or blocking up of the fistulous opening, recurring again and again with great severity. Alfred Graefe* narrates a case of this kind, in which he was finally obliged to excise the lachrymal gland, in order to cure the disease and relieve the patient of this constant suffering and annoyance. Mr. Bowman† succeeded in curing an obstinate and long established external fistula of the lachrymal gland, by establishing an artificial opening on the conjunctival surface by a small seton, and then closing the external aperture.

Various kinds of tumour are met with in the lachrymal gland, but by far the most frequent are those of a sarcomatous nature. Whereas, cancer is of very rare occurrence, and is probably always secondary, extending from the neighbouring tissues to the gland. Knapp‡, however, reports a case of hypertrophy of the lachrymal gland with carcinoma.

Sometimes the secretions of the gland may undergo chalky degeneration and dacryoliths be formed.

Extirpation of the lachrymal gland may have to be performed for hypertrophy or chronic inflammation of this organ, if it produces much disfigurement or displacement of the eyeball. It has, however, been lately strongly recommended as a cure for very obstinate and severe cases of lachrymal disease. This operation has been particularly practised by Mr. Zachariah Laurence for the latter class of diseases, and a full description of the mode of operating will be found in his paper upon the subject.§ The patient having been placed under the influence of chloroform, the surgeon is to divide with a scalpel the skin, muscle, and fascia over the upper and outer third of the orbit, to the extent of about an inch, so as freely to enter the orbit at the situation of the lachrymal gland. The latter may easily be felt with the tip of the little finger, as a small, hard body. If there is any difficulty in finding the gland, Mr. Laurence recommends that the external commissure of the lids should be at once divided by a horizontal incision, which should meet the outer extremity of the first. Thus a triangular flap will be formed with its apex outwards, and the gland can be more readily reached. The latter is then to be firmly seized with a sharp hook, drawn forth, and carefully excised. Tolerably free hæmorrhage generally ensues, but this can be readily arrested by the application of a stream of cold water. The wound is to be closed with fine silver

* "A. f. O.," viii, 1, 279.
† "R. L. O. H. Rep.," 1, 288.
‡ "Kl. Monatsbl.," 1865, 378.
§ "Ophthalmic Review," No. 12, 361.

wire sutures, this should not, however, be done until all bleeding has ceased, otherwise, there may be extensive extravasation of blood into the cellular tissue of the upper lid.

2.—STILLICIDIUM LACRYMARUM (EPIPHORA).

Although the term epiphora is generally applied to every kind of "watery eye," this is, strictly speaking, erroneous, and hence it should only be used in those cases in which there is an undue secretion of tears, and of the mucus secreted by the conjunctiva; so that the canaliculi cannot carry the tears off, but they flow over the lids and cheek. The epiphora may be due to some irritation conveyed to the lachrymal nerves from the conjunctiva or cornea. Thus, if a foreign body is lodged on the conjunctiva or cornea, a considerable degree of lachrymation at once takes place. The same occurs in many of the inflammations of the eye, more especially phlyctenular ophthalmia, the different forms of corneitis, and also in some of the morbid changes of the deeper tissues of the eyeball. Mental emotion will also produce it. The degree of lachrymation will of course vary with the nature and intensity of the morbid process, and also according to individual circumstances. From this condition we must distinguish that in which there is no hypersecretion of tears, but the lachrymation is due to an impediment or obstruction to their efflux through the lachrymal passages. This is termed "*stillicidium lacrymarum.*" In such cases the tears collect at the corner of the eye, causing the patient frequently to wipe his eyes; or else they slowly flow drop by drop over the edge of the lower lid, which gradually becomes sore, red and swollen, from the constant moistening. This irritable condition of the lids then tends still more to increase the lachrymation, and to alter the position and the structure of the puncta and canaliculi. The eyes often become very irritable, the patients complaining much of the constant pricking, heat, and itching in them, which is much aggravated by reading, writing, etc., and by any exposure to bright light, wind, or dust. If the true nature of this irritability of the eye and of the lachrymation is overlooked, very obstinate and intractable inflammation of the edge of the lid and of the conjunctiva may ensue, which sets defiance to every form of collyrium or topical application, but readily yields if the impediment in the lachrymal apparatus is removed, and the stillicidium cured. The obstruction to the efflux of the tears may be situated at any point of the lachrymal canal, at the puncta, the canaliculi, the sac, or the nasal duct.

We sometimes notice in elderly persons, or after a severe illness, that the orbicularis palpebrarum is so much relaxed, that the tears are

no longer propelled by it into the puncta, but that they collect in the central portion of the lower lid, which is sunk down and somewhat everted, in the form of a little pouch or hollow. In such cases, the fluid does not readily pass into the puncta, even although these may be patent. This relaxation of the orbicularis is, in elderly persons, often due to atrophy of the orbital cellular tissue, and perhaps of the orbicularis.

The puncta lacrymalia may undergo certain changes of position and form, or even become obliterated. In their normal position, they are turned directly inwards towards the eyeball, so that the tears which collect in the lacus lacrymarum near the caruncle may be readily guided into the puncta and canaliculi, thence to make their way through the lachrymal sac and nasal duct. Now when the position of the punctum is changed, so that instead of being just sufficiently inverted, it stands erect or is everted, the tears can no longer enter it, but must collect in the corner of the eye and overflow the lid, and a very slight, perhaps almost imperceptible displacement will suffice for this. It has already been stated that this constant moistening of the lids soon makes them very irritable, swollen, and inflamed, which will tend still more to evert the punctum. This malposition of the puncta is most frequently met with after diseases which cause a shrinking of the external skin of the eyelid, as for instance, eczema, or inflammation of the edge of the lid, ectropium, etc. Also, if the conjunctiva or caruncle are much swollen or hypertrophied, so that the edge of the lid is somewhat pushed away from the eye. Small tumours or cysts, situated close to the puncta may also produce it. On the other hand, the malposition of the punctum may not consist in its being everted, but in the edge of the lid and punctum being turned in, which may occur when the eye is much sunken in the orbit. This faulty position of the punctum is very frequently overlooked. The punctum, and a portion of the canaliculus, may also be dilated and have lost its contractility, appearing in the form of a prominent nipple, so that the entrance of the tears is rendered difficult. Or again, the punctum may be greatly contracted in size, or even quite obliterated, having become covered by a layer of epithelium. This is apt to be the case in very chronic inflammation of the conjunctiva and edge of the eyelid, in which the secretions are altered and diminished, and a thin layer of desiccated epithelium is formed over the free edge of the lid and the punctum.

The best mode of treating malposition of the punctum—whether it be erect, everted, or turned in—is by Mr. Bowman's operation of slitting up the punctum and the canaliculus, and thus changing the closed into an open channel, into which the tears can gain ready entrance. This little operation may be performed in various ways, and although it appears simple and easy enough, yet it sometimes requires

a certain degree of nicety and care to perform it quickly and with success, more especially if the patient is timid and restless. Let us suppose that the lower punctum of the right eye is to be divided. The patient should be seated with his head supported against the back of an arm-chair, or the chest of the surgeon. The latter should then, standing behind the patient, introduce a very fine sharp-pointed grooved director (Fig. 85) vertically into the punctum, and then, turning it horizontally, he should run it (with the groove upwards) along the canaliculus as far as the inner edge of the lachrymal sac. Whilst the director is passing along the canaliculus, the skin of the lower eyelid should be put tightly on the stretch, by being drawn outwards and somewhat downwards with the forefinger of the left hand. Otherwise, if the lining membrane of the canaliculus is swollen or lax, it may become tucked up in front of the director, and thus somewhat impede its progress. When the point of the director has reached the further end of the canaliculus, it is to be taken in the left hand, between the forefinger and thumb, the lower lid being at the same time put upon the stretch by the ring finger of the same hand. The patient being then directed to look upwards, the point of a cataract knife (held between the forefinger and thumb of the right hand, the ring-finger of which is at the same time to raise the upper lid) is inserted into the punctum and its edge run along the groove of the director to the inner wall of the sac, so that the lower canaliculus may be slit up to its whole extent. If the patient is very timid and restless, and nips his eyelids very firmly together, the aid of an assistant is generally required. To obviate this, some surgeons employ a very fine pair of straight, blunt-pointed scissors, the one blade of which is to be inserted into the punctum and run along to the extremity of the canaliculus, which should be at the same time put upon the stretch, and then divided at one sharp cut. I myself prefer Bowman's narrow probe-pointed canaliculus knife to any other instrument. It should, however, be made very narrow, and its probe-point be very small, otherwise it may be difficult to enter it if the punctum is very minute. In such a case, the latter should first be somewhat dilated with the point of the director, and this will generally suffice for the ready admission of the point of the knife, which should then be run, with its sharp edge upwards, along the canaliculus quite up to its extremity, and the latter be divided along its whole course by lifting the knife somewhat from heel to point. Care should be taken that the canaliculus is divided to its full extent. For slitting the upper punctum and canaliculus this knife, or the grooved director and cataract knife, may also be em-

Fig. 85.

ployed, although I generally prefer Weber's beak-pointed knife for this purpose.

In selecting this instrument, we must be particular that the nodular point as well as the cutting portion of the blade, are not made too large, else a difficulty will be experienced in inserting it into the upper punctum, and passing it along the canaliculus. The beak point should be passed well down into the sac, so that the upper canaliculus may be divided to its whole extent. The bleeding which follows the slitting up of the canaliculus is generally but very slight, and when it has ceased, the film of blood-coagulum should be removed with a small pair of forceps, from the whole length of the wound, and a little olive-oil be applied to the latter, so as to prevent its closing. Moreover, it is advisable to pass a director along the incision every day for a few days, so as to keep this patent.

But the canaliculi may also be contracted, or partially or wholly obliterated, their passage being narrowed by a swollen and inflamed condition of the lining membrane, or from cicatricial changes which the latter has undergone, in consequence, perhaps, of preceding inflammation. Such cicatrices are most frequently met with after a granular condition of the lining membrane, for the granular inflammation may extend from the conjunctiva into the canal, and even into the lachrymal sac. The cicatrices may, however, be of traumatic origin, having been perhaps produced by wounds or burns, or by the bruising and tearing of the canal caused by a clumsy and rude passage of the probes. The swollen and turgid condition of the canaliculus is due either to an inflammation extending to it from the conjunctiva or the lachrymal sac, or may be caused by the presence of some foreign body within it, such as an eyelash, a dacryolith, or a small fungus. Although the stricture may exist at any point of the canaliculi, it is most frequently situated at the spot where the latter open into the sac.

If the lower punctum should be obliterated (atresia) and quite invisible on the most careful search (aided by a magnifying lens), an ingenious operation of Mr. Streatfeild* may be executed, viz., after having divided the upper punctum and canaliculus, a fine director (suitably bent) is to be passed by this aperture into the inferior canaliculus, and, if possible, through the lower punctum; if not, the lower canaliculus can easily be laid open upon it. This operation will also be found very serviceable in those cases, in which the lower punctum and a portion of the lower canal are obliterated. The converse may also be done, the director may be introduced by the lower punctum, and brought out by the upper. These operations, however, often require considerable dexterity and patience.

If the canaliculus is only narrowed, it should be well laid open in

* "R. L. O. H. Rep.," ii, 4.

the manner above directed. If the stricture exists at the neck of the sac, and is firm and contracted, it should be freely divided with a canula knife, which is to be introduced sheathed, and then, when it has arrived opposite the point of stricture, the sheath is drawn back, and the blade uncovered. This instrument is best introduced by the upper canaliculus, which should have been previously divided; or the stricture may be incised with Weber's knife. After the division, the stricture must be treated by the use of probes. I shall return to this subject and to these instruments in treating of stricture of the lachrymal passages. If the lower canaliculus (owing to a swollen and thickened condition of the lid) remains everted, even after having been divided, Mr. Critchett* advises that a portion of the posterior wall of the canal should be seized and snipped out with scissors, "thus effecting the treble objects of drawing the canal more inwards towards the caruncle, of forming a reservoir into which the tears may run, and of preventing any reunion of the parts." But if the whole or the greater portion of the lower canaliculus is obliterated, it will be different. In such cases, if the patient is troubled with epiphora, the upper canaliculus should be freely slit open along its whole extent, so that the tears may gain an easy entrance. But if this should not suffice, and the lower canal be only partially obliterated, we should endeavour to pass back a very fine grooved director from the opening in the upper canaliculus into the lower one, and lay this open upon the director.

3.—INFLAMMATION OF THE LACHRYMAL SAC (DACRYOCYSTITIS).

This disease is frequently very acute in character, and is then accompanied by intense pain, which extends to the corresponding side of the head and face, and there is, moreover, often marked constitutional disturbance or feverishness. The skin over the region of the lachrymal sac and its vicinity becomes swollen, red, and glistening, and an oval swelling of varying size appears at this spot. The inflammatory swelling often also extends to the eyelids and face. The former become very puffy and œdematous, so that they are only opened with difficulty, and then it is perhaps noticed that the conjunctiva is injected and swollen, and that there is a certain degree of chemosis. From this great swelling of the lids and face, the case assumes somewhat the appearance of erysipelas of the face, for which it might indeed be mistaken by a superficial observer. The swelling is often very sensitive, the patient involuntarily shrinking back from any attempt to touch it.

* Lectures on the Diseases of the Lachrymal Apparatus, "Lancet," 1863, vol. 2, p. 697.

If the inflammatory symptoms are but moderate, the sensitiveness is much less marked, and on exerting a certain degree of pressure, we may be able to press out a small quantity of pus through the puncta, or it may pass down the nasal duct. The swelling and thickening of the lining membrane of the passages may, however, be so considerable, as to prevent the exit of any discharge. Moreover, the opening into the sac may have become somewhat displaced, on account of the swelling of the lining membrane and the enlargement of the cavity of the sac, and thus offer another obstacle to the escape of the contents.

But when the inflammatory swelling has somewhat subsided, and the size of the ducts is thus increased, the discharge may often be very freely squeezed out of the puncta, welling up at the inner angle of the eye and flowing over the lid. Together with the pain, the patient experiences a feeling of dryness and weight in that side of the nose; and if the disease has been preceded by blenorrhœa of the sac, or a stricture in the lachrymal passages, there is always a distinct history of the pre-existence of a more or less considerable and obstinate epiphora. In the acute inflammation of the sac, the onset of the disease is generally very rapid and intense, reaching its acme in the course of a few days. It may, however, be more protracted and chronic in its course, and all the inflammatory symptoms be less marked and severe. If the disease is left to itself, we find that the swelling gains in size, the skin over it becomes thinner and thinner, a distinct feeling of fluctuation is experienced, and finally, the abscess makes a spontaneous opening through the skin, and a considerable amount of pus escapes. The perforation is rapidly followed by a great diminution in the intensity of the inflammatory symptoms. For some time, matter will continue to ooze out through the opening, but finally, the latter may close and cicatrize firmly, and the disease become cured; or there may remain a chronic inflammation of the sac, which often proves very obstinate and intractable. Fresh inflammatory exacerbations may supervene, pus be again collected, and thus a relapse take place. In rare instances, the inflammation is so severe as to destroy the lining membrane of the sac, and the latter may thus become obliterated. Or again, the aperture in the skin may scab over, pus become again collected in the sac, and force its way once more through the opening; this perhaps occurring again and again, until finally a fistulous opening is left, through which a thin muco-purulent discharge and the tears constantly ooze. In yet other cases, the sac may undergo ulceration at one point, and the matter escape into the neighbouring cellular tissue, thus giving rise to a secondary sac or pouch, perforation may finally take place, and a fistulous opening be established, leading (perhaps by a long track) into this deverticulum. In some instances, there are several such pouches burrowing beneath the skin in different

directions. They are, however, generally only met with in the chronic form of dacryocystitis.

Inflammation of the lachrymal sac is often due to an extension of the inflammation of the mucous lining of the nostril to the nasal duct and the sac, or downwards from the conjunctiva and canaliculus. Hence, it may supervene upon nasal catarrh, or conjunctivitis (more especially the granular form). It may also follow blenorrhœa of the sac. Periostitis and caries of the nasal bones, more especially in persons of a scrofulous or syphilitic diathesis, may likewise produce it. It sometimes occurs as a primary affection, being then generally due to exposure to cold and wet. It is often stated that erysipelas is a frequent cause, but it would rather appear that the latter disease is the effect, and not the cause.

Our chief effort in treating these cases must be directed towards the establishment of a free and ready exit for the discharge. This is best done by dividing the punctum and canaliculus quite into the sac. If the opening into the latter is somewhat contracted, I am in the habit of dividing the upper canaliculus with Weber's knife, and then passing the latter into the sac, and freely incising its neck. In this way a very free opening is obtained, through which the contents of the sac can be readily emptied, for a slight pressure upon the latter will suffice to cause the escape of the pus. A probe may then be passed, so as to dilate the neck of the sac and the nasal duct. But if the mucous lining is much inflamed and swollen, it is wiser to abstain from too much meddling and probing, as this only tends to irritate, and excite fresh inflammation. A free exit having been obtained for the discharge, the pain and inflammatory symptoms soon subside, and, moreover, all danger of perforation is prevented. Indeed, by at once employing this mode of treatment, we may often avert this danger, even when the skin over the swelling has already become very thin. To aid in allaying the inflammation, warm poppy fomentations, or a leech or two may be applied. But if the disease has advanced so far that perforation is imminent, the sac should be freely laid open with a scalpel, and the pus evacuated. The incision should run in a downward and outward direction, and be sufficiently large to permit of the ready escape of the discharge. A narrow strip of lint should be inserted into the sac, so as to keep the wound open for a few days, and allow of the draining off of the matter. A warm poultice is to be applied after the operation, and frequently changed for the first day or two. When the inflammation has considerably abated, the canaliculus should be divided and a probe passed into the nasal duct, so that a free passage may be made for the discharge and the tears. The opening into the sac will then soon close firmly, leaving but a very slight cicatrix behind. To hasten the cicatrization, the edge of the opening may be lightly touched

with sulphate of copper. If perforation has already taken place before the surgeon was consulted, the canaliculus and neck of the sac should be freely divided, and a probe passed. In such cases, the edges of the perforation are often very ragged and granular; indeed, there may even be an ulcerated opening of a considerable size. This should be touched with sulphate of copper, a probe be passed daily through the duct, and then the fistulous opening will soon be found rapidly to heal. If any fistulous openings exist in connection with deverticula, they should be freely laid open, and caused to heal from the bottom.

Should a condition of chronic inflammation of the sac, accompanied by a muco-purulent discharge, persist for some time after the perforation is closed, and the more acute inflammatory symptoms have disappeared, the sac should be syringed out with an astringent lotion. Before employing this, it is well to inject the sac with water so as to flush out all the discharge, and then a weak astringent injection (Zinc. Sulph. gr. ii—iv, or Alum gr. ij, Aq., dist. ℥j) should be employed. This will diminish the inflammatory swelling and secretion of the lachrymal passages. This injection should be used every day, or every other day, according to circumstances, and will generally soon produce very considerable improvement. Its strength should gradually be increased. Various kinds of syringes have been devised for this purpose, but the best is a small graduated glass syringe holding about half an ounce. I am in the habit of employing one made for me by Messrs. Weiss, which differs somewhat from that in ordinary use. The instrument consists of two separate parts, the canula and the syringe.

The silver canula is of the size of Bowman's No. 6 probe, and is about three inches in length. At the top is a cross bar, by which it can be easily held and directed, and beyond this bar is a portion of india-rubber tubing about $1\frac{1}{4}$-inch in length, ending in a silver mount into which the nozzle of the syringe fits firmly. The advantage of the india-rubber tubing is, that when the canula is passed quite down into the nasal duct, the patient can lean forward with his face over a basin, and the surgeon, standing in front of the patient, can bend the india-rubber tube forward to the necessary extent, and readily insert the nozzle of the syringe, and thus inject the fluid without any difficulty. Whereas, with the ordinary silver canula it is often difficult to do so, on account of the prominence of the brow. The fitting of the nozzle into the canula by a plain mount is much better than by a screw, because if the screw sticks a little, or the patient is restless, the lining membrane of the lachrymal passages may easily be bruised in the endeavour to screw the nozzle on. The instrument is to be used in the following manner:—The canula is to be passed down, by the upper or lower canaliculus, through the sac into the nasal duct, and allowed to remain there for five or ten minutes, so as to dilate the passage. The

patient being then directed to lean his face well forward over a basin, the nozzle of the syringe is gently inserted into the canula, and the fluid slowly injected, which will flow out through the nostril into the basin. Whilst injecting, the surgeon should, with his left hand, seize the canula by the cross bar, and slowly withdraw it, so that the fluid may come in contact with every part of the duct and sac. The first injection should consist of water, in order to wash away the discharge, the canula should then be re-introduced, and the astringent injection be used. Mr. Bowman employs a small india-rubber ball syringe, but the stream from this is often too weak to force its way through, if the lining membrane of the sac and duct is greatly swollen, or the stricture very firm. If the case proves very obstinate, and the patient cannot possibly submit to a lengthened course of treatment, and is yet anxiously desirous to be relieved of the complaint, it may be necessary to destroy the sac, but such a course should only be followed in very rare and exceptional instances. I shall, however, return to this subject when treating of blenorrhœa, and of obstinate strictures of the duct and sac.

4.—BLENORRHŒA OF THE SAC (MUCOCELE).

This disease is often developed very slowly and insidiously, coming on without the patient being almost aware that there is anything the matter, except perhaps a little epiphora, and a slight and occasional swelling in the region of the lachrymal sac, accompanied, if the latter is pressed, by a little oozing out of turbid, viscid discharge, which, passing over the cornea, dims the sight. The swelling of the sac varies considerably in size and hardness. It is generally elastic and firm, and the skin somewhat red; on squeezing out the discharge, the tip of the finger sinks a little into the skin. The distension of the sac undergoes considerable alterations, varying with the changes in the temperature, and the exposure to which the patient subjects himself. As long as the weather is warm and dry, the patient may be quite free from any trouble, but as soon as he exposes himself to a cold bleak wind or a damp atmosphere, the sac becomes inflamed and swollen, the eye is watery, and on pressure upon the sac, a copious discharge wells up through the puncta. The frequent recurrence or long existence of this condition, leads to a thickened and villous state of the lining membrane of the sac and ducts, and the secretion becomes more thick and muco-purulent in character. If it constantly regurgitates through the puncta, these and the canaliculi may become somewhat dilated. Stricture of some part of the nasal duct, or of the canaliculus near its opening into the sac, if it has not already occurred, will generally soon supervene.

In some cases, the sac, instead of being thickened and hypertrophied,

becomes thinned and greatly distended; being filled with a thin, glairy, viscid fluid which flows down the nasal duct, or oozes up through the puncta.

Blenorrhœa of the lachrymal sac is almost always met with as a secondary affection, being often consecutive upon an inflammation of the Schneiderian membrane, which, ascending along the nasal duct, has reached the sac. Hence nasal catarrh, and periostitis or caries of the nasal bones are not unfrequent causes of the disease. Or it may supervene upon inflammation of the conjunctiva (more especially granular ophthalmia), or of the edge of the lid. Malposition or contraction of the puncta, or a narrowing or stricture of the lachrymal canal also often produce it. Indeed, obstructions in the lachrymal passages, either above or below the sac, are very fruitful sources of blenorrhœa. This disease is therefore often met with in cases in which there is a narrowing, obliteration, or eversion of the puncta; or a contraction or stricture of the canaliculus or of the nasal duct, which may be due to inflammatory swelling of the lining membrane, or to presence of cicatrices. Polypi or other growths, which by compression narrow or obstruct the duct, may also give rise to it. Persons in whom the root of the nose is very flat and broad, and the eyes far apart, are very subject to diseases of the lachrymal apparatus, on account of the diminution of the antero-posterior diameter of the duct. But the same thing may occur, as Arlt and Wecker point out, if the nose is very prominent and narrow, so that the passage is much narrowed laterally. Blenorrhœa of the sac often supervenes upon acute inflammation of the latter, which, after having perhaps caused repeated perforation and escape of the discharge, passes over into a state of chronic inflammation, accompanied by a thinnish muco-purulent discharge. Acute inflammatory exacerbations recur every now and then, and a more or less extensive and firm stricture of the lachrymal or nasal duct is almost always present.

Only in very rare instances do we find that the disease, if left to itself, undergoes any considerable or permanent improvement, much less a cure. For even in spite of the best and most patient treatment, it often proves very obstinate and intractable. The lining membrane of the sac and duct becomes hypertrophied and swollen, and often undergoes extensive cicatricial changes, being transformed into a fibro-tendinous tissue, and the discharge becoming thin, glairy, and viscid, or in some cases of a thick gluey character (Stellwag).

Strictures of the lachrymal passages vary very considerably in extent, firmness, and situation. Their most frequent seat is the point where the canaliculi open into the sac, or where the latter passes into the nasal duct; but they may also be situated at a lower part of the

duct, and hence the necessity of always passing the probe through the whole length of the latter, in order that we may ascertain whether any stricture exists at its lower portion. If the stricture be due to a thickened, swollen condition of the lining membrane, and if it be considerable in extent, it will oppose a certain degree of obstruction to the passage of the probe, and will embrace the latter firmly and closely, but will yield to the gentle yet steady pressure of the probe. The dense cicatricial stricture affords a more obstinate resistance, and it may be difficult to pass even a very small probe, without employing a considerable degree of force. The symptoms to which a stricture gives rise, are, epiphora, blenorrhœa or inflammation of the sac, and a glairy, viscid or muco-purulent discharge.

The first and fundamental principle in the treatment of blenorrhœa of the sac and stricture of the lachrymal passages is, to divide one or both puncta and canaliculi, and to pass a probe down through the nasal duct. The mode of dividing the puncta and the canaliculi has been already described. The probes which are best adapted for catheterization, are those of Mr. Bowman,* which are made of silver, and of six different sizes. No. 1 is very small, like a fine hair probe; No. 6 is about $\frac{1}{20}$ of an inch in diameter. Mr. Teale Pridgin, of Leeds, recommends a bulbed probe, which is also preferred by Mr. Critchett,† who thinks that it passes more readily, and is less apt to lacerate the mucous lining, or to make a false passage. I, as a rule, use Mr. Bowman's probes, but frequently employ a considerably larger size than No. 6. The instrument is to be introduced in the following manner:—The end of the probe having been slightly bent, so that it may pass more readily forward into the nasal duct, its point should be inserted vertically into the lower punctum, the skin being at the same time put on the stretch, and then passed horizontally along the opened canaliculus until its extremity reaches the inner wall of the sac, which is easily recognised by its presenting a hard, bony obstruction to the probe. The latter is then to be turned vertically, the convexity of the bend looking backwards, and slowly and gently passed into the sac; when the latter is gained, the direction of the instrument must be slightly altered, the point being directed somewhat outwards and forwards, so that it may readily pass into the nasal duct, through which it is to be pushed until it reaches the floor of the nose. When the lining membrane of the sac and of the duct is much swollen and hypertrophied, it is sometimes rather difficult to find this entrance, as it may be somewhat displaced or contracted, or more or less covered by a small fold of the mucous membrane, which thus forms a little valve over it. If, after some careful searching, we do not succeed in finding the opening into the nasal

* "R. L. O. H. Rep.," i, 10.

† "Lancet," 1864, vol. i, 147.

duct, it is better to withdraw the probe and to wait for a day or two until the inflammatory swelling has subsided, than to attempt to force the passage of the probe; for this may not only produce severe laceration of the membrane, but lead to the formation of a false passage; or the probe should be withdrawn, its curvature somewhat altered, and then be again inserted, in the hopes of finding the aperture. The first probe that is passed should only be of medium size (No. 3 or 4 of Bowman), but if the stricture is very considerable, No. 2, or even No. 1, may have to be tried before it can be passed. The instrument should be allowed to remain in the duct for five or ten minutes, and then gently withdrawn, and this catheterization should be repeated every day or every other day, according to the exigencies of the case. The size of the probe should be increased until we arrive at No. 6. If the probe is arrested at the point where the canaliculi join the sac, the skin near the tendo oculi will be moved with the movement of the probe, and an elastic obstruction be felt; whereas, when the instrument has entered the sac, the skin does not wrinkle or move.

The sac often becomes considerably diminished in size, and its walls thinned, if on account of displacement of the puncta, or stricture of the canaliculi, the sac has been empty for a very long period. We then find great difficulty in introducing the probe into the sac, as it repeatedly slips out again. In many cases, it suffices to open the lower canaliculus and to pass the probe through it; in others it may be necessary also to divide the upper one. This is more especially the case if we desire to get a very free opening into the sac, to pass an extra sized probe, or if there exists any stricture at the entrance of the sac, where the canaliculi open into it. If the latter be the case, I prefer to open the upper punctum and canaliculus with Weber's beak-pointed knife, the point of which should then be passed quite down into the sac, and the internal palpebral ligament freely divided subcutaneously. In doing so, the slightly convex cutting edge of the blade should be turned forwards and outwards, and the internal palpebral ligament divided subcutaneously, with a slightly sawing movement. It will be felt to grate a little, and its division is followed by more or less copious bleeding. This having been done, a probe should be passed down to ascertain the exact situation, nature, and extent of any existing stricture.* Weber uses for this purpose a graduated bi-conical sound, which increases very rapidly in size from the point upwards. This is to be forced through the stricture, if the latter readily yields; if this is not the case, but the lining membrane is much swollen and inflamed, it is better to postpone the probing for a few days, until the inflammatory swelling has subsided,

* Vide Weber's articles on Diseases of the Lachrymal Apparatus, "A. f. O.," viii, 1, 107; and "Kl. Monatsbl.," 1863.

to hasten which end, injections of water and of astringent lotions are to be employed. The internal palpebral ligament may also be divided with Bowman's canula knife; the upper canaliculus is to be freely divided, and then the point of the knife is to be passed, sheathed, into the sac, the sheath withdrawn, and the ligament divided subcutaneously; or the director and cataract knife may be used. Weber's knife will, however, be found more convenient for this purpose. The opening into the sac may also be widened with Bowman's dilator, the blunt blades of which, in separating like those of scissors, dilate the opening into the sac.

For some years past, bougies of laminaria digitata have been used by several surgeons of eminence. They were first introduced for this purpose by Mr. Couper, and have been extensively employed by him and Mr. Critchett. I have also often used them with marked success in cases of very obstinate stricture. Their peculiar advantage consists in their imbibing the fluid in the lachrymal passages, and swelling up to double and treble their original size. But there is the danger that they may swell up to such an extent *beyond* the point of stricture, that the dilated bulbous part can only be drawn back through the stricture at the expense of much contusion or even laceration of the lining membrane at this point, or, what is still worse, that in the great effort to extract the probe it may break short, and necessitate its excision. The best mode of obviating these difficulties, and yet at the same time to produce a slow and gradual dilatation, is to draw back the probe a very little at intervals of a minute or so, in order that it may not have time to swell up considerably, below the stricture. By this gradual retraction, the latter will, moreover, be gently dilated by the enlarging probe. By pursuing this method, and by always being extremely careful to use these probes with delicacy and gentleness, I have found great benefit from their employment. Their use, however, requires so much supervision, that it is somewhat difficult to find sufficient time in hospital practice; where the patients are so numerous, that one may easily forget to withdraw the probe a little at short intervals, and let it swell up too much. In order to limit the dilatation to the point of stricture, the rest of the bougie may be covered with copal varnish.

If the blenorrhœa proves obstinate, and the discharge as well as the swelling of the sac and duct continue, great benefit is found from the systematic use of astringent injections, of sulphate of zinc, alum, or acetate of lead. Their strength must vary according to the amount and nature of the discharge and the degree of swelling of the lining membrane. Before their use, the sac must be washed out with an injection of water. The patient should also be directed frequently to press out the discharge, for if it is allowed to accumulate in the sac

and to become decomposed, it proves a source of considerable irritation, and may even set up acute inflammation of the sac.

Dr. Stilling of Cassel, has devised a cure for strictures of the lachrymal passages by internal incision.* The punctum having been divided, he passes down a probe and finds the exact seat of the stricture, then withdraws the probe and passes down his knife† (Fig. 86) to the stricture, and divides it in three or four directions. This having been done, he withdraws the knife, re-introduces the probe, and, if another stricture is found further down, also divides this. Dr. Warlomont, in a very recent article in the "Annales d'Oculistique," ‡ speaks in the warmest terms of his great and immediate success with this operation, and recites several cases. He operates in the following manner:— The upper punctum having been divided with Weber's knife, he next passes Weber's bi-conical sound down into the nasal duct, and leaves it there for a few minutes. On its removal, he immediately passes Stilling's knife completely down into the nasal duct, so that its whole blade disappears, and then incises the duct in three or four directions, until the knife can be turned quite freely in all directions. No dilator or probe is introduced after the operation; and, according to Stilling and Warlomont, even severe and obstinate cases are thus immediately and permanently cured. The favourable action of this operation appears to be chiefly due to its affording a very free exit to the contents of the sac.

Fig. 86.

Dr. Herzenstein proposes the forcible dilatation of the stricture, on the principle of Mr. Barnard Holt's dilatation of stricture of the urethra.

We sometimes find that the alterations in the lining membrane of the sac are so great, that they persist even after the passage of the tears is unobstructed; and then it may be necessary to have recourse to some direct treatment of the sac. Thus, if the latter is not only much dilated, but also thickened and secreting much muco-purulent discharge, Mr. Bowman has dissected out the anterior half of the thickened sac. Mr. Critchett has treated such cases successfully by laying open the sac, and destroying a portion of the interior with potassa cum calce. As

* Vide Dr. Stilling's brochure, "Ueber die Heilung der Verengerungen der Thränenwege mittelst der Innern Incision." Cassel, 1868.

† The blade of this knife is 13 mm. long, 3 mm. broad nearest the handle, and gradually narrows down to ¾ mm. at the point, which is somewhat rounded but cutting. The blade passes over into a flat stem, which is about the size of Bowman's largest probe, and is attached to the handle. The back of the blade should be made strong and rather wedge-shaped, and its temper should not be too fine, otherwise, it may easily break or a portion of it chip off, in forcing it through, or in incising the stricture. This knife may be obtained of Messrs. Weiss.

‡ "Annales d'Oculistique," Oct., 1868.

this condition of the lining membrane of the sac, as well as the considerable dilatation of the latter, are to a great extent maintained and increased by the constant flow of the tears into the sac, Weber* has remedied this by producing an eversion of the punctum, so that the tears cannot flow into the canaliculus; thus causing them to collect in the little reservoir, formed by the lower lid being slightly turned away from the eyeball. He gains this end, by passing a needle, armed with a stout thread, through the skin and muscle close to the punctum, and bringing it out again a little further inwards, so as to embrace the punctum and a small fold of the skin within the suture, which is to be tightly knotted. This will readily produce a slight ectropium, and the beneficial effect of preventing the entrance of the tears into the lachrymal sac, will generally be already evident within 24 hours afterwards. I have sometimes gained great benefit in such cases from the application of a firm compress bandage over the sac, which prevents the entrance of the tears. This mode of treatment is also of great use in those cases in which the sac is much thinned and dilated, and secretes a large quantity of thin glairy discharge. Mr. Critchett† has devised an ingenious little truss, so as to keep up a gentle and continuous pressure.

If the stricture is very firm and dense, and there is much tendency for it to close after the removal of the probe, a style may be passed into the duct by the slit canaliculus, and left in for a few days. The upper portion is to be very thin and bent at a very acute angle, so as to be bent over the lower lid, thus keeping the other portion *in situ*. The bent portion may also be made so thin and small, that it will lie along the opening made in the lower punctum, and thus be invisible. Mr. Bowman first introduced this mode of treatment, and it is often attended with success, but in some cases, the style sets up a considerable degree of irritation, and may even give rise to ulceration if it is left in too long. The size of the style should be gradually increased as the stricture yields, until it has attained dimensions considerably larger than Bowman's probe No. 6. Dr. Seeley of Cincinnati informs me, that he uses this mode of treatment to a very considerable extent, and with marked success. The old-fashioned style, which used to be inserted into the nasal duct through an external opening in the sac, has fallen into well-merited and almost entire disuse.

In very severe and obstinate cases of chronic inflammation of the sac, accompanied perhaps by ulceration and periostitis, and a severe stricture or even closure of the duct, cases which resist every mode of treatment and prove a great and constant source of annoyance and

* "Kl. Monatsbl." 1865, 106.

† Lectures on Diseases of Lachrymal Apparatus, "Lancet," 1864, 1, 148.

trouble to the patient, it may be necessary to obliterate the sac. This is also indicated if the patient cannot remain under medical treatment for a sufficient length of time to lead to any reasonable hope of benefit by the usual mode of treatment, and is yet very anxious to be relieved from this very troublesome affection. This mode of treatment should, I think, be only adopted in very exceptional cases, which have resisted every other means of treatment. For it is surprising what a degree of improvement may often be attained by treating these cases with patience and care, although it must be confessed that a very long time is but too frequently required before much improvement takes place. Obliteration of the sac is, moreover, only indicated if the natural secretion of the tears is not considerable, so that they are nearly entirely carried off by evaporation, otherwise, great and annoying epiphora remains after the destruction of the sac.

Various methods of destroying the sac have been devised and recommended. At one time, the actual cautery was extensively employed for this purpose, but lately the galvano-caustic apparatus has been largely substituted for it. The sac is to be opened by a free incision, which is to extend likewise through the tendo-oculi into the upper portion of the sac, which forms a cul de sac above the tendon, and thoroughly cleansed out. When the hæmorrhage has ceased, the lips of the wound are to be kept apart by Manfredi's speculum, which is moreover provided with side plates to prevent the cheek from being burnt. Instead of the actual cautery or the galvano-caustic apparatus, various caustics are often employed, *e.g.*, nitrate of silver, butter of antimony, potassa c. calce, perchloride of iron, etc. I myself prefer the nitrate of silver, which I first saw employed for this purpose with great success by Von Graefe. It is easily manageable, very safe, and leaves the smoothest and least unsightly cicatrix of any caustic. Before attempting to destroy the sac, the puncta and canaliculi must always be first obliterated, so as to stop the entrance of tears into the sac, otherwise their admission will prevent, or at least greatly retard, the adhesive inflammation and obliteration of the sac. The best method of closing the puncta and canaliculi is to pass into them a very fine probe, coated with nitrate of silver, or a thin hot wire, which will set up adhesive inflammation, thus obliterating the puncta, and closing the canaliculi. When this end has been obtained, the sac must be laid open to its whole extent by a free incision, thoroughly cleansed out, and when the bleeding has entirely ceased, the walls of the sac should be touched with nitrate of silver. Cold compresses should be applied to diminish the inflammatory symptoms. The nitrate of silver should be repeated several times, at intervals of about two days, before the epithelium is formed. Or at the end of forty-eight hours the thick eschar should be completely removed, and a small firm compress be

applied to the sac, so as to bring its raw surfaces together, a firm bandage being placed over the compress, in order to keep it in situ.

At the Ophthalmological Congress, held at Heidelberg this autumn, Dr. Berlin narrated several cases of very obstinate and severe disease of the sac, in which he obtained a successful result by extirpation of the latter.

In severe and intractable cases of epiphora, inflammation of the sac, etc., the extirpation of the lachrymal gland has been strongly urged by several surgeons, more especially by Mr. Zachariah Laurence,* who has practised it extensively; it has also been employed by Mr. Carter, Dr. Taylor, Mr. Windsor, and others.

5.—FISTULA OF THE LACHRYMAL SAC, ETC.

By this term is understood a communication between the lachrymal sac or passages and the external integument. I have already mentioned, when speaking of the inflammation of the sac, that after spontaneous perforation of the latter, a more or less extensive fistulous opening may be left, which may prove very obstinate and intractable if there is a very firm or impassable stricture, or considerable disease of the bone. Caries and necrosis of the bony walls of the sac are a very frequent cause of fistula. The latter, on the other hand, is but very rarely produced by direct injury, or a wound of the sac. The fistula may either open directly into the sac, or there may exist a fistulous track of varying length. The edges of the fistula may be at first swollen, irregular, and somewhat ulcerated, the ulceration perhaps extending to some distance from the aperture. But after a time it contracts in size, its margin becomes smoother, and finally, only a very minute opening, which hardly admits the finest probe, may be left, this is sometimes termed capillary fistula. If the orifice is retracted, and its edges covered with healthy-looking skin, the minute aperture may be easily overlooked, but on pressing the sac, a small tear-drop will be seen to exude.

The best treatment for lachrymal fistula is that of slitting up the puncta, dividing the internal palpebral ligament, and passing a probe down frequently. If the passage is free, this will generally cause the fistula to heal in the course of a few days. But if the passage is impermeable, or the disease of the bone extensive, it may be necessary to obliterate the sac, or to force the passage. The latter is to be done with one of Bowman's probes or Weber's dilator. But extreme care must be taken to do this with delicacy, for if rude force be used, much mischief is sure to accrue. In the capillary fistula, the edges of which

* Vide Mr. Laurence's article, "On Removal of the Lachrymal Gland as a radical cure for Lachrymal Disease," "Ophthalmic Review," No. 12.

are covered by smooth skin, it is sometimes advisable to pare the edges, so as to make them raw, and then to close the minute aperture with a suture, which will cause the opening to heal by first intention.

Polypi of the sac are of rare occurrence. They closely resemble nasal polypi in structure, and may attain the size of a small nut. They give rise to a peculiar feeling of resilience and elasticity to the finger, and although on pressure a certain quantity of glairy or mucopurulent fluid may be evacuated, yet we cannot empty the sac completely. On incising it, some fluid escapes, and the polypus (like a gelatinous mass) springs into the wound.* If the sac is extensively diseased, or there is a very firm stricture of the nasal duct, it may be necessary to obliterate the sac after the removal of the polypus.

Cases of hæmorrhage into the sac, producing thus an impermeability of the latter, are of rare occurrence. Two instances of this kind have been recorded by Von Graefe†. The presence of chalky concretions (dacryoliths) in the ducts or in the lachrymal sac is also but rarely observed.

Whilst in some instances, there is an absence of the punctum in either lid, which is generally due to its obliteration by inflammation, it may also occur that there is more than one punctum. These supplementary puncta are generally met with in the lower lid, and are situated quite close to the punctum proper‡.

* Vide a case of Von Graefe's, "A. f. O.," i, 283.

† "A. f. O.," iii, 1, 337.

‡ Vide cases of Supplementary Puncta recorded amongst others by V. Graefe, "A. f. O.," i, 1, 288; Weber, ib., viii, i, 1, 352; and Zehender, "Klin. Monatsbl.," 1863, p. 394.

Chapter XVI.

DISEASES OF THE ORBIT.

1.—INFLAMMATION OF THE CELLULAR TISSUE OF THE ORBIT (CELLULITIS ORBITÆ).

The symptoms and course of this disease are generally of a very acute and severe inflammatory character. The eyelids become rapidly swollen, red, and hot, the palpebral and ocular conjunctiva much injected, and there is mostly great serous chemosis, surrounding the cornea in the form of a thick dusky-red mound, the edges of which may even overlap and partially hide the cornea. The patient complains of intense, intermittent pain in and around the eye, and extending over the corresponding side of the forehead. There is also generally marked, febrile constitutional disturbance; and if the inflammation should extend from the orbit to the cranium, severe cerebral symptoms will supervene. The eyeball soon becomes protruded. At the outset of the disease, this protrusion is not very marked, and may only become evident when the two eyes are compared. But when the inflammatory swelling of the orbital cellular tissue increases, and still more when pus is formed, the exophthalmos rapidly augments, perhaps even to such a degree, that the dusky, swollen lids can no longer be closed over the eyeball, but the latter projects more or less between them. If the pus collects chiefly at the bottom of the orbit, the protrusion is uniform, and straightforward in the axis of the eyeball, and not in one particular direction, as is generally the case in the exophthalmos accompanying periostitis of the orbit. The movements of the eyeball are also uniformly impaired, and not especially so in one direction. If the patient attempts to move the eye, or it is touched, more especially if it is slightly pushed back into the orbit, intense pain is produced. But this is not the case if the point of the little finger be gently passed along and somewhat beneath the edge of the orbit, and we do not find a special point, where its touch excites great pain, as is the case in periostitis. The formation of pus is generally accompanied by well-marked rigors.

From the exposure of the protruded eyeball to the atmosphere, the secretions on the surface of the conjunctiva and the chemotic swelling become dried in the form of hard, dark crusts. The surface of the cornea may also become roughened and clouded, from desiccation of its epithelium and its exposure to mechanical irritants. The sight is often much impaired by the stretching of, or pressure exerted upon, the optic nerve, and the retinal veins are generally more or less engorged and tortuous; there being, perhaps, at the same time a serous infiltration of the disc and the retina in its vicinity. The field of vision is also somewhat contracted, often considerably so. If the exophthalmos lasts for any length of time, optic neuritis may supervene upon the congestion and engorgement of the optic nerve, followed, perhaps, by consecutive atrophy of the latter.

If the pus be formed in sufficient quantity, it makes its way forward from the bottom of the orbit, and may cause distinct fluctuation behind the conjunctiva or the lids; and it perforates either through the lid or through the conjunctiva, and in the latter case, it will appear to come from within the eye. But the inflammation and suppuration may also invade the eyeball, and panophthalmitis be set up; pus will appear in the anterior chamber, the pain will be still more increased in severity, and will only be ameliorated when the cornea gives way, and the lens and the humours of the eye are evacuated. Sometimes, the swelling of the eyelids is so tense and great, that all sense of fluctuation is lost.

Although the severity of the inflammatory symptoms met with in orbital cellulitis vary considerably in degree, the disease generally runs a more or less acute course. But according to Mackenzie,* the latter may, in very rare instances, be extremely chronic. Not until a very long time, perhaps many months, has elapsed, does matter accumulate in the orbit, and then the eye gradually protrudes, the lids become somewhat swollen and red, the pus makes its way to the surface, the skin gives way, and a sinus may be left, often proving extremely obstinate in the treatment.

In framing our prognosis, we must always remember that cellulitis not unfrequently becomes complicated with periostitis, leading subsequently to caries or necrosis. That, moreover, the inflammation may extend backwards along the periosteum to the membranes of the brain, producing meningitis or abscess of the brain. If caries or necrosis of the walls of the orbit has taken place, the pus may make its way through this aperture into the cranium or antrum of Highmore, etc. Moreover, the patient's general health, already perhaps undermined by a long and very serious illness, may give way beneath the acute and protracted sufferings produced by the disease, if the latter is improperly

* Diseases of the Eye, 299.

allowed to run its course, and is not arrested and relieved by a timely evacuation of the pus.

Amongst the most frequent causes of inflammation of the cellular tissue of the orbit, are contused or incised wounds of, and the lodgement of foreign bodies in, the orbit. The disease may also be caused by sudden changes of temperature, and exposure to cold and wet; and it may occur secondarily in severe constitutional diseases, such as pyæmia, puerperal fever, etc. It may also be due to the extension of the inflammation from neighbouring parts, as in erysipelas of the head and face, severe inflammation of the lachrymal sac, or operations performed upon the latter, more especially its destruction by the galvano-caustic apparatus or very strong caustics; or it may ensue upon panophthalmitis, or operations upon the eye or eyelids.

The treatment should be chiefly directed to subduing and arresting the inflammatory symptoms. If the disease is due to an injury, the treatment suitable to its special character (vide Injuries of the Orbit) must be adopted, and cold compresses and leeches should be applied. But if suppuration has already set in, these applications should be changed for hot poppy fomentations or hot poultices, and a free incision with a bistoury should be made at an early period, in order that the pus may be evacuated. If much doubt exists as to the true nature of the disease, a small exploratory incision should be made, and if pus is found to ooze out, the incision should be sufficiently enlarged to permit of its free and ready escape. If possible, the opening should be made through the conjunctiva, and not through the eyelids; but if the abscess points directly beneath the latter, the incision must be made at this spot.

In making the incision through the conjunctiva, the upper lid should be raised with the finger, and a scalpel, or the point of a cataract knife, passed through the conjunctiva above the upper edge of the eyeball into the orbit. Care should be taken that the globe is not injured, and to avoid this, the edge of the knife should be directed somewhat upwards. Warm poultices are then to be applied, and the edges of the wound are to be kept open by daily passing a probe between them If the track of the wound is deep and long, and a fear is entertained that it may not heal from the bottom, a small dossil of lint should be inserted as a tent, and changed every day. The sinus should also be syringed out once or twice a day with a mild astringent lotion (Zinc. Sulph. gr. iv. Aq. dist. ʒij). If the healing of the sinus prove obstinate and protracted, a careful examination must be made as to the presence of carious or necrosed portions of bone. In the latter case, time should be allowed for the loosening or detachment of the spicula of bone, and the incision should then be sufficiently enlarged, and the fragments of bone removed with a pair of forceps.

If panophthalmitis co-exists with the abscess in the orbit, and there

is pus in the anterior chamber, paracentesis should be performed, and the pus evacuated.

The patient's health should be sustained by a generous diet and tonics, care being at the same time taken that the bowels are kept well open, and febrile symptoms alleviated by maintaining a free action of the kidneys and the skin.

When the pus has been evacuated, the protrusion of the eye will gradually diminish, and the latter re-assume its normal position. If the eye has otherwise escaped all injury, and the impairment of vision was simply due to stretching of the optic nerve and stasis in the retinal circulation, the sight will rapidly improve. Sometimes, however, a curtailment of the movements of the eye in certain directions may remain behind.

2.—PERIOSTITIS OF THE ORBIT.

We meet with two forms of periostitis of the orbit, the *acute* and the *chronic*.

In the *acute* periostitis, the inflammatory symptoms are often very severe and pronounced. The patient complains of great pain in and around the eye, and the constitutional symptoms may also be very severe. The eyelids, more especially the upper one, become swollen, red, hot, and painful, but the swelling and redness are, as a rule, not so extreme, and do not advance with such rapidity, as in cellulitis of the orbit; moreover, in periostitis, the swelling of the two lids is not alike in degree, but one is generally more swollen than the other. The ocular conjunctiva and sub-conjunctival tissue are injected, and there is more or less serous chemosis. The eyeball becomes somewhat protruded, even perhaps to such a degree (if much pus is formed) that the eyelids cannot be closed. The protrusion is not, however, straightforward, as is generally the case in abscess of the orbit, but towards one side, the movements of the eyeball are therefore not curtailed equally in all directions, but more in certain directions than in others. This is due to the fact that the periostitis is chiefly and specially confined to one wall or one portion of the orbit. Thus, if the inner and upper wall of the orbit are affected, the eyeball would protrude downwards and outwards, and the movements would be especially curtailed in the upward and inward direction. If the tip of the little finger is passed along the upper or lower edge of the orbit, and pushed somewhat back into the cavity, we are often able to detect a point where its pressure causes severe pain, and where there is distinct swelling, thus indicating the seat of the disease. Sometimes, the patients can themselves localize the situation of the periostitis with much exactitude. In the course of acute periostitis, the cellular tissue generally also becomes extensively

inflamed, a great amount of pus may be formed, the eye be very considerably protruded, and its movements greatly, or even completely, impaired. The disease then assumes a mixed type of periostitis and abscess of the orbit. The periostitis is generally accompanied from the outset by a certain degree of inflammation of the bone itself.

In the *chronic* periostitis, the inflammatory symptoms are far less pronounced, and the disease is more protracted and insidious in its course. The swelling and redness of the eyelids, the injection of the conjunctiva, the chemosis, and the protrusion of the eye, are generally far less severe than in the acute form. Pain is experienced in and above the eye, which mostly increases in severity towards night, and is markedly augmented by pressure upon the edge of the orbit, or by pressing the eye backwards in a certain direction. Sometimes, decided swelling of the orbit can be detected at one point. A certain amount of suppuration generally takes place, and if pus is formed in considerable quantity, it will, of course, cause great protrusion of the eye. As a rule, however, the suppuration is limited, and the pus is apt to accumulate between the periosteum and the bone, and lift up the former. The periosteum often becomes greatly swollen and thickened, giving rise perhaps to little nodules or tuberosities. These may subsequently again diminish in size, and finally only leave a somewhat thickened condition of the periosteum, or they may undergo ossification, and thus give rise to exostoses. If the bone becomes involved, caries, and often necrosis will result, and the inflammation or the pus may extend through the aperture in the orbit to the cavity of the cranium, or into the frontal sinus. Indeed, the great danger of the disease is, that the inflammation should extend from the orbit back to the membranes of the brain, and set up fatal meningitis, or that an abscess should be formed in the brain.

Periostitis is sometimes met with in infants, and is indeed far more common amongst young persons than in adults. The most frequent causes of acute periostitis are penetrating wounds of the orbit with sharp cutting instruments; or severe contusion of its edge from blows, or blunt instruments; and the lodgement of foreign bodies within the orbit. It may also be secondary, the inflammation extending from the periosteum of some of the neighbouring cavities, *e.g.*, frontal sinus, maxillary space, etc. Exposure to damp and cold and to sudden changes of temperature may also give rise to it. As already stated, it may likewise appear in the course of inflammation of the cellular tissue of the orbit. Chronic periostitis is most frequently due to syphilis.

The general plan of treatment resembles very closely that recommended for inflammation of the cellular tissue of the orbit, and if the presence of pus is suspected, it should be evacuated as early as possible. Where the disease is due to syphilis, the iodide and bromide

of potassium, in combination with some preparation of mercury, should be administered, or the mercurial bath should be employed. Care should be taken not to enfeeble the patient's health, but to fortify it as much as possible by tonics and a generous diet.

3.—CARIES AND NECROSIS OF THE ORBIT.

At the commencement of a carious affection of the bones of the orbit, there is generally a certain degree of œdematous swelling of the eyelids, which are also somewhat red and perhaps painful. The conjunctiva and subconjunctival tissue are injected, and the eye is irritable and watery. The œdema of the eyelids is often very considerable, particularly in children of a scrofulous diathesis. Soon, a spot is noticed where the eyelid assumes a more dusky red tint; here the abscess points, the skin gives way, and through this small perforation a thin scanty, muco-purulent or "stringy" discharge oozes out. On passing a probe through this aperture, we find that it leads to a portion of bare roughened bone. The edges of the opening generally become somewhat everted, swollen, and ulcerated, and covered perhaps with fleshy granulations. A portion of the bone, as a rule, becomes necrosed, and small fragments are exfoliated. After this condition has lasted for a more or less considerable length of time, the sinus closes up, the aperture heals, but during the process of cicatrization, the integuments become adherent to the periosteum, and thus an eversion of the lid, perhaps of very considerable extent, may be produced, causing a great exposure of the eyeball (lagophthalmos) with all its deleterious consequences.

The course of the disease is often most protracted, especially in persons of feeble health, and of a scrofulous or syphilitic diathesis, in whom relapses are very apt to occur. The disease improves, the sinus and external aperture appear to be healing kindly, when a relapse takes place, fresh symptoms of inflammation supervene, the discharge again increases in quantity, and fresh portions of bone are perhaps exfoliated.

Caries and necrosis may occur in different portions of the orbit; thus, the bottom of the latter may be the seat of the disease, as is often the case after periostitis of this portion of the cavity. In rarer instances, it may supervene upon inflammation of the cellular tissue of the orbit, accompanied by periostitis. Sometimes the caries is confined to the margin of the orbit, or it occurs just within the cavity near the edge. In such cases, the upper or lower lid, according to circumstances, may become extensively involved in the cicatrix, and a very considerable ectropium result. These cases of caries and necrosis of the margin of the orbit are generally the result of a blow or fall upon this

part, and are frequently met with in children, more particularly those of a scrofulous diathesis. Syphilis is a frequent cause of caries of the orbit, and the disease of the bone may in such cases be due to an extension of the affection from the nasal fossæ.

The principles of treatment should resemble those recommended for periostitis. The pus should be evacuated as early as possible, the fistulous sinus be washed out frequently with warm water or mild astringent injections, and a small tent of lint should be introduced, in order to cause the sinus to heal from the bottom. If a loose spiculum of bone is detached with the probe, the external opening should be somewhat enlarged, and the fragment be carefully removed with forceps. The treatment of the lagophthalmos and ectropium consequent upon the caries, is fully described in the articles upon these subjects.

4.—INFLAMMATION OF THE CAPSULE OF TENON.

The fibrous capsule which envelopes the eyeball (capsule of Tenon) is occasionally subject to inflammation. This disease is particularly distinguished by the appearance of a more or less marked chemosis round the cornea, there being at the same time considerable conjunctival and subconjunctival injection. On closer examination, we find that there is no apparent cause for this chemosis, for the cornea, iris, and deeper tunics of the eye are unaffected, and the sight and the field of vision are also good. The eyelids are likewise somewhat red and swollen. The eyeball is, moreover, slightly protruded, although perhaps to so inconsiderable a degree that it might escape observation unless the state of the two eyes is compared. There is, at the same time, a certain impairment of the movements of the eyeball, which is especially evident in the extreme movements in different directions, when diplopia will also arise. The pain in and around the eye may be somewhat severe, but it never reaches the same intensity as in cellulitis or periostitis of the orbit. The progress of the disease is generally slow, eight or ten weeks perhaps elapsing before it is cured.

It is generally of rheumatic origin, being due to a draught of cold air, as, for instance, in railway travelling, etc., or to sudden changes of temperature. It is also seen in cases of irido-choroiditis supervening upon operations, especially those for cataract. According to Wecker, it may also follow the operation for strabismus, if the sclerotic has been much exposed, or the capsule of Tenon too freely incised.

If the inflammatory symptoms are severe, a few leeches should be applied to the temple, and warm poppy fomentations be prescribed, together with the compound belladonna ointment. If the Tenonitis is due to a traumatic origin, as, for instance, in the operation for strabismus, ice compresses should be applied.

5.—EXOPHTHALMIC GOITRE (GRAVES'S DISEASE, MORBUS BASEDOWII, ETC.).

This is a very interesting and peculiar disease, the true nature and cause of which are at present unknown. Amongst the first symptoms are, generally, great palpitation and acceleration of the action of the heart, the pulse perhaps reaching 120 or 150 beats in the minute. There is at the same time much nervous excitement and dyspnœa. Sometimes there are, moreover, symptoms of gastric derangement, such as frequent and obstinate retching and vomiting, or diarrhœa. It is now perhaps also noticed that the eyes have a peculiar and somewhat staring look, which is due to a retraction of the upper eyelid, leaving the eyeball much uncovered, and giving an expression of astonishment to the patient. Moreover, as Von Graefe has pointed out, the upper lid does not quite follow the movements of the eyeball when the person looks upwards or downwards, but remains somewhat too elevated. This elevation of the upper lid is quite independent of the exophthalmos, and generally appears during the stage of progression, and may disappear without any diminution in the protrusion of the eye. It may also, according to Von Graefe, be relieved by the use of subcutaneous injection of morphia. The cardiac symptoms may have lasted perhaps some little time before those of bronchocele and exophthalmos present themselves. The latter symptoms generally appear about the same time, but do not necessarily bear any absolute relation to each other, and need not co-exist; for, according to Prael,* in exceptional instances, the bronchocele may be absent. There is, moreover, nothing peculiar in this form of bronchocele, excepting that the veins are generally much dilated, even, perhaps to such a degree that the disease might be termed "bronchocele aneurysmatica;" and often a distinct diastolic murmur can be heard in them. According to Virchow,† there is, at the commencement, only a simple swelling of the thyroid gland, the disease becoming gradually developed into a true bronchocele. Degenerative changes, of a gelatinous or cystoid nature may then occur, or nodulated, fibroid indurations be formed. As all these changes occur also in common bronchocele, Virchow thinks it probable that the affection of the thyroid is of a *secondary* nature.

At the commencement, the cardiac affection seems simply to consist in the greatly increased action and violent palpitations of the heart, but after a time dilatation and hypertrophy, more especially of the left ventricle, ensue. There is often a marked bellows murmur, without

* "A. f. O.," iii, 2, 209.

† "Krankhafte Geschwülste," iii, 1, 76.

perhaps any valvular affection, and the murmur may extend into the aorta and carotid. The pulsation in the carotid is sometimes quite evident at a little distance from the patient. The aorta and larger arteries have occasionally been found to have undergone atheromatous changes.

The exophthalmos may become so considerable, that the eyelids cannot be closed over the cornea, but the latter, and a more or less considerable portion of the sclerotic, protrude between them. The protrusion of the eye is not generally straightforward, in the direction of the optic axis, but towards one side, frequently the nasal. On account of the constant exposure of the uncovered cornea to the influence of external irritants, its epithelial covering becomes roughened and thick, ulcers are formed, which, extending in circumference and depth, may lead to extensive perforation of the cornea, and even to subsequent atrophy of the eyeball. The eyelids at the same time become inflamed, the ocular conjunctiva injected, and perhaps œdematous, and of a dusky-red colour from constant exposure to the atmosphere and irritants. The suppuration which may occur in this disease is not, however, of neuro-paralytic origin, but Von Graefe thinks it is due to a paralysis of the "trophic" fibres of the fifth nerve, as was shown in Meissner's experiments.

Cases of suppuration of the cornea are not, however, of frequent occurrence, and I have only met with a single instance of the kind, where a young woman affected with exophthalmic goitre, had lost both eyes from suppuration of the cornea, and the eyeballs, although shrunken, were still very prominent. According to Von Graefe, it occurs more frequently amongst men than women; thus out of 14 cases in which suppuration took place, it occurred ten times in men and four times in women.*

The exophthalmos is due to hypertrophy of the adipose cellular tissue of the orbit, and to a hyperæmic swelling of this tissue, which may at first be diminished by pressure and rapidly disappears after death.† Recklinghausen has also observed fatty degeneration of the muscles of the eyeball. Dr. Wright‡ found, besides strong dilatation of the veins, a small quantity of half coagulated blood extravasated over the eyeball.

The true cause of the disease and the nature of the connection between the affection of the heart, the thyroid gland, and the eye are at present unknown. It was supposed by some authors, that the pressure of the enlarged thyroid upon the cervical blood-vessels caused the protrusion of the eye. In opposition to this view it may, however, be urged that we often meet with very large bronchoceles without any

* Berliner, "Klin. Wochenschr.," 1867, 649. † Virchow, l. c., 76.
‡ "Med. Times and Gazette," 1865, Nov.

exophthalmos; and, on the other hand, as has been shown by Praell, the latter may exist without any enlargement of the thyroid gland. Others have supposed that the symptoms are due to anæmia, and Mackenzie speaks of the disease as "Anæmic Exophthalmos." But it is impossible that anæmia could be the direct cause of such a condition, and it could, therefore, as Virchow points out, only act in so far, that the morbid condition of the blood exerts a deleterious influence upon the nerves.

It is, however, far more probable that the affection is due to an irritation or neurosis of the sympathetic nerve, producing hypertrophy of the adipose tissue of the orbit and dilatation of the veins. There is, moreover, another fact which would argue in favour of this view of irritation of the sympathetic, viz., the retraction of the upper lid; for H. Müller discovered unstriped muscular fibres in the upper lid, which are supplied by branches of the sympathetic. Any irritation of these nervelets would cause an elevation of the lid, whereas, if this irritability were allayed, the retraction would disappear. Now the latter, as has already been mentioned, may be observed to occur after the subcutaneous injection of morphia. The anatomical conditions of the sympathetic have, however, been found to vary considerably. Thus some observers (Wright, Moore, Trousseau, etc.) found the cervical ganglia of the sympathetic enlarged, hard, and firm; and, on microscopical examination, they were seen to be filled with a granular substance, like a lymphatic gland in the first stage of tuberculosis. The trunk of the sympathetic, as well as the branches going to the inferior thyroid and vertebral arteries, were found to be enlarged. Whereas Recklinghausen,* on the contrary, observed that the trunk and the ganglia of the sympathetic were diminished in size, as if atrophic, without, however, presenting any histological changes. One fact, which argues rather against the assumption that the disease is due to irritation of the sympathetic, is the condition of the pupil; for the latter was only in some cases dilated.

Virchow, in speaking of the functional disturbances, also calls attention to the fact, that together with the disappearance of the bronchocele in consequence of small doses of iodine, marked acceleration of the pulse, and palpitation of the heart may be observed. Now as the same thing has been occasionally noticed when spontaneous diminution of the bronchocele has taken place, the question arises whether these symptoms may not be due to an admixture of soluble goitre-material with the blood.

The disease occurs most frequently in women, especially during the time of puberty, or during confinement. It is also observed to be paired with disturbances of the uterine functions, particularly chlo-

* Virchow, l. cit., p. 80.

rosis, and may supervene upon severe constitutional diseases. According to Von Graefe, it is not only more rare amongst men, but in them it occurs at a later period and with greater severity. It has been caused by severe bodily labour, or mental shocks, fright, great depression, etc.

The course of the disease is mostly very slow and protracted, and relapses are very apt to occur, more especially if there still exists great disturbance in the action of the heart. Amongst men, the prognosis should be very guarded, as the disease assumes a much more severe character, and is more frequently complicated with serious affections of the cornea. On account of the impediment produced in the intra-ocular circulation by the exophthalmos, the retinal veins are sometimes dilated and tortuous, but otherwise there are no changes in the fundus, and the function of the retina is generally unimpaired. Hypermetropia may arise on account of the flattening of the eye.

With regard to treatment, the most benefit seems to be derived from the administration of tonics, more especially the preparations of quinine and steel, together with a generous diet, plenty of open-air exercise, and, if necessary, a change of air and a prolonged residence in the country. A firm compress bandage will often cause the exophthalmos to diminish considerably. The peculiar retraction of the upper eyelid may be, if necessary, alleviated by an operation upon the levator palpebræ, as has been advised by Von Graefe. He was formerly in the habit of recommending tarsoraphia for this elevation of the upper lid, but now prefers a partial tenotomy of the levator palpebræ superioris. The latter operation is to be performed as follows:* The horn spatula having been introduced beneath the upper lid, so as to put it well on the stretch, he makes a horizontal incision through the skin of the upper lid, extending nearly the whole length of the latter, and situated about 1‴ above the upper edge of the tarsal cartilage. He then divides the orbicularis, or, still better, excises a small horizontal portion of it, in order to gain a better view of the subjacent parts. A careful exposure of the tarso-orbital fascia will bring into view the vertical or oblique striation which indicates the tendon of the levator palpebræ, which here passes over into, and becomes blended with, the cartilage. With a very narrow knife, the point where they are blended is then to be incised at each side, so that only a narrow central bridge (of about 1‴ in width) remains standing. Care must of course be taken not to perforate the conjunctiva. The result of the operation is an incomplete ptosis, which diminishes considerably during the first few weeks, the remainder just neutralizing the retraction of the upper lid which before existed.

* Vide Compte-Rendu of the Congrès d'Ophthalmologie, 1867; also "Kl. Monatsbl.," 1867, p. 272.

6.—TUMOURS OF THE ORBIT.

It would be quite beyond the plan and scope of this work, to enter at length into all the varieties of tumour that may be met with in the orbit, as well as the points of difference in their structure, diagnosis, and mode of development; I shall, therefore, confine myself to a broad and practical division of this subject, and shall endeavour briefly to give the most characteristic and leading features presented by the principal varieties of tumour, as well as the different modes of treatment which are more especially indicated.

Tumours of the orbit may be developed primarily in the latter, or may commence within the eye or one of the neighbouring cavities, and, gradually increasing in size, finally make their way into the orbit. As long as the tumour is confined within the eye, its progress may be slow and protracted, but when it has once perforated the ocular tunics, its growth, being no longer restrained by the firm sclerotic, is often very rapid, so that it may within a short time attain a very considerable size.

Tumours may be developed from any part of the orbit; they may spring from the bottom of the cavity, from its walls, or from its most anterior part close to the edge. As the morbid growth increases in size, the eyeball will be more and more protruded, and the direction of this protrusion will depend upon the principal situation of the tumour. The exophthalmos may finally become so great, that the eyeball is quite pushed out of the orbit upon the cheek. Together with the protrusion, the movements of the globe will be more or less impaired. The eyelids are generally swollen and œdematous, and the œdema may be so great, that it is impossible to judge of the true nature of the tumour, or it may even obscure the presence of the latter. If the tumour is chiefly situated at the upper part of the orbit, a certain degree of ptosis is frequently present. The eyelids are in other cases greatly everted, their exposed conjunctival surface being swollen and fleshy in appearance. There is often also a very considerable degree of chemosis of a dirty, dusky-red tint. The sight may suffer from the optic nerve being stretched or pressed upon by the tumour, or from the impediment to the intra-ocular circulation. The efflux from the retinal veins is retarded, symptoms of inflammation of the optic nerve may supervene, and if the tumour be not removed, the optic nerve may undergo consecutive atrophy. But the sight may also be greatly impaired, or even lost from inflammation or extensive ulceration of the cornea, dependent upon its constant exposure to the action of external irritants, when the eye is much protruded. Perforation or sloughing of the cornea may ensue, and the contents of the globe escaping, the eye may gradually undergo atrophy.

In attempting the removal of any tumour of the orbit by operation, we should always take into anxious consideration its size, rate of progress, suspected nature, and situation; as well as the condition of the eye, and the general health of the patient. If there is still sight, we should always endeavour to remove the morbid growth, if possible, without sacrificing the eye. But in some cases, more especially of malignant tumours, it is quite impossible to remove the whole of the morbid growth, without the removal of the eye; and in such instances, it is far wiser to sacrifice the latter, than to run the risk of leaving portions of tumour behind, to prove the ready source of a recurrence of the disease. We should, if possible, remove the tumour through the conjunctiva, but if this is not practicable, the incision must be carried through the skin of the lids. The incision should in such a case be always horizontal, and perhaps slightly curved, so as to correspond with the natural wrinkles of the skin, and thus avoid the formation of unsightly cicatrices.

In order to gain more room to work in, it may also be necessary to divide the outer canthus. We should always endeavour to extirpate the tumour without any injury to the neighbouring parts, and for this reason the knife must not be two freely used, but the attachments of the tumour should rather be loosened with the tip of the finger, the handle of a scalpel, or with the point of a silver knife. In some tumours, it is necessary to gouge out the different portions, or to snip them off the walls of the periosteum with a pair of blunt-pointed, curved scissors. The use of the chloride of zinc paste in cases of removal of malignant tumours, as well as those whose recurrence may be feared, will be considered when speaking of these tumours in detail.

(1.) FIBROUS TUMOURS.

The fibrous tumour is especially characterised by the fact that its structure closely resembles that of the radiating fibrillar connective tissue, the fibrillæ being closely packed together. On a section, such a tumour presents a firm and perhaps somewhat rough surface, traversed by bundles of parallel fibres. Its colour is of a greyish-white, or greyish-yellow tint. The tumour is always surrounded by a distinct sheath of thickened connective tissue, and is penetrated by a small number of vessels. These tumours may undergo secondary changes, and cysts may be formed, and in such a case their firmness is diminished, and a certain degree of fluctuation may be perceptible; and if this is considerable, they may be easily mistaken for cysts. Or again, they may undergo osseous or calcareous changes, the bone being generally met with in the form of small spicula.

These tumours grow from the periosteum either by a broad base, or

by one or more pedicles. They are generally formed near the edge of the orbit, and if they are stalked, they may be felt in the form of small, firm, circumscribed, moveable growths. The consistence of the tumour may vary very considerably. It is generally firm and hard, from the thickening and condensation of the radiating, connective tissue elements. In other cases, however, it is softish and perhaps lobulated, or the surface may be soft and the central portion, or that nearest to the point of origin from the periosteum, may be firm and hard. The progress of the tumour is generally very slow, and the firmer varieties do not, as a rule, acquire a very considerable size. It is different, however, with the softer kinds, as they may attain a great magnitude. Thus Mooren* mentions a fibrous tumour of the orbit which, after a former operation, attained the size of a child's head, and involved the bones of the face and head. Mr. Critchett† narrates a remarkable case of fibrous tumour of the orbit removed at two sittings. Zehender‡ has also recorded a case, in which he successfully removed a large fibrous tumour (preserving the eye), and applied the chloride of zinc paste on a strip of plaster to the bottom of the orbit, the surface of the leather on which the caustic paste was spread being turned outwards away from the eye, and the latter protected by the interposition of a thick layer of charpie. This, however, only just sufficed to save the eyeball from the action of the paste, as the outer surface of the globe was covered by a slight layer of eschar, the sclerotic remaining, however, uninjured.

If the fibrous tumours are small in size, and situated near the edge of the orbit, they can generally be removed without any danger; but if they are large, extend deeply into the orbit, and are widely attached to the periosteum, either by a broad base or by several pedicles, operative interference must be extensive, and may set up very considerable inflammation, extending perhaps to the periosteum of the orbit, and from thence to the brain. Or the operation may be followed by fatal erysipelas.§

(2.) SARCOMATOUS (FIBRO-PLASTIC) TUMOURS.

Sarcomatous tumours are particularly distinguished in their minute structure by the fact that they are composed of various shaped, closely packed cells, and a scanty intercellular substance. These cells vary much in size and form, being stellate, circular, oblong, spindle shaped, etc. If the cells contain pigment, it is termed melanotic sarcoma. The

* Mooren, "Ophthalmiatrische Beobachtungen," p. 41.
† "Med. Times and Gazette," 1852, p. 465.
‡ "A. f. O.," iv, 2, 55.
§ Vide Mackenzie, p. 327.

fibro-plastic variety show marked spindle-shaped cells with a large ovoid nucleus and long, perhaps subdivided, filamentous extremities. On account of this peculiar shape of the cell, and these long terminal projections, it was formerly supposed that the connective tissue was formed by a division of these cells. But this, as Virchow* points out, is erroneous, for it is the special characteristic of these tumours that their cells persist as cells, and do not become developed into connective tissue; for if this development took place, and a considerable formation of fibrillar intercellular substance really occurred, and if the cells were transformed into fibres, the tumour would simply be a fibroma and not sarcomatous. In fact, the fibro-plastic tumour is nothing but a spindle-shaped celled sarcoma. The malignant fibrous and recurrent fibroid tumours of Paget are also varieties of sarcoma. The amount of the fibrillar intercellular substance varies considerably in quantity. In some cases, it is firm and dense, in others, on account of the great development of the cells, it may have nearly disappeared; in the latter case, the tumour is very soft and becomes medullary.

Sarcomatous tumours are not benign in character, but show a great tendency to infection of neighbouring organs, commencing first in the homologous tissues, and then passing on to the heterologous. But they also affect distant organs, and as the lymphatic glands frequently remain unaffected, it has been supposed that the infection is carried more by the blood than by the lymphatic vessels.

According to Virchow, the sarcomatous tumours of the orbit "are generally developed from the adipose cellular tissue behind the eye, after a time pushing the eyeball out of the orbit, and appearing beneath the conjunctiva in the form of round, firm protrusions, finally assuming a fungoid character. Their commencement may often be traced to distinct traumatic causes. If no operation is performed, the eye is in the end destroyed by pressure or inflammation, and at the best becomes atrophied. Or again, the fungus may grow inwards, reach the dura mater, invade the cranium, and generally ends in metastases, amongst which, those of the bones of the skull, are the most remarkable. Most of the orbital sarcomata have a softish consistence, and belong to the melano-, myxo-, or gliosarcomata. They are generally multi-cellular. But even those consisting of smaller cells may be operated upon with success."† Frequently, the sarcomatous tumours, especially melanotic sarcoma, originate in the eyeball, and subsequently make their way into the orbit.

The great danger of the disease is its extension into the neighbouring cavities, the bony walls, which separate these from the orbit, being destroyed by caries or necrosis, or worn through by the pressure of the tumour. In such a case, the extension of the growth in an outward

* "Krankhafte Geschwülste," ii, 1, 180. † Ib., p. 349.

direction may be slow and protracted. The operator thinking that he has only to deal with a moderate, sharply defined tumour, is surprised to find it extending far into neighbouring cavities, in which it has perhaps reached a very considerable size (Stellwag).

But the tumour may be originally developed in some other cavity, as for instance the nasal fossa,* or antrum of Highmore,† and extend thence into the orbit.

These tumours are very apt to recur, and may have to be operated upon several times. Thus in a case narrated by Mr. Quain he operated three times.‡ If the sight is unaffected, we should endeavour to remove the tumour without sacrificing the eyeball, and in order that all remains of the morbid growth may be removed, the chloride of zinc paste, spread upon strips of lint, should be inserted into the wound, care being taken that the dry side of the lint is turned towards the eye, and the latter should be still further protected by the interposition of layers of charpie. That the caustic may be applied without injury to the eyeball or its muscles was already shown in Zehender's case; Mr. Hulke§ has more lately published a similar instance.

But where the disease is extensive, the eyeball lost, or there is no doubt as to the malignant nature of the disease, the globe must be excised with the tumour, and the latter should be as thoroughly removed as possible. But the excision of the morbid growth with the knife and blunt-pointed curved scissors alone, will not suffice in cases where the tumour is of a sarcomatous or carcinomatous nature, and infiltrates more or less the neighbouring structures; for then it cannot with certainty be completely removed, and remnants of tumour are sure to be left behind. The surgeon should endeavour to remove as much as possible of the morbid growth by chipping it away from the walls of the orbit, exploring beforehand with the finger the mass which he is about to excise. If the walls of the orbit are also affected, the periosteum, or even portions of the diseased bone, may be readily removed with the elevator. In order to check the hæmorrhage, and to destroy any remaining portions of the morbid growth which could not be reached with the scissors, the hot iron should be applied to the wounded surface, and then, when all bleeding has ceased, the chloride of zinc paste, spread upon strips of lint, is to be applied to the wound. The chloride of zinc paste has been used extensively, and most successfully, at the Middlesex Hospital, where the following formula is generally employed:—One part by weight of chloride of zinc is rubbed up with four parts of flour, to which sufficient tinctura opii is added to make a paste of the consistence of honey.

* Graefe, "A. f. O.," i, 1, 419.

† Pagenstecher, "Klinische Beobachtungen," i, 76, 1861.

‡ "Med. Times," 1854, No. 201. § "R. L. O. H. Rep.," v, 4, 346.

To many surgeons the use of the hot iron and of an escharotic to the orbit will appear a most dangerous proceeding, on account of the thinness of the roof of the orbit, which divides it from the brain. But experience proves that this proceeding, if carefully and expertly performed, is not fraught with any particular risk, for the action of the hot iron is superficial, and that of the chloride of zinc can be also very well regulated. Moreover, it produces little or no constitutional disturbance, and only excites slight inflammation of the living tissues beyond the slough. The truth of these statements is sufficiently proved by the very remarkable cases in which this line of treatment has been pursued by Mr. De Morgan, Mr. Moore, Mr. Hulke, and Mr. Lawson, and which have been brought before the notice of the profession at different periods.

Mr. Hulke* reports a very interesting case of large fungating melanotic sarcoma which had become developed from a shrunken eyeball, filled the cavity of the orbit, and protruded between the eyelids, which was successfully extirpated with the aid of the actual cautery and chloride of zinc paste.

A very interesting and important case of recurrent fibroid tumour, which has been operated upon several times by Mr. Lawson, is recorded in the forthcoming number of the "R. L. O. H. Reports."

(3.) FATTY TUMOURS OF THE ORBIT.

The fatty tumours are developed in the adipose cellular tissue of the orbit, either in its cavity or between the recti muscles, just beneath the conjunctiva. They generally occur in early life, and are sometimes perhaps congenital. They increase slowly in growth, are not accompanied by any symptoms of pain or inflammation, and vary much in size and consistence. The latter will depend upon the relative amount of the fatty material, and the firmness and quantity of the fibro-cellular tissue. They are often very elastic to the touch, and give rise to a sense of fluctuation, which may deceive us as to their true nature, and cause them, perhaps, to be mistaken for a cyst. No difficulty is generally experienced in their removal, which should, if possible, be done from within the eyelid.

(4.) OSSEOUS AND CARTILAGINEOUS TUMOURS.

According to Mackenzie,† we may distinguish three forms of exostosis of the orbit: 1, the cellular; 2, the craggy, or semi-cartilagi-

* Hulke on Orbital Tumours, "R. L. O. H. Rep.," v, 3, 181.

† "Treatise on Diseases of the Eye," 4th edition, p. 41.

neous; 3, the ivory. The cellular exostosis is characterised by its being composed of an osseous crust, which surrounds a softish substance, traversed by numerous delicate bony partitions. Sometimes, it may contain hydatids. This form of exostosis springs from the periosteum, does not generally acquire a considerable size, and may remain quite stationary. The craggy, or semi-cartilagineous exostosis generally consists in the centre of osseous laminæ, which are surrounded by cartilage, over which the periosteum may be imperfectly traced, but it has no complete shell. It may grow from the cancelli or from the periosteum. The ivory exostosis is the form most frequently met with in the orbit; it is excessively hard, and consists of perfectly developed, dense, and very firm bone tissue. According to Mackenzie, it originates in the diploe, presses the compact tissue of the bone before it, and forms a round, smooth, or somewhat nodulated tumour. It, moreover, shows a disposition to extend into the cranium.

Exostosis frequently supervenes upon periostitis and ostitis, and may be due to a scrofulous or syphilitic diathesis, or be produced by injuries, such as falls or blows upon the orbit, or by fractures of the latter.

These osseous tumours are more or less hard to the touch, slow in their progress and growth, and generally accompanied by little or no pain or inflammatory symptoms. Sometimes, the pain may, however, be severe, more especially if symptoms of periostitis supervene in the course of the disease. The degree of exophthalmos and impairment of the movements of the eye will vary with the extent and situation of the exostosis. It is often quite impossible to determine the exact nature of the disease before operation, more especially when the tumour is situated deep in the orbit. Ivory exostosis is frequently developed from the frontal or ethmoid bone.

In the early stage, the treatment should be directed to promote the absorption of the tumour, by the administration of the iodide of potassium internally, the application of mercurial ointment over the brow, etc. The patient's general health must be attended to, and kept up by a generous diet and tonics, residence in the country or at the sea side, etc.

If the exostosis is small and remains stationary, it should not be interfered with by operation. But if it is increasing in size, and is producing exophthalmos, etc., the surgeon should endeavour to remove it.

The tumour should be freely exposed by one or more incisions, carried through the integuments and between the fibres of the orbicularis, or, if necessary, by dissecting back the lids. In order to gain plenty of room, it may also be necessary to divide the outer commissure of the lids. The tumour having been thus exposed, is to be stripped of

its periosteum and carefully excised with a scalpel, assisted by cutting pliers and strong bone forceps. Great care must be taken not to injure the upper and inner wall of the orbit by a rough and thoughtless use of the instruments. The ivory exostoses are frequently so firm and hard, and so intimately and widely connected with the bone, that it may be impossible to complete the operation, and the latter must be desisted from. Mr. Haynes Walton narrates a case in which he successfully removed a large ivory exostosis.* Two similar instances are recorded by Maisonneuve.

Sometimes, however, the tumour is so excessively hard, and its attachment so extensive, that it resists all the efforts made with the saw, cutting pliers, or mallet; little splinters of bone may be chipped off, but the great mass of the growth is impregnable, and the operation has to be abandoned. Such instances have been recorded by Mackenzie† and Knapp.‡ In Knapp's case, seven weeks after the operation, the first five having been passed very quietly and favourably, the patient was attacked with symptoms of meningitis, of which she died. On post mortem examination, a general thickening of the cranium was discovered, together with a large exostosis, about the size of a goose's egg, springing from the frontal bone. In a subsequent case of ivory exostosis, Knapp succeeded in removing the tumour.§

The true cartilagineous tumours (enchondroma), are only very rarely met with in the orbit. Many of the cases which have been recorded under this name, were in reality instances of osteo-steatoma or osteo-sarcoma. This mistake is the more easily made, as some of these tumours in the course of their development undergo cartilagineous changes before becoming ossified.

Although these cartilagineous tumours as a rule spring from the bone, they may also become developed from the softer tunics of the orbit. They are most frequently met with in youthful individuals. In a case of Von Graefe's‖ it occurred in a child only seven months old, it being stated that the tumour had existed since the first month after birth.

(5.) CYSTIC TUMOURS OF THE ORBIT.

Cysts may occur at various parts of the orbit, either deep in its cavity behind the eyeball, or near its upper or lower margin. Whilst some of these cysts contain hydatids, others are developed from the follicles of the lids. At first, their true nature may be readily recognizable, but when they attain a considerable size, the connection

* "Surgical Diseases of the Eye," 286.

† L. c., 48.

‡ "A. f. O.," viii, 1, 239.

§ "Kl. Monatsbl.," 1865, 376.

‖ "A. f. O.," i, 1, 415.

between the cyst and the follicle may become so attenuated, stretched, or even torn through, that their real mode of origin is often overlooked. The consistence and contents of these follicular cysts are subject to considerable variations. Thus in the atheromatous form, the contents are of a friable, cheesy, or curdy nature; whereas, in the steomatous they rather resemble suet.

Other cysts spring from the glandular structures of the conjunctiva, and may contain a yellow, serous, or rather viscid and albuminous fluid, like white of egg (the latter kind of cyst is termed hygroma). They may be about the size of a pea or bean, and situated near the surface of the conjunctiva. But they sometimes extend back into the orbit, attain a very considerable size, and then give rise to great exophthalmos. In rare instances, the cysts contain a brown hæmorrhagic fluid.

Some orbital cysts have been found to have hairs, etc., growing from their internal walls.

Two kinds of hydatids are met with in the orbit, the echinococcus, and the cysticercus. The former is much larger, and occurs in greater numbers than the cysticercus. Thus the echinococcus may acquire the size of a filbert, and be present in great quantities, causing an excessive protrusion of the eye. In a case of Lawrence's, quoted by Mackenzie,* half a teacup-full of echinococci, varying in size from a pea to a filbert, were emptied from an orbital cyst. Mr. Bowman† operated upon a somewhat similar case, in which three hydatids came away a few days after the operation. Two were as big as large marbles, the third about half the size. In a case of Waldhauer's,‡ some of the hydatids, of which there was a great quantity, had acquired the size of a hazel nut. The hydatid is enclosed in a capsule of thickened connective tissue, besides the proper cyst wall. The cysticerci are much smaller in size than the echinococci, and their cyst wall much slighter and thinner.

Cystic tumours of the orbit are generally slow in their progress, and may remain but small in size; if they however grow considerably, the eyeball will gradually be protruded. Their development is generally unaccompanied by any pain, but when they are very large, and have caused great exophthalmos, the sufferings of the patient are often most intense, the pain extending perhaps over the corresponding side of the head and face. The tumour is not, however, tender to the touch. If the cyst is situated near the front of the orbit, so that it can be seen and felt, it will present a round or ovoid appearance, of varying size, and is observed to be quite unconnected with the eyeball. If the cyst-wall is thin and soft, the tumour will be very elastic to the touch, and

* Mackenzie, 1087. † Ib., 1088.

‡ "Kl. Monatsbl.," 1865, p. 385.

distinctly fluctuating. If firm pressure is applied, it may perhaps be made to recede into the orbit, re-appearing, however, when the pressure is relaxed. If the cyst wall is thick, or the integuments over the tumour are swollen, the latter will on a superficial examination feel somewhat firm, the fluctuation being only discovered on deeper pressure.

If any doubt exists as to the nature of the tumour, an exploratory puncture or incision should be made, and then if the cyst is found to be only moderate in extent and not reaching very far back, and if its contents are dense, it should be excised, which is best done by dissecting it out with the aid of a silver knife, or the end of the handle of a scalpel, assisted by the finger. If the contents are fluid, and the cyst is large, it will be better to empty it (if necessary, repeated several times) by an incision, and then to permit it to close by adhesive inflammation. Sometimes strips of lint are inserted, thus setting up suppurative inflammation; but this is dangerous if the cyst extends deeply into the orbit, as the inflammation might extend to the lining membranes of the brain. Injections of iodine have been recommended, but they are also accompanied by considerable risk.

I may state that at the commencement of the disease it is often extremely difficult, or even impossible to diagnose with anything like certainty, whether the nature of the orbital tumour is benign or malignant. There are, however, certain points, which may assist us in our diagnosis. Thus, in malignant affections, the general health of the patient mostly suffers considerably even at an early stage; whereas, in the benign tumours this is not the case, the patient retaining good, and even blooming health, excepting indeed the tumour has attained a very considerable size, and produces great pain by pressing upon the eyeball, or stretching the nerves.

The progress of a malignant tumour is also, as a rule, much more rapid that when it is benign. The rapidity of its growth will, however, vary according to circumstances. Thus, as long as it is confined to the posterior portion of the orbit, the pressure of the eyeball offers a certain degree of check to its development, and somewhat restrains its rapid growth. The same is the case in intra-ocular malignant tumours, whose progress may be comparatively very slow as long as they are confined by the external coats of the eye; but when these have once given way, and the tumour sprouts forth, its increase in size is always most marked and rapid. The pain is also much more intense and continuous in malignant tumours, but this symptom is not very reliable, for even in benign tumours it may be very severe, if the eye is much protruded.

Von Graefe* lays great importance upon the degree to which the

* "A. f. O.," x, 1, 194.

muscles of the eye and their nerves are implicated, as a point of diagnosis between benign and malignant tumours of the orbit. Malignant growths, according to him, always cause a much greater and earlier impairment of the movements of the eye, so that the latter may be already almost immoveable, whilst the exophthalmos is yet but slight in degree. In estimating the amount of immobility, we must, of course, take into consideration the mechanical effect of the tumour, and the change of position of the eyeball.

The skin and neighbouring parts are more frequently affected in malignant tumours, so that the boundaries of the latter cannot be so exactly made out, and the skin is not so moveable over them. Malignant growths of the orbit are also of more common occurrence in children than in adults. Thus Leber has found that in one-third of the cases of cancer of the eye and orbit, the patients were under ten years of age.

Whether or not the tumour springs from the eye or is continuous with it, may be estimated by the nature of the movements of the eyeball. If the movements take place round the turning point of the protruded eye, it proves that the normal layer of connective tissue between the posterior hemisphere of the eyeball and the tumour still exists. Whereas, if the tumour and the globe are continuous, the movements will not be round the turning point of the eye (Graefe).

Cancerous tumours of the orbit may be developed from the walls of the latter, from the adipose cellular tissue, or may extend into the orbit from neighbouring cavities or from the eyeball.

The medullary and melanotic cancer are far more frequently met with in the orbit than scirrhus.

(6.) SCIRRHUS.

Scirrhus of the orbit is generally due to some injury, or to prior inflammation. It may show itself in the form of one large scirrhous mass implicating the whole of the orbit, or in the form of small, circumscribed, hard tumours, which closely resemble exostoses in their appearance. Its growth is generally slow, and not accompanied by much or severe pain.

The following case of scirrhus tumour of the orbit is of rare importance and interest, as illustrating the great benefit to be derived from extirpation, followed by the application of the hot iron and chloride of zinc paste.

A woman, aged 48, upon her admission into the Middlesex Hospital under Mr. Lawson, January 30th, 1866, had her left eye protruded a full inch beyond its fellow by a hard solid growth, which could be dis-

tinctly felt with the finger to be filling the orbit. The surface of the cornea was ulcerated, and the eye had only perception of light. The upper lid could not close over the globe. About four months before her admission a hard scirrhous tubercle was noticed in front of the ear, it was now about the size of a bean. Mr. Lawson excised the eyeball and the whole of the cancer down to the orbital walls, and then applied the actual cautery to arrest the bleeding. Strips of lint, covered with chloride of zinc paste, were then applied to the bottom of the orbit and around its walls. He next excised the tubercle on the face, and also applied to this, after all bleeding had ceased, the chloride of zinc paste. Large superficial sloughs were at first detached, and in about three months afterwards the whole bony orbit became completely detached, and Mr. Lawson pulled it away in one piece (Fig. 87).* The exact size and appearance of the orbit after its removal are here very correctly represented. It is now in the museum of the Middlesex Hospital. The patient had a good deal of pain in the head and sickness during the separation of the bone from the neighbouring tissues, but all these symptoms at once ceased after the orbit had come away.

Fig. 87.

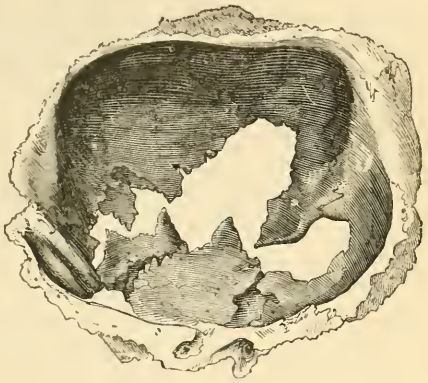

Fig. 88.

Up to this date, November 1868, nearly 3 years after the operation, she is still perfectly well, and has had no recurrence of the disease. Her present appearance is well illustrated in Fig. 88.†

* Transactions of the Pathological Society, 1867, p. 233.

† These woodcuts (which were kindly lent by Mr. Lawson to the author), are from photographs by Mr. Heisch.

(7.) MEDULLARY CANCER.

This is especially distinguished by its soft consistence, which greatly resembles that of rice, by the peculiar cauliflower excrescences, or the red fleshy, fungous appearance (fungus hæmatodes) which it presents when protruding from the orbit. The form of the tumour may be tolerably circumscribed, and it may not be very adherent to the periosteum; or it may be closely connected with the latter, also invading and destroying the muscles of the eye, the periosteum, and, finally, the bones of the orbit, and then extending into the neighbouring cavities. It may likewise extend along the optic nerve to the brain.

The tumour may grow with considerable rapidity, and attain an enormous size, and this is especially the case when it recurs, after the eyeball and the primary tumour have been extirpated.

The following case of Mr. De Morgan's graphically illustrates the appearances presented by such a tumour, as well as the mode of treatment which should be adopted, and which proved successful for a period of 14 months, when the patient died from a secondary tumour in the cranium, the disease having travelled back along the optic nerve.

The patient,* James Vinall, was 33 years of age, healthy, and also of a healthy family, when he received, in August, 1863, a blow on the left eye. In two months the sight became impaired, and there was deep-seated pain in the orbit, and in February, 1864, he was quite blind in this eye. Mr. Woolcott detected an intra-ocular, cancerous growth, and removed the eye on 20th April. The parts healed rapidly, and his health improved. In May he had again severe darting pain at the back of the orbit, and shortly afterwards a tumour protruded between the lids. The morbid growth increased with great rapidity, and his health and strength failed greatly. In August, the tumour began to bleed, and the hæmorrhage recurred daily. In October, a piece, about the size of a large walnut, dropped off from the centre of the mass. He became a patient in the Middlesex Hospital on November 3, 1864. Mr. De Morgan gives the following description of the tumour and the operation performed upon it:—

"A large, irregular tumour projected from the orbit, excavated in the centre, and sloughing (see Fig. 89). The margins of the lids could be traced over it, spread out and stretched to a remarkable degree. At the lower and outer part, the tumour involved the structure of the cheek. Its general surface was somewhat flattened and circular, and measured four inches across. It projected nearly four inches forward from the cheek on the outside, and about two inches and three-quarters from the nasal side. No alteration could be detected in the cranial

* "Pathological Society's Transactions," 1866, 265.

bones; nor were any diseased glands to be felt. The patient had never had any cerebral symptoms. He was in a wretched state of health

Fig. 89.

from continued bleeding and offensive discharge, and from severe and constant pain. As, at two hospitals, the surgeons who saw him declined to operate, he was fully impressed with the hopelessness of his case, but he was anxious to have anything done to free him for a time from the pain and discharge. With this view I consented to operate, anticipating only a short reprieve from death, but hoping that I might be able by destroying the disease as it sprouted again, to give him some relief and comfort. The success which attended Mr. Moore's operation on the case of rodent ulcer, brought before the British Medical Association, determined me to follow the same plan, and thus destroy the disease as effectually as I could. I removed the tumour on the 23rd of November, 1864, by first cutting the mass from the orbit with strong curved scissors, and then removing all the parts to which the growth extended external to the lids themselves. The actual cautery was then freely applied over the whole surface of the orbit and parts around, and finally the whole was covered with a layer of cotton-wool, thickly coated with the chloride of zinc paste.

"There was very little hæmorrhage, and he scarcely had pain after the operation. In a fortnight a large mass of the charred tissue was thrown off, with some parts of the orbital bones. Portions of the bones of the orbit exfoliated from time to time, until much of the framework

came away, exposing in one part the dura mater, and opening the nasal and maxillary cavities. Healthy granulations soon covered the whole surface. He rapidly gained health and strength. One or two little millet-seed looking excrescences remained at the inner part of the wall of the cavity, but they did not appear to grow; from time to time, however, they were touched with the chloride of zinc, or nitrate of silver."

In September, 1865, he again applied, suffering from severe rheumatic pains in the right hip; he had lost flesh, and the pulse was up to 100. The excrescences on the inside of the orbit having increased in size (one was as large as a small nut), were cut away by Mr. De Morgan, and the tissue around them destroyed by the chloride of zinc.

The microscopic examination of the tumour, made by Mr. Hulke, showed it to be medullary cancer. The optic nerve appeared healthy on section; but extending between the inner and outer sheath in the loose connective tissue, were small diffused patches of cancer elements, lying in the meshes of the healthy tissue.

Fig. 90.

Fig. 90 shows the patient's condition when he appeared before the Pathological Society, on Feb. 6th, 1868.* He was then apparently quite well.

Although the patient appeared to be quite well in February, 1866, he died on July 11th, having lived 1 year and 8 months after the operation. He had for some time suffered greatly from sciatica, which was soon followed by paraplegia. He had also vertical hemiopia of the remaining eye. On post mortem examination, a large tumour was found in the middle fossa of the skull, growing apparently from the orbital foramen and sphenoidal fissure, the optic nerve as far as the commissure being involved in, and undistinguishable from it. Cancerous deposits were also found in the glands around the aorta, and adhering to the nerve

* This and the preceding cut are from photographs by Mr. Heisch, and have been kindly lent to the author by the Council of the Pathological Society.

trunks of the cauda equina. The orbit was empty, and free from any cancerous growth.

The return of the disease, and its fatal termination, were consequently only due to the fact that the optic nerve was involved in the cancerous affection. Mr. De Morgan therefore thinks that these facts justify the belief, that had the operation been done in the same manner at an earlier period, the patient might have remained well.

(8.) MELANOTIC CANCER.

Melanotic tumours of the orbit are, like those within the eye, often either of a sarcomatous or a mixed character, one portion of the morbid growth being of a sarcomatous nature, another carcinomatous. The character and progress of melanotic cancer have already been given in the articles upon tumours of the choroid (p. 448), and need not be entered upon here, as the disease does not differ essentially in its course and nature (excepting its colour) from other cancerous affections of the orbit.

(9.) EPITHELIAL CANCER.

Epithelial cancer of the orbit is also occasionally met with, originating in the skin of the temple, cheek, or nose, and extending from thence into the orbit. Mr. Hulke* narrates a most interesting case of epithelial cancer of the orbit caused by a severe blow upon the cheek, in which the symptoms presented by the disease closely resembled those of carbuncular cellulitis.

7.—VASCULAR TUMOURS OF THE ORBIT.

(1.) Cavernous Tumour.

Only four instances of this very rare form of orbital tumour have been recorded, by Lebert,† de Ricci,‡ Von Graefe,§ and Wecker.‖

These tumours do not present any specially characteristic features in their external appearance, excepting that they are prone to undergo marked spontaneous changes in size, which are dependent upon mechanical hyperæmia of the morbid growth. Thus, any straining

* "R. L. O. H. Rep.," v, 336.

† Abhandlungen aus dem Gebiete der praktischen Chirurgie. Berlin, 1848, p. 88.

‡ "Dublin Quarterly Journal," 1865, November, p. 338.

§ "A. f. O.," vii, 2, p. 12.

‖ Wecker, "Maladies des Yeux," 2nd edit., i, 793.

or violent exertion, or stooping position of the head, may be followed by a striking increase in the size of the tumour. In Von Graefe's case, the mere pressure of the pillow in bed upon this side of the head and face gave rise to a temporary protrusion of the eye, accompanied by great congestion of the conjunctival and subconjunctival vessels.

The growth of these tumours is generally slow, more especially if they are situated deeply in the orbit, for then the pressure of the eyeball restrains their rapid development.

The cavernous tumour* is surrounded by a capsule of dense cellular tissue, which is only very loosely connected to the adipose tissue of the orbit, so that the tumour can be very readily and completely removed, with but a very slight amount of hæmorrhage. On a section, it is seen to be of a spongy nature, and to be traversed by delicate meshes of fibrillar connective tissue, dividing it into a vast number of little compartments. These interspaces contain blood, which can be readily squeezed out by a little pressure, and this causes a considerable diminution in the bulk of the tumour, which at the same time becomes of a pale greyish tint.

The erectile tumours (telangiectasis) which are met with in the orbit, almost invariably take their origin from the eyelids, and then, increasing in size, extend thence into the orbit. They are described in the article on Tumours of the Eyelids.

(2.) Aneurisms of the Orbit.

Aneurism by anastomosis is of far less frequent occurrence in the orbit than was at one time supposed, and many of the cases which have been described under this name, were evidently instances of diffuse aneurism. Aneurism by anastomosis is met with principally in young children, and is mostly congenital. The tumour commences in or near the skin, is connected with the subcutaneous tissue, and presents the appearance of an irregular nodulated growth, consisting of convolutions of dilated arteries; the vessels in the neighbourhood participating in the increased action. The origin of the tumour is neither sudden nor produced by direct violence, but is slow, and its increase in size is tardy and gradual. The size of the swelling is much increased by any position or exertion which causes congestion of the head, *e.g.*, stooping, straining, coughing, etc. Although the tumour presents distinct signs of pulsation and thrilling, no effect (or only a very tardy one) is produced upon these symptoms, or upon the swelling, by compression of the carotid artery. Moreover, as was strongly insisted upon by Mr. John Bell, aneurism by anastomosis is not curable by ligature of vessels. The best treatment is that of subcutaneous ligature of the

* Virchow, "Krankhafte Geschwülste," iii, 1, 358.

tumour, the ligature being either applied in a circular manner, so as to include the base of the tumour within a single loop, or else the figure of 8 ligature should be employed. If the growth is of considerable size, and is divided into different nodulated portions, these may be operated upon successively by the ligature; or threads saturated with a solution of the perchloride of iron may be drawn through the tumour, so that they cross and re-cross each other in various directions. These modes of operating are far more safe than, and much to be preferred to, the injection of the perchloride of iron, or other agents for the purpose of producing coagulation. Dr. Althaus's treatment by electrolysis might also be tried.

True aneurisms of the orbit are of rare occurrence, and do not attain any considerable bulk, on account of the small size of both the ophthalmic artery and the central artery of the retina. In a case recorded by Mr. Guthrie,* an aneurism of the ophthalmic artery of each side, about the size of a large nut, was discovered after death. The ophthalmic vein was greatly enlarged, and obstructed near its passage through the sphenoidal fissure by the great increase in size of the recti muscles, which had also acquired an almost cartilagineous hardness. Although the eyes were greatly protruded, the sight was hardly affected, and the exophthalmos was evidently as much due to the state of the muscles as to the dilatation of the vessels. There was an audible hissing noise in the head, which was attributed to aneurism. As the disease existed on both sides, Mr. Guthrie did not propose ligature of the carotid.

Cases of aneurism of the central artery of the retina have been observed by Graefe (senior), Schmidler, and A. Cooper. In Graefe's case the central artery of the retina was dilated to the size of a stalk of grass. But Sous† was in one case able to diagnose the affection with the ophthalmoscope. He observed in a woman of 64, a red ovoid tumour on the left optic disc, extending somewhat beyond its margin, and, after becoming suddenly narrower, passing over into one of the retinal arteries. It presented evident signs of pulsation, the dilatation being synchronous with the systole of the heart. The other retinal arteries were very narrow and threadlike, the veins somewhat dilated.

Diffuse or false aneurism of the orbit is of far more frequent occurrence. It may be either primary and traumatic, or consecutive in its origin. In the former case, the walls of the artery are torn or ruptured by a sudden blow or wound of the head or orbit, or a fall upon the head,

* "Lectures on Operative Surgery," p. 158.

† "Annales d'Oculistique," 1865.

and the effect is immediate, blood is effused into the orbital cellular tissue, and a certain degree of exophthalmos may be produced. As the exophthalmos increases, the eyelids become swollen, red, and œdematous, the conjunctival and subconjunctival vessels congested, the movements of the eyeball diminished, and the sight perhaps more or less impaired. The blood-vessels around the eye are also sometimes dilated and tortuous. A bluish, elastic, soft tumour now makes its appearance at some point of the edge of the orbit, and shows distinct pulsations, which are evident both to the eye and touch, are synchronous with the systole of the heart, and accompanied by an audible thrill. If the ear is applied, a peculiar humming or whirring sound is heard, like the action of a steam-engine, threshing-machine, or humming-top, and this proves a source of the greatest distress and anxiety to the patient. This may extend over a considerable portion of the head. In a case narrated by Dr. Joseph Bell,* this whirring sound was audible to a bystander at the distance of a yard. There is often also intense pain in and around the orbit and over the corresponding side of the head. Compression of the carotid artery at once stops the pulsation, and pressure upon the tumour generally causes it distinctly to diminish in size. In some cases, the appearances of an aneurismal tumour do not come on till some length of time after the accident, and its increase is slow and gradual; in other instances, the symptoms supervene immediately, or very rapidly upon the injury.

The consecutive diffuse aneurism of the orbit is frequently preceded by a true aneurism, accompanied by a fatty or atheromatous degeneration of the walls of the vessel, which thus become weakened. But the disease of the walls of the blood-vessel may also be alone present. Any sudden strain or exertion on the part of the patient causes the vessel to give way, and this is accompanied by a very marked and sudden pain through the head and eye, as if a pistol had been shot off, or something had given way within the head. The blood flows through the rent in the artery, and, becoming infiltrated in the surrounding cellular tissue, a cavity, communicating directly with the vessel, is formed. Symptoms of exophthalmos, together with pulsation and a bruit in the tumour, and other symptoms of aneurism, supervene, the patient at the same time experiencing intense pain. Sometimes, the disease may appear spontaneously without the slightest apparent cause, and without any accident or violent exertion. It has been frequently met with in women during the time of pregnancy or childbirth. Compression of the carotid causes a considerable diminution or arrest of the pulsation and bruit, but is sometimes accompanied by severe pain and distressing symptoms of fulness in the head (Gioppi). Or these may be produced to a very

* "Edinburgh Medical Journal," 1861, p. 1064.

marked degree by sudden relaxation of the pressure, whereas a gradual removal produces no pain.*

But all the symptoms of orbital aneurism may exist without the presence of any such affection within the orbit; the pulsating orbital tumour being simply due to some compression of the ophthalmic vein, which prevents the efflux of the blood from the orbit. The cause of this compression is frequently the presence of an aneurism of the ophthalmic artery near its origin, or of the internal carotid artery. Thus Mr. Nunneley, in his valuable and interesting paper on "Vascular Protrusion of the Eyeball,"† narrates, amongst other cases, that of a patient in whom he successfully tied the carotid, in 1859, for a pulsating tumour of the orbit. In 1864 she died, and on post mortem examination the presence of a circumscribed aneurism of the ophthalmic artery was discovered, just at its origin, of the size of a hazel nut. The trunk and branches of the ophthalmic artery, continued forwards into the orbit, being of small size. The following case of Mr. Bowman's‡ is also of much interest, as showing how all the symptoms of orbital aneurism may be simulated without the existence of any such affection. The patient, a woman, aged 40, noticed severe pain in the left temple very shortly after a blow of the fist on the left side of the head and temple. A fortnight afterwards, she felt a constant rushing sensation on the same side of the head, like the beat of a steam-engine, which increased with acceleration of the heart's action. On her admission into King's College Hospital, under Mr. Bowman, the eye was prominent and congested, the pupil dilated but active, distant sight was perfect, but she was unable to read. There was a loud sibilant bruit over the left side of the head, being synchronous with the beating of the heart; also distinct pulsation of the left eye, apparent to the touch, and a loud bruit could be heard when the stethoscope was placed on the closed eyelids. Mr. Bowman tied the common carotid, and the pulsation and bruit, hitherto felt and heard over the front of the eye, at once ceased. But the patient died 18 days after the operation from phagedænic ulceration and hæmorrhage from the wound. On post mortem examination, no appearance of an aneurism could be discovered, and it is difficult, as Mr. Hulke says in reporting the case "to explain the aneurismal symptoms by the pathological appearances which were those of phlebitis of the cavernous, transverse, circular, and petrosal sinuses. The internal carotid may have been partially compressed by the swollen walls of the cavernous sinus against the side of the body of the sphenoid bone, giving rise to the bruit, which would have a good conducting medium in the cranial bones. The plugging of the trunk of the ophthalmic vein, where it

* Dr. Joseph Bell, l. c., p. 1065.

† "Med.-Chir. Trans.," vol. 48, 1865, p. 29.

‡ "R. L. O. H. Rep.," ii, p. 6.

joins the cavernous sinus, by obstructing the return of blood from the orbit, accounts for the protrusion of the eyeball, and perhaps also for the pulsation which was felt when the finger was laid on it, because each diastole of the ophthalmic artery must have been attended by a general momentary increase of the whole quantity of blood in the orbit, because its exit through the ophthalmic vein was cut off, and the resisting bony walls of the orbit could permit a distension in front only."

The operation of ligature of the common carotid has proved very successful in cases of aneurism or supposed aneurism of the orbit. Thus, Dr. Morton, of Pennsylvania, has collected thirty cases in which the common carotid was tied, of these twenty-two were cured, three partially successful, two unsuccessful, and three fatal. Since then Mr. Zachariah Laurence* has successfully performed the operation, and another successful case is reported by Dr. Bell.†

Digital compression of the carotid has proved successful in three cases, viz., in those of Gioppi,‡ Vanzetti,§ and Freeman.‖ In a case of Sczokalskis's¶ digital compression was continued for fifty-six hours, together with ice-cold compresses and small doses of digitalis, but proved quite unavailing. Ligature of the common carotid was then performed with perfect success. Digital compression may be applied in such a manner as to press the common carotid directly back against the vertebral column; but in this mode the jugular vein is very apt to be also compressed, which produces great congestion of the head. It is, therefore, better to raise the carotid somewhat, and compress it between the fingers. Relays of assistants should be ready to alternate in this duty. Sometimes, however, it cannot be borne for longer than four or five minutes at a time. The success of these cases should encourage us to give this method of treatment by digital compression a fair trial, before having recourse to ligature of the carotid, for this operation can always be performed if compression fails.

Two cases have been successfully treated by styptics; and Mr. Holmes mentions a case of traumatic aneurism cured by the administration of the extract of ergot, and tincture of green hellebore, together with complete rest and low diet.** Two cases in which electrolysis and

* "Ophthalmic Review," 12.

† "Edinburgh Medical Journal," 1867, July.

‡ "Annales d'Oculistique," November and December, 1858.

§ "Annali Univers.," 1858, p. 148; vide also "Lancet," March 15, 1862.

‖ "American Journal of Med. Science," July, 1866.

¶ "Kl. Monatsbl.," ii, 427. For further information, and a tabulated arrangement of cases of aneurism that have been operated upon, I would refer the reader to Dr. Morton's able paper in "Amer. Jour. of Med. Science," April, 1865, and Zehender's article in "Kl. Monatsbl.," 1868, 99.

** "Amer. Jour. of Med. Science," July, 1864.

injection of the perchloride of iron were tried, are narrated in Zander and Geissler.* The latter remedy is, however, excessively dangerous, for instantaneous death has been caused by it more than once.

8.—EFFUSION OF BLOOD INTO THE ORBIT.

The effusion of blood into the orbit is generally rapid, and can mostly be traced to some direct cause, such as a blow or fall upon the eye or head, incised or punctured wounds of the orbit, or the lodgement of a foreign body within the latter. In rarer instances, the hæmorrhage may be due to violent exertion or straining, or may even be spontaneous in its origin. The eye generally becomes rapidly protruded, and its mobility curtailed. Frequently the protrusion, as well as the impairment of the mobility of the eyeball, occur chiefly in certain directions. The sight is more or less affected, and this is chiefly due to direct pressure upon the optic nerve by the effusion, but in cases of injuries to the head, it must be remembered that the affection of the sight may be dependent upon some cerebral lesion. Thus, consecutive neuro-retinitis may become developed, being due to the inflammation of the meninges.† On account of the impairment of the mobility of the eye there is also diplopia. The eyelids are often much swollen, contused, discoloured, and perhaps studded with ecchymoses, which may also occur in the conjunctiva and subconjunctival tissue. Moreover, although the blood may be at first confined to the posterior portion of the orbit, it may press forward and become diffused beneath the conjunctiva, and thus produce considerable chemosis. In cases of orbital hæmorrhage dependent upon fracture of the bones of the orbit, it has been supposed that the presence of ecchymoses in the eyelids is a guide to the diagnosis of the seat of the fracture. Velpeau especially insisted upon the importance of this symptom. When ecchymosis of the lids exists alone or precedes subconjunctival effusion, it was supposed to be indicative of a fracture of the margin of the orbit. Whereas, subconjunctival effusion existing with other symptoms of fracture of the orbit, in which there was no ecchymosis of the eyelids, or this only came on subsequently, was supposed to be pathognomonic of the injury being situated deeper in, or at the bottom of, the orbit. But absolute reliance cannot be placed upon these symptoms, for the bones of the orbit may be fractured, and yet there may be not the slightest effusion of blood either under the conjunctiva, or into the eyelids. If there is a fracture of the inner or lower wall of the orbit, emphysema of the latter may also be produced, and then the protrusion of the eye will be increased when the nose is blown.

* Verletzungen des Auges, 433.

† Vide Manz, "A. f. O.," xii, 1, 1.

The treatment must be chiefly directed to hastening the absorption of the blood. Cold compresses and a firm bandage will be found most serviceable. Only in those cases in which the effusion of the blood is very great, and causes extreme exophthalmos with very severe suffering to the patient, is it advisable to make incisions, in order to permit the escape of the blood. In the majority of cases, it is wiser to permit it to be absorbed.

9.—EMPHYSEMA OF THE ORBIT.

Emphysema of the orbit is generally accompanied by a similar condition of the eyelids. The affection may be produced by a rupture of the ethmoidal cells, by fracture of the frontal sinus, in which case the swelling may extend to the forehead and temple, or, as is most frequently the case, by a rupture of the lachrymal sac. The air is admitted into the cellular tissue of the orbit and eyelids, causing great protrusion of the eye and swelling of the lids, both subsiding considerably when gentle pressure is applied to the eyeball and lids. If the affection is due to a rupture of the lachrymal sac, the swelling may be immediately produced by the patient's forcibly blowing his nose. The emphysematous swelling is very elastic to the touch, and there are marked symptoms of crepitation.

10.—PRESSURE UPON THE ORBIT FROM NEIGHBOURING CAVITIES.

Dilatation of the cavities in the vicinity of the orbit will cause a contraction and malformation of the latter, accompanied by more or less considerable exophthalmos, curtailment of the mobility of the eyeball, and impairment of vision.

*Diseases of the frontal sinus** may produce considerable dilatation of this cavity, which then encroaches upon the orbit, giving rise to a contraction and malformation of the latter, and consequent protrusion of the eyeball. Amongst such affections of the frontal sinus, must be enumerated acute and chronic inflammation of its lining membrane, giving rise to the formation of a purulent or muco-purulent discharge; in rarer instances polypi, cystic tumours, and entozoa are met with; also, perhaps, exostosis. The latter is, however, according to Mackenzie, so extremely rare, that he is not aware of a single recorded case of exostosis of the frontal sinus, although he happens to have two specimens in his own collection.† Of these diseases of the frontal sinus,

* Vide Mr. Hulke's articles on Diseases of the Frontal Sinus, "R. L. O. H. Rep.," iii, 147.

† Mackenzie's, "Diseases of the Eye," 4th edit., i, p. 59.

acute and chronic inflammation, terminating in abscess, are the most common.

The symptoms presented by abscess of the frontal sinus are often somewhat obscure, and may mislead even an experienced surgeon, for they may very closely simulate those presented by an intra-orbital tumour.

The disease generally presents the following symptoms:—The patient experiences a feeling of fulness and uneasiness over the eyebrow, accompanied by a dull aching pain, which is sometimes increased by pressure upon this spot, or by any exertion or posture which causes an acceleration of the circulation. In the acute abscess, the muco-purulent discharge generally perforates the roof of the orbit, or makes its way into the nose at an early stage, before there has been time for the sinus to become much dilated. If the discharge has made its way into the orbit, the eyelids become red and swollen, the upper lid perhaps drooping a little, and a small elastic tumour appears at the inner and upper angle of the orbit. As the abscess increases in size, the eyeball is displaced in a downward and outward direction, becomes more and more protruded, and its mobility impaired, in consequence of which, diplopia manifests itself when the patient looks upwards. If the abscess is not opened, it will point and burst through the skin of the upper eyelid, generally near its inner angle, or perhaps lower down, just above the tendon of the orbicularis, when the fistulous opening which remains may be mistaken for inflammation of the lachrymal sac. But if a probe be passed into the opening, the sinus will be found to extend in an upward and backward direction, perhaps to a very considerable distance. Sometimes, there are several fistulous openings. In a chronic abscess, the frontal sinus often becomes very considerably distended by the collection of mucus, and this produces great exophthalmos and gives rise to a marked prominence over the eyebrow. The progress of the chronic abscess is often extremely slow and protracted, and accompanied by but little pain and discomfort until symptoms of exophthalmos and diplopia supervene. Inflammation and abscess of the frontal sinus are, in the majority of cases, caused by blows or falls upon this part of the face.

As the symptoms are generally at the outset very obscure, the treatment can then be only directed to the alleviation of the pain or inflammation, by the application of warm poppy fomentations. But when the presence of matter is ascertained, a free incision should be made into the swelling just beneath the supra-orbital arch, and the pus be thoroughly evacuated, the finger or a small piece of sponge being introduced into the cavity of the frontal sinus for this purpose. The point of the forefinger should then be inserted into the dilated sinus in order to ascertain its relation with the neighbouring cavities, and also

the condition of its lining membrane. The point of the little finger should next be introduced up the corresponding nostril as high as the floor of the dilated sinus, and a bistoury should be passed through the opening in the frontal sinus, and the lower wall of the latter, just over the tip of the finger introduced by the nostril, should be incised, so that a free communication may be established between the sinus and the nasal cavity. A stout seton, composed of several thick silk threads, is then to be passed through the aperture in the skin into the sinus and thence through the nostril, the free end, projecting through the latter, being tied to that which projects from the incision in the skin, so that a large and easily moveable loop is formed, which should be freely moved by the patient two or three times a day, so as to keep the opening between the nasal cavity and sinus permanently patent. The patient is to be kept in bed for some days and closely watched. The seton should be worn for several weeks, or even longer, but should be removed if it gives rise to much irritation or to cerebral symptoms. When the communication with the nose has been permanently established, the seton should be removed, and the opening in the skin will then granulate and heal. I have seen several cases very successfully treated in this way by Mr. Bowman.

Enlargement of the maxillary sinus, the nasal cavity, and the cavity of the cranium may also cause pressure upon, and a contraction of, the cavity of the orbit, accompanied by protrusion of the eye and limitation of its movements. For interesting cases illustrative of these different conditions, I must refer the reader to Mackenzie's "Treatise on Diseases of the Eye."

11.—WOUNDS AND INJURIES OF THE ORBIT.

Incised and punctured wounds of the orbit should always be watched with care, for serious symptoms do not always arise directly after the injury, and may not manifest themselves till some time afterwards. The instrument which has inflicted the injury should be examined, in order that we may ascertain whether a portion of it has not been broken off, and perhaps remains lodged within the orbit. Even if the eyeball itself and the bones of the orbit have escaped direct injury, inflammation of the cellular tissue of the orbit and a more or less extensive formation of pus are very likely to occur.

Foreign bodies, more especially if they are small in size, such as shot, splinters of glass, steel, etc., may remain for a long time undetected within the orbit. The lodgement of a foreign body in the orbit may

prove dangerous by direct injury to the eyeball itself, the optic nerve, or the orbital walls, which may be fractured. Or it may produce inflammation of the cellular tissue of the orbit, or of the periosteum, etc.

Sometimes, very large foreign bodies have been lodged in the orbit without the patient being aware of their presence. Very extraordinary cases of this kind have been recorded, amongst others, by Nelaton,* and Mr. R. B. Carter, of Stroud.† In the latter instance, a portion of hat-peg $3\frac{3}{10}$ inches in length, had remained impacted in the orbit for from ten to twenty days without the patient's being aware of it. It was so successfully removed by Mr. Clarke, that the patient recovered without a single unfavourable symptom, the vision and movements of the eye being unimpaired.

Fractures of the walls of the orbit are extremely dangerous, more especially when the roof or upper portion of the inner wall is fractured, for the foreign body (frequently the stem of a pointed instrument, as the ferrule of an umbrella, etc.) may penetrate the cranium, or the splinters of the fractured bone may set up great irritation and inflammation of the brain and the meninges. The severe character of the injury and the presence of cerebral symptoms, may not show themselves for a day or two after the accident.

If the fracture extends from the orbit into the ethmoidal or frontal cells, there is generally emphysema of the orbit and eyelids.

The treatment of injuries of the orbit must vary with their nature. In cases of incised and punctured wounds, we must endeavour to subdue the inflammatory reaction by cold compresses, leeches, etc., and an early evacuation of the pus. Foreign bodies should be removed as soon as possible, except if they are of so small a size that they would be found with difficulty, and their removal might cause more disturbance than their presence.

Before an operation is attempted for the removal of a foreign body, the size, nature, and position of the latter should be ascertained as accurately as possible by a careful examination. If the foreign body be considerable in size, and situated deeply in the orbit, so that it must be cut down upon, the outer canthus may have to be divided in order that the upper or lower lid (as the case may be) can be turned up or down. The conjunctiva between the eyeball and the lid should be divided over the point where it is supposed that the foreign body is situated, and a probe or the tip of the little finger be introduced to ascertain its exact position, when it may be grasped and extracted with a pair of forceps. The incision should never be made through the skin of the eyelid, for the contraction consequent upon the cicatrization of the wound may give rise to a subsequent ectropium. The lips of the

* Zander and Geissler, lo. cit., 225. † "Ophth. Rev.," No. 4, p. 337.

incision at the outer canthus are then to be united by two or three fine sutures, or the twisted wire suture.

In fractures of the orbit the most absolute rest must be enforced, the patient should be placed upon low diet, and the use of stimulants should be forbidden. Cold compresses, and, if necessary, leeches, should be applied.

The eyeball may be dislocated and pushed out of the orbit, by a foreign body, *e.g.*, a piece of iron, the ferrule of an umbrella or stick, etc., being thrust into the socket. In such cases, the eye lies upon the cheek, protruding far beyond the lids, which cannot be closed over it. The optic nerve is, of course greatly stretched, and vision more or less completely lost, but on the removal of the foreign body, and replacement of the eye, the sight may be perfectly restored. The foreign body should be immediately extracted, and the eye replaced. The latter is to be done by gently, yet firmly and steadily, pressing the eyeball back, which will cause it suddenly to spring back into the orbit, the sight being then generally at once restored. The eye should be retained in its position by a firm compress bandage.

12.—EXCISION OF THE EYEBALL.

The modern method of removing the eye was first devised by Bonnet and O'Ferral in 1841, independently of each other. Stoeber practised it in 1842, and Critchett first introduced it in London in 1851.

The principal advantages of this operation over the old one are, that the eye is removed from the ocular capsule without any injury to, or interference with, the cellular tissue of the orbit, or a division of the outer commissure of the eyelids; that the muscles are divided quite close to their insertion into the sclerotic, that nearly the whole of the conjunctiva is preserved, and that only a few blood-vessels are divided. Thus there is but a moderate amount of hæmorrhage, and an excellent degree of mobility is preserved for the insertion of an artificial eye.

The operation is best performed in the following manner:—The patient should lie on a couch, and a large sponge should be placed beneath the temple and cheek of the side corresponding to the eye about to be removed, so that the blood may not flow down his neck or over his clothes. An assistant should be ready with several smaller sponges, to wipe away the blood from the eye during the different steps of the operation. The patient having been brought thoroughly under the influence of chloroform, and the eyelids held apart by the stop speculum, the operator places himself behind the patient, and, fixing the eyeball steadily with a pair of forceps, divides the conjunctiva all

round the cornea and quite close to the latter, with a pair of strong blunt-pointed scissors curved on the flat. He next incises the subconjunctival tissue at one point, and, passing a strabismus hook through this aperture, catches up one of the recti muscles, and divides it quite close to its insertion. The four recti muscles are to be thus divided in succession. When this has been done, the operator presses back the upper and lower eyelid, so as to make the eyeball spring forth through the small opening in the conjunctiva and protrude between the eyelids. The cut end of the tendon of the external or internal rectus muscle being seized with the forceps, and the eyeball rolled to the corresponding side, the scissors (closed) are to be passed along the posterior surface of the globe until the optic nerve is reached, when the blades are to be opened and the nerve divided quite close to the sclerotic. The eyeball should now be lifted forward by the fingers, and any portions of conjunctiva or subconjunctival tissue which may adhere to the globe, as well as the insertion of the oblique muscles, are to be divided close to the sclerotic. This finishes the operation, and the eye will have been removed quite free from conjunctival or muscular tissue, and present a perfectly smooth and polished appearance.

As the operator stands behind the patient, it will be found most easy to divide the optic nerve of the right eye from the temporal side, the eye being at the same time rotated inwards; the left optic nerve, on the contrary, is best divided from the nasal side. By so doing, the right hand can be used for either eye, and the operator is not obliged to alter his position.

The hæmorrhage which ensues upon the division of the optic nerve and ophthalmic artery, is generally soon stopped by making a stream of cold water from a sponge (or for want of this, from the narrow spout of a small jug) play upon the bottom of the orbit, and it will not be necessary to ligature any vessel. When the hæmorrhage has stopped, the lips of the conjunctival aperture, through which the eye has been removed, may be brought together by a fine suture, passed through the four little lappets left in the interval of the recti muscles. The suture, which is best inserted with the long needle with a handle devised for this purpose by Mr. Hulke, may then be firmly tied, so that the lips of the incision may be accurately brought together. It is still better, however, to wait with the tying of the suture for an hour or two, until all hæmorrhage has ceased. Although the insertion of the suture brings the edges of the conjunctival wound very nicely together, it should not be employed in those cases in which the excised eye is acutely inflamed, as it prevents the exit of inflammatory exudations. After the completion of the operation, the stop speculum should be exchanged for a thin wire one, and a fold of wet lint, covered by a small sponge, should be inserted into the orbit, and tied down firmly with

a bandage, so as to stop all hæmorrhage. At the end of an hour or two, this may be removed, and moist lint applied over the closed eyelids. The retraction of the lids by the speculum for an hour or two after the operation prevents their becoming œdematous and discoloured.

The after treatment of cases of excision of the eye is generally very simple. A cold compress should be applied during the first few days, and the orbit syringed out with a little luke-warm water, to cleanse away the discharge. If the latter should continue for longer than a week or ten days, and the conjunctiva looks red and swollen, a mild astringent injection of sulphate of zinc or alum should be used two or three times daily. If symptoms of inflammation of the cellular tissue of the orbit should supervene, warm bread-and-water poultices, or warm poppy fomentations should be applied, and the exit of pus be facilitated by a free incision into the conjunctiva; this should never be neglected if the lips of the wound have been closed by a suture. Should small granulations make their appearance on the conjunctival cicatrix, these should be at once snipped off with a pair of scissors.

When the eye is excised on account of the presence of an intra-ocular tumour, the optic nerve, instead of being divided close to the globe, must be cut as far back as we can reach, in order that all the diseased portion may, if possible, be removed. Or Von Graefe's preliminary division of the optic nerve may be performed, a description of which will be found in the article on intra-ocular tumours (p. 374). The extirpation of the eye together with the soft parts of the orbit, as in orbital tumours, is a more severe and protracted operation than the simple excision. The outer commissure of the lids must generally be divided, in order to give more room for the extirpation of the eye and the morbid contents of the orbit.

13.—THE APPLICATION OF ARTIFICIAL EYES (PROTHESIS OCULI).

The use of an artificial eye should not be allowed until five or six weeks after the excision, until the cicatrix has become firmly united, and the parts are quiet and free from all irritation. If the eye has been removed on account of sympathetic irritation of the other, special care must be taken that no artificial eye is worn until all the sympathetic symptoms have permanently disappeared for some months, and the eye must be carefully watched for some time afterwards, lest the artificial eye might re-awaken them. Indeed, the wearing of an artificial eye for too long a time, so that it sets up great irritation, may even give rise to sympathetic disease.*

* Vide an interesting case of this kind recorded by Mr. Lawson, "R. L. O. H. Rep.," vi, 2, 123.

At first, a small eye should be worn for a short time each day, and then, when the parts have become accustomed to it and there is a complete absence of all symptoms of irritation, a larger one may be adopted and worn for a longer period, and at last the whole day, but it should *always be removed at night.* After the lapse of some months, the internal surface of the eye becomes rough, and as this is a ready source of irritation and discomfort a new one is required.

As the insertion and removal of the artificial eye requires some little knack and practice, I subjoin the following concise and plain rules, which are given to the patients at the Royal London Ophthalmic Hospital.

Instructions for Persons wearing an Artificial Eye.—It should be taken out every night, and replaced in the morning.

To put the Eye in.—Place the left hand flat upon the forehead, with the fingers downwards, and with the two middle fingers raise the upper eyelid towards the eyebrow; then with the right hand, push the upper edge of the artificial eye beneath the upper eyelid, which may be allowed to drop upon the eye. The eye must now be supported with the middle fingers of the left hand, whilst the lower eyelid is raised over its lower edge with the right hand.

To take the Eye out.—The lower eyelid must be drawn downwards with the middle finger of the left hand, and then with the right hand the end of a small bodkin must be put beneath the lower edge of the artificial eye, which must be raised gently forward over the lower eyelid, when it will readily drop out; at this time care must be taken that the eye does not fall on the ground or other hard place, as it is very brittle, and might easily be broken by a fall.*

After it has been worn daily for six months, the polished surface of the artificial eye becomes rough; when this happens, it should be replaced by a new one; for, unless this is done, uneasiness and inflammation may result.

* In order to avoid this accident, the patient should stoop over a cushion or handkerchief placed on a table, or over a bed.

Chapter XVII.

DISEASES OF THE EYELIDS.

1.—ŒDEMA OF THE EYELIDS, ETC.

Œdema *of the lids* very frequently accompanies (as we have seen) the severer forms of inflammation of the conjunctiva, cornea, and iris. It may, however, be also dependent upon some disturbance of the general health, more especially in feeble and delicate persons. It is often due to an affection of the heart or kidneys, and should, therefore, always arouse our suspicions, and lead us to examine as to the presence of general dropsy, and of albumen in the urine. The degree of œdematous swelling of the lids is subject to much variation. If it be due to constitutional causes, it is often but inconsiderable in degree, giving rise only to a little puffiness and fulness of the lid, which is generally greatest in the morning, and diminishes during the day. Sometimes, the puffiness is principally confined to the lower lid, forming a little pouch or sack, which is very unsightly if it be considerable in size and if the subcutaneous veins are dilated, as the swelling then assumes a dusky, bluish tint. The swelling produced by œdema is smooth, pale, soft, and semi-transparent, and it is easily pitted with the point of the finger, the mark remaining for a little time.

If the œdema is due to constitutional causes, the treatment must be chiefly directed to their alleviation, when the swelling of the lid will soon subside. Where the puffiness of the lids occurs spontaneously in persons of a feeble, delicate habit, tonics should be administered, and the general health attended to. A compress bandage should be applied, and I have also found benefit from the use of warm aromatic bags (containing camomile flowers, camphor, etc.) tied firmly over the eye. If the œdema is very obstinate and unsightly, a small horizontal fold of skin may be excised. Where this condition is dependent upon some other disease of the eye, this must be treated, and when it is alleviated, the puffiness will soon disappear.

Emphysema of the lids is due to the admission of air into the arcolar tissue, and is generally caused by a fracture of the nasal bones, or of

the frontal or ethmoidal cells, and rupture of the mucous membrane; though generally produced by severe blows or falls, it may arise after blowing the nose very forcibly. The swelling of the lid is tense and elastic, and there is distinct crepitation on pressure; the colour of the skin is, however, unchanged. The treatment consists in the application of a compress bandage, with the use of a mildly stimulating lotion.

In *erythema (hyperæmia) of the eyelids* the skin is very much reddened, and presents a bright scarlet flush, which temporarily disappears upon pressure. There is, however, but very little, if any, swelling of the lid, and no pain, although the patient complains of a great sensation of heat. The redness generally extends somewhat on to the cheek, and the palpebral and ocular conjunctiva may likewise be injected. The veins of the skin are also sometimes dilated. This affection is not unfrequently due to prolonged exposure to very bright sunlight or intense heat, and is also met with in persons suffering from some irregularity of the general circulation. Compresses, soaked in cold water or in goulard lotion, should be frequently applied; and a solution of nitrate of silver (gr. iv, ad. ℥j) may be painted over the outside of the lids. If there is much vascularity of the conjunctiva, and a slight muco-purulent discharge, a weak collyrium of sulphate of zinc or alum should be prescribed.

A peculiar bluish discolouration of the eyelids (more especially the lower one) is occasionally observed in persons of feeble health, and of a very transparent and delicate complexion. This dark tint is especially conspicuous beneath the lower lid, producing a dark blue, semicircular ring. This appearance is due to a dilatation of the subcutaneous veins, which are the more conspicuous on account of the delicacy of the skin. It is often difficult to cure this discolouration, more especially if a certain degree of œdema of the lid co-exists. I have found the most benefit from the use of a solution of Tannin (gr. iv—viii, to. ℥j of water), which is to be painted frequently over the outside of the eyelids. When this has been employed for some little time, a solution of acetate of lead or of nitrate of silver should be substituted. Care must, however, be taken that the nitrate of silver does not discolour the latter, which is especially apt to happen at the points where the latter is a little wrinkled. The general health should at the same time be attended to, irregularities in the circulation or the digestive functions be rectified, and abstinence from every form of dissipation strictly enforced.

2.—INFLAMMATION OF THE EYELIDS, ETC.

In the acute phlegmonous inflammation (abscess) of the eyelids, there is great redness, heat, and swelling of the lids, which are also acutely sensitive to the touch. The skin is greatly reddened, and, as the disease

advances, it assumes a darker and more dusky hue. The conjunctiva is also injected, and there is often a considerable degree of chemosis. The swelling is firm and hard and not œdematous; it often extends over the eyebrow and cheek, and may became so considerable that the upper lid is swollen up to the size of a pigeon's egg, or even larger. This hardness is at first especially conspicuous at one point, which feels like a little, firm, circumscribed nodule; this increases more and more in size, then the hardness gradually yields, the swelling becomes softer, more doughy, and there is a distinct sense of fluctuation. The skin becomes thinned and yellowishly discoloured at one point, gives way, and a large quantity of thick creamy pus escapes. In rarer instances, the perforation occurs through the conjunctiva. When the abscess forms at the inner angle of the eye, near the lachrymal sac, it has been termed *anchylops*, and may then be mistaken for acute inflammation of the sac. If it perforates at the inner canthus, it is called *ægilops*. It generally, however, occurs in the upper lid, which, on account of the swelling, hangs immoveably down, so that the palpebral aperture is quite closed. The pain is mostly very great, and of a violently throbbing character, extending over the corresponding side of the head and face. There is often also much constitutional disturbance and feverishness. The course of the disease may, however, be more chronic, and all the inflammatory symptoms be subacute in character. Abscess of the eyelid is almost always of traumatic origin, being produced by wounds or blows upon the eye. It may, however, occur spontaneously, or supervene upon severe inflammation of the conjunctiva, or erysipelas of the eyelids.

If the disease is seen at the very outset, we should endeavour to produce the resolution of the inflammatory swelling by the application of cold (iced) compresses, leeches, etc. But if we cannot succeed in this, hot poultices or sedative fomentations should be applied, in order to accelerate the formation of pus, and as soon as fluctuation is felt, a free incision should be made into the swelling parallel to the edge of the lid, so as to give ready exit to the discharge. For if this is not done, but the abscess is allowed to perforate spontaneously, the sufferings of the patient are not only greatly aggravated and prolonged, but the opening will be ragged and insufficient, and by the contraction of the cavity of the abscess, will tend to produce ectropium. If perforation has already occurred, the opening should be enlarged if it is insufficient for the free discharge of matter; and if several apertures exist close together, they should be laid open into one large wound. After the escape of the pus, warm poultices should be applied, and subsequently warm water dressing and a compress bandage, so as to keep the lid in position and the walls of the abscess in contact, and thus hasten the union. A generous diet and tonics should be prescribed. Any eversion

or malposition of the eyelid or puncta must be treated at a subsequent period.

In Erysipelas of the lids the swelling is not firm, hard, and of a dusky-red tint, but œdematous, softer, and of a more rosy, semi-transparent hue, the blush disappearing on pressure. The cuticle is frequently elevated in the form of small blisters by an effusion of serum. The swelling of the lid is often very considerable, and extends over the eyebrow and down the cheek; the conjunctiva is injected, and there is more or less chemosis. There is likewise much constitutional disturbance; the patient is feverish, his tongue foul and loaded, and he is often extremely weak and feeble. The pain is generally not very great nor of a throbbing or pulsating character. If pus is formed, the swelling assumes greater firmness, the skin becomes more tense and of a livid, dusky-red tint, and the pain, heat, and throbbing increase in severity. The swelling becomes softer, there is a distinct feeling of fluctuation, and then, if left to itself, the abscess points and perforates. The matter may extend freely into the connective tissue, and give rise to extensive sloughs. But erysipelas may produce much more serious complications, for the inflammation may extend to the cellular tissue of the orbit, giving rise to abscess within the latter and great exophthalmos, followed perhaps by sloughing of the cornea and loss of the eye; or, the inflammation may extend backwards from the orbit, along the optic nerve to the brain, and set up meningitis; or, again, the erysipelatous inflammation may also become diffuse, and extend to the face. The purulent matter, as Mackenzie points out, may likewise make its way into the lachrymal sac, which becomes filled with pus from without; in the production of which, its lining membrane has no share.

Erysipelas of the eyelids may be spontaneous in origin, being caused by exposure to cold and wet, more especially if the patient is already in feeble and delicate health from want or dissipation. It is often, however, of traumatic origin, being due to injuries, wounds, etc., of the lids. Our first object in the treatment must be to strengthen the patient. If the stomach is much deranged, the tongue loaded, the breath fœtid, a brisk purgative or an emetic should be at once administered. Then tonics should be given, more especially the tincture of steel, or preparations of steel and quinine. The diet must be generous, and stimulants, particularly port wine and brandy, should be freely administered. Warm poppy or laudanum fomentations should be applied to the lids, or they may be painted with collodion. If pus is forming, a free incision must be made at once, in order to permit of its ready escape. If the chemosis is very considerable and firm, so that it presses upon the vessels which supply the cornea, and thus endangers the nutrition of the latter, the chemotic swelling should be incised at different points; but if the pressure of the swollen lids is threatening this danger,

the outer canthus should be divided. When the erysipelatous inflammation has extended to the orbital cellular tissue, and the eye is protruded from a collection of pus or effusion into the orbit, a free and deep incision should be made so as to evacuate it.

Cases of *anthrax* (carbuncle) of the lids generally occur in elderly persons of feeble health. The inflammatory swelling is of a dusky, livid-red, and firm and circumscribed, and there is a great tendency to sloughing. Vesicles form on the lid and burst, discharging sanious matter; the skin and areolar tissue become black and gangrenous, and, sloughing out, leave a more or less deep cavity, which then granulates and cicatrizes. A crucial incision should be made into the swelling at an early stage, so as to allow the escape of matter, and facilitate the separation of the slough, and warm poultices should then be applied. The patient's strength must be sustained by a liberal administration of brandy, wine, tonics, and a good diet. If the pain is great, opium must be given, either internally, or by the subcutaneous injection.

Malignant pustule of the lids is said to be somewhat common in certain parts of France and of the continent, but I have never heard of its having been met with in England in its true type. According to Mackenzie, it is characterised by the formation of a vesicle filled with bloody serum, which is accompanied by a great and firm swelling of the lids, the skin of which is dusky and red. The base of the pustule is hard and nodular, and soon becomes sloughed, the gangrene spreading with great rapidity. There is severe constitutional disturbance, much fever, and intense pain. The disease is almost always produced by contact with decomposing carcases of cattle, or with animals suffering from farcy; hence it is most frequently met with amongst tanners, butchers, drovers, etc. It is so extremely dangerous that it may prove fatal within 24 hours of the outset, the inflammation extending to the head and neck, and the eye being either destroyed at the time, or subsequently from exposure. Mackenzie states that the best treatment is a deep crucial incision of the swelling, followed by the immediate application of the actual cautery. Tonics and stimulants should be very freely administered.

3.—SYPHILITIC AND EXANTHEMATOUS AFFECTIONS OF THE EYELIDS.

Syphilitic ulceration of the eyelid generally commences at its free edge, along which it rapidly spreads, more especially towards the skin, showing a greater tendency to extend in this direction than inwards towards the conjunctiva. The eyelid is much inflamed and swollen in the vicinity of the ulcer, and of a dusky, livid hue. The swelling is firm

and hard, and feels nodulated. The ulcer has a hard, cartilaginous base, its edges are irregular, and its bottom presents a peculiar dirty and lardaceous appearance. The whole surface of the lid is often swollen and indurated, and of a dusky-red tint, the inflammation extending generally to the conjunctiva, and being accompanied by a muco-purulent discharge. If the disease is not recognised and properly treated, the ulcer will rapidly spread, become deeply notched, and perhaps soon eat its way through the whole substance of the lid, destroying skin, cartilage, and conjunctiva. Indeed its ravages may be so great, that the whole of the eyelid may become destroyed, and the disease even extend to the other lid. In rarer instances, the ulcer may occupy the internal surface of the eyelid, and spread over a considerable portion of the palpebral conjunctiva without appearing externally. If the ulcer is situated at the inner canthus, or the inner edge of the lower lid in the vicinity of the lachrymal sac, it may be mistaken for a fistula of the latter; indeed it may penetrate into the sac. It is often somewhat difficult to determine with certainty the true nature of the disease, or to make the differential diagnosis between the syphilitic ulcer and the different forms of lupus and epithelioma. The syphilitic character of the ulceration must, however, be suspected, if it proves very obstinate, and instead of yielding to the usual remedies, gets worse and spreads more and more. We must then carefully and searchingly inquire into the history of the case, and ascertain whether any other symptoms of syphilis are present, such as eruptions of the skin, ulceration of the throat, etc., or whether there has been any chance of direct contagion. For although these ulcers are almost always secondary, a primary hard chancre of the lid may be met with. The softer variety appears, however, to be of rare occurrence. The ulceration may also extend to the eyelids from the neighbouring parts, such as the nose, etc. The treatment must consist in bringing the patient as rapidly as possible under the influence of mercury, either by inunction or mercurial baths; and the system should be kept slightly under its action for some time, otherwise a relapse may occur, or the ulcer return. The latter should be freely touched with caustic, and when it is beginning to heal, the red precipitate ointment, or the black wash, should be applied, in order to accelerate the cicatrization. If the ulceration proves very obstinate, and resists the action of mercury, much advantage is often experienced from a course of Zittman's decoction, as this is accompanied by a very free action of the skin. If this be inapplicable, warm baths should be prescribed for the same purpose.

In infants, the existence of congenital syphilis generally manifests itself by the appearance of papular or pustular eruptions on the face, hands, and around the anus. The eyelids are inflamed and swollen,

there is a purulent discharge, and, in very weak and feeble children, there is much danger of sloughing of the cornea and loss of the eye. Small doses of calomel and opium should be administered, and an astringent collyrium, or the red precipitate ointment should be applied.

I have already mentioned, when treating of the exanthematous affections of the conjunctiva, that the eyelids are also very prone to suffer during the exanthemata, more especially in small-pox. Eczema of the lids occurs very frequently in conjunction with eczema of the face. It is also due to severe and protracted inflammation of the conjunctiva or cornea, more especially phlyctenular ophthalmia, and is caused by the irritation of the constant discharge, and of the hot scalding tears flowing over the edge of the lid and down the cheek. The proper mode of treatment is described at p. 67.

4.—INFLAMMATION OF THE EDGES OF THE EYELIDS (TINEA TARSI, OPHTHALMIA TARSI, BLEPHARITIS MARGINALIS), ETC.

In the mildest form of the disease, we notice only a hyperæmic condition of the edges of the lids, which look angry, red, and sore. There is at the same time a feeling of heat and itching in the eyes, which becomes aggravated by exposure to very bright light, a smoky atmosphere, or by long continued use of the eyes at fine work. On awaking in the morning, the patient notices that the lids are somewhat glued together, and that small crusts form upon and clog the lashes, which are perhaps stuck together into little bundles by the hardening and drying of the discharge. The edges of the lids now become somewhat thickened and hypertrophied, and appear red, glazed, and shining. The discharge is also more copious and thicker, and the crusts more firm and consistent. If the disease advances, small white pustules are formed here and there at the roots of the lashes, which project through the pustules, or the latter may be situated between the cilia. These little pustules become excoriated, and exude a yellowish muco-purulent discharge, and readily bleed if the edge of the lid is rubbed, or the crusts are roughly removed. The margin of the lid becomes more and more inflamed, swollen, and irregularly notched, and the pustules may invade its whole extent, so that it looks quite raw and ulcerated when the crusts have been removed. When the whole substance of the lid along the margin is thickened and hardened, it is termed *tylosis*. The conjunctiva generally participates more or less in the inflammation, and this, together with the inflamed condition and altered secretion of the Meibomian glands, causes a sensation of sand and grit in the eyes, which feel, moreover, hot, dry, and very itchy.

This itchiness is especially marked, if the lid and cheeks become excoriated and inflamed. If conjunctivitis supervenes, there is of course an increase in the discharge, which now assumes a muco-purulent character. In the severer cases of blepharitis marginalis, suppuration of the hair follicles takes place, and the pustules which form at the base of the cilia may attain a considerable size, and, on giving way or being pressed, they exude a thick muco-purulent discharge, which dries upon the edge of the lid in the form of thick firm crusts, beneath which the margin of the lid is ulcerated, and perhaps deeply notched and indented. The lashes become loose, and are shed; either falling out, or remaining glued to the crusts. For some time, new lashes are formed, but they are not of normal strength or growth, but are weak, crooked, and stunted; but if the disease runs a very protracted course, and is severe in character, the lashes cease to grow, and a more or less considerable portion of the lid is completely deprived of them (madarosis), or, at best, a few, thin, straggling cilia are scattered sparsely along its margin. The position of the lashes often undergoes a considerable change, so that they become inverted, crooked, and stunted (trichiasis), or a double row of cilia (distichiasis) may be formed, either along the greater portion of the lid, or chiefly at one point. There is also much danger that the cicatrization of the ulcers should lead to a closure and obliteration of the Meibomian apertures, so that these become skinned over; the secretion from the glands is thus blocked up, and on pressing the edge of the lid no discharge exudes. This condition, and the inflammation of the Meibomian glands which often supervenes, aggravates still more the intensity and obstinacy of the disease. Indeed, when the apertures of the greater number of the Meibomian follicles are obliterated, the case may be considered incurable, and only capable of alleviation. Whereas, if these ducts are still open, a cure may with perseverance and care be looked upon as certain, although many months may elapse before it can be attained. On account of the thickening and hypertrophy of the edge of the lid, this gradually shows a tendency to become somewhat everted, and now the lachrymal punctum, instead of being turned in towards the eyeball, becomes erect or even everted, and the tears which can no longer enter it, flow over the edge of the lid, and thus tend still more to maintain or aggravate its inflammation. Moreover, the latter may extend to the puncta and canaliculi, and cause their obliteration. The inner edge of the lid loses its angularity, becomes rounded off, smooth, hardened, and cuticular in character. The contraction of the skin which ensues upon the cicatrization of the excoriated lids and cheek, moreover, increases this tendency to ectropium, so that even a considerable degree of lagophthalmos may be produced.

Blepharitis marginalis is frequently produced by the various forms of conjunctivitis or corneitis, more especially if the latter are accompanied by a great discharge of hot scalding tears, which constantly moisten and excoriate the edges of the lids. But it occurs also as a primary disease, and is then generally due to prolonged exposure to wind, cold, bright glare, or to an impure smoky atmosphere. Its intensity is much aggravated by dirt and want, and it is, therefore, most frequently met with amongst the poorer classes, and especially amongst those nationalities in which habits of cleanliness do not prevail. It occurs most frequently amongst children, but it is also met with in adults, and is especially prone to attack persons of a delicate, feeble, and scrofulous constitution, or who suffer from impairment of the digestion; in such, it proves especially obstinate and apt to recur. Dr. McCall Anderson considers that this disease is neither more nor less than a pustular eczema (impetigo) attacking the edges of the lids.*

In the treatment of this disease, the greatest attention must be paid to the most scrupulous cleanliness. In mild cases, the eye should be frequently washed with tepid water, or warm milk and water, so as to remove the crusts from the lashes, and when this has been done, a little of the weak nitrate of mercury ointment should be applied to the roots of the lashes with a fine camel's hair brush. If this proves too irritating, we should diminish the strength of this ointment by an admixture of one or two parts of lard. If the crusts are thick and firm, and the edges of the lids very swollen and red, mere ablution with warm water will not suffice, but compresses, steeped in hot water, should be applied for ten or twenty minutes, and frequently changed during this period. This should be repeated three or four times a day, or hot bread and water, or linseed meal poultices may be applied instead of the compresses. This will greatly alleviate the inflammation, and the crusts will be so thoroughly soaked and softened, that they will either become detached spontaneously, or can be removed without difficulty or injury to the lid. The hot compresses or poultices will be found especially useful in the morning, when the crusts are thick, and the lids firmly glued together by the nocturnal discharge. After the removal of the crusts, the lids may be bathed with tepid water, and then some astringent ointment or lotion should be applied. Before doing so, any diseased or stunted eyelashes should be extracted with the cilia forceps, as this favours the growth of the new ones, and renders the application of the topical remedy more easy. Indeed, if the disease is severe and implicates the greater portion of the lid, it will be well to remove the greater part of the lashes, or, as suggested by Mr. Streatfeild, to cut them down quite close to the margin. A great number of ointments

* "A practical Treatise upon Eczema," by Dr. McCall Anderson, p. 107.

and lotions have been recommended for this disease, and in very chronic and obstinate cases it is advisable occasionally to change the remedy.

In the milder forms, the application, night and morning, of the weak nitrate of mercury, or the red or white precipitate ointment will suffice.

If the edge of the lid is much excoriated, a solution of nitrate of silver (gr. v—x ad ℥j.) should be lightly painted over it every day; or pledgets of lint, dipped in a weaker solution of nitrate of silver or of sulphate of zinc, should be periodically applied. If small pustules or ulcers have formed, these should be touched with a finely pointed crayon of sulphate of copper or the mitigated nitrate of silver. I have also found very great benefit from the use of Wecker's ointment, which consists of equal parts of Oleum Lini and Emplastrum Plumbi, with a little Balsam of Peru. This is spread on a pledget of lint and applied to the lids at bed time, being kept on all night. On its removal in the morning, the eyes are to be well sponged with warm water. Dr. McCall Anderson strongly recommends the use of a solution of potassa fusa (usually ten grains to an ounce of water), a very little of which is to be painted every day on the edges of the lids with a fine brush by the surgeon himself. A large brush, soaked in cold water, should be in readiness to stop the action when desired. If any conjunctivitis co-exists, a drop or two of a collyrium of sulphate of zinc, or of alum should be applied two or three times a day. The eyes should also be protected against bright light and cold winds by a pair of blue eye-protectors. Together with this local treatment, great attention must be paid to the patient's general health. If he is of a scrofulous habit, or in delicate health, cod liver oil with steel or quinine should be administered. His diet should be nutritious but easily digestible, and all excess, more especially in drinking, should be avoided. Indeed, even the moderate use of stimulants cannot be borne by some of these patients, causing an aggravation or a relapse of the disease. In obstinate cases, I have also derived much benefit from the prolonged use of arsenic.

Acne ciliaris is not unfrequently met with; we then notice one or more small nodules, due to an inflammation of the sebaceous or hair follicles, and situated close to the edge of the lid, which is more or less swollen, red, and inflamed; indeed, if the attack is severe, the whole lid may be very œdematous. These nodules are situated in the subcutaneous cellular tissue, and are somewhat moveable, and several cilia may sprout out from the apex of the little pustules. The latter gradually increase in size, and, after having attained a certain volume, may undergo resolution; but they generally suppurate, the pus escaping either through the duct of the follicle, or making its way through the

external skin. In other cases, the nodule becomes hardened and indurated (*acne indurata*), and may thus exist unchanged for a very long time.

This disease is mostly met with in youthful individuals, who may be otherwise in very good health, excepting that they show a disposition to acne of the face. It may, however, occur independently of this, if the secretion of the sebaceous follicles of the eyelids is from any cause morbidly altered; so that, either from its excess in quantity or hardness, it becomes confined in the gland, and then sets up inflammation. On account of the larger size and number of the sebaceous follicles in the upper lid, acne occurs more frequently in this than in the lower. The causes of acne ciliaris resemble those of acne in general, and, like the latter, this disease generally runs a protracted course, and is very apt to recur. Amongst the principal causes, I may mention irregularities in diet, free indulgence in wine, spirits, or other excesses; and, in females, derangement of the uterine functions. Exposure to dust, dirt, cold winds, bright glare, etc., increases the severity and obstinacy of the disease, and favours the tendency to relapses. If the affection has lasted for some time and is accompanied by a good deal of inflammation, it may become complicated with blepharitis marginalis.

Great attention should be paid to the cleanliness of the lids, which should be frequently washed, so that any discharge which clogs the lashes, or has become encrusted on the lids, may be removed. The loose or affected eyelashes should be frequently plucked out. If the nodule and the neighbouring portion of the lid are red, inflamed, and painful, cold compresses should be applied, but if signs of suppuration appear, hot poultices or fomentation should be substituted, and the pustule be punctured, in order that the discharge may find a ready exit. In the indurated form, an ointment containing mercury or iodide of potassium should be applied. The diet and habits of the patient should be carefully regulated, and if he is feeble and delicate in health, tonics should be administered.

The presence of lice* on the eyelashes (phtheiriasis ciliarum) might be mistaken for tinea, but the crusts present a more circumscribed and beaded form. The citrine or red precipitate ointment should be applied twice daily, which will generally kill the pediculi in a few days. If they are numerous, it may be necessary to clip the lashes very close.

5.—EPHIDROSIS AND CHROMHYDROSIS.

An excessive secretion of the sudoriferous glands of the lids, more especially the upper, is occasionally met with. The perspiration exudes

* "R. L. O. H. Rep.," ii, 125.

so freely that the surface of the lid is covered by a thin layer or film of fluid, reaching perhaps nearly up to the edge of the orbit. This condition is termed Ephidrosis. On wiping the skin dry with a fine dossil of linen, we can easily notice (with the aid of a magnifying-glass) that the moisture exudes from innumerable little pores, flows together into larger drops, and finally covers the lid with a thin layer of fluid (Von Graefe*). Soon the conjunctiva becomes somewhat injected and inflamed, the edges of the lids sore and excoriated (more especially at the angles of the eye) from the constant irritation of the moisture, and an obstinate blepharitis marginalis, with a slight degree of conjunctivitis, is set up. The patient at the same time complains of a peculiar itching and biting sensation on the outer surface of the lid. The affection is very obstinate and protracted, for although astringent lotions and collyria benefit the inflammation of the conjunctiva and the edge of the lid, they exert but little, if any, influence upon the secretion of fluid. Wecker recommends his "Pommade antiblepharitique" (p. 677). The general health, and especially the action of the skin and kidneys, should be attended to.

Chromhydrosis (stearrhæa nigricans of Erasmus Wilson). Under this title has been described a very peculiar pigmented condition of the eyelids, which is characterised by the appearance of a dark brown or brownish-black discolouration of the lids, more especially the lower, which is chiefly noticeable in the folds of the skin, and does not reach up to the lashes. It can be readily removed with oil or glycerine, but, apparently, not with water. It has been chiefly met with in females, more especially those of a nervous, hysterical temperament, and there can be but little doubt that it is artificial, being due to some pigment painted on by the patient in order to deceive her medical attendant, and to awaken interest or compassion. For a very full account of this condition, I would refer the reader to The French Translation of Mackenzie, iii, 44, and to a paper read by Dr. Warlomont, before the Heidelberg Ophthalmological Congress, 1864, vide "Kl. Monatsbl.," 1864, 381.

6.—HORDEOLUM (STYE).

This disease is not, as is sometimes supposed, an inflammatory affection of the Meibomian glands, but is a furuncular inflammation of the connective tissue of the lids, having its seat generally in the vicinity of the hair follicles, and near the margin of the lid. In most cases, there is only one boil, in others, there are several. At the outset of the disease, we notice a small circumscribed nodule or button near the edge of the lid, the skin being freely moveable over it. If the development is very acute, the lid is often much inflamed, very red, and

* "A. f. O.," iv, 2, 254.

œdematous; and although these symptoms are generally confined to the portion of the lid in the vicinity of the stye, they may extend to the whole eyelid. If the upper lid is the one affected, it may hang down in a massive fold and quite close the palpebral aperture, there being at the same time, perhaps, a good deal of photophobia and lachrymation. The patient generally complains of very considerable pain, and the swelling in the vicinity of the nodule is exquisitely tender to the touch; sometimes, there is also a good deal of feverishness and constitutional disturbance, the sufferings of the patient being quite out of proportion to the extent of the disease. The latter may, however, run a more subacute or chronic course. The prominence produced by the nodule is mostly at once evident to the eye, assuming the appearance of a little circumscribed tumour, about the size of a pea, the skin of the lid in its vicinity being of a dusky, angry red. Sometimes, several lashes project from its apex, if it is situated at the margin of the lid. If it be not visible, its presence may be easily detected by lightly passing the tip of the finger over the surface of the eyelid. On eversion of the latter, the conjunctiva will generally appear smooth and unaltered, but if the hordeolum points inwards, the circumscribed nodule will appear on the inner surface of the lid, the conjunctiva over and around it being reddened and swollen. The apex of the little button presents a greyish yellow tint, if suppuration has set in and the matter "points." If the disease is allowed to run its course, it may sometimes undergo resolution, but, as a rule, suppuration sets in and perforation takes place, more or less thick purulent matter being discharged, together with which there is often mixed some greyish-white gelatinous substance, consisting of ill-developed or broken down connective tissue. This is discharged in little lumps. The disease shows a very great tendency to recur again and again, so that its existence may be prolonged for very many months, and this has led some authorities to consider it dependent upon some peculiar diathesis. It is most frequently met with in youthful individuals, more especially in those of rather delicate health, who are often subject to acne, or who are addicted to free living or dissipation. If the course of the disease is protracted, and more especially if there are frequent relapses, it is not unfrequently followed by chalazion, due to inflammatory changes in the Meibomian glands, and followed by fatty or chalky degeneration of their contents.

At the very outset of the disease, more especially if there are severe inflammatory symptoms, cold compresses should be applied; but, as a rule, I prefer the use of hot poultices, which should be changed very frequently; for this will greatly accelerate the formation of pus, and expedite the progress of the case. When suppuration has set in, and the skin has become thinned and yellow at one point, a small incision should be made to permit of the ready escape of the pus, with which

will generally be mixed some of the grey gelatinous connective tissue. The pain is immediately and greatly relieved by the incision. When cicatrization has taken place, I have found much benefit, in preventing a recurrence of the disease, from the use of a weak ointment of nitrate of silver (gr. ij.—iv. ad ℥j.). If the patient is feeble and out of health, tonics must be given, and the digestive functions thoroughly regulated.

7.—TUMOURS OF THE EYELIDS.

Chalazion (Tarsal tumour, Tarsal cyst) is a tumour due to inflammatory changes of the Meibomian glands or ducts, giving rise to an alteration and retention of the secretions. If the inflammation has been acute, or if an acute inflammatory exacerbation has occurred, suppuration may take place and pus be formed. In other cases, the contents of the cyst, instead of being purulent or muco-purulent, are fluid, gelatinous, fatty, or sebaceous and clotted. The tumour is generally about the size of a little pea, but may increase to that of a small bean; it is situated at some distance from the free margin of the lid, and is generally most manifest on its inner surface, lying close beneath the conjunctiva (which is often considerably thinned), and forming here a small, circumscribed, bluish or yellowish-white tumour, which springs prominently into view when the lid is well everted and the conjunctiva put upon the stretch. In other and rarer cases, the tumour points outwards and lies close beneath the skin, which is frequently somewhat reddened and thinned over and around it. It occurs far more frequently in the upper than in the lower lid. Sometimes, it may exist in both eyelids, or in both eyes.

If the tumour is small and hard, and its formation has been extremely slow, we may endeavour to favour its absorption by the use of red precipitate or iodide of potassium ointment, but as a rule this proves quite ineffectual, and we must generally have recourse to operative interference. If the tumour presents upon the conjunctival surface, the lid should be thoroughly everted, and the conjunctiva put upon the stretch, so as to render the little nodule prominent and tense. A free crucial incision should then be made into it with a cataract knife or small scalpel, so that it may be laid well open. If the contents are fluid or muco-purulent, they will at once escape; if this is, however, not the case, and they are somewhat coherently gelatinous, a small curette should be introduced, and gently turned round, so as to break down and scoop out the contents. Should small portions of the latter adhere to the wall of the cyst, they should be snipped off with a pair of scissors curved on the flat. If the tumour is deeply seated and near the outer surface, the incisions must be proportionately deep, and

extend through the tarsus, as it is generally better to open the tumour, if possible, from within, for we thus avoid the formation of a cicatrix in the skin. Special attention must be paid to this if the chalazion is situated near the margin of the lid, and particularly near the punctum, for then the cicatrix would be very prone to produce a certain degree of eversion of the edge of the lid, and displacement of the punctum. But if the tumour is situated at some distance from the edge of the lid and in its central or outer portion, lying close beneath the skin, and if the latter is lax, the incision may be made from the outside; for the wrinkles of the loose skin will hide the cicatrix and prevent the danger of eversion. The removal of the contents is generally accompanied by considerable bleeding, and the tumour may, hence, appear to be hardly reduced in size. But in the course of a few days, the adhesive inflammation supervening on the operation will cause a contraction of the cyst, and it, and the thickening of the structures in its vicinity, will rapidly disappear. This adhesive inflammation may be augmented by lightly touching the interior of the cyst with a finely pointed crayon of nitrate of silver.

If the tumour is hard and firm, I generally direct the patient to apply hot poultices for a day or two before the incision, as this accelerates any tendency to suppuration, and softens the contents so that they are less tenacious and more easily removed. As patients affected with chalazion often suffer from irregularities of the digestive functions, these should be carefully attended to.

The Meibomian follicles sometimes become obstructed, without there being any swelling or dilatation of the glands. These obstructions are due to an accumulation of the secretion in the ducts, giving rise to small yellowish-white concretions, either studded irregularly about the smooth conjunctival surface, or arranged, perhaps, in single file, like little pin's heads, along the course of the duct. If these are very small, few in number, and unattended with any inconvenience or irritation, we need not interfere; but if they are numerous, large in size, and productive of irritation, they should be pricked with the point of a knife, and the hardened contents squeezed out, or their removal may be facilitated by using a grooved spud.

Milium is a minute white tumour, about the size of a millet seed, hence its name, which is mostly situated at or near the free edge of the lid. It generally occurs isolated, although perhaps in considerable numbers, or the tumours may be arranged in clusters. The cilia sprout forth from the centre of, and between, these little nodules. The latter should be pricked, and their soft, suet-like contents squeezed out.

Molluscum, or *albuminoid tumour* is of the same nature as milium, but attains a much more considerable size, and is generally situated at some little distance from the edge of the lid, and is quite painless.

The skin over it is, as a rule, somewhat thinned, so that its yellowish-white colour and nodulated surface are very evident. In its centre is sometimes noticed a minute opening, through which a little white fluid exudes, and drying, forms a little brittle crust upon it. In recent cases, this matter is contagious. If the tumour exists for a very long time, its attachment to the skin may be stretched and elongated, so that it has a more or less distinct neck or pedicle, which renders it pendulous. Molluscum is generally not confined to the lids, but occurs at the same time upon the face and other parts of the body. The crust upon its apex should be detached with a pair of forceps, the nodule pricked or slightly incised, and the contents squeezed out between the thumb nails. If it is not emptied at once, the pressure should be repeated. When several mollusca exist on the eyelids and face, it is better to operate upon them all at one sitting.

Sebaceous tumours occur most frequently in children, and resemble molluscum in their nature, but attain a still more considerable size, reaching perhaps that of a large filbert or even a small walnut. They occur most frequently at the outer and upper margin of the orbit, close to the eyebrow. The skin over the tumour generally retains its normal appearance, or may become somewhat reddened. The contents are enclosed in a cyst wall, the posterior portion of which is somewhat thickened and hypertrophied, and are suet-like and sebaceous, consisting of broken down epithelial cells, fat molecules and hairs. In other cases, the tumour is softer, and its contents more oily. If it is very small and its appearance does not annoy the patient, it may be left untouched, but, otherwise, it should be removed at an early stage. As in order to prevent its return, it is necessary to remove it whole, it is better not to puncture it and squeeze out its contents, but to dissect it out, if possible without tearing or pricking the cyst wall. Hence, a free incision should be made through the skin, with a cataract knife or small scalpel, and parallel to the edge of the orbit. When the tumour is of considerable size, a crucial incision may be made so as to facilitate the dissection, but generally one long incision will suffice. The tumour should then be slowly and carefully dissected away, the adhesions between the cyst-wall and the surrounding cellular tissue being delicately severed with the point of the knife, or detached by gentle traction, assisted perhaps with the end of the handle of the knife. An assistant should be ready with a sponge, to wipe away the blood, so that the operator may constantly have a good view of the outline of the tumour and its adhesions, otherwise, the cyst-wall may easily be pricked, and its white pultaceous contents begin to escape, which greatly increases the difficulty of completely removing the tumour. If the cyst-wall has not been removed entire, the remaining portions may be lightly touched with nitrate of silver. In order to accelerate the union, the edges of the wound should

be brought together with fine sutures, and cold water dressing be applied.

Fibroma is met with in the eyelids in the form of a small, hard, circumscribed tumour, being sometimes congenital, and occasionally exquisitely painful to the touch. These tumours occasionally assume a cartilagineous character, and spring prominently into view when the eyelid is everted, looking like a second tarsal cartilage (Wecker). Von Graefe* reports a tumour of this kind, occurring at the outer angle of the eye, and which had attained the size of half a hazel nut. It was situated in the submucous connective tissue, and, on removal, was found to consist of true bone tissue.

Fibromas increase but very slowly in size, and this forms the chief distinguishing feature between them and sarcomatous tumours, for they cannot be distinguished with certainty from the latter except with the microscope.

Under the term *cylindroma* Von Graefe describes a peculiar tumour† which is sarcomatous in its nature, and is met with in close vicinity to the eye, *e.g.*, the eyelids, orbit, etc., or the head. It is particularly distinguished by the fact that, together with its sarcomatous structure, it shows peculiar club-shaped outgrowths from the capillaries and veins (Recklinghausen‡). The tumour is very painful if firmly pressed, but spontaneous pain only occurs periodically. It shows a tendency to recur after removal, as it is very difficult to extirpate it completely.

Warts occasionally form on or near the edges of the eyelids, and should be snipped off with a pair of scissors, or touched with caustic or acetic acid. If their base is narrow, a silk or fine horse-hair ligature should be applied, so as to strangulate it, which will cause the wart to drop off in the course of a few days.

Fatty tumours are not of frequent occurrence in the eyelids, they may generally be readily recognised by their smooth, circumscribed, somewhat lobulated form, and are firm and elastic to the touch. Their progress is, as a rule, extremely slow, and they can be readily removed.

Epithelial cancer is almost the only malignant tumour which occurs primarily in the eyelids, for the other forms, such as scirrhus, medullary cancer, etc., are generally only secondarily met with in this situation.

Epithelial cancer shows itself most frequently in the lower eyelid, and near the outer canthus. It occurs generally in persons above the age of forty, or even in those much more aged, being rarely met with in youthful individuals. At the outset, the disease assumes the appearance of a small, circumscribed, slightly elevated induration,

* "Kl. Monatsbl.," 1863, p. 23.

† "A. f. O.," x, 1, 184. ‡ Ibid., 190.

situated at, or close to, the edge of the lid, and looking like a wart or a small thickened crust. It is covered by healthy-looking, uninflamed skin, and a few varicose vessels are perhaps seen to pass over or near it. The surface of the little nodule often looks rough and scaly, as if the cuticle were thickened. It may remain in this condition for a very long period, and years may elapse before it increases materially in size, or becomes ulcerated. On this account, and from its being quite painless, it is often entirely disregarded by the patient, who supposes it to be simply a wart. When the disease occurs in the skin over the lachrymal sac, it has been mistaken for dacryocystitis. Thus Mackenzie mentions one instance, in which the patient called to have a style introduced, and another, in which one had actually been worn. But sooner or later it gradually and almost imperceptibly increases somewhat in size, creeping along the edge of the lid and assuming a lengthened, ovoid shape. Its surface becomes broken and excoriated, and a thin, greyish-yellow discharge exudes from it, which hardens upon it in the form of dark, rough crusts. Then ulceration sets in, and the tumour slowly spreads in circumference and depth, the edges of the ulcer being somewhat elevated, and studded, perhaps, with a few palish-red tubercles, which rapidly form again if abscised. The skin around the tumour is but little thickened, swollen, or discoloured, and this distinguishes the disease from lupus, and also from syphilitic ulcer. Moreover, the slowness of its growth and the history of the case, would prevent its being mistaken for the latter. When the ulceration sets in, the pain increases, but seldom to any considerable degree, nor is it of a very acute, lancinating character, but if any nerves are exposed by the ulceration, the patient's sufferings will of course be much augmented. The discharge is of a yellowish colour, healthy in nature, and free from fetor.* Sometimes, the ulcer may become temporarily cicatrised, either completely or in part, and then remain apparently healed for a certain time; but soon a breach of surface again occurs, and fresh ulceration sets in. In time, the ulcer invades the lid more and more, spreading along its surface and extending deeply into its structure, until it may eat its way completely through its whole thickness, and appear on the conjunctival surface; thence, perhaps, extending to the orbit. If the lids are destroyed, the eyeball will be exposed, and suppuration of the cornea may ensue, accompanied perhaps by loss of the lens and a considerable portion of the vitreous humour, and followed by atrophy of the globe. Mackenzie† has witnessed the most excruciating pain ensuing upon implication of the eyeball, or when the ulceration affected the infra-orbitary and supra-orbitary nerves. The disease may also extend to the face, finally opening into the mouth.

* Vide Dr. Jacob's able paper on this disease, "Dublin Hospital Reports," vol. iv, 1827.

† "Diseases of the Eye," 4th ed., 137.

The veins which pass over the ulcer often give way and cause very considerable hæmorrhage.

The cause of the disease is frequently dubious, but sometimes we are able distinctly to trace its origin to some injury or blow, or the existence of some prolonged source of irritation.

If the disease is moderate in extent and circumscribed, so that there is hope of entirely removing it, the treatment by extirpation is, I think, as a rule, the best; care being taken to carry the incisions through the healthy integuments, for fear of leaving any of the morbid tissue behind. The incision is generally made of a V shape, and sufficiently large to include all the diseased portion within it. The edges of the wound should be brought together with fine sutures; or if the loss of substance is considerable, a plastic operation should be performed, and the skin brought from the temple or cheek. Mackenzie, however, prefers to make a semilunar incision, and to allow the wound to heal by granulation. It must be admitted, however, that even when the operation has been followed by a firm cicatrix, and the disease has appeared to have been cured, that after a time a relapse has taken place; and hence the treatment by escharotics and other agents has been strongly recommended. Potassa fusa and the chloride of zinc paste have been especially used as caustics. Mackenzie* strongly recommends the sulphate of zinc for this purpose. The water of crystallisation of the sulphate of zinc having been driven off by heat, and the residuum reduced to a fine powder, he mixed it with a little glycerine, so as to form a thick tenacious paste, and on the point of a bit of stick, applied it over the scab and the hard edges of the ulcer; the part being then covered with a bit of dry lint. This treatment was repeated two or three times, and produced a firm, healthy cicatrix, and apparently an excellent cure.

Dr. Broadbent's treatment by injection of acetic acid (one part of strong acid to about four of water) may also be tried, and has proved very successful in the hands of several distinguished surgeons, amongst others, Mr. Power,† M. Wecker,‡ etc. Dr. Althaus's treatment by electrolysis may also be tried, being quite free from any pain or discomfort. M. Bergeron§ recommends the internal and local use of chlorate of potash.

8.—NÆVUS MATERNUS (TELANGIECTASIS).

This disease is occasionally met with on the eyelids, and may vary considerably in size and appearance. Its surface may be smooth

* "R. L. O. H. Rep.," ii, 5.

† Mr. Power on Diseases of the Eye, p. 103.

‡ Wecker, "Maladies des Yeux," 2nd edition, i, 659.

§ Ib., p. 659.

and even, or granulated, and perhaps divisible into two or three distinct portions. The colour also varies from a light scarlet to a dark bluish-red or purple. Nævi may be quite superficial and confined to the skin, or extend deeper and implicate the subcutaneous tissue, perhaps to a considerable extent. They have also been divided into an arterial or active, and a venous or passive form. The former are firm and distinctly pulsatile to the touch, and cannot be emptied, except the vessels which supply them are compressed (Mackenzie). The venous are softer and more elastic, and can be easily emptied by pressure. On the patient's stooping down, the nævus rapidly swells up, and becomes dark and very tense.

The disease is often congenital, and may increase gradually up to a certain point, and then remain almost stationary, or else it may spontaneously diminish in size, and slowly disappear without leaving a trace behind.

Various modes of treatment have been recommended for this disease. Of these the best are, I think, the application of threads soaked in perchloride of iron, the various forms of ligature, and electrolysis. Injection of the perchloride of iron is excessively dangerous, and several cases of instantaneous death have been recorded. Hence it is far wiser to traverse the tumour in different directions with threads dipped in perchloride of iron, and to allow them to remain in for a few days. The subcutaneous ligature, either a figure of 8, or circular, also proves very successful. If the tumour is considerable in size, and divisible into several portions, one of these may be taken at a time, and the operation repeated several times. Wecker* transfixes the base of the little tumour by two needles crossed at right angles (+), and then firmly strangulates the base with a thread passed beneath the needles.

The application of electrolysis to these nævi, appears to me to be very serviceable. Dr. Althaus,† to whom we are indebted for the introduction of this mode of treatment, has found it very successful, and narrates a case in which a nævus of the eyelid (in a patient of Mr. White Cooper) was rapidly cured without leaving any trace behind. The great advantages of electrolysis are, that it is free from all pain and danger, and that it does not leave any scar or disfigurement.

Galvano-puncture has also been recommended.

9.—PTOSIS.

In this affection the upper eyelid droops down, so that the palpebral aperture is greatly narrowed, and the cornea more or less covered,

* L. c., 653.

† Vide Dr. Althaus's interesting work on Electrolysis.

the patient being unable by a voluntary effort to raise the lid. In the chapter upon the paralytic affections of the muscles of the eye, it was mentioned that ptosis is a frequent symptom in paralysis of the third nerve, on account of the *levator palpebræ superioris* being supplied by this nerve. In a complete paralysis of the third nerve, we should find, besides the ptosis, that on our lifting the patient's eyelid, the eye would be immoveable in all directions except outwards, that the pupil would be dilated and the power of accommodation paralysed. The ptosis may be either partial or complete; in the former case, the upper lid can still be somewhat lifted, and does not droop to the full extent, in the latter, it hangs down quite immoveable, and has to be lifted up by the assistance of the finger. The palpebral aperture may, however, be somewhat widened, and the upper lid slightly elevated by the relaxation of the orbicularis and the contraction of the frontalis muscle. The causes of the paralysis of the third nerve have already been mentioned at p. 565, and I need not here recur to them. It must be stated, however, that in some rare instances, the branch to the levator palpebræ may be alone implicated, owing to its direct compression by an exostosis, tumour, etc., the other branches of the third nerve being unaffected. Or again, some traumatic lesion, implicating the nerve or the muscle itself, may be the cause. Ptosis may also occur independently of any paralytic affection, being due to some want of development or congenital insufficiency of the levator palpebræ, which co-exists sometimes with epicanthus. Or it may remain after the great swelling of the lid and hypertrophy of the conjunctiva accompanying purulent or granular ophthalmia, the levator not being sufficiently strong to overcome the weight. A certain degree of ptosis is also sometimes observed in aged people, if there is a great superabundance of flaccid skin, and the levator palpebræ is at the same time somewhat weak.

The treatment must be varied according to the cause of the affection. If it be due to paralysis, the general line of treatment laid down in the chapter upon the Paralytic Affections of the Eye (p. 567) must be followed. Electricity often proves of considerable benefit. But if the disease resists all these remedies, recourse must be had to operative interference. In those cases, in which the ptosis is simply due to an over-abundance or hypertrophy of the skin, a horizontal fold of the latter, parallel to the edge of the lid, should be pinched up with a pair of forceps and excised, the edges of the wound being united by fine sutures.

The attempt has, moreover, been made by Bowman and Von Graefe to bring forward the insertion of the levator palpebræ, and thus augment its power, on the same principle upon which the insertion of some of the ocular muscles is sometimes brought forward. But the

results were not favourable. Von Graefe* has more lately devised the following operation:—A transverse incision is made through the skin of the upper lid about 2½ lines from its free margin, and extending the whole length of the lid, the incision being made to gape by a vertical traction upon its edges, and by somewhat separating the subcutaneous cellular tissue with the knife. When a sufficient breadth of the orbicularis has been thus exposed, it is to be seized with the forceps, and a portion of about four or five lines in width is to be excised, care being taken not to injure the subjacent fascia. The incision is then to be united by sutures, which are to be carried through the skin and the cut edges of the orbicularis. The effect of this operation is to cause a subcutaneous shortening of the upper lid, to weaken the action of the orbicularis, and thus to assist that of the levator. If the length of the lid is increased, Von Graefe, after having finished the transverse incision, makes a second, having its convexity upwards, so that a shortening of the skin may be combined with the subcutaneous shortening of the lid.

10.—PARALYSIS OF THE ORBICULARIS PALPEBRARUM.

In this affection we find that the eyelids cannot be completely closed, on account of the inefficient elevation of the lower lid, so that a chink of varying size exists between the two lids. By a strong effort of the will, the patient may succeed (more easily if the other eye is closed), in almost shutting the lids by the relaxation of the levator palpebræ. The wide gaping of the eyelids gives a peculiarly staring appearance to the patient, and is termed *lagophthalmos*. The paralytic lagophthalmos is present even during sleep, and resists the action of reflex irritants applied to the conjunctiva. Paralysis of the orbicularis is soon followed by other symptoms. There is marked epiphora, and the constant flowing of the tears over the cheek soon causes irritation and excoriation of the edges of the lids, upon which thickening and eversion supervene. The exposure of the eye to external irritants (such as particles of dust, etc.) soon produces conjunctivitis and superficial corneitis, ending, perhaps, in pannus and xerophthalmia.

The affection of the orbicularis is due to paralysis of the portio dura. The orbicularis may be alone affected, or the paralysis may extend to several, or all the branches of the portio dura. It is only very rarely met together with hemiplegia. The causes of the disease may be peripheral or central. Amongst the former, exposure to cold air, damp, etc., is the most frequent. It may also be caused by direct pressure (as from a tumour) upon any part of the nerve, or by in-

* "A. f. O.," ix, 2, 57.

juries which implicate the latter. Amongst the cerebral causes, need only be mentioned the presence of tumours, syphilitic exudations, hæmorrhagic or purulent effusions, etc., and different lesions situated at the base of the brain. If the disease is due to paralysis, the treatment laid down in the article upon paralytic affections of the muscles of the eye should be pursued.

11.—BLEPHAROSPASM.

This affection varies much in intensity. In slight degrees, there may only exist a moderate degree of temporary twitching and contraction of the lids, which soon passes off again. In very severe forms, the spasm of the orbicularis may be so great, that the eyelids are firmly pressed together, and that it is quite impossible for the patient or the surgeon to open them even to a slight degree. The endeavour forcibly to open the eye is intensely painful, and may even almost throw the patient into epileptiform convulsions. At the outset, the disease is generally but moderate, but if the cause persists, or efficient treatment is not adopted, it gradually increases in severity, and the spasm, which was before perhaps only periodical, becomes permanent, so that the patient cannot open his eye at all. Then the other eye may become affected in a similar manner, and the muscles of the face, neck, and even of the extremities, may undergo spasmodic contractions.*

Blepharospasm is often met with in the course of inflammatory affections of the cornea and conjunctiva, or if a foreign body has become lodged within the folds of the latter. In such cases, it is evidently due to a reflex neurosis dependent upon irritation of some of the branches of the fifth nerve. This disease likewise occurs in severe cases of hyperæsthesia of the retina. It is also observed in connection with neuralgia of the supra-orbital nerve, or of other branches of the fifth; the exact seat of these affections being perhaps unsuspected until a certain spot is found, where firm pressure will at once arrest the spasm. It must be mentioned, however, that in some instances even direct pressure upon the facial nerve at its exit through the stylo-mastoid foramen, will stop the blepharospasm (Romberg).

The treatment of the disease must vary with the cause and duration. Thus the severe blepharospasm often noticed in the course of corneal affections disappears with them; or if it persists, it often yields to tonics, immersion of the head in cold water, sea bathing, and the subcutaneous injection of morphia. Indeed, the latter remedy is often found of great benefit in the treatment of these spasmodic affections. From one-sixth to one-third of a grain of morphia should be injected

* "A. f. O.," i, 1, 440.

at the point where pressure will stop the spasm, and be occasionally repeated. If, however, these remedies fail to cure the blepharospasm, and if pressure upon the supra-orbital nerve stops it, and enables the patient momentarily to open his eye, this nerve must be divided. This operation was first performed by Von Graefe, at Romberg's suggestion, in a case of intense blepharospasm which had supervened upon the lodgement of a foreign body in the folds of the conjunctiva. It was evidently a case of hyperæsthesia of the orbicularis from contusion, and was considered by Romberg to be a reflex spasm due to a pathological irritation of the sensory nerves. He, therefore, advised the division of the supra-orbital nerve, from which recurrent (sensory) branches are probably distributed to the orbicularis. The operation proved perfectly successful, and has since then been often repeated by Graefe and other surgeons with much benefit. The supra-orbital nerve should be divided close to its exit from the supra-orbital foramen, and in order to facilitate this, the eyebrow should be drawn well upwards, so as to make the skin tense. If the nerve is not completely divided, the effect will only be slight or temporary, and the operation should be repeated. As this non-success may sometimes be due to a reunion of the divided ends of the nerve, some surgeons have cut out a piece of the latter. After the operation, there should be a certain degree of anæsthesia just above the divided portion of the nerve, and in the upper lid. The operation should be performed under chloroform, more especially in children. Prior to its performance, the surgeon should, of course, try whether the firm compression of the supra-orbital nerve alleviates the blepharospasm, for only in such cases can we expect a favourable result.

Nictitation, or involuntary convulsive twitching of the eyelids, is occasionally met with in a varying degree, and is generally owing to a reflex neurosis producing a spasmodic contraction of the orbicularis; these twitchings following each other in rapid succession. The affection may be limited to one eye, or involve both, the upper lid being more frequently implicated than the lower. It is always markedly increased by any nervousness or agitation of mind, and is frequently met with in persons in a weak, nervous, or hysterical condition. It may also be due to some local irritation, as an inverted lash, slight inflammation of the conjunctiva, etc. It is sometimes observed in cases of hypermetropia, in which glasses are not worn, and will then disappear with the removal of the cause. In nervous and delicate persons, the general health should be attended to, an aromatic and slightly stimulating lotion applied to the lids, and the eye-douche be used. In hypermetropia, the proper glasses should be ordered, and then the twitching will soon disappear.

12.—TRICHIASIS AND DISTICHIASIS.

These conditions are characterised by an irregularity in the growth and direction of the eyelashes, which are more or less inverted. In trichiasis the lashes are irregular, some perhaps having a natural position and appearance, whilst others are incurved, thin, pale, straggling, and stunted. In distichiasis, there are two distinct rows of lashes, the outer being in the usual position, the inner being situated further back and turned inwards. The double arrangement is, however, often only apparent, being due to a thickening and stretching of the edge of the lid, and a consequent alteration in the direction of the hair bulbs and the cilia. Both trichiasis and distichiasis may affect the whole length of the lid, or be limited to a certain portion or portions of it; and if the malposition only involves a very few, colourless, thin cilia, it may readily be overlooked, and maintain a prolonged and very annoying irritation of the eye and lids.

This faulty position of the cilia is generally accompanied, or soon followed, by a certain degree of inversion of the eyelid (entropium), and perhaps by a shortening and incurvation of the tarsal cartilage. But in the simple and true trichiasis or distichiasis this is not the case, and the position of the lid and the condition of the cartilage are perfectly normal.

The most frequent causes of these conditions are long continued and severe inflammations of the conjunctiva (purulent and granular ophthalmia, etc.), and of the edge of the lid; in which the hair follicles have undergone inflammatory and suppurative changes, so that they are either destroyed, or their functions so much impaired, that the growth of the lashes is injured, and they become weak, stunted, and distorted. Ulcers and small abscesses at the roots of the cilia, or injuries (burns, cuts, etc.) of the edge of the lid, may also produce these affections.

The irregular growth and inversion of the lashes, even although only a few may be involved, set up considerable irritation of the eye, which becomes watery, red, and irritable, the patient complaining of a constant pricking and itching in it, as if a minute foreign body, or a little sand or grit were lodged beneath the lid. If the affection is allowed to continue, the symptoms of irritation increase in severity, and there may be considerable lachrymation and photophobia. The constant spasmodic contraction of the eyelids causes an inversion of the edge of the latter, which may in time become permanent, so that an entropium is superadded to the trichiasis. After a time, the constant friction of the inverted or stunted lashes against the cornea sets

up a superficial corneitis, and a more or less severe degree of pannus will supervene.

The treatment of distichiasis and trichiasis must vary with the extent and severity of the disease. If only a few, straggling cilia are misplaced, their repeated evulsion may eventually cure the affection. By frequently extracting the lashes, we may in time succeed in causing an atrophy of the hair bulbs, and thus arrest the growth of the cilia. Indeed, many patients learn to do this very well for themselves, or are satisfied to have the lashes extracted every few weeks by their medical attendant. If the trichiasis is confined to a very few and scattered lashes, this treatment may suffice. But the oft-repeated evulsion occasionally leads, after a time, to a certain degree of irritability of the eye, and may thus become a source of annoyance to the patient. Sometimes, the destruction of the hair follicles by the application of liquor potassæ also proves successful, where only a few cilia are implicated. A horn spatula having been inserted beneath the eyelid, and the edge of the latter put on the stretch and somewhat everted, so that the row of lashes is brought well into view, the point of a needle (dipped into liquor potassæ) should be run up to the roots of the distorted lashes, so as to reach their follicles; or liquified potassa fusa may be employed for this purpose and in the same manner, as has been proposed by Dr. Williams.* This will generally soon cause their destruction. Some surgeons also produce the latter by means of the application of a strong caustic solution (*e.g.*, the sulph-hydrate of calcium). In order that it may not extend to the conjunctiva or the cheek, and set up considerable inflammation, the surrounding parts should be smeared with oil, the edge of the lids be well everted, and the solution very carefully applied. The calcium is to be washed away with a sponge after four or five minutes. But if a considerable extent of the lid is treated in this manner, a very unsightly baldness (madarosis) will ensue. And hence it is always wiser to endeavour, where a considerable length of the edge of the lid is involved, to perform some operation which shall prove a cure, and yet preserve the eyelashes. Very numerous operations have been proposed for the cure of trichiasis, more especially when combined, as is generally the case, with entropium. Some of these consist in the complete excision of some or all of the eyelashes, others in giving the latter a different direction but not destroying them.

When only a limited number of lashes are misplaced, the following is the best mode of excising them.

If the upper lid is the seat of the disease, Snellen's modification of Desmarres' clamp, Fig. 91, should be used. The lower blade should be inserted beneath the upper eyelid, and the two blades then screwed

* "R. L. O. H. Rep.," iii, 219.

down, so as to compress the eyelid firmly between them and control the bleeding. In the operations for slight, partial trichiasis, it

Fig. 91.

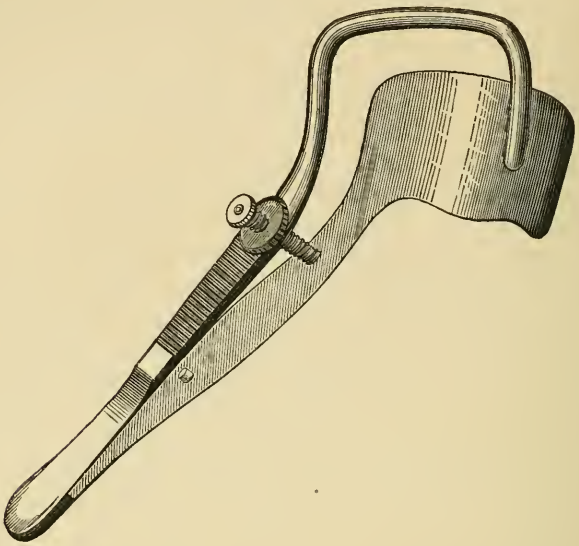

is not so necessary to use this instrument, as for those which are performed when a considerable portion of the lid is implicated. An incision is then to be made with a small scalpel (or with a broad iridectomy knife) at the edge of the lid, just between the misplaced lashes and the openings of the Meibomian ducts, so that the cilia are included in the anterior portion of the incision. The latter is to extend upwards to about 3‴, and its length should include all the distorted lashes. Two incisions are then to be made through the edge of the lid and the skin, these incisions meeting at the centre, so as to form two sides of a triangle, the base of which is formed by the lower incision along the margin of the lid. This triangle, which includes the bulbs of the misplaced lashes, should then be removed. The lateral incisions may also be made with a pair of curved scissors, one point of which is to be inserted at the angles of the longitudinal wound. The lateral edges of the incision are to be brought together with fine sutures.

Herzenstein has devised the following operation for trichiasis, which appears to be especially applicable to the partial forms, where only a few cilia are implicated. It consists in the insertion of a thread, which sets up considerable irritation, and the accompanying suppuration causes the destruction of the follicles of the displaced cilia. Dr. Herzenstein performs the operation in the following manner :—He enters

a needle (*N*, Fig. 92), carrying a fine silken thread, at the edge of the lid between the cilia and the openings of the Meibomian ducts, at *a* (Fig. 92), passes it along subcutaneously in a vertical direction, and brings it out at *b*, slightly above the margin of the lid. The one thread is here drawn through, and the needle again inserted at the same opening, *b*, and passed along subcutaneously, and parallel to the margin of the lid, to the extent of the distorted lashes (to *c*). The thread is here again drawn through, and the needle re-inserted at the same orifice, *c*, and passed down vertically to make its way out at a point (*d*) between the borders of the margin of the lid. The two ends of the thread are then firmly tied, and permitted to cut their way out. Cold compresses should be applied. If numerous, little yellow spots of suppuration appear, the thread should be at once removed. He has also operated successfully in cases where a very considerable extent of the lid was affected.*

Fig. 92.

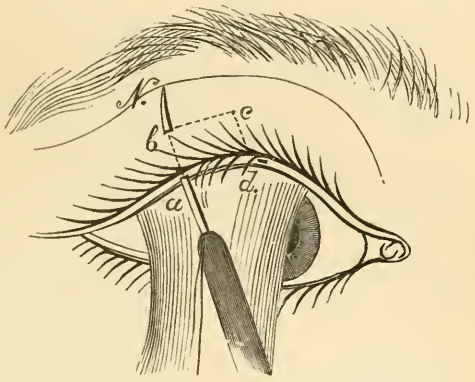

When a considerable portion of the lashes is misplaced, we must remove a long narrow strip of the edge of the lid, which includes these faulty cilia, or even "scalp" the whole lid. Snellen's clamp having been applied, an incision is to be made with a scalpel or cataract knife along the free edge of the lid between the eyelashes and the opening of the Meibomian glands, so as to split the cartilage into two, and sufficiently deep to pass beyond the roots of the lashes. A second incision is then to be made on the external surface of the lid, and carried along, and parallel to, its edge, just behind the row of lashes, so that the two incisions meet, and the strip of skin and integument, containing all the faulty lashes and their roots, is then to be excised. This operation may be partial or extend nearly to the whole length of the lid, according to the extent of the faulty lashes. On completing the excision, the part should be sponged, and the cartilage be closely examined, to discover if any of the hair bulbs (which appear like minute black spots) have escaped, in which case, they should be excised, otherwise the cilia will, of course, grow again. Sutures need not be employed, but a cold wet compress should be applied.

* "A. f. O.," xii, 1, 76.

The above operation is certainly efficacious in curing the trichiasis, but it is unsightly, more especially in the upper lid, and the entire absence of the eyelashes and their protective influence may give rise to a good deal of inflammation, from exposure of the eye to external irritants, such as dust, etc. However, in persons who are careless as to their personal appearance, and are anxious to be quickly and effectually cured of the disease, this operation will be found a very suitable one. But in those cases, in which it is of importance to preserve the eyelashes, and simply to give them a different and better position, so that in place of being turned in, they are well everted, the operation of transplantation is to be much preferred. Indeed, I almost invariably perform it in preference to that of scalping, even although the personal appearance may be of no particular importance. The two following are, I think, the best operations for transplantation.

1. Arlt's modification of Jaesche's operation. As this is a tedious and painful proceeding, the patient should be put under the influence of chloroform. Snellen's clamp having been applied, an incision is to be carried along the free edge of the eyelid, between the cilia and the openings of the Meibomian ducts, and reaching to a depth of about 2‴, care being taken to avoid the punctum. In this way, the free edge of the lid will be split into two portions. The anterior containing the integuments, eyelashes, and their bulbs, etc., and the posterior the cartilage and the efferent ducts of the Meibomian glands. When this incision is completed, a second is to be carried along the outer surface of the lid, about $1\frac{1}{2}$‴ or 2‴ above the eyelashes, and parallel to them. This incision is to extend through the skin and the orbicularis down to the cartilage, and be of sufficient length to pass at each extremity somewhat beyond the first incision. In the next place, a third, semi-circular incision is to be made from one extremity of the second incision to the other (as in Fig. 93), so that a semi-circular portion of skin is included within it. This portion of skin is then to be very carefully dissected away, without any injury of the orbicularis. The size of the flap must vary with the amount of eversion which we desire; in simple cases of trichiasis, without any entropium, it need be but small. When this has been done, the edges of the incisions should be brought together by fine sutures. The effect of this shortening of the skin of the eyelid will be to roll out the edge

Fig. 93.

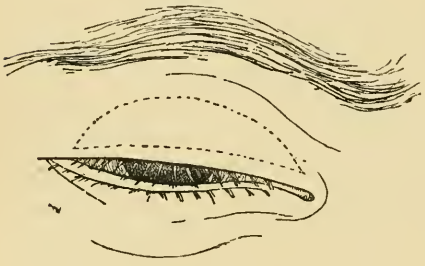

of the lid and the eyelashes, which can be the more effectually done as the edge of the lid has been split into two, and the external portion is thus greatly liberated.

I have found this operation generally very successful, but it must be confessed that it does occasionally fail in two ways. 1st. The change in the position of the faulty cilia, which are situated near the extremities of the incision, may not be sufficient. 2nd. The nutrition of the narrow bridge containing the eyelashes may be here and there impaired, leading to a partial slough and loss of the lashes at this point. To obviate these ill results, and yet to preserve all the advantages of this method of operating, Von Graefe has devised the following modification :*—

2. Von Graefe's operation (vide Fig. 94). He makes two vertical incisions 4‴ in length, which pass upwards from the anterior edge of the lid through the skin and orbicularis, and form the lateral margins of the portion of the lid which is to be transplanted. Hence, if the trichiasis is complete, and extends to the whole length of the eyelid, the external vertical incision will be at the outer commissure, the inner at the upper lachrymal punctum (which should be preserved intact). In the next place, an incision is to be carried along the free edge of the lid between the cilia and the Meibomian ducts, just as in Arlt's operation. The lashes can now be well everted, and in order to assist still further in maintaining this position, an oval portion of skin may be excised (vide Fig. 94), or this may be effected by the application of two or three vertical sutures, without excision.

Fig. 94.

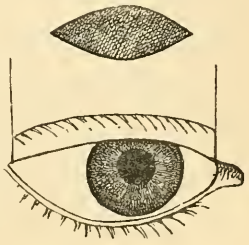

13.—ENTROPIUM.

In this condition, the free edge of the eyelid is more or less inverted, so that the eyelashes are turned in and sweep against the eyeball. The entropium may be either partial or complete, and be limited to one eyelid, or affect both. We must distinguish two principal forms of the disease. 1. The spasmodic or acute entropium, and 2, the chronic entropium, which is caused by inflammatory changes in the conjunctiva and cartilage.

The spasmodic entropium is acute in character, and occurs chiefly in elderly persons (hence it is often also termed senile entropium), the skin of whose eyelids is very lax, and who have perhaps had their eyes bandaged up for some length of time ; thus, it is often observed if a firm

* "A. f. O.," x, 2, 226.

bandage or pad has been worn, either on account of some operation on the eye, or for some inflammatory affection. Indeed the photophobia and long continued spasm of the lid attendant upon the latter, may give rise to entropium by the spasmodic contraction of the orbicularis, which causes the edge of the lid to roll in, more especially if the skin of the lid is very abundant and lax. In this form of spasmodic entropium, we observe that the lashes have become tucked in towards the eyeball, and are quite hidden from view, the margin of the lid being rolled in upon itself, and presenting its smooth, rounded edge upwards. On gently drawing back the eyelid into its normal position, we notice that it looks, perhaps, quite healthy, or only slightly swollen and red; but its edge is not sore or notched, and the eyelashes are perfectly regular and well developed, being neither distorted nor dwarfed. The lid can be temporarily retained in its natural position, but very soon it rolls in again, especially if the patient should wink. This form of entropium is particularly met with in the lower eyelid, but may also affect the upper.

In the chronic entropium the appearances are very different, for on everting the edge of the lid, we generally find it inflamed, excoriated, contracted, and notched. The eyelashes are sparse and irregular in their growth, showing the characters of distichiasis or trichiasis, and being dwarfed and stunted. Instead of the eyelid presenting folds of super-abundant, lax skin, it often looks rather shortened and tightly stretched, the cartilage being contracted and incurved; and on eversion of the eyelid (which is frequently performed with difficulty), the conjunctiva shows the remains of inflammatory, and often deeply marked cicatricial changes. The length of the palpebral opening (from angle to angle) is frequently considerably diminished in size, so that the eye looks smaller and sunken. The induration and contraction of the cartilage are often very marked, and it may be shortened horizontally or transversely. These changes in the cartilage are especially observed as a consequence of severe and long standing granular ophthalmia. This form of entropium is generally caused by various inflammations of the conjunctiva and the edge of the lid, more especially if there is much photophobia, and, in consequence of this, severe blepharospasm. Long persistent distichiasis or trichiasis may also, as has been already stated, give rise to a certain degree of entropium. The latter may likewise occur when the eyeball is atrophied and shrunken, so that it no longer fills out the orbit and sustains the lids, which consequently show a tendency to become rolled in. Entropium may also be of traumatic origin. Thus, burns, scalds, injuries from lime, or wounds of the inner surface of the eyelid, may produce it, by causing a destruction and cicatricial contraction of the conjunctival and subconjunctival tissue. In such cases, symblepharon often co-exists.

The presence of entropium generally soon sets up great irritation of the eye, producing photophobia, lachrymation, and blepharospasm. Subsequently, superficial corneitis supervenes, and a more or less dense pannus may be formed, leading to still graver complications if the inversion of the lids is not cured. In some instances, however, even a tolerably severe degree of entropium may exist for some time without setting up much irritation.

The treatment of entropium must vary according to the nature and extent of the disease. In the slight and recent cases of spasmodic or senile entropium (especially of the lower lid), it may suffice to replace the lid in its normal position, and then to paint its external surface with collodion.* This will dry at once, and prevent the lid from again inverting. The collodion must be renewed every two or three days. But if the entropium is too considerable in degree for this mode of treatment, a narrow horizontal fold of skin, running parallel and close to the edge of the lid, and a portion of orbicularis should be removed. A fold of skin of the requisite size having been caught up between the branches of the entropium forceps, is to be excised by a few rapid snips of the scissors, and then a portion of the orbicularis should, if necessary, be also removed. Before beginning the excision of the skin, we should see what effect the pinching up of the fold between the forceps has upon the position of the lid. If it does not evert the latter sufficiently, a larger fold must be seized; if its effect is too great, the size of the fold must be diminished. As a rule, no sutures will be required, but a light pad and bandage should be applied, when the bleeding has ceased. It has been also recommended to excise one or more small oval portions of integument in a vertical direction, the edges being united by fine sutures. The removal of a horizontal fold of skin is, however, in my experience, to be preferred.

As the palpebral aperture is frequently considerably shortened in chronic cases of entropium, so that the eye looks very small, much benefit is often derived from slitting up the outer canthus (cantho-plasty). Indeed, in some cases this proceeding may suffice to cure the inversion of the lids; or this operation should be combined with one of those for entropium. The outer canthus may be divided with a bistoury or with a pair of strong scissors. In the former case, a director should be introduced beneath the outer commissure, and the latter divided upon it with the bistoury to the requisite extent, the incision running in a horizontal direction and being in the prolongation of the palpebral aperture. If scissors are employed, one blade should be passed behind the outer canthus, the other in front, and the commissure be divided with one sharp cut. An assistant is then to stretch the incision in a vertical direction, so as to cause it to gape. The conjunctival surface

* Vide Mr. Bowman's paper, "Braithwaite's Retrospect," 1851.

of the incision is to be united at one or more points to the skin by a fine suture, in order to prevent union taking place. One suture should be applied at the upper angle, another at the lower, and, if advisable, a third may be inserted at the outer extremity of the wound. This operation of canthoplasty is often also indicated in cases of anchyloblepharon or symblepharon.

Fig. 95.

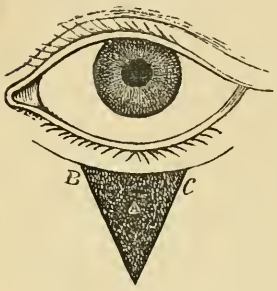

Fig. 96.

Von Graefe* strongly recommends the following operation for spasmodic entropium. He makes a horizontal incision (Fig. 95) through the skin, parallel to the edge of the lower lid and about $1\frac{1}{2}'''$ from its anterior margin, the extremities of the incision running up to within $1'''$ or $2'''$ of a vertical line passing through each commissure. He then removes a triangular portion of skin (A), the two lateral flaps, B and C, are somewhat dissected up and united by two or three fine horizontal sutures. The horizontal wound is left to cicatrize. He varies the height and breadth of the triangle, according to the degree of relaxation of this portion of the lid. The height is of little consequence, but the breadth may have to vary from $3'''$ to $5'''$. If we desire to gain a still more considerable effect, the vertical incisions may be made of the shape represented in Fig. 96.

If, together with a spasmodic entropium of the upper lid, the cartilage is contracted, Von Graefe, after having made the horizontal incision and removed a triangular portion of skin (Fig. 97), carries a horizontal incision through the fibres of the orbicularis muscle close to the edge of the lid, and pushes them up so as to expose the external surface of the cartilage. A triangular portion of the latter (B) is then to be removed, the position of the triangle being the reverse of that in the skin, so that the base of the triangle (varying in extent from $2\frac{1}{2}'''$ to $3'''$) reaches close to the upper edge of the cartilage, and its apex lies close to the margin of the lid. The whole thickness of the cartilage should be removed, so that only the conjunctiva remains. The middle suture ($\beta\ \beta$) should pass through the edges of the incision in the cartilage. It is generally necessary to combine

Fig. 97.

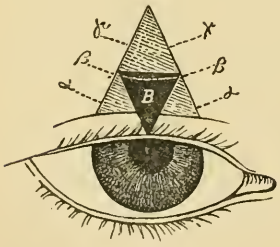

* "A. f. O.," x, 2, 222.

canthoplasty with this operation, as it may otherwise diminish the size of the palpebral aperture too much.

In those cases of entropium in which the tarsal cartilage is unaffected and has retained its normal curvature, the operations of transplantation of Arlt or Von Graefe (page 697), will be found very serviceable. But if the entropium is considerable, a larger portion of skin should be removed (together with some of the fibres of the orbicularis) than in the case of simple trichiasis.

The following operation of Pagenstecher* will also be found an exceedingly good one. He commences by dividing the external commissure of the lids to such an extent, that the wound in the conjunctiva equals from 2‴ to 3‴, and that in the skin from 3‴ to 4‴. By moderately stretching the edges of the incision downwards, the horizontal wound is changed into a vertical one, and the opposed surfaces of skin and conjunctiva are then to be united by sutures. By this proceeding the palpebral aperture is enlarged, a slight ectropium is produced, and the action of the orbicularis is diminished by the interposition of the conjunctiva between its fibres. The lid being everted, he next inserts several ligatures, more especially at those points where the cilia have a faulty position. For this purpose, the lax skin of the lid and the fibres of the orbicularis are to be lifted up into a horizontal fold with a pair of forceps, and a curved needle (armed with a strong, waxed thread) passed through the base of the fold, quite close to the external surface of the tarsal cartilage. The point of the needle is then to be brought out at the edge of the lid, slightly to the outer side of the apertures of the Meibomian ducts. The ligature is to be firmly tied and allowed to suppurate out, which generally occurs in from 6 to 10 days. As a rule, two or three ligatures will suffice to produce a considerable eversion of the margin of the lid. The effect of each suture can be calculated according to the width of the fold of skin which is lifted up. The advantages which Pagenstecher claims for this operation are:—1. That the pressure which the lid exercises upon the eyeball is diminished by the widening of the palpebral aperture; 2, the prevention of the cilia coming into contact with the cornea; 3, the eyelashes are preserved and their normal growth promoted. The little scars left by the sutures very soon disappear, without leaving any trace behind them.† Cold water dressing should be employed in order to alleviate the inflammation, which is sometimes severe, and a bandage should be applied so as to keep the parts quiet. In some cases, the sutures may be removed before they slough out.

Snellen† recommends a ligature to be inserted in the following

* "Klinische Beobachtungen," 1861; also "Compte-Rendu du Congrès d'Ophthalmologie," 1862, p. 241.

† "Compte-Rendu du Congrès d'Ophthalmologie," 1862, p. 236.

manner:—The lid being very much everted, he passes two needles (attached to each end of a silken thread) from within outwards through the whole thickness of the lid, so that the one needle pierces the upper margin of the cartilage, and the other passes a little above this edge. The needles are then re-introduced at the points of exit, passed down to the anterior surface of the cartilage and along it, beneath the orbicularis, towards the edge of the eyelid, being brought out just in front of the lashes, close to each other, at about a distance of two millimètres. The upper edge of the tarsal cartilage is thus enclosed in a sling, and in tying the threads near the ciliary border, we evert the edge of the lid and draw it upwards. The thread may be removed about the third day, care being taken that no portion of it remains behind, otherwise sloughing may occur. It must be admitted, however, that ligatures alone, often prove but of slight, or only temporary benefit.

When the entropium is paired with contraction and incurvation of the tarsal cartilage, operations which simply act upon the position of the lid by the removal of a portion of skin, and perhaps some of the fibres of the orbicularis, no longer suffice; but we must then also remove a portion of the cartilage, so that the cicatrization may cause a contraction of the outer portion of the cartilage, and thus counteract the incurvation.

For this purpose Mr. Streatfeild* devised his operation of "grooving the cartilage," which answers very well when the latter is simply incurved without being contracted. He performs the operation thus:—"The lid is held with Desmarres' forceps, the flat blade passed under the lid, and the ring fixed upon the skin, so as to make it tense and expose the edge of the lid. An incision with a scalpel is made of the desired length, just through the skin, along the palpebral margin, at a distance of a line or less, so as to expose but not to divide the roots of the lashes; and then just beyond them the incision is continued down to the cartilage (the extremities of this wound are inclined towards the edge of the lid); a second incision, farther from the palpebral margin, is made at once down to the cartilage in a similar direction to the first; and at a distance of a line or more, and joining it at both extremities; these two incisions are then continued deeply into the cartilage in an oblique direction towards each other. With a pair of forceps the strip to be excised is seized and detached with the scalpel."

I have succeeded in curing severe cases of entropium with marked contraction and incurvation of the cartilage by a combination of Arlt and Streatfeild's method. The first steps of the operation are identical with those of Arlt's (p. 696); but after the removal of the oval portion of skin, I make a longitudinal incision through the fibres of the orbicularis down to the cartilage. The latter being well exposed, I make

* "R. L. O. H. Rep.," i, 121.

two longitudinal incisions (inclining towards each other) in it, nearly down to its inner surface. The incisions should slope so much that they meet near the posterior surface of the cartilage, and thus include a wedge-shaped strip of the latter, the base of the wedge being turned towards the skin, and the apex towards the conjunctiva. This strip of cartilage is then to be excised with the scalpel. The size of this strip will depend upon the degree and extent of the incurvation and contraction of the cartilage. The edges of the incision in the skin should be neatly brought together by sutures, which are to be passed somewhat deeply, so as to include a portion of the orbicularis, but need not be passed through the cartilage.

14.—ECTROPIUM.

In this condition, the eyelid is more or less everted and its conjunctival surface exposed. The degree of ectropium varies greatly, being in some cases so slight that the edge of the lid is but a very little turned out and drooping, whereas in others, the whole eyelid is everted and its lining membrane apparent.

Slight degrees of ectropium are often seen in elderly people, more especially if they are affected with a chronic inflammation and thickening of the conjunctiva and edge of the lids. This, together with a certain degree of atrophy and relaxation of the orbicularis, causes the edge of the lid (especially the lower) to become somewhat everted and drooping, so that its margin is no longer applied to the eyeball, but sinks away from it. In consequence of this slight eversion, the punctum lacrymale is no longer turned in towards the eyeball, but is erect or everted. The tears, instead of being carried off through the canaliculus, collect at the inner corner of the eye, so that the eye appears to be always moist and swimming in tears; the latter flow over the edge of the lid, and thus maintain and increase any existing excoriation or inflammation of its margin. Severe inflammations of the conjunctiva (especially purulent and granular ophthalmia) are frequently the cause of ectropium, particularly if they are accompanied by great swelling and hypertrophy of the conjunctiva, and by such considerable chemosis, that the latter protrudes perhaps between the lids. For if the œdematous infiltration and swelling of the lid subside, but those of the conjunctiva continue, the lid is apt to become everted by the action of the orbicularis; being assisted in this by the hypertrophy of the conjunctiva, to which the external portion of the lid can offer no counterpoise, and also by the great degree of chemosis. If such an eversion occurs, and is not at once replaced, the compression of the cartilage and of the upper portion of the lid soon produce great strangulation and a serous and

hæmorrhagic infiltration of the lid, which greatly increase the swelling. Hence the tumour, as Mackenzie remarks, is occasioned in a great measure by strangulation, like the swelling in paraphimosis. We not unfrequently observe such cases of ectropium in children suffering from purulent ophthalmia, in whom the lid has become accidentally everted during the application of local remedies, etc.; and instead of having been at once replaced, some time, perhaps several days, has elapsed before medical aid was sought. The strangulation is greatly increased in children by their violent fits of crying and struggling. In chronic cases of purulent and granular ophthalmia, the conjunctiva is not only swollen and hypertrophied, but the cartilage becomes relaxed and stretched, so that it no longer maintains the proper curvature and position of the lid, but assists materially in the production of the ectropium. The lid becomes at the same time elongated; indeed, ectropium seldom exists for any length of time without causing a certain, often considerable, increase in the length of the lid.

Paralysis of the portio dura also causes ectropium (especially of the lower lid) and lagophthalmos. Intra-orbital tumours, abscess of the orbit, etc., often produce eversion of the lid, on account of the exophthalmos to which they give rise.

But the most frequent cause of ectropium is found in the presence of cicatrices, excoriations, etc., in the vicinity of the edges of the lids, for by their contraction, during cicatrization, the margin of the lid becomes more or less everted. Thus, in long-continued excoriation or eczematous inflammation of the edge of the lid and its vicinity, we find that a contraction of the skin takes place, and the lid becomes somewhat everted. This can often be observed in cases of inflammation of the conjunctiva and cornea, accompanied by severe lachrymation. The edge of the lid becomes swollen and inflamed, its margin rounded, the eyelashes stretched and displaced, and the punctum everted and perhaps obliterated. Various injuries to the external surface of the lids or the integuments in their vicinity, such as burns, scalds, wounds, etc., which produce loss of substance, may give rise by their cicatrization to more or less considerable ectropium.

Caries of the orbit, more especially at its outer and lower margin, is a fruitful source of very severe and obstinate forms of ectropium; for the caries is frequently accompanied by the destruction of a considerable portion of the substance of the lid and of the cartilage, which may be implicated in the cicatrix and adherent to the bone. Thus, we sometimes find the smooth surface of the lid drawn at one point into a small funnel-shaped aperture, which extends deeply down as far as the bone, to which its apex is adherent. Abscess of the frontal sinus, which perforates by a small opening through the upper portion of the lid, may be followed by an adhesion of the lid to the

aperture in the bone, and a considerable degree of ectropium. In cases of ectropium of the upper lid, due to caries, we may often notice (as Mackenzie points out) the vicarious action of the lower lid, which becomes somewhat raised, so as to accommodate itself to the deficiency of the upper.

Ectropium generally soon produces a chronic inflammation of the conjunctiva and cornea, on account of the exposure of the eye to the irritating influences of the atmosphere, and of foreign substances, such as dust, etc. After a time, the conjunctiva becomes thickened, swollen, and desiccated, its epithelial layer hypertrophied and roughened, and at length xerophthalmia may be produced, the conjunctiva and cartilage undergoing atrophic changes. The cornea becomes inflamed, pannus supervenes, or deep ulcers are formed, which may lead to extensive perforation and all its dangerous consequences, such as staphyloma, or even atrophy of the eyeball. We often find, however, that the effect of the ectropium upon the eye is but inconsiderable, and is not followed by any marked inflammation of the conjunctiva or cornea. This is due to the fact, that the eyeball is rolled upwards, and is thus protected by the upper lid (the wrinkling and contraction of the brow often assisting in this), which thus guards it against external irritants. Hence, we sometimes find that patients apply to us for treatment of the ectropium far less on account of the inflammatory or other affections, than for the sake of having their personal appearance improved, which is rendered extremely unsightly from the exposure of the red, fleshy conjunctiva. In consequence of the ectropium and the malposition of the puncta, the tears cannot enter the latter, but flow over the cheek, and from the lachrymal sac being in a constant state of emptiness and non-use, it may in time shrink and become permanently diminished in size (Weber),* its walls being thinned and atrophied.

In the eversion consequent upon inflammation and hypertrophy of the conjunctiva, the lid should be *at once* replaced, if we see the case sufficiently early, and should be retained in its proper position by a compress bandage. Directions should also be given to the attendants in cases of purulent ophthalmia, etc., more especially in children, immediately to replace the lid if it becomes everted during the application of topical remedies. If this treatment does not suffice, and there is great hypertrophy and proliferation of the conjunctiva, the surface of the latter should be touched with mitigated nitrate of silver, the effect of which is, however, to be at once neutralized with salt and water. The conjunctiva is then to be freely scarified, which will generally cause a considerable diminution in the size of the lid. In some cases it is, however, necessary to excise a more or less considerable portion of

* "A. f. O.," viii, 1, 95.

the swollen and hypertrophied conjunctiva. If these remedies fail, we must have recourse to operative interference; but I may mention that the operations proposed and practised at different times are far too numerous to be entered upon here, and I shall consequently confine myself to a description of those which have been found to be the most useful and successful. I must state, however, that no very definite or precise rules can be laid down as to the exact method of operating, for we constantly meet with cases of ectropium so variable in degree and extent, that we are obliged to modify and alter the mode of operating, in order to adapt it to the exigencies of each individual case.

In the above form of ectropium, as well as in the senile, the best treatment is the diminution of the palpebral aperture by the operation of tarsoraphia, more especially if there is a certain degree of lengthening of the eyelid. Before proceeding to operate, the surgeon should take the outer edges of the lids between his forefinger and thumb, and draw them somewhat out towards the external canthus, and then approximate them towards each other at this point, in order that he may be able accurately to estimate the extent to which the palpebral aperture should be narrowed. The effect which this narrowing has upon the edge of the everted lid should likewise be noted, as also the fact whether the lid has to be a little raised or depressed, in order to bring it into a proper position. If the puncta are erect or everted, they should be slit up, so as to facilitate the entrance of the tears into the sac.

Tarsoraphia, which was first devised by Walther, is to be performed as follows:—The operator having inserted a horn or ivory spatula between the lids at the outer canthus, makes an incision through the skin and connective tissue parallel to the edge of the upper lid, and about three-quarters of a line from its margin. This incision is to be commenced at the outer canthus, and carried along the edge of the lid to a distance of from $1\frac{1}{2}'''$ to $3'''$; it is then to be carried vertically down to, and through, the anterior edge of the lid. This portion of the lid, including its cilia, is then to be completely excised from this point to the outer canthus, care being taken that the hair follicles are not divided obliquely, but entirely removed, otherwise, they will grow again. The same proceeding is then to be repeated in the lower lid, so that the two raw surfaces of the edges of the lids can be accurately applied to each other, and united by two or three sutures. In order still more to facilitate the union, and to give the lashes a more perfect and favourable inclination, Von Graefe* has modified the operation in the following manner. He carries on horizontally the inner portion of the vertical incision (which has been made perpendicularly through the edge of the lid) to the extent of about $1'''$ or $1\frac{1}{2}'''$ towards the nose, along the pos-

* "A. f. O.," iv, 2, 201.

terior border of the margin of the lid, and pares the latter by removing a small slip of conjunctiva. This is to be done in each lid, the cilia being of course left at the outer portion of this part of the lid. In those cases in which there is a considerable elongation of the edge of the lower lid, as well as of its cartilage, an unsightly pucker or fold is apt to be produced by the sutures at the outer canthus. To obviate this, a triangular portion of the substance of the lower lid should be excised near the outer commissure, the base of the triangle being turned towards the edge of the lid. The operation of tarsoraphia will also be found very useful in lagophthalmos due to paralysis of the portio dura, as well as in that which is sometimes noticed after the old squint operation.

For the senile or spastic forms of ectropium, tarsoraphia will be found greatly preferable to the operation of Adams, which consists in the removal of a triangular, V-shaped piece from the whole thickness of the lid, the base of the triangle being turned towards the margin of the latter, and the apex towards the cheek. The edges of the wound are then to be brought accurately together by sutures, one of which should be inserted close to the margin of the tarsus, so that the lips of the wound may be brought very closely together at this point. The chief disadvantage of this operation is, that when it is done near the central part of the lid, it shortens the edge of the latter without elevating it at the outer canthus, hence it is closely pressed against the eyeball, which may, moreover, be somewhat irritated by the pucker or fold to which the cicatrix gives rise. If this operation is adopted, it should, therefore, be performed close to the outer canthus, as this tends to elevate the edge of the lid at this point.

We have now to turn our attention to those cases in which a partial or complete ectropium is due to a cicatrix, which is situated at a short distance from the edge of the lid, and causes eversion of the latter by traction.

Very numerous operations have been devised to remedy this defect, of which I shall only mention those of Wharton Jones (sometimes also termed Samson's operation), Dieffenbach, and Von Graefe, for they are, I think, the most generally useful and successful.

Mr. Wharton Jones's operation is to be performed in the following manner :*—" The eyelid is set free by incisions made in such a way, that when the eyelid is brought back into its natural position, the gap which is left may be closed by bringing its edges together by suture, and thus obtaining immediate union. Unlike the Celsian operation, the narrower the cicatrice the more secure the result. The flap of skin embraced by the incisions is not separated from the subjacent parts; but advantage

* Vide Mr. Wharton Jones, " Treatise on Ophthalmic Medicine and Surgery," p. 627.

being taken of the looseness of the subcutaneous cellular tissue, the flap is pressed downwards,* and thus the eyelid is set free. The success of this operation depends very much on the looseness of the cellular tissue. For some days before the operation, therefore, the skin should be moved up and down, in order to render the cellular tissue more yielding."

Fig. 98.

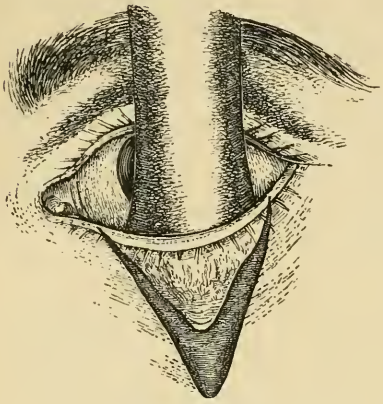

After Stellwag.

Fig. 99.

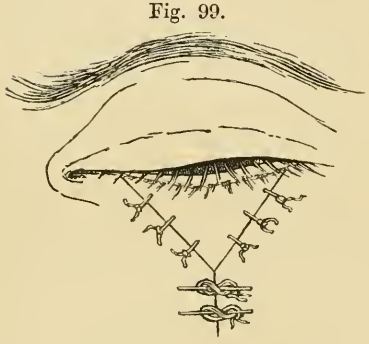

After Stellwag.

In Figs. 98 and 99, the method of performing this operation upon the lower eyelid is illustrated. A horn spatula having been inserted beneath the lower lid, so as to render this tense, two straight incisions are to be made from the edge of the lid, in such a manner that they converge towards each other, and meet at such a distance below the lid, that the cicatrix is completely included within the triangular flap thus formed. The flap is then to be pressed upwards, so as to bring the edge of the lid into its normal position, and all the opposing bridles of cellular tissue are to be divided, without however dissecting off the flap from the subjacent parts, except perhaps very slightly at the periphery. The edges of the wound existing below the apex of the flap are next to be closely united by two common or twisted sutures (Fig. 99), and then the two edges of the flap are to be accurately united by sutures at each side to the opposite margin of the wound. If it be necessary somewhat to shorten the edge of the lid, tarsoraphia may be united with this operation. The above method of operating is especially indicated in those cases of ectropium, in which the shape and form of the lid are but little changed, its margin being chiefly elongated.

Dieffenbach devised the following operation for eversion of the

* Mr. Jones is here describing the method in which the operation is to be performed on the upper lid; in the lower lid, of course, the flap would be pressed upwards, and the natural position of the edge of the lid would be thus regained.

lower lid, due to a cicatrix situated at a short distance from it. The cicatrix is to be included within a triangular flap, the base of which is to be turned towards the margin of the lid, the apex to the cheek. This triangular portion is then to be removed, and the incision, which represents the base of the triangle, is to be prolonged horizontally on each side to a short distance, in order to facilitate the approximation of the lateral edges of the triangle, which should be raised from the subjacent parts by a few incisions with the scalpel. The two lateral incisions of the triangle are to be united by fine sutures, and then the horizontal incision, on each side of the base of the triangle, is also to be brought together by sutures.

Von Graefe has lately introduced the following method of operating for the severer cases of ectropium of the lower lid, more especially those which are the result of chronic blepharo-adenitis. He makes a horizontal incision just behind the edge of the lid, in the intermarginal space, from the lower punctum to the outer canthus. From the extremities of this line (Fig. 100) two incisions are then to descend vertically down the cheek, for a distance of from 8‴ to 10‴. The square flap *A* is next to be dissected up, and, if necessary, somewhat raised subcutaneously beyond the lower extremities of the vertical incisions. The flap is then to be seized at its upper edge by two pairs of broad forceps, and forcibly stretched upwards, and maintained in this position by sutures, which are to be applied first at the vertical incisions, commencing at their lower extremity. The two upper angles, which now project considerably above the upper margin of the opposite edge of the wound, should next be sufficiently bevelled off, and this is best done by making a somewhat bent incision (*B B*) whose acute angle *C* is then to be drawn up and united to *D*. The effect of this bent incision *B B* is twofold, viz., it shortens the edge of the lid, and elevates the flap. The closer to the edge of the lid that the point *C* is brought, the less does it elevate the flap, but the more does it shorten the edge of the lid. Whereas, the closer the point *C* lies to the vertical incision, the more is the flap elevated, and the less is the edge of the lid shortened. The more exact measurements as to the size of the incisions, etc., can only be determined during the performance of the operation, more especially the adaptation of the flap in its new position, as we must shape and modify them according to circumstances. Indeed this holds good in all plastic operations. Finally, the horizontal wound is to be closed with sutures, and in such a manner that the latter include broad portions of skin, but only narrow ones of conjunctiva; as this is more favourable for the

Fig. 100.

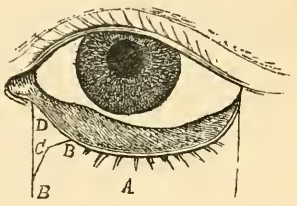

subsequent fastening of the flap, for the different threads of the sutures are to be tolerably tightly fixed to the forehead. A firm compress bandage is to be applied during the first twenty-four hours. Von Graefe has found this operation much more successful than that of Dieffenbach.*

In those instances of ectropium in which extensive cicatrices involve a considerable portion, or even the whole thickness of the lid, as often occurs in caries or necrosis of the bone, or in cases of cancer, etc., of the lids, it may be necessary completely to excise the affected portion, and to fill up the wound by transplanting a flap taken from the adjacent integuments. This operation of making a new eyelid is termed *blepharoplasty*, and very numerous modifications of it have been from time to time devised; Dieffenbach and Fricke having been amongst the first to practise it. The flap is sometimes taken from the temple and forehead, in other cases, from the cheek or side of the nose, according to the size and position of the cicatrix or growth which is to be excised. The flap has even been formed from the back of the hand.† I shall, however, only describe a few of the more important and most generally successful modes of operating, which will suffice to illustrate the principles that should guide us, but the details of which must be modified and altered according to the exigencies of special cases. There are, however, a few points which apply to all these cases of blepharoplasty, and attention to which, greatly increases the chance of a favourable result. Thus, the size of the flap should always be larger than the wound into which it is to be fitted, in order that this may be completely filled up, and its edges and those of the flap be readily united without any undue stretching; a certain degree of latitude being also allowed for a little shrinking or contraction of the flap. Care must likewise be taken that the surrounding skin is not too much stretched, when the flap is fastened in its new position; hence, if any undue tension exists, a few superficial incisions should be made in the skin near the base of the flap, so as somewhat to liberate it. The base of the flap should always be made sufficiently broad to maintain the vitality of the transplanted portion, which is otherwise prone to slough. This vitality may, however, be also impaired by the unhealthy condition of the skin from which the flap is taken; by its being too firmly pressed against the bone by a very tight compress bandage; or, on the other hand, by its not being kept in sufficiently close contact. The prospect of the success of the operation is always best, when the integuments from which the flap is taken are quite healthy, and are free from all cicatricial or inflammatory changes.

* "A. f. O.," x, 2, 229. † Vide Wharton Jones, loc. cit., p. 638.

In Fig. 101 is illustrated the method of excising a large cicatrix of the upper lid, which has produced extensive ectropium. The cicatrix

Fig. 101.

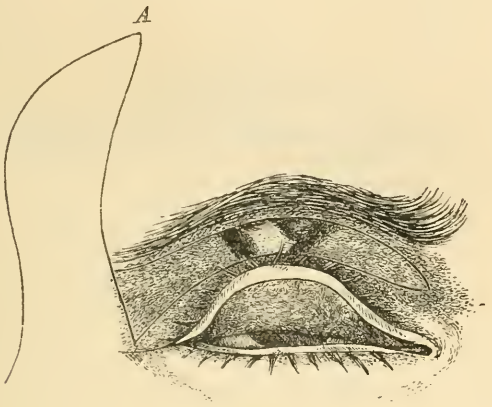

After Stellwag.

is to be included within two horizontal incisions, which converge towards each other at the inner (nasal) side, but diverge and descend somewhat at the temple. The diseased portion of the lid is then to be carefully dissected away from the subjacent tissue, so as thoroughly to liberate the lid, which is then to be drawn into its normal position. The extent and shape of the wound which is thus made, are to be estimated with as much accuracy as possible, and a corresponding flap (*A*, Fig. 101) is then to be dissected from the skin of the temple. For reasons stated above, the size of this flap should, however, be somewhat larger than the wound into which it is to be fitted. When the flap has been carefully dissected off, so that only its base remains standing, it is to be twisted somewhat upon itself, fitted into the wound, and carefully fastened there by numerous fine sutures; the incisions in the temple being closed in the same way.

In Fig. 102 is shown the method of fastening a flap which has been dissected out from the temple into a wound in the lower eyelid.

Dieffenbach made three incisions, which formed an equilateral triangle, and included the cicatrix; the one incision being carried parallel to, and somewhat, below the margin of the lower lid, Fig. 103. He then excised the portion included within the triangle, and next dissected an oblong flap of skin (Fig. 103 *A*) from the parts immediately adjacent to the wound, and shifted it laterally into the latter, retaining it in this position by sutures (Fig. 104).

Fig. 102.

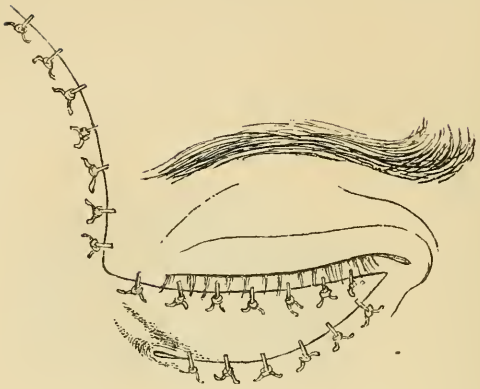

After Stellwag.

Fig. 103.

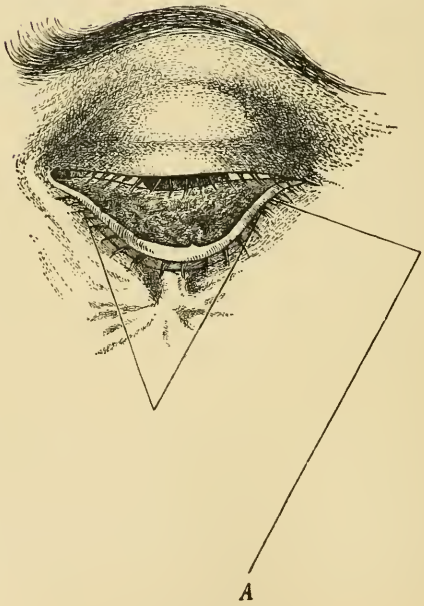

After Stellwag.

Fig. 104.

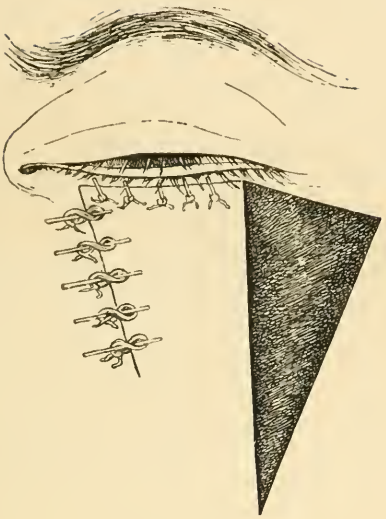

After Stellwag.

If the margin of the lid is implicated in the disease, it must also be included in the part which is excised; and the upper, horizontal incision of the new flap should then be made somewhat longer, so that this portion of the flap may form the edge of the lid.

Knapp has described* an ingenious modification of blepharoplasty, performed by him in a case in which a cancerous tumour occupied the inner two-thirds of the lower lid (including its edge), extending somewhat beyond the inner angle of the eye, and involving the skin of the nose to an extent of from 2‴ to 3‴. As the flap is apt to contract when it is made with its base downwards, and may thus give rise to ectropium, Dr. Knapp, at the suggestion of Dr. Fritz Pagenstecher, operated in the following manner:—He included the tumour between straight incisions (which were carried well into the healthy tissue). After the morbid growth had been thoroughly removed, he prolonged the internal horizontal incisions towards the nose, and thus prepared a square, horizontal flap at this point. He then made (in the prolongation of the palpebral aperture) an incision from the outer canthus slightly upwards into the skin of the temple; and next a second incision, which was at first a straight prolongation of the lower edge of the wound, but was then somewhat arched downwards on to the cheek, the concavity looking downwards. The long flap thus formed, and which increased considerably in width towards its base, was then dis-

* "A. f. O.," xiii, 1, 183.

sected off from the subjacent tissue, drawn forwards, and its inner angle united by twisted sutures to the vertical edge of the nasal flap. Both flaps, though rather tightly stretched, entirely covered the wound, and formed a very successful artificial lid. The external fourth of the latter, which had remained standing, now formed the most internal portion. The edges of the wound were then carefully united by very numerous sutures, and a compress bandage applied for 48 hours. Perfect union resulted, and the patient was discharged 14 days afterwards, completely cured. The palpebral aperture was slightly (about 2‴) diminished in length, but could be easily and perfectly opened and closed by the action of the upper lid. The lower lid was closely applied to the globe, and Knapp states that this was one of the most successful cases of blepharoplasty with which he has met. In cases in which we unite the opposite edges of two flaps, care must always be taken to allow a sufficient amount of skin, so as to permit of a certain degree of contraction and gaping of the edges of the flaps, in case that they should not unite by first intention, which is not unlikely to occur.

In those cases, in which cicatrices or cancerous growths implicate the inner or outer canthus, and to a small extent the opposite edges of the two lids, the flap which is to cover the wound may be taken from the skin of the nose or the temple, according to the situation of the disease. In such instances, the following operation, devised by Hasner, will be found useful :—If the morbid growth be situated at the outer canthus, and implicates to a certain extent the edges of the upper and lower lid, the tumour is to be included above and below between two elliptical incisions, which should be laid well in the healthy integument. The line of junction of these two incisions should then be slightly prolonged outwards, and a sufficiently large flap be excised from the temple. The upper extremity of this flap is to be bifurcated, so as to fit easily into the wound made in the edges of the lid at the outer canthus. If the disease is situated at the inner canthus, the flap should be taken from the side of the nose.

If the cicatricial adhesions are narrow and not very firm, it may suffice to divide them subcutaneously, and thus to liberate the lid, and allow it to assume its normal position.

15.—INJURIES, WOUNDS, ETC., OF THE EYELIDS.

Ecchymosis of the eyelids is of frequent occurrence, being chiefly the consequence of a severe blow or fall upon the eye, and is hence often met with in pugilistic encounters. It is due to a sanguineous effusion into the areolar tissue of the eyelids, which gives rise to a dark, livid discoloration, commonly termed a "black-eye." As a rule, it occurs within a few hours after the accident; it may, however, come on at

once, the discoloration extending from the eyelids to the neighbouring parts. These facts distinguish this form of ecchymosis from that which is due to a counter-fracture of the orbit, for then the reverse obtains, the discoloration shows itself after a much longer interval, and gradually extends to the eyelids. Together with the effusion of blood into the areolar tissue of the lids, there is often much serous infiltration and swelling of the latter and of the surrounding parts, the lids being perhaps so swollen that the eye is firmly closed. The discoloration is at first dark and livid, but gradually undergoes various changes of tint, turning bluish-red, green, yellow, etc. A black eye generally disappears in two or three weeks' time, but the absorption of blood may be accelerated by various local remedies. Directly after the injury, compresses of lint dipped in ice-cold water should be applied, and very frequently changed, being retained in position by a firm bandage. This application of a cold compress tends greatly to limit the effusion of blood. The absorption of the latter is subsequently much hastened by the continuous application of a firm bandage, together with which an evaporating lotion should be employed. Of the two, the bandage will, however, be found to render the greater service in accelerating the absorption. The tincture of arnica has long enjoyed a great and special reputation for curing black eyes. It should be employed as a lotion (Tr. Arnicæ. Mont. ʒij, ad. Aq. Dist., or Mist. Camphor ℥iv). A compress of lint is to be soaked in this, and applied to the lids by a firm bandage. The following formula recommended by Mr. Lawson is also a very good one:—℞ Tr. Arnic. Mont. ʒiv; Liq. Ammon. Acet. ℥j; Sp. Rosism. ʒiv; Mist. Camph. ad ℥viii. M. f. lotio. A poultice of black bryony-root is likewise much in vogue amongst the public. The swollen parts should never be pricked or punctured, as this tends to produce suppuration and erysipelas.

Wounds of the eyelids vary in danger according to their situation and extent, and according to the fact whether they are simply incised, or are punctured, and accompanied perhaps by considerable bruising and contusion of the parts. If the incision is superficial and horizontal, and has only divided the skin and a few of the fibres of the obicularis, it will soon heal by first intention, if the edges of the wound are brought together by sutures and strips of plaster, and little, if any, mark will be left behind. But when the wound is extensive and has penetrated deeply into the upper lid, implicating perhaps the cartilage, and dividing the fibres of the levator palpebræ, its consequences are much more serious. For not only may it produce a considerable degree of ptosis, but, on account of the suppuration which may supervene, contraction and shrinking of the integuments may ensue, and give rise to a severe and obstinate ectropium. If the cut is vertical, it may divide the tarsal edge of the lid, splitting it up and laying it open to a more or

less considerable extent, thus giving rise to an unsightly gap or coloboma. If the rent is situated near the inner angle of the eye, it may divide the canaliculus, and tear it away from the punctum lacrymale. In a small punctured wound, the danger is but slight, if it is confined to the eyelid and has not extended into the orbit or injured the eyeball, otherwise, it may produce more or less severe orbital cellulitis; or, if the globe has been injured, serious consequences may arise, and the eye be perhaps completely lost. If the wound or tear in the eyelid has been accompanied by severe contusion of the parts, there is always much danger of suppuration or even of sloughing setting in. Wounds of the eyelids implicating the infra-orbital nerve have been noticed to produce amaurosis, which was termed sympathetic. The cases of this kind which have been narrated, occurred, however, before the discovery of the ophthalmoscope, and hence the true condition of the fundus oculi was not known.

Wounds of the skin of the eyelids should be brought accurately together with fine sutures and strips of plaster, the part being kept cool and at rest by the application of a moist compress and a bandage. Even where the wound extends deeply into the tissue of the eyelid, and is accompanied by much bruising, it is better to unite its edges by sutures than to leave it to heal by granulation, as this will produce a more or less considerable loss of substance, contraction of the integuments, and very probably ectropium. If the tarsal edge has been divided by a vertical cut, the edges of the gap should be very carefully brought together, and maintained in accurate apposition by the insertion of one or more twisted sutures. One suture should always be applied as close as possible to the edge of the lid, so that the margin of the latter may become closely and accurately united. The edges of the gap may, if necessary, be pared; the needle should be a very fine one, and should be inserted through the cartilage. If the canaliculus has been divided, its opening should be searched for, and a director (Fig. 85, p. 611) should be inserted, and the canaliculus be slit open into the sac, with a cataract knife.

The eyelids are often also injured by burns or scalds from hot seething fluid, the flame of a candle, etc., the explosion of gunpowder, or the action of strong caustic fluids. If the edges of the lids are severely injured, these may become adherent, and a more or less extensive anchyloblepharon be produced, or symblepharon may ensue, if the conjunctiva has been implicated in the injury. Moreover, a very severe and obstinate form of ectropium often ensues upon burns of the lids, on account of the shrinking and contraction of the skin which accompany and supervene upon the cicatrization. This is especially observed in the lower lid. If the injury is so extensive that little is left of the eyelids except the cartilage and the conjunctiva, the ectro-

pium and consequent lagophthalmos are so great, that severe inflammation of the cornea and other structures of the eye supervenes, and the latter is generally soon destroyed.

In slight cases of scalds or burns of the eyelids in which the cutis is not destroyed, cold water dressing should be applied and constantly renewed for the first 24 or 36 hours. If a blister forms, this should be pricked and the serum allowed to escape, the water dressing being then re-applied. If the injury has been so severe that the skin is destroyed, simple cerate dressing should be applied, and great care be taken that the lid is kept upon the stretch during the period of cicatrization, in order that new skin may be formed, and ectropium be thus avoided. A bandage should, therefore, be so applied as to keep the lid upon the stretch, and the patient should not be allowed to use his eyes until complete cicatrization has taken place.

The eyelids often become greatly inflamed and swollen from the stings of insects, such as bees, gnats, etc. The sting should be removed as soon as possible, and cold water dressing, or evaporating lotions be prescribed.

Amongst the congenital malformations of the eye, we sometimes meet with epicanthus and coloboma of the eyelid.

Epicanthus consists in the presence of a crescentic fold of skin, which passes from the nose to the eyebrow, and overlaps and hides, to a greater or less extent, the inner canthus. If it is considerably developed it is very unsightly, and it may be necessary to cure it by operative interference. But we should wait with an operation until the child gets older, for it is often found that the deformity gradually disappears, as the bones of the nose become more developed and the latter more prominent. If this should not, however, occur, an elliptical fold of skin (the size of which must vary with the amount of effect which we desire to produce) is to be excised from the upper portion of the nose. The edges of the wound should be somewhat dissected up, so that they may be the more readily approximated, and the lips of the wound closed with sutures.

Coloboma or fissure of the eyelid is a congenital deformity, which is but of rare occurrence. It is sometimes associated with cleft palate, hare-lip, coloboma of the iris and choroid, and other arrests of development. The fissure may be confined to one eyelid, or be present in both; or again, a double cleft may exist, the two fissures being, perhaps, close to each other, and connected by a small intervening bridge. To cure this condition, the edges of the coloboma should be pared, and then accurately brought together by fine twisted sutures, which should pass through the cartilage, the one suture being quite closely applied to the free edge of the lid, so that the lips of the cleft may here be very evenly and accurately united.

EXPLANATION OF THE PLATES.

PLATE I.

Figs. 1 and 2.

The Normal Fundus Oculi (*vide* p. 305).

In Fig. 1 (which is taken from a person with black hair and a dark brown iris) the optic nerve entrance appears circular, and of a yellowish white tint. The blood-vessels emerge somewhat to the left of the centre of the disc, which is here of a deeper white. The paler vessels are the retinal arteries, the darker ones the veins. They pass over the disc to the retina, where they course and divide in different directions, chiefly upwards, downwards, and towards the left. At some little distance to the right of, and slightly below, the disc, is noticed a large dark-red spot, with a small white dot in the centre. This is the macula lutea, or yellow spot, with its foramen centrale. It will be observed that the vessels course round the yellow spot, leaving it free. The fine grey film in the region of the disc and the yellow spot is due to the reflex yielded by the retina; it is only observable in dark eyes, and is consequently altogether absent in Fig. 2. The fundus of the eye is of a rich dark-red tint, and only the retinal vessels are apparent, those of the choroid being hidden by the density of the pigment in the epithelial layer and stroma of the choroid.

In Fig. 2 (taken from the eye of a person with very light hair and a blue iris) the appearances are quite different. The disc is of a more rosy tint, the retinal vessels, although very distinct, are less markedly so than on the darker background of Fig. 1. The region of the yellow spot is of a bright red colour, and the foramen centrale appears in the form of a little light circle. But the greatest difference is noticed in the pale, brilliantly red colour of the fundus, and the distinctness with which the finest branches of the choroidal vessels can be traced. The ciliary arteries enter in the region of the yellow spot, and, running towards the periphery, ramify in various directions, and partly pass over directly into the larger branches of the vasa vorticosa, situated at the equator of the eye.

Plate I.

After Liebreich's Atlas.

Berlin, Winckelmann & Söhne (H Porsch) lith.

PLATE II.

Fig. 3.

Sclerotico-choroiditis Posterior (Staphyloma Posticum) p. 427.

This figure illustrates the appearances presented by an extensive sclerotico-choroiditis posterior. Towards the outer side of the disc is observed a large white figure, over which the retinal vessels appear to run a somewhat straighter course, and to be rather more numerous and distinct. The disc is oval, and its shortest diameter (in this case the horizontal) shows the direction in which the ectasia (bulging) is situated. In the vicinity of the disc and of the white figure, the choroid is observed to be somewhat thinned; on the left, the pigment in the epithelial layer is diminished, and hence the choroidal vessels are particularly marked. The intra-vascular spaces are here also peculiarly conspicuous and striking, which is due to the increase in the pigment of the stroma. Whereas, on the right side of the figure, the pigmentation of the epithelial layer conceals the subjacent tissue and the vessels.

Fig. 4.

Choroiditis Disseminata Syphilitica, with Secondary Atrophy of the Retina and Optic Nerve (p. 422).

In this figure we notice very numerous, irregular, circumscribed spots of a palish-pink or whitish tint, surrounded by a dark fringe of pigment; others, appearing simply as small black patches. In some of the larger spots, a choroidal vessel can be distinctly seen to pass over it. The optic disc is atrophied, and of a bluish tint. It is completely devoid of blood-vessels, excepting the two little twigs which can just be discerned running over its edge. But not a single retinal vessel can be seen over the whole fundus; and on account of this atrophy of the retina, the choroidal vessels appear with unusual distinctness.

Plate II.

PLATE III.

Fig. 5.

Retinitis Pigmentosa (p. 349).

Numerous large, irregular, black figures are observed scattered about the fundus, being arranged at some points along the retinal vessels, which are extremely attenuated, and here and there quite unapparent. At other situations, the black patches show irregular prolongations, the extremities of which touch those of other spots. Hence they assume a certain similarity to bone corpuscles. The optic nerve is white and atrophied, and the retinal arteries are excessively small and attenuated.

Fig. 6.

Retinitis Albuminurica (p. 336).

This illustration is peculiarly characteristic of the ophthalmoscopic appearances presented by the retinitis met with in Bright's disease. At the disc, and in its vicinity, is observed a delicate grey opacity, which is caused by a serous infiltration and proliferation of the connective tissue of the retina. Beyond this, lies the white glistening mound, which is due to sclerosis of the optic nerve fibres and fatty degeneration of the connective tissue elements. The extreme margin of this white mound is broken up into small, irregular patches, which assume, in the region of the yellow spot (to the left of the disc), a peculiar stellate arrangement, looking as if they had been splashed in with a brush. The retinal arteries are much diminished, both in calibre and number. The veins are dilated and tortuous, and the vessel running upwards, is interrupted in its course by the infiltration, and, at the point of interruption, are noticed well-marked blood extravasations. These, as well as most of the other hæmorrhages, show by their irregular outline and striated, feathery appearance, that they lie in the optic nerve layer of the retina.

Plate III.

5.

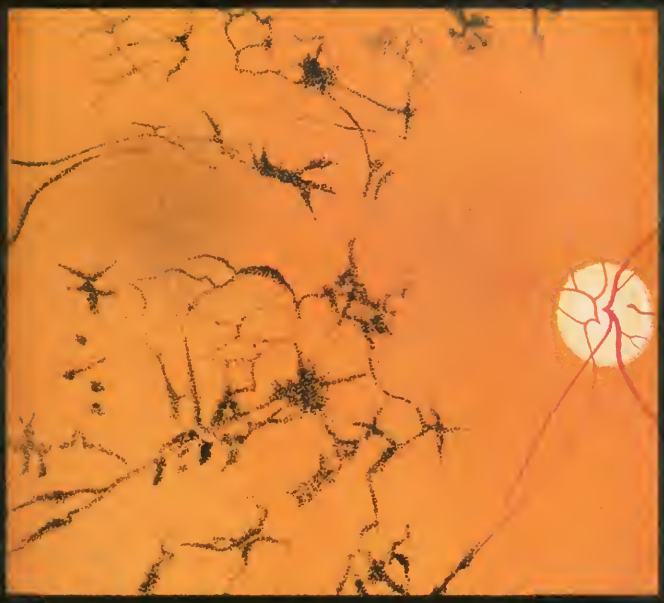

6.

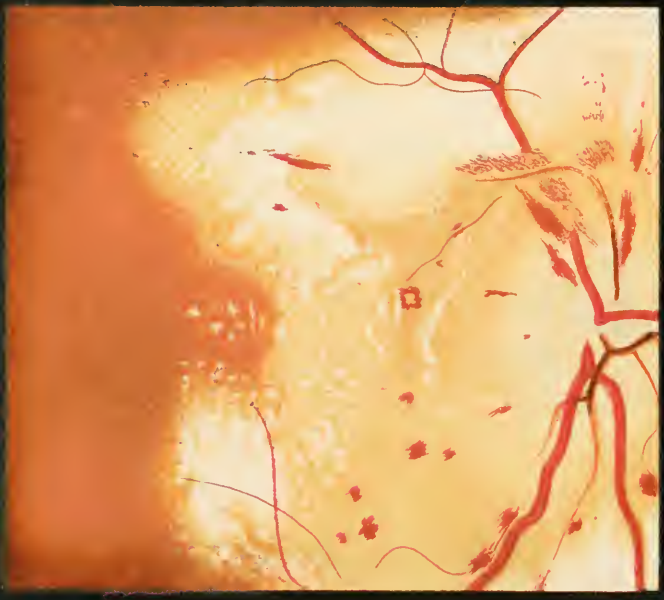

PLATE IV.

Fig. 7.

Hæmorrhagic Effusions into the Retina, Retinitis Apoplectica (p. 347).

[At p. 347 this figure has been, by mistake, described as being on Plate VI.]

In Fig. 7, numerous blood effusions of varying size and shape are noticed in the retina, being situated in different layers of the latter. But even between the larger patches, the retina is not free, for minute hæmorrhagic spots are strewn about in all directions. The retinal arteries are here and there filled with blood coagula, but at other points they are quite bloodless, and changed into narrow white bands. In a few branches, the circulation is, however, unimpeded.

Fig. 8.

Embolism of the Central Artery of the Retina (p. 363).

Here we notice, in the region of the yellow spot, a well marked greyish white opacity, which is due to a serous infiltration of the retina. In its centre, is a conspicuous cherry-coloured spot which is not caused by a blood effusion, as might be supposed at the first glance, but is due to the fact, that the retina is transparent at this point, and thus permits the choroid to shine through, which assumes a redder tinge in consequence of the contrast with the greyish-white opacity. The vessels running towards the yellow spot, are particularly conspicuous on account of the blood coagula which they contain, and of the white opacity. The outline of the disc is slightly undefined and encircled by a faint opacity. The retinal veins show a distinct retardation in the circulation, and contain here and there blood coagula. The arteries are greatly diminished in size, and become quite indistinct at certain points of their course.

Plate IV.

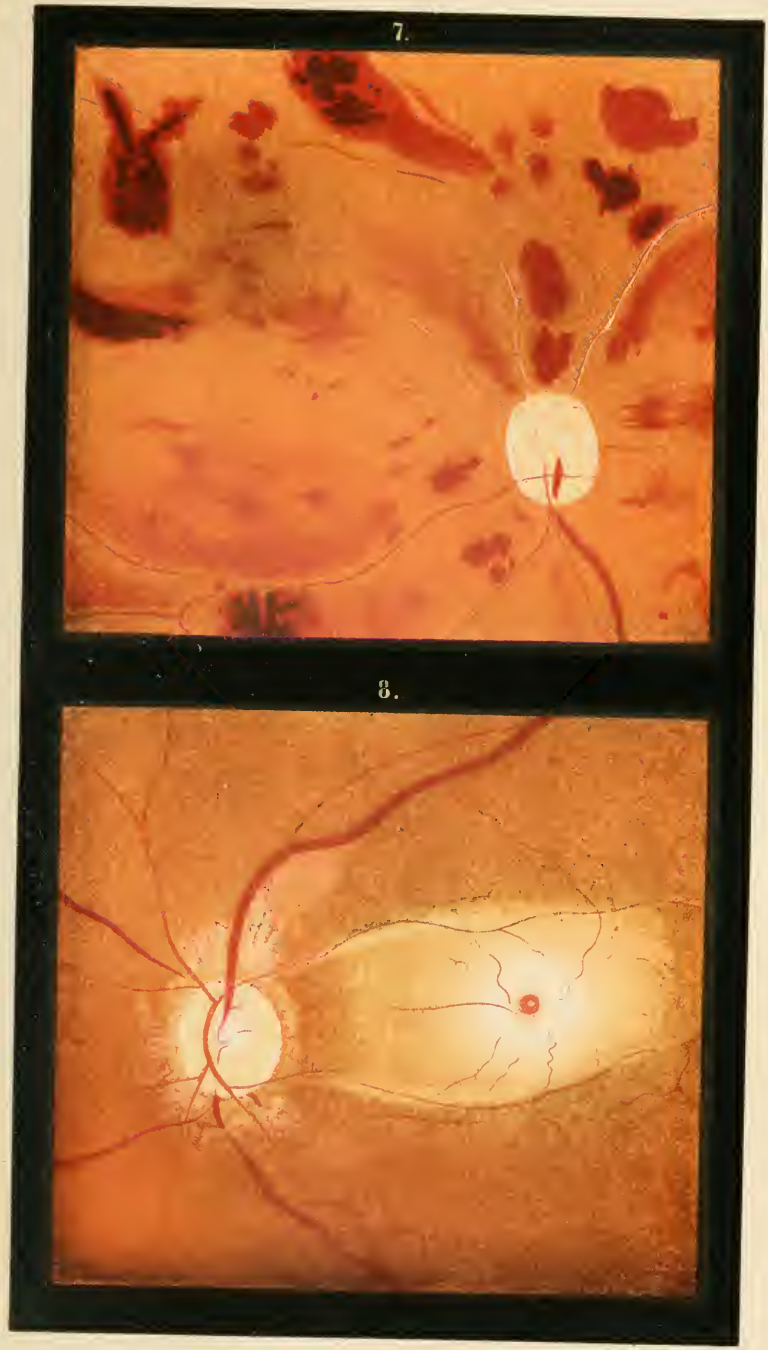

PLATE V.

Fig. 9.

Cysticercus in the Vitreous Humour (p. 325).

This figure illustrates the appearance presented by a cysticercus in the vitreous humour. The entozoon shows itself in the form of a well-defined, bluish-grey vesicle, which is so transparent, that in the central portion the red tint from the choroid can be distinctly seen to shine through. The neck is more opaque in tint than the rest of the entozoon, and is studded with small white dots (chalky particles). At the head, two suckers can be recognised, the other two being placed posteriorly. The buccal extremity is directed upwards. The small, circular, grey spots which partly encircle the vesicle, are caused, according to Liebreich, by a peculiar opacity of the vitreous humour due to the suction of the entozoon, and are quite characteristic of the presence of a cysticercus.

Fig. 10.

Detachment of the Retina (p. 353).

Fig. 10 represents a case of old standing and extensive detachment of the retina. The lower half of the retina (which shows a tolerably sharply-defined edge towards the left) bulges forwards into the vitreous humour, and is thrown into well-marked folds, and on this account, as well as of the colour of the subjacent fluid, it shows a peculiar greenish-grey tint. The retinal vessels are undulating and tortuous, riding on the folds of the retina, and they assume a darker tint in consequence of the grey background.

Plate V.

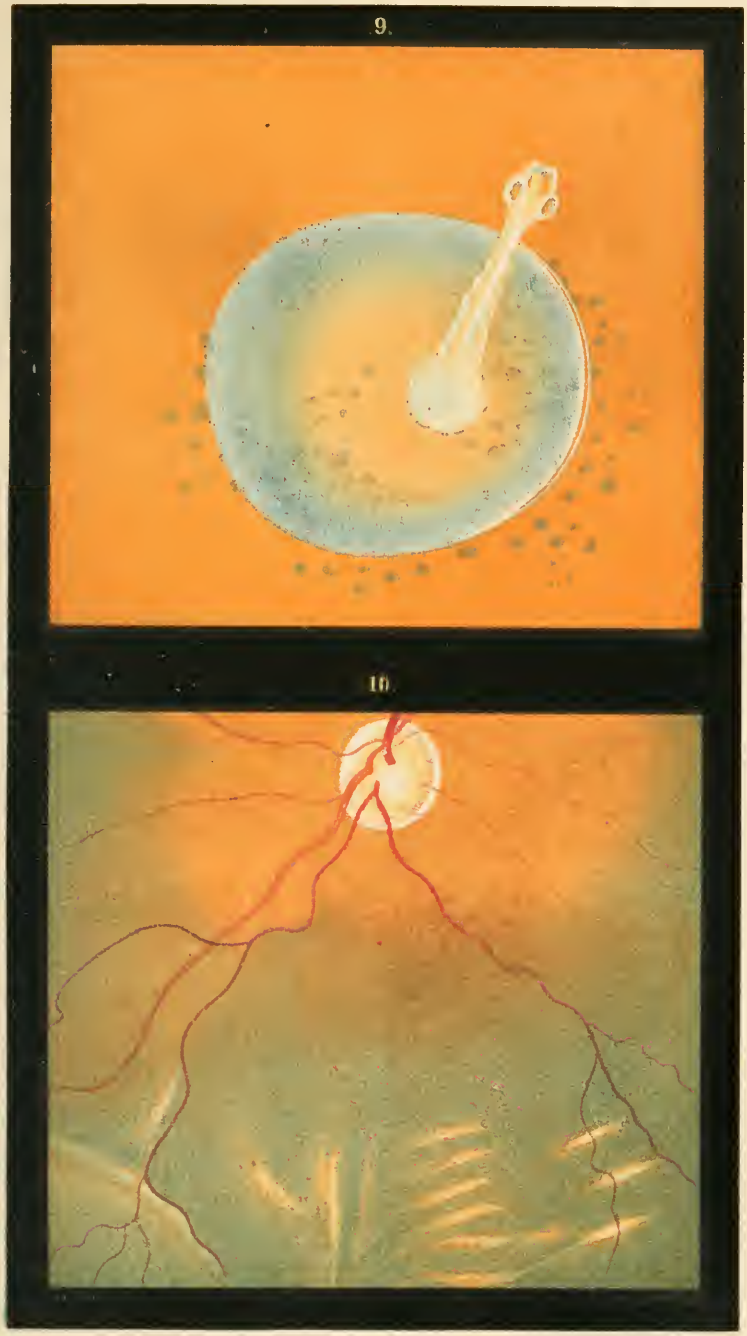

PLATE VI.

Figs. 11 and 12.

Atrophy of the Optic Nerve (p. 385).

Fig. 11 shows the appearances presented by atrophy of the optic nerve, in a patient affected with loco-motor ataxy. The disc is slightly excavated, and of the peculiar bluish mottled tint, so frequently observed in the atrophy dependent upon spinal disease. The arteries are small and attenuated. Fig. 12 represents a case of white atrophy after meningitis. The disc is very white, and faintly cupped. The arteries are much diminished in calibre, and some of the veins (as some of those in Fig. 11) show a well-marked, white streak along their margin, which is due to sclerosis of the tunica adventitia.

Figs. 13 and 14.

Optic Neuritis (p. 375).

In Fig. 13 is represented the swollen and enlarged papilla consequent upon optic neuritis, the opacity of the disc being dense and markedly striated. The retinal veins are enlarged and tortuous, the arteries diminished in size, and, here and there, hidden by the exudation. Fig. 14 shows the condition of the same optic nerve two years later, when consecutive atrophy had supervened. The uniformly opaque tint of the disc, as well as its somewhat undefined margin, help to distinguish it at a glance from the progressive form of atrophy (Fig. 12). Moreover, although the veins are less dilated than in Fig. 13, they yet retain a certain degree of tortuosity.

Figs. 15 and 16.

Glaucomatous excavation of the Optic Nerve (p. 390).

In these two figures, are observed different degrees of glaucomatous excavation. Both present all the characteristic features of this disease, but in Fig. 15 they are less marked than in Fig. 16, in which the cup is much deeper and more abrupt. In each case, the disc is surrounded by a pale light girdle, its colour is much darker at the periphery than in the centre, and the retinal vessels are more or less considerably bent or interrupted at the edge of the papilla.

Plate VI.

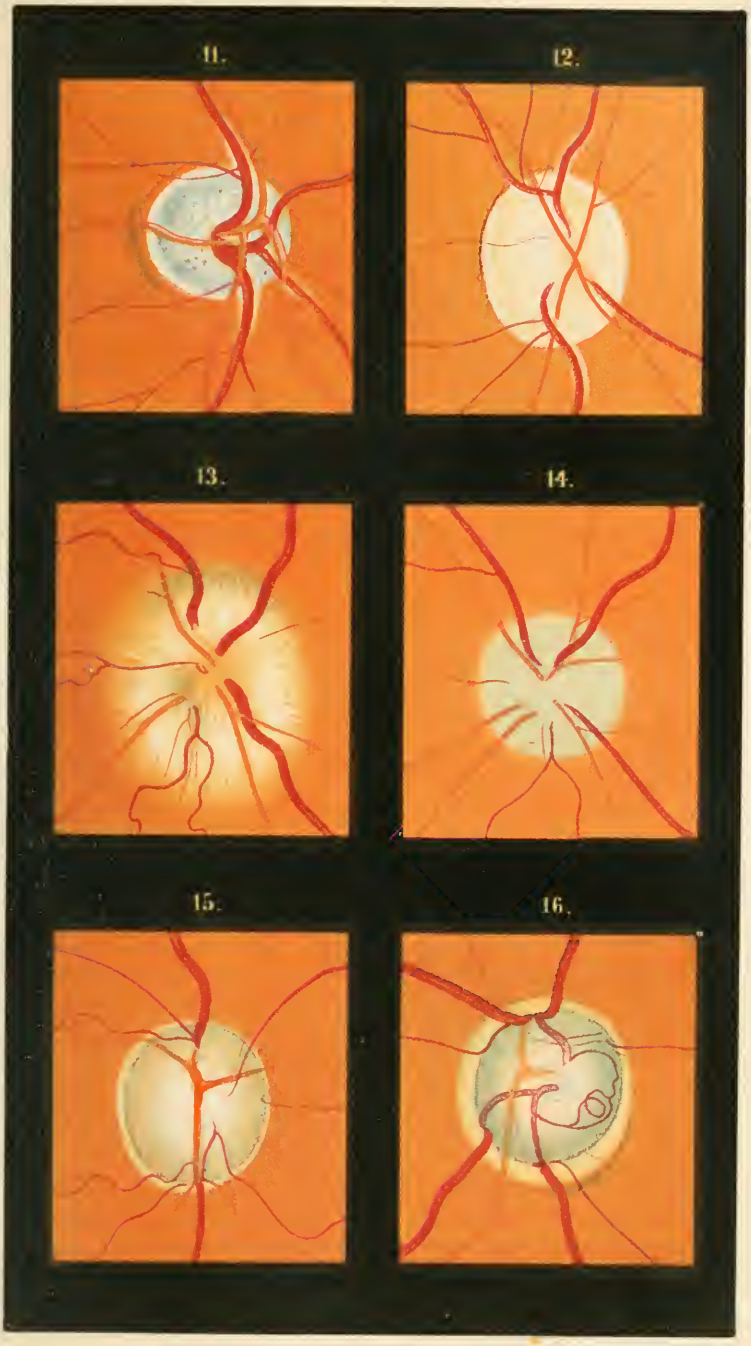

INDEX.

A.

Abscess of cornea, 99.
—— lachrymal sac, 613.
—— orbit, 627.
—— frontal sinus, 661.
Absorption, cure of cataract by, 265.
Accommodation, nature of, 498.
—— action of atropine upon, 162.
—— action of Calabar bean upon, 540.
—— mechanism of, 500.
—— negative, 502.
—— paralysis of, 539.
—— range of, 503.
—— binocular range of, 505.
—— negative range of, 505.
Acne ciliaris, 677.
Acuteness of vision, modes of estimating, 4.
Aegilops, 670.
Agnew, Dr., on capsular cataract, 276.
Albuminuria, a cause of retinitis, 336.
—— a cause of amblyopia, 341, 412.
Allbutt, Dr., on optic neuritis, 376.
—— on the state of the optic nerve in the insane, 404.
Althaus, Dr., on electrolysis, 655, 687.
—— on locomotor ataxy, 407.
Amaurosis, 396.
—— simulation of, 420.
Ametropia, 500.
Amblyopic affections, 396.
Amblyopia, 412.
—— ex anopsiâ, 413, 578.
—— anæmic, 409.
—— from blood poisoning, 410.
—— congestive, 409.
—— potatorum, 410.
—— saturnina, 412.
—— from tobacco, 411.
—— uræmic, 412.
—— from non-use, 413, 578.
Anchyloblepharon, 80.
Anchylops, 670.
Anderson, Dr. McCall, on eczema of lid, 676.
Aneurism of the orbit, 654.
—— by anastomosis, in orbit, 654.
—— —— of eyelids, 686.
—— of central artery of retina, 655.
Anterior chamber, changes in the contents of, etc., 182.
Anthrax, of the eyelids, 672.
Aphakia, 538.
Aqueous humour, cure of cataract by repeated evacuation of, 273.
Aquo-capsulitis, 148.
Arcus senilis, 128.
Arlt, Prof., on cause of pterygium, 74.
—— on operation for entropium, 696.
Artificial eye, mode of insertion, 666.
—— leech, 13.
Asthenopia, due to hypermetropia, 522.
—— muscular, 600.
—— retinal, 522.
Astigmatism, 525.
—— acquired, 533.
—— compound, 532.
—— congenital, 533.
—— diagnosis of, 526, 529.
—— irregular, 528, 537.
—— mixed, 532, 536.
—— regular, 528, 533.
—— simple, 532, 534.
—— ophthalmoscopic diagnosis of, 532.
—— treatment of, by cylindrical lenses, 534.
Ataxy, locomotor, a cause of amaurosis, 403.
Atresia of the lachrymal puncta, 612.
Atrophy of the optic nerve, 385.
—— of the retina, 374.
Atropine, action of, on the accommodation, 162.
—— —— on the iris, 162.
—— anomalous effects of, 94—note.
—— idiosyncrasy against, 93—note.
—— in iritis, 154.
—— necessity of its being pure, 93—note.
—— poisoning by, 157.
Aut-ophthalmoscope of Giraud Teulon, 297.
Axes, secondary of lenses, 490.
Axis, optic, 494.
—— of turning, 549.

B.

Bader, Mr., on inoculation, 62.
—— on syndectomy, 61—note.
Bandages, different forms of, 11.
—— compress bandage in corneitis, 105.

Bandages, Von Graefe's, 12.
—— Liebreich's, 11.
Basedowii, Morbus, 634.
Becker, Dr., on accommodation of the eye, 501.
Bell, Dr. Joseph, on aneurism of orbit, 656.
Belladonna ointment, 21.
Benedikt, Dr., on electricity, 568.
Bergmann, Dr., on retinitis albuminurica, 339.
Bergeron, Dr., on treatment of epithelial cancer of lids, 686.
Berlin, Dr., on diphtheritic conjunctivitis, 44.
—— on extirpation of lachrymal sac, 625.
Binocular vision, mode of examination of, 576.
—— —— in strabismus, 575, 577.
Black eye, 715.
Blenorrhœa, 22.
—— of lachrymal sac, 617.
Blepharitis marginalis, 674.
Blepharo-adenitis, 675.
Blepharoplasty, 710.
Blepharospasm, 690.
Blood effused into anterior chamber, 183.
—— —— choroid, 453.
—— —— conjunctiva, 87.
—— —— eyelids, 714.
—— —— orbit, 659.
—— —— retina, 332, 347.
—— —— vitreous humour, 316.
Böhm, Dr., on Nystagmus, 570
Bonnet, capsule of, 587.
Borelli's, Dr., operation for staphyloma, 140.
Bowman, Mr., on aneurism of the orbit, 657.
—— on abscess of frontal sinus, 662.
—— on astigmatism, 533.
—— on conical cornea, 131.
—— on treatment of capsular opacities, by two-needle operation, 275.
—— on iridectomy, 176.
—— on irido-choroiditis, 193.
—— on treatment of obstructed ducts, 610.
—— on treatment of detached retina, 359.
—— on scoop extraction of cataract, 256.
—— suction syringe for cataract, 272.
—— on strabismus, 573.
—— sympathetic ophthalmia, 200.
—— on estimating the degree of tension of the eye, 2.
Brachymetropia, 499.
Broadbent, Dr., on treatment of cancer by injection of acetic acid, 668.
Busch, Dr., on tubercles in the choroid, 440.
Buphthalmos, 133.
Buys, Dr., on use of acetate of lead in granular ophthalmia, 58.

C.

Calabar bean, action of on iris, 162.
—— —— —— ciliary muscle, 540.
Calculus lachrymal, 608.
—— Meibomian, 682.
Calomel, insufflation of, 67.
Canaliculi, division of, 612.
—— obstructions in, 612.
Cancer of choroid, 448.
—— of conjunctiva, 86.
—— epithelial, of eyelids, 684.
—— of orbit, 647, 648.
Canthoplasty, 699.
Canton, Mr., on arcus senilis, 128.
Capsule of Bonnet, 587.
—— Tenon, 587.
Capsular cataract, 227.
—— —— anterior, 228.
—— —— posterior, 224.
Carbuncle of the eyelids, 672.
Cardinal points in diagrammatic eye, 495.
Caries of the orbit, 632.
Carter, Mr., on injuries of orbit, 663.
—— on compound object lens, 302.
Cartilagineous tumours of orbit, 643.
Cataract, ætiology of, 215.
—— diagnosis of, 217.
—— symptoms of, 217.
—— anterior capsular, 228.
—— black, 223.
—— capsular, 227.
—— congenital, 219, 221.
—— cortical, 221.
—— diabetic, 215.
—— lamellar or zonular, 219.
—— Morgagnian, 226.
—— nuclear or hard senile, 223.
—— posterior capsular (polar), 224.
—— pyramidal, 228.
—— siliculose or chalky, 222.
—— traumatic, 226.
—— treatment of, by division, 265.
—— —— by flap extraction, 233.
—— —— —— with iridectomy, 249.
—— —— by Von Graefe's extraction, 258.
—— —— by linear extraction, 252.
—— —— by repeated paracentesis corneæ, 273.
—— —— by reclination or couching, 265.
—— —— by scoop extraction, 255.
—— —— by suction, 271.
—— —— by removal of lens in its capsule, 250.
—— —— of lamellar, 269.
—— —— of traumatic, 270.
—— secondary, operations for, 274.

Catarrhal ophthalmia, 16.
Cat's-eye, amaurotic, 368.
Catoptric test, 218.
Caustics, on the use of, in purulent ophthalmia, 32.
Caustic mitigated, on use of, 33.
Cellulitis of the orbit, 627.
Charpie, 12—note.
Chalazion, 681.
Chemosis, 18.
Chlorine water, use of, 53, 60, 69.
Cholesterine in vitreous humour, 321.
Clover's, Mr., chloroform-apparatus, 250.
Choroid, diseases of, 422.
—— cavernous sarcoma of, 450.
—— carcinoma of, 448.
—— colloid disease of, 439.
—— coloboma of, 450.
—— detachment of, 454.
—— formation of bone in, 450.
—— hæmorrhage from, 453.
—— hyperæmia, of, 422.
—— myoma of, 449.
—— rupture of, 451.
—— sarcoma of, 443.
—— tubercles of, 440.
—— tumours of, 443.
Choroiditis areolar, 424.
—— disseminated or exudative, 422
—— syphilitic, 423.
—— suppurative, 434.
Chromhydrosis, 679.
Ciliary body, inflammation of, 206.
—— muscle, affections of, 539.
—— —— atony of, 541.
—— —— paralysis of, 539.
—— —— spasm of, 541.
—— neuralgia, 19.
—— region, injuries of, 208.
Circles of diffusion, 495.
Coccius, Prof., compound object lens of, 302.
—— ophthalmoscope of, 291.
—— on glaucoma, 475.
Cohn, Dr., on mica spectacles, 546.
—— on myopia, 508.
Cohnheim, Dr., on tubercles of choroid, 440.
Coloboma of eyelid, 717.
—— of iris, 170.
—— of choroid, 450.
Colloid disease of choroid, 439.
Colour-blindness, 419.
Compression, digital, in orbital aneurism, 658.
Conical cornea, 128.
—— —— treatment of, by iridectomy, 131.
—— —— —— iridodesis, 131.
—— —— —— Von Graefe's, 131.
Conjunctiva, diseases of the, 15.
—— cysts of, 85.
—— cysticercus in, 85.
—— emphysema of, 88.
Conjunctiva, epithelial cancer of, 86.
—— hæmorrhage into, 87.
—— hyperæmia of, 15.
—— injuries of, 81.
—— lithiasis of, 87.
—— medullary cancer of, 86.
—— melanotic cancer of, 86.
—— nævi of, 87.
—— œdema of, 88.
—— polypus of, 83.
—— syphilitic ulcers of, 87.
—— tumours of, 83.
Conjunctival discharge, contagiousness of, 28.
Conjunctivitis, catarrhal, 16.
—— exanthematous, 70.
—— diphtheritic, 40.
—— gonorrhœal, 36.
—— granular, 45.
—— phlyctenular, 64.
—— purulent, 22.
Contusions of eyelids, 715.
Convergent strabismus, 579.
Coredialysis, 181.
Corelysis, 180.
Corectopia, 171.
Cornea, diseases of, 89.
—— abscess of, 99.
—— conical, 128.
—— —— treatment of, by iridectomy, 131.
—— —— —— by iridodesis, 131.
—— —— —— Von Graefe's, 131.
—— fistula of, 116.
—— hernia of, 110.
—— herpes of, 91.
—— injuries of, 140.
—— neuro-paralytic affection of, 102.
—— opacities of, 122.
—— paracentesis of, 100, 113.
—— perforation of, 26, 111.
—— staphyloma of, 134, 135.
—— suppuration of, after flap extraction, 245.
—— tumours of, 143.
—— ulcers of, 108.
—— crescentic ulcer of, 109.
—— perforating ulcer of, 109.
—— transparent ulcer of, 110.
—— vesicles on the, 95.
Corneitis, diffuse, 117.
—— vascular diffuse, 117,
—— non-vascular diffuse, 121.
—— fascicular, 95.
—— phlyctenular, 91.
—— suppurative, 97.
—— inflammatory suppurative, 98.
—— non-inflammatory suppurative, 101.
Couper, Mr., on sympathetic ophthalmia, 199.
Couching, 265.
Critchett, Mr., on iridodesis, 178.
—— operation of, on canaliculus, 613.
—— —— of re-adjustment, 599.

380 581 Coarse disease

Critchett, Mr., operation of, for strabismus, 593.
—— —— for staphyloma, 137.
—— on use of seton in ulcers of the cornea, 114.
—— on scoop extraction, 256.
Cyclitis, 206.
Cylindrical lenses, 534.
—— use of, in astigmatism, 534.
Cylindroma of eyelid, 684.
Cyst, tarsal, 681.
—— in iris, 167.
Cysticercus in anterior chamber, 184.
—— of the orbit, 646.
—— in vitreous humour, 323.
Cystoid cicatrix in glaucoma, 487.

D.

Dacryo-adenitis, 605.
Dacryocystitis, 613.
Dacryoliths, 608.
Dacryops, 606.
Daltonism, 419.
Deformity of orbit from pressure, 660.
De Morgan, Mr. Campbell, on medullary cancer of orbit, 650.
Depression of cataract, 265.
Descemetitis, 148.
Destruction of lachrymal sac, 624.
Detachment of the retina, 353.
—— of the choroid, 454.
Deviation, primary, of visual lines, 554.
—— secondary, of visual lines, 554.
—— —— in paralytic affections of ocular muscles, 555.
—— —— in strabismus concomitans, 572.
Dieffenbach's operation for ectropium, 709.
Digital pressure in orbital aneurism, 658.
Diphtheritic conjunctivitis, 40.
Diplopia, homonymous, 9.
—— crossed, 9.
—— monocular, 538.
—— operations for, 597.
Dislocation of the eye, 664.
—— of the lens, 277.
Distichiasis, 692.
Divergent strabismus, 582.
Division of cataract, 265.
Dixon, Mr., on peculiar deposit in cornea, 124.
—— on dislocation of lens, 280.
Donders, Prof., on ametropia, 500.
—— on astigmatism, 525.
—— on brachymetropia, 499.
—— on colloid disease of choroid, 439.
—— on emmetropia, 498.
—— on entoptics, 319.
—— on glaucoma, 470.
—— on hypermetropia, 499.
—— on retinitis pigmentosa, 351.
Donders, Prof., on sclerotico-choroiditis posterior, 432.
—— on stenopaic spectacles, 127.
—— sympathetic ophthalmia, 195.
—— on vertical meridian, 548.
—— on visual line, 496.
Duct, lachrymal, obstruction of, 618.
—— —— — Bowman's treatment of, 619.
—— —— — Critchett's treatment of, 619.
—— —— — Stillings' treatment of, 622.
—— —— — Warlomont's treatment of, 622.
—— —— — Weber's treatment of, 620.
—— nasal, stricture of, 618.

E.

Ecchymosis of conjunctiva, 87.
—— of eyelids, 714.
—— of retina, 332, 347.
Echinococcus in orbit, 646.
Ectopia lentis, 277.
Ectropium, 703.
—— from inflammatory hypertrophy of conjunctiva, 704.
—— from cicatrices, wounds, &c., 704.
—— from caries, 705.
—— Adams' operation for, 707.
—— Dieffenbach's operation for, 709.
—— Graefe's operation for, 709.
—— Hasner's operation for, 714.
—— Wharton Jones' operation for, 708.
—— Knapp's operation for, 713.
—— treatment by blepharoplasty (transplantation), 710.
—— treatment of, by tarsoraphia, 706.
Eczema of the lids, 674.
Effusion, of blood, into anterior chamber, 183.
—— —— into choroid, 453.
—— —— into conjunctiva, 87.
—— —— into eyelids, 714.
—— —— into retina, 332.
—— —— into vitreous humour, 316.
Egyptian ophthalmia, 22.
Electricity, in paralysis of ocular muscles, 568.
Electrolysis, 655, 686, 687.
Embolism, of choroidal vessels, 438.
—— of retinal artery, 363.
Emmetropia, 498.
Emphysema of eyelids, 668.
Enchondroma of orbit, 645.
Encysted tumours of orbit, 645.
Entoptics, 319.
Entozoa, vide Cysticercus and Echinococcus.
Entropium, 697.
—— acute or spasmodic, 698.
—— chronic, 698.

Entropium, senile, 698.
—— Arlt's operation for, 696.
—— Author's operation for, 703.
—— Graefe's, 700.
—— Pagenstecher's, 701.
—— Snellen's, 702.
—— Streatfeild's, 702.
Enucleation of eyeball, 664.
Ephidrosis, 678.
Epicanthus, 717.
Epilepsy of the retina, 361.
Epiphora, 609.
Episcleritis, 65, 209.
Epithelial cancer of eyelids, 684.
Erectile tumours of eyelids, 686.
—— —— of orbit, 654.
Eruptions, syphilitic, of eyelids, 672.
Erysipelas of eyelids, 671.
Erythema of eyelids, 669.
Evacuation of aqueous humour, 35, 113.
Eversion of the upper lid, 1.
—— of the eyelids, 703.
Exanthematous ophthalmiæ, 70.
Excavation of optic nerve, 388.
—— — atrophic, 389.
—— — glaucomatous, 390.
—— — physiological, 309.
Excision of eyeball, 664.
Exophthalmic goitre, 634.
Exostosis of orbit, 631, 643.
Extirpation of eyeball, 664.
—— of lachrymal gland, 608.
—— of lachrymal sac, 625.
Extraction, of cataract, in capsule, 250.
—— —— by flap operation, 233.
—— —— by Von Graefe's operation, 258.
—— —— by linear incision, 252.
—— —— by scoop operation, 255.
—— —— by suction, 271.
Eye, diagrammatic eye of Listing, 495.
—— douche, 14.
—— general inflammation of, 434.
—— rupture of, 214.
Eyeball, dislocation of, 664.
—— excision of, 664.
Eyelashes, inversion of, 692.
—— transplantation of, 696.
Eyelids, diseases of, 668.
—— abscess of, 669.
—— anthrax of, 672.
—— contusions of, 714.
—— ecchymosis of, 714.
—— encysted tumours of, 681.
—— epithelial cancer of, 684.
—— erysipelas of, 671.
—— erythema of, 669.
—— eversion of, 703.
—— inflammation of edges of, 674.
—— inversion of, 697.
—— nævus of, 686.
—— œdema of, 668.
—— tumours of, 681.
—— ulcers, syphilitic, of, 686.
Eyelids, warts of, 684.
—— wounds of, 715.

F.

Far point, 503.
Farsightedness, 515.
Fatty degeneration of retina, 339.
—— —— in retinitis albuminurica, 339.
—— tumours of conjunctiva, 84.
—— —— of eyelids, 681.
Fibroma of eyelid, 684.
—— of orbit, 639.
Field of vision in amblyopic affections, 397, 405.
—— —— contraction of, in detached retina, 356.
—— —— —— in retinitis pigmentosa, 352.
—— —— erroneous projection of, 555.
—— —— in hemiopia, 398.
—— —— equilateral or homonymous contraction of, 398.
—— —— examination of, 5.
—— —— Author's method, 7.
—— —— Mr. Teale's, 8.
—— —— Dr. Wecker's, 8.
Fistula of cornea, 116.
—— of lachrymal sac, 625.
Flap extraction of cataract, 233.
Focal interval, 527.
—— line, anterior, 527.
—— —— posterior, 527.
Focus of lenses, 489, 493.
Foci, conjugate of lenses, 490.
Fomentations, warm, in suppurative corneitis, 104.
Foreign bodies in the conjunctiva, 81.
—— —— cornea, 140.
—— —— iris, 167.
—— —— lens, 227.
—— —— vitreous, 321.
Formation of bone in choroid, 450.
Förster, Dr., on areolar choroiditis, 424.
Fractures of walls of orbit, 664.
Frank, Dr., on granular ophthalmia, 46.
—— on rupture of the choroid, 453.
Fraser, Dr., on Calabar bean, 540.
Freeman, Dr., on digital compression of orbital aneurism, 658.
Frontal sinus, diseases of, 660.
—— —— abscess of, 661.
Fundus oculi, ophthalmoscopic appearances of healthy, 305.
Fungus, hæmatodes of eyeball, 370.
Furnari, Dr., on syndectomy, 61.

G.

Galvano-caustic apparatus for destruction of lachrymal sac, 624.
Gerontoxon (arcus senilis), 128.

Gibson's operation for cataract, 252.
Gioppi, Dr., on digital compression of orbital aneurism, 658.
Giraud-Teulon's, Dr., aut-ophthalmoscope, 297.
—— binocular ophthalmoscope, 294.
Gland, lachrymal, diseases of, 606.
—— —— extirpation of, 608.
Glaucoma, 456.
—— acute inflammatory, 459, 463.
—— chronic inflammatory, 467.
—— fulminans, 467.
—— hæmorrhagic form of, 466.
—— iridectomy in, 485.
—— nature and causes of, 474.
—— premonitory stage of, 459.
—— prognosis of, 479.
—— simplex, 470.
—— subacute, 466.
Glioma of retina, 367.
Glio-sarcoma of retina, 367.
Goitre exophthalmic, 634.
Gonorrhœal ophthalmia, 37.
—— iritis, 152.
Graefe, Von, Prof., on amblyopic affections, 396.
—— on bandages for the eye, 12.
—— on treatment of cataract by linear extraction, 252.
—— operation of, for cataract, 258.
—— on use of caustic in ophthalmia, 33.
—— on conical cornea, 131.
—— on cysticercus in vitreous, 323, 324.
—— on ectropium, 709.
—— on embolism of central artery of retina, 363.
—— on entropium, 700.
—— on exophthalmic goitre, 634.
—— on fomentations (warm), 58, 104.
—— on glaucoma, 457.
—— on glioma retinæ, 368, 370.
—— on irido-choroiditis, 192–3.
—— on muscular asthenopia, 601.
—— on muscles of the eye, 548.
—— on tumours of optic nerve, 393.
—— on optic neuritis, 376.
—— on ptosis, 389.
—— on retro-ocular optic neuritis, 384.
—— on detachment of retina, 359.
—— on hyperæsthesia of retina, 366.
—— on central recurrent retinitis, 346.
—— on trichiasis, 697.
—— on sarcoma of choroid, 443.
—— on sclerotico-choroiditis posterior, 431.
—— on operation for staphyloma, 139.
—— on strabismus, 577.
—— on operation for strabismus, 587.
—— on operation for re-adjustment, 598.
—— on sympathetic ophthalmia, 196.
—— on sympathetic choroido-retinitis, 197.
—— on tubercles of the choroid, 440.
Graefe, Alfred, Dr., on ischæmia retinæ, 362.
—— on the muscles of the eye, 549.
Granular ophthalmia (acute), 50.
Granulations, chronic, 53.
—— vesicular, 46.
Graves's disease, 634.
Green's, Dr., test-objects for astigmatism, 529.
Guthrie, Mr., on aneurism of orbit, 655.
Gun Cap in Eye —— 227.271.

H.

Haffmans, Dr., on glaucoma, 470.
Hasner, Dr., on pterygium, 74.
—— on ectropium, 714.
Hæmorrhage into anterior chamber, 183.
—— from choroid, 453.
—— into conjunctiva, 87.
—— into orbit, 659.
—— into retina, 332, 347.
—— into vitreous humour, 316.
—— cerebral, a cause of amaurosis, 402.
Helmholtz, Prof., on accommodation of eye, 500.
—— ophthalmoscope of, 287.
—— on the visual line, 494.
Hemeralopia, 416.
—— in retinitis pigmentosa, 352.
Hemiopia, 398.
—— equilateral or homonymous, 398.
—— temporal, 398.
Herpes of the conjunctiva, 64.
—— of the cornea, 91.
Herzenstein, Dr., on treatment of trichiasis, 694.
—— on stricture of lachrymal passages, 622.
Heurteloup, Baron, artificial leech of, 13.
Hippus, 164.
Hirschberg, Dr., on glioma retinæ, 368, 370.
Hordeolum, 679.
Horner, Dr., on glaucoma, 476.
Hulke, Mr. J. W., on aneurism of orbit, 657.
—— on colloid disease of choroid, 446.
—— on cysts in the iris, 168.
—— on epithelial cancer of orbit, 653.
—— on diseases of frontal sinus, 660.
—— on glioma retinæ, 372.
—— on optic neuritis, 382.
—— on sarcoma of choroid, 446.
—— on sarcoma of orbit, 643.
Hutchinson, Mr. Jonathan, on diffuse corneitis, 120.
—— on glaucoma, 476.
—— on optic neuritis, 377.
—— on pyramida lcataract, 228.
—— on tobacco amaurosis, 387.
Hyalitis, 315.
Hyaloid artery, persistent, 326.
Hydatids of orbit, 646.

Hydrophthalmia, 132.
Hypæmia, 183.
Hyperæmia of conjunctiva, 15.
—— of choroid, 422.
—— of iris, 144.
—— of retina, 327.
Hypermetropia, 499, 517.
—— absolute, 521.
—— acquired, 520.
—— facultative, 521.
—— latent, 520.
—— manifest, 520.
—— ophthalmoscopic diagnosis of, 518.
—— original, 520.
—— relative, 521.
—— a frequent cause of asthenopia, 522.
—— a frequent cause of convergent squint, 523.
Hypopyon, different origins of, 99.

I.

Image, actual, of fundus oculi, 288, 299.
—— virtual, of fundus oculi, 289, 302.
Infinite distance, meaning of term, 489.
Inflammation of cellular tissue of orbit, 627.
—— of choroid, 423.
—— conjunctiva, 16.
—— cornea, 16.
—— edge of the eyelids, 669.
—— of eye generally, 434.
—— of iris, 144.
—— of iris and choroid, 185.
—— of lachrymal gland, 605.
—— of lachrymal sac, 613.
—— of retina, 329.
—— of vitreous humour, 313.
Injection of lachrymal passages, 616.
—— sub-conjunctival, of salt and water in corneal opacities, 126.
Injuries of the ciliary region, 208.
—— of the conjunctiva, 81.
—— of the cornea, 140.
—— of the iris, 165.
—— of the lens, 226.
—— of the lids, 714.
—— of the orbit, 662.
—— of the sclerotic, 213.
Inoculation, as treatment for pannus, 62.
Insufficiency of internal recti muscles, 600.
Interval, focal, 527.
Intraocular tension, mode of estimating degree of, 2.
Inversion of lid, 697.
Iridectomy, mode of performing, 172.
—— in lamellar cataract, 269.
—— in conical cornea, 130.
—— in corneal opacities, 127.
—— in corneitis, 107.
—— in glaucoma, 479, 485.
—— in irido-choroiditis, 190.
—— in iritis, 160.
Iridectomy, indications for performance of, 177.
Irideremia, 170.
Irido-choroiditis, 185.
Irido-cyclitis, 146, 206.
Iridodesis, mode of performing, 178.
—— in lamellar cataract, 269.
—— in conical cornea, 131.
—— in corneal opacities, 127.
Iridodialysis, 181.
Iridodonesis, 165.
Iris, congenital, absence of, 170.
—— cancer of, 169.
—— coloboma of, 170.
—— cysts of, 167.
—— hyperæmia of, 144.
—— inflammation of, 144.
—— injuries of, 165.
—— prolapse of, 111.
—— tremulous, 165.
—— tumours, etc., of, 167.
—— wounds of, 165.
Iritis, 144.
—— chronic, 152.
—— gonorrhœal, 152.
—— idiopathic, simple, 148.
—— parenchymatous, 149.
—— serous, 148.
—— suppurative, 149.
—— sympathetic, 152.
—— traumatic, 151.
Ischæmia of the retina, 362.
Iwanoff on glioma of the retina, 371.
—— on retinitis, 333.
—— on perivascular retinitis, 334.

J.

Jackson, Dr. Hughlings, on epilepsy of retina, 361.
—— on optic neuritis, 378, 380.
Jacobson, Prof., on cataract, 249.
—— on tumour of optic nerve, 393.
Jaeger, Prof. v., on staphyloma posticum, 432.
—— test types of, 4.
Jago, Dr., on entoptics, 319.
Jones, Mr. Wharton, on astigmatism, 525.
—— on operation for ectropium, 708.
Javal, Dr., optometer of, 530.
—— on simulation of amaurosis, 421.
—— on treatment of strabismus, 585.

K.

Keratitis, see corneitis.
Keratocele, 110.
Keratoglobus, 132.
Keratonyxis, see division of cataract, 265.
Knapp, Dr., on astigmatism, 532.

Knapp, Dr., on ectropium, 713.
—— on embolism of choroidal vessels 438.
—— on exostosis of orbit, 645.
—— on metamorphopsia, 356.
—— on glioma of the retina, 372.

L.

Lachrymal apparatus, diseases of, 605.
—— calculus, 626.
—— canals, obstructions of, 612.
—— gland, diseases of, 605.
—— —— cysts of, 606.
—— —— extirpation of, 608.
—— —— fistula of, 607.
—— —— hypertrophy of, 606.
—— —— inflammation of, 605.
—— puncta, eversion of, 610.
—— —— malposition of, 610.
—— —— obliteration of, 612.
—— sac, abscess of, 613.
—— —— blenorrhœa of, 617.
—— —— extirpation of, 625.
—— —— fistula of, 625.
—— —— hæmorrhage into, 626.
—— —— inflammation of, 613.
—— —— obliteration of, 624.
—— —— polypus of, 626.
Lagophthalmos, 689.
Laminaria bougies, 621.
Lapis divinus, 16—note.
Laurence, Mr. Zachariah, on aneurism of orbit, 658.
—— on extirpation of lachrymal gland, 608.
—— binocular ophthalmoscope of, 296.
—— pupillometer of, 161.
—— on retinitis pigmentosa, 353.
—— on simulation of amaurosis, 421.
—— strabismometer of, 555.
Lawson, Mr. George, on atropine, 94—note.
—— on inoculation, 63.
—— on recurrent fibroid orbital tumour, 643.
—— on scirrhus of orbit, 648.
—— on sympathetic ophthalmia, 199.
—— on syndectomy, 64.
—— on traumatic cataract, 227.
—— on wounds of the iris, 166.
Lead, acetate of, in granulations, 58.
—— deposit of, on cornea, 126.
Leared, Dr., on effect of Turkish bath on cerebral circulation, 407—note.
Lens, crystalline, affections of, 215.
—— —— absence of (aphakia), 538
—— —— dislocation of, 277.
Lenses, optical, properties of, 489.
—— spherical, 489.
—— convex, 489.
—— concave, 492.
—— cylindrical, 531.
Leucoma, 122.
Lice of eyelashes, 678.
Lids (see Eyelids).
Lime, effects of, thrown into eye, 83.
Liebreich, Dr., on amaurosis, 397.
—— bandage of, 11.
—— on syphilitic choroiditis, 423.
—— on cysticercus in vitreous, 325.
—— on embolism of central artery of retina, 364.
—— ophthalmoscope of, 290, 293.
—— on pigmentation of optic nerve, 392.
—— on retinitis, 334.
—— on retinitis leucæmica, 343.
—— on retinitis pigmentosa, 353.
—— on operation for strabismus, 594.
—— on operation for re-adjustment, 599.
Listing, Dr., diagrammatic eye of, 495.
—— on entoptics, 319.
Longsightedness, 515.

M.

Macula lutea, ophthalmoscopic appearance of, 305.
Mackenzie, Dr., on cellulitis of orbit, 628.
—— on ectropium, 704.
—— on epithelial cancer of lids, 685.
—— on exostosis of frontal sinus, 660.
—— on exostosis of orbit, 643.
—— on malignant pustule of the lids, 672
Madarosis, 675.
Malignant pustule of lids, 672.
Manz, Dr., on tubercles of choroid, 440.
Marston, Dr., on granular ophthalmia, 46—note, 49.
Mauthner, Dr., on bifurcation of optic nerve fibres, 395.
—— on discoloration of optic nerve, 386.
Maxillary sinus, enlargement of, 662.
Measles, ophthalmia from, 70.
Measure, linear, of squint, 555.
Medullary, carcinoma of choroid, 448.
—— —— of orbit, 650.
Meibomian follicles, obstruction of, 682.
—— glands, inflammation of, 675.
Meissner, on neuro-paralytic ophthalmia, 103.
Melanotic cancer of choroid, 448.
—— cancer of orbit, 653.
Meningitis, a cause of amaurosis, 401.
—— cerebro-spinal, cause of panophthalmitis, 436.
Meridian, vertical, of eye, action of several muscles on, 548.
Mesoropter, muscular, 553.
Metamorphopsia, 336, 356.
Meyer, Dr., on division of ciliary nerves in sympathetic ophthalmia, 205.
Micropsia, 335.
Military ophthalmia, 28.

Metastasis, 37.

Milium, 682.
Molluscum of eyelids, 682.
Mooren, Dr., on cataract, 248.
—— on diphtheritic conjunctivitis, 44.
—— on hyperæsthesia of retina, 367.
—— on telangiectasis of iris, 168.
Morphia, subcutaneous injection of, in poisoning by atropine, 157.
Moss, Mr., on purulent ophthalmia, 33.
Mucocele, 617.
Müller, Prof. Heinrich, on capsular cataract, 227.
—— on colloid disease of choroid, 439.
—— on orbital unstriped muscular fibres, 560—note.
—— on retinitis albuminurica, 340.
—— on retinitis pigmentosa, 351.
Muscæ volitantes, 318.
Muscles of the eye, affections of, 548.
—— —— action of, 548.
—— —— paralysis of, 553.
Muscle-plane, 549.
Muscular asthenopia, 600.
Mydriasis, 160.
Myocephalon, 26.
Myodesopia, 318.
Myopia, 499, 506.
—— ophthalmoscopic diagnosis of, 509.
Myosis, 164.

N.

Nævus maternus of eyelids, 686.
Nagel, Dr., on retinitis, 334.
Nasal duct, exploration of, 619.
—— stricture of, 618.
—— treatment of stricture of, 619.
Near point, 503.
Near sightedness, 506.
Nebulæ of cornea, 122.
Necrosis of orbit, 632.
Negation, active, of retinal image in strabismus, 413, 575.
—— passive, of retinal image in cataract, 230, 413.
Negative accommodation, 502.
Nephritic retinitis, 336.
Neuritis, optic, 375.
Neuro-paralytic affection of cornea, 102.
Neurosis, sympathetic, 195.
Nictitation, 691.
Night-blindness, 416.
Nitrate of silver, action of on conjunctiva, 35.
Nunneley, Mr., on vascular protrusion of eyeball, 657.
Nystagmus, 569.

O.

Oblique illumination, 2.
—— muscles, origin of, 550.
Oblique muscles, functions of, 551.
Obliteration of lachrymal sac, 624.
—— of pupil, 147.
Ocular sheath, 587.
—— —— inflammation of, 633.
Œdema of conjunctiva, 18, 24.
—— of eyelids, 668.
—— of retina, 330.
Onyx, 98.
Opacities of cornea, 122.
—— of lens, 215.
—— of vitreous, 315.
Ophthalmia, Catarrhal, 16.
—— diphtheritic, 40.
—— Egyptian, 22.
—— exanthematous, 70.
—— gonorrhœal, 36.
—— granular, 45.
—— membranous, 24.
—— military, 22.
—— neonatorum, 38.
—— neuroparalytic, 102.
—— phlyctenular, 64.
—— purulent, 22.
—— sympathetic, 194.
—— tarsi, 674.
Ophthalmoscope, mode of using, 298.
—— binocular, of Giraud-Teulon, 294.
—— —— of Laurence and Heisch, 296.
—— of Coccius, 291.
—— of Helmholtz, 287.
—— of Liebreich, 290.
—— of Zehender, 292.
—— fixed, of Liebreich, 293.
—— —— of Smith and Beck, 294.
Ophthalmoscopic appearances of healthy eyes, 304.
Optic axis, 494, 496.
—— disc, normal, ophthalmoscopic appearances of, 306.
—— nerve, diseases of, 375.
—— —— atrophy of, 385.
—— —— consecutive atrophy of, 387.
—— —— simple progressive atrophy of, 386.
—— —— in cerebral amaurosis, 400.
—— —— condition of in tobacco amaurosis, 387.
—— —— discoloration of, 386—note.
—— —— excavation or cupping of, 388.
—— —— of from atrophy, 389.
—— —— congenital excavation of, 388.
—— —— glaucomatous excavation of, 390.
—— —— fibres, opaque, 393.
—— —— inflammation of, 375.
—— —— pigmentation of, 392.
—— —— tumours of, 393.
Optic neuritis, 375.
—— ascending, 376.
—— descending, 376.
—— retro-ocular, 384.
Optometer of Von Graefe, 506.
—— of Javal, 530.

Percussion cap in Eye — 227. 271

Orbicularis palpebrarum, palsy of, 689.
—— —— spasm of, 690.
Orbit, diseases of, 627.
—— abscess of, 627.
—— aneurisms of, 654.
—— diffuse or false aneurism of, 655.
—— true aneurism of, 655.
—— caries of, 632.
—— cellulitis of, 627.
—— emphysema of, 660.
—— exostosis of, 643.
—— fractures of, 664.
—— hæmorrhage into, 659..
—— hydatids in, 646.
—— inflammation of cellular tissue of, 627.
—— injuries of, 662.
—— necrosis of, 632.
—— periostitis of, 630.
—— pressure upon, from neighbouring cavities, 660.
—— wounds of, 662.
—— tumours of, 638.
—— —— cartilagineous, 643.
—— —— cavernous, 653.
—— —— cystic, 645.
—— —— erectile, 654.
—— —— fatty, 643.
—— —— fibrous, 639.
—— —— osseous, 643.
—— —— sarcomatous (fibro-plastic), 640.
—— —— vascular, 653.
—— cancer of, 647.
—— —— epithelial, 653.
—— —— medullary, 650.
—— —— melanotic, 653.
—— —— scirrhus, 648.
Orthoscopic spectacles of Dr. Scheffler, 545.
Oscillation of eyeballs, 569.

P.

Pagenstecher, Dr., on extraction of cataract, 251.
—— on operation for entropium, 701.
—— on yellow oxide of mercury ointment, 68.
Pannus, 89.
—— from granulations, 56, 90.
—— herpeticus, 65, 91.
—— traumatic, 55.
Panophthalmitis, 434.
Pantoscopic spectacles, 544.
Paracentesis corneæ, 100, 113.
Paralysis of muscles of the eye, 553.
—— of fourth nerve, 563.
—— of sixth nerve, 553.
—— of third nerve, 559.
—— of portio dura of seventh nerve, 689.
Paralysis of the levator palbebræ superioris, 687.
—— of the orbicularis palpebrarum, 689.
Perforation of cornea, 111.
Periostitis of orbit, 630.
Periscopic spectacles, 544.
Peritomy, 61.
Perivascular retinitis, 334.
Phlegmonous inflammation of eyelids, 669.
Phlyctenular ophthalmia, 64.
Phlyctenulæ of cornea, 91.
Phosphènes, 493.
Photophobia, 69.
Phtheiriasis of the eyelashes, 678.
Phthisis oculi, 188.
Pinguecula, 84.
Piringer, on contagiousness of conjunctival discharge, 28.
Polycoria, 171.
Polyopia, monocular, 528.
Polypi of lachrymal sac, 626.
Pope, Dr., on retinitis pigmentosa, 351.
Prael, Dr., on exophthalmic goitre, 634.
Presbyopia, 515.
Pressure, intraocular, 2, 459.
—— bandage, 13.
Prisms, the action of, 10.
—— in muscular asthenopia, 602.
—— in strabismus, 584.
Prismatic spectacles, 544.
Probes, lachrymal, 619.
—— laminaria, 621.
Prolapse of iris, 115, 244.
Prothesis oculi, 666.
Protrusion of globe, 634, 638.
Pterygium, 73.
Ptosis, 687.
Puncta lacrymalia, 610.
—— —— eversion of, 610.
—— —— malposition of, 610.
—— —— obliteration of, 612.
—— —— obstruction of, 612.
Punctum proximum, 503.
—— remotissimum, 503.
Pupil, artificial, operations for, 172.
—— —— by incision, 180.
—— —— by iridectomy, 172.
—— —— by iridodesis, 178.
—— —— by iridodialysis, 181.
—— dilatation of, 160.
—— adhesions of, 147.
—— contraction of, 164.
—— exclusion of, 147.
—— occlusion of, 147.
—— action of atropine on, 161.
—— action of Calabar bean on, 162.
Pupillary membrane, persistence of, 171.
Pupillometer, Mr. Laurence's, 161.
Purulent ophthalmia, 22.
Pustular ophthalmia, 64.
Pustule, malignant of eyelid, 672.

Q.

Quinine, amblyopia from excessive use of, 412.

R.

Range of accommodation, 503.
—— absolute, 503.
—— binocular, 505.
—— relative, 505.
—— —— negative, 506.
—— —— positive, 505.
Re-adjustment, operation of, 569, 598.
—— —— Critchett's, 599.
—— —— Von Graefe's 598.
—— —— Liebreich's, 599.
Reclination of cataract, 265.
Recti muscles, functions of, 551.
—— —— origin of, 550.
—— —— insufficiency of internal, 600.
Rectus muscle, paralysis of external, 553.
—— —— of inferior, 562.
—— —— of internal, 560.
—— —— of superior, 561.
Refraction of the eye, 488, 498.
—— diseases of, 498.
—— different in the two eyes, 546.
Refracting media, ophthalmoscopic examination of, 310.
Retina, diseases of, 327.
—— anæsthesia of, 418.
—— aneurism of central artery of, 655.
—— atrophy of, 374.
—— detachment of, 353.
—— embolism of central artery of, 363.
—— epilepsy of, 361.
—— glioma of, 367.
—— hyperæmia of, 327.
—— hyperæsthesia of, 366.
—— inflammation of, 329.
—— ischæmia of, 362.
—— operation upon the, in detachment of retina, 359.
—— paralysis of, 414.
—— tumours of, 367.
Retinitis, 329.
—— albuminurica (nephritic) 336.
—— apoplectica, 347.
—— central recurrent, 346.
—— idiopathic, 329.
—— leucæmic, 343.
—— parenchymatous, 331.
—— perivascular, 334.
—— pigmentosa, 349.
—— serous, 329.
—— syphilitic, 343.
Retro-ocular neuritis, 384.
Rheumatic iritis, 151.
Robertson, Dr. Argyle, on Calabar bean, 540.
Romberg, Prof., on blepharospasm, 691.
Rothmund, Dr., on subconjunctival injection of salt and water in corneal opacities, 126.
Rupture of the choroid, 451.

S.

Sac, lachrymal, diseases of, 613.
—— —— destruction of, 624.
Saemisch, Dr., on foreign bodies in anterior chamber, 183.
Sarcoma of choroid, 443.
—— of ciliary body, 448.
—— of orbit, 640.
Scalping the eyelids, 695.
Scarlatina, ophthalmia in, 70.
Scheffler, Dr., on spectacles, 545.
Schultze, Prof. Max., on colour blindness, 419.
Schiff, Dr., on neuro-paralytic ophthalmia, 104.
Schweigger, Prof., on astigmatism, 532.
—— on capsular cataract, 227.
—— on glioma retinæ, 370.
—— on retinitis albuminurica, 339.
—— on retinitis pigmentosa, 350.
—— on staphyloma posticum, 431.
Scirrhus of orbit, 648.
Sclerotic, diseases of, 209.
—— injuries and wounds of, 213.
Sclerectasia posterior, 427.
Sclerotico-choroiditis posterior, 427.
Scoop extraction, 255.
Scotomata, 399, 406.
Sebaceous cysts of eyelids, 683.
Secondary cataract, 274.
Seeley, Dr., on use of style, 623.
Seton in corneitis, 97, 114.
Sheath, ocular, 587.
Shields, glass, in symblepharon, 78.
Short-sightedness, 506.
Sinus, frontal, diseases of, 660.
—— —— abscess of, 661.
Slitting up of the punctum, 610.
Small-pox, ophthalmia in, 70.
Snellen, Dr., test-types of, 4.
—— on neuro-paralytic ophthalmia, 103.
Snow blindness, 418.
Solution of cataract, 265.
Sous, Dr., on aneurism of central artery of retina, 655.
Spasm of the ocular muscles, 569.
—— of the eyelids, 690.
Specks of cornea, 122.
Spectacles, 542.
—— curved blue, 545.
—— decentred, 544.
—— decentred of Giraud-Teulon, 544.
—— mica, Dr. Cohn's, 546.
—— orthoscopic, of Scheffler, 545.
—— pantoscopic, 544.
—— periscopic, 544.
—— prismatic, 544.

Spectacles, stenopaic, in corneal opacities, 127.
—— in different refraction of the two eyes, 546.
Sperino, Dr., on paracentesis of cornea as a cure for cataract, etc., 273.
Spinal cord, diseases of, a cause of amaurosis, 403.
Squint, vide Strabismus.
Staphyloma, 111.
—— of cornea and iris, 134.
—— treatment of, 134—140.
—— Borelli's operation for, 140.
—— Critchett's operation for, 137.
—— operation by excision, 136.
—— Graefe's operation for, 139.
—— anterior sclerotic, 210.
—— posterior, 427.
—— racemosum, 112.
Stauung's papille, 376.
Steinheil's glass cone, 513.
Stellwag von Carion on granulations, 45.
Stillicidium lacrymarum, 609.
Stilling, Dr., operation of, for stricture of lachrymal passages, 622.
Strabismometer of Mr. Laurence, 555.
Strabismus, 571.
—— active negation of retinal image in, 575.
—— primary deviation in, 554.
—— secondary deviation in, 554.
—— linear measurement of, 555.
—— alternans, 575.
—— apparent, 524, 578.
—— concomitans, 572.
—— convergent, 579.
—— —— in hypermetropia, 523, 580.
—— —— in myopia, 582.
—— divergent, 582.
—— —— in myopia, 582.
—— monolateral, 575.
—— paralytic, 554, 558.
—— periodic, 580.
—— treatment of, 584.
—— orthopædic treatment of, 584.
—— Javal's orthopædic treatment of, 585.
—— treatment of, by operation, 585.
—— Critchett's operation for, 593.
—— Von Graefe's operation for, 587.
—— Liebreich's operation for, 594.
—— paralytic, operation for, 598.
—— periodic, operation for, 596.
—— secondary, operation for, 598.
Streatfeild, Mr., on corelysis, 180.
—— on entropium, 702.
—— on operation for obliterated puncta, 612.
Stricture of lachrymal passages, 618.
—— of nasal duct, 618.
Stromeyer, Dr., on granular ophthalmia, 47.
Stye on the lids, 679.
Style, lachrymal, 623.
Suction syringe for cataract, use of, 272
—— —— Mr. Bowman's, 272.
—— instrument, Mr. Teale's, 272.
Supra-orbital nerve, division of, in blepharospasm, 691.
Suture, conjunctival, in strabismus operation, 591.
Symblepharon, 77.
—— operations for, 78.
—— Arlt's operation for, 79.
—— Teale's operation for, 79.
Sympathetic ophthalmia, 194.
—— choroido-retinitis, 197.
—— irido-cyclitis, 195.
—— serous iritis, 197.
—— neurosis, 195.
Synchysis, 320.
—— sparkling, 321.
Syndectomy, 61.
Synechia, 147.
—— annular, 147.
—— anterior, 111.
—— posterior, 147.
Syndectomy, 61.
Syphilitic choroiditis, 423.
—— corneitis, 117.
—— iritis, 150.
—— retinitis, 343.
—— ulcers of conjunctiva, 87.
—— ulcers of eyelids, 673.
Syringe for lachrymal apparatus, 616.
—— suction, for removal of cataract, 272.
Szokalski on orbital aneurism, 658.

T.

Tarsal cysts, 681.
—— ophthalmia, 674.
Tarsoraphia, 706.
Taylor, Dr., on cataract, 263.
Teale, Mr. Pridgin, on removal of cataract by suction, 272.
—— on cysticercus in anterior chamber, 184.
—— on mercury and atropine in iritis, 158.
—— on method of examining the field of vision, 8.
—— on operation for symblepharon, 79.
Telangiectasis of iris, 168.
—— of eyelids, 686.
Tenon, capsule of, 587.
—— inflammation of capsule of, 633.
Tenonitis, 633.
Tension, intra-ocular, mode of estimating, 2.
—— —— in glaucoma, 459.
—— —— in detached retina, 358.
—— —— in intra-ocular tumours, 369, 445.
Tenotomy for strabismus, 585.
Third nerve, paralysis of, 559.

Tinea tarsi, 674.
Tobacco amaurosis, 411.
Trachoma, 54.
Transplantation of cilia, 696.
—— operation of, for restoration of eyelid, 710.
Traumatic cataract, 226, 270.
Tremulous iris, 165.
Trichiasis, 692.
Truss, Mr. Critchett's, for lachrymal sac, 623.
Tubercles of the choroid, 440.
Tumours, cerebral, a cause of amaurosis, 402.
—— of choroid, 443.
—— of conjunctiva, 83.
—— of cornea, 143.
—— of eyelids, 681.
—— of iris, 167.
—— of optic nerve, 393.
—— of orbit, 638.
—— of retina, 367.
Turpentine, use of, in iritis, 159.
Twitching of eyelids, 691.
Tylosis, 674.

U.

Ulcers of cornea, 108.
—— syphilitic, of eyelids, 672.
Unguis, 98.

V.

Vanzetti, Dr., on orbital aneurism, 658.
Variolous ophthalmia, 70.
Venous pulsation of central vessels of the retina, 308.
Vernon, Mr., on tubercle of choroid, 442.
Vesicular granulations, 46.
Vessels, conjunctival, 17—note.
—— sclerotic, 17.
—— subconjunctival, 17.
Virchow, Prof., on exophthalmic goitre, 634.
—— on glioma of the retina, 368, 370.
—— on sarcoma of choroid, 446.
—— on sarcoma of orbit, 641.
Visual angle, 496.
—— line, 494, 496
Vision, binocular, mode of examination of, 576.
—— —— in strabismus, 575.
—— field of, mode of examination of, 5.
Vitreous humour, diseases of, 313.
—— —— cholesterine crystals in, 321.
—— —— cysticercus in, 323.
—— —— fluid condition of, 320.
—— —— foreign bodies, in, 321.
—— —— hæmorrhage into, 316.
—— —— inflammation of, 313.
Vitreous humours, neo-plastic formations in, 326.
—— —— new blood-vessels in, 326.
—— —— opacities of, 315.

W.

Walton, Mr. Haynes, on exostosis of orbit, 645.
Warlomont, Dr., on chromhydrosis, 679.
—— on Stilling's operation, 622.
Warts on conjunctiva, 85.
—— on eyelids, 684.
Watery eye, 609.
Watson, Mr. Spencer, on setons in corneitis, 114—note.
Weakness of sight (asthenopia), 522.
Weber, Dr., on abscess of cornea, 99.
—— canaliculus knife of, 620.
—— on corelysis, 180.
—— graduated lachrymal sound of, 620.
—— on persistence of pupillary membrane, 171.
Wecker, Dr. on fistula of cornea, 117.
—— on method of examining visual field, 8.
—— on foreign bodies in anterior chamber, 183.
—— on removing lens in its capsule, 251.
—— on myoma of choroid, 449.
—— ointment of, for tinea tarsi, 677.
—— on detached retina, 361.
Wedl, Prof., on colloid disease of choroid, 439.
Wegner, Dr., on glaucoma, 476.
Welz, von, Dr., on simulation of amaurosis, 420.
Wordsworth, Mr., on glass shields in symblepharon, 79.
—— on tobacco amaurosis, 411.
Wounds of cornea, 140.
—— of eyelids, 714.
—— of iris, 165.
—— of lens, 226.
—— of orbit, 662.
—— of sclerotic, 213.

Mude. v iii, 13).

X.

Xerophthalmia, 72.

Z.

Zehender, Prof., ophthalmoscope of, 292.
—— on fistula of cornea, 117.
—— on orbital tumours, 640.
Zinc, chloride of paste, in orbital tumours, 642.

Zittmann's Decoction, 5

LONDON
HARRISON AND SONS, PRINTERS IN ORDINARY TO HER MAJESTY, ST. MARTIN'S LANE.

UNIVERSITY OF CALIFORNIA LIBRARY
Los Angeles
This book is DUE on the last date stamped below.

Form L9–Series 4939